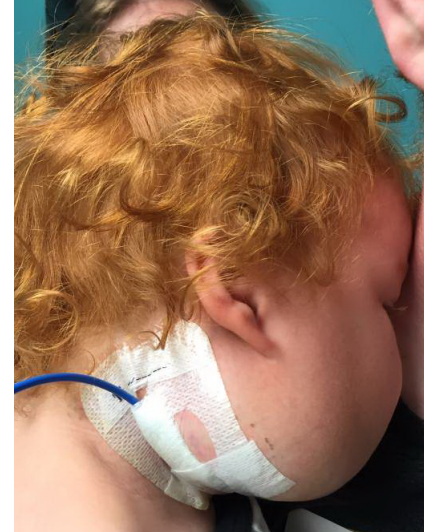
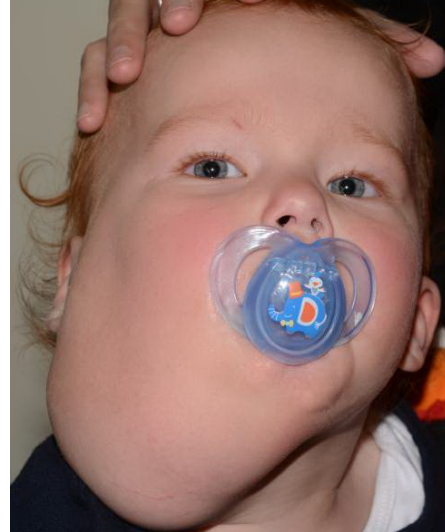
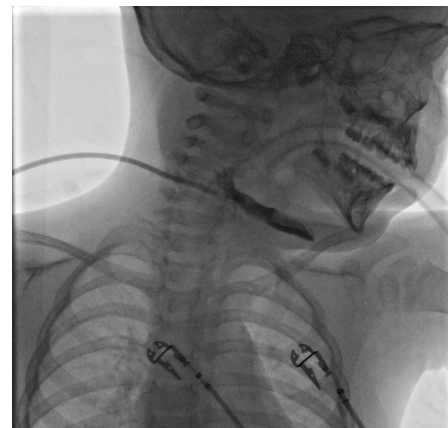
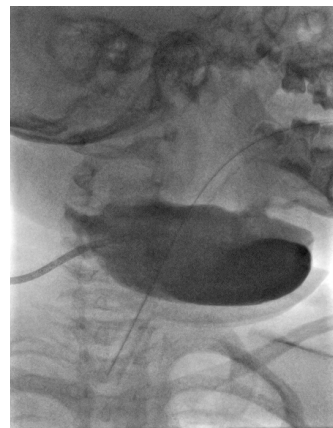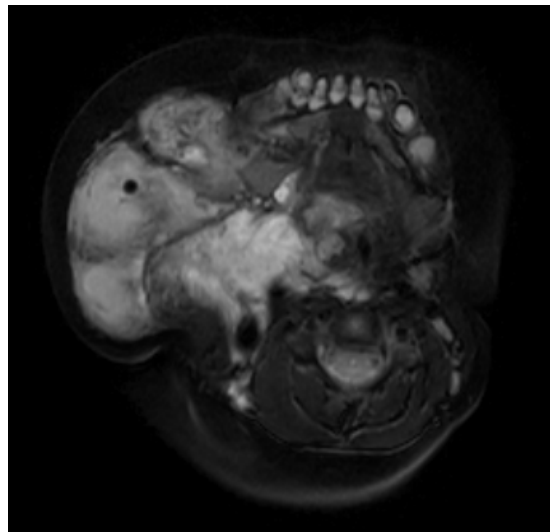
Case 1: a pain in the neck

- HPI: 2 year with chronic refractory right face/neck mixed LM with episodic swelling triggered by infection compromising airway
- First surgical debulking
- Rapid development of additional micro and macrocysts → additional sclerotherapy
- Adjuvant sirolimus oral therapy
- Second surgical debulking



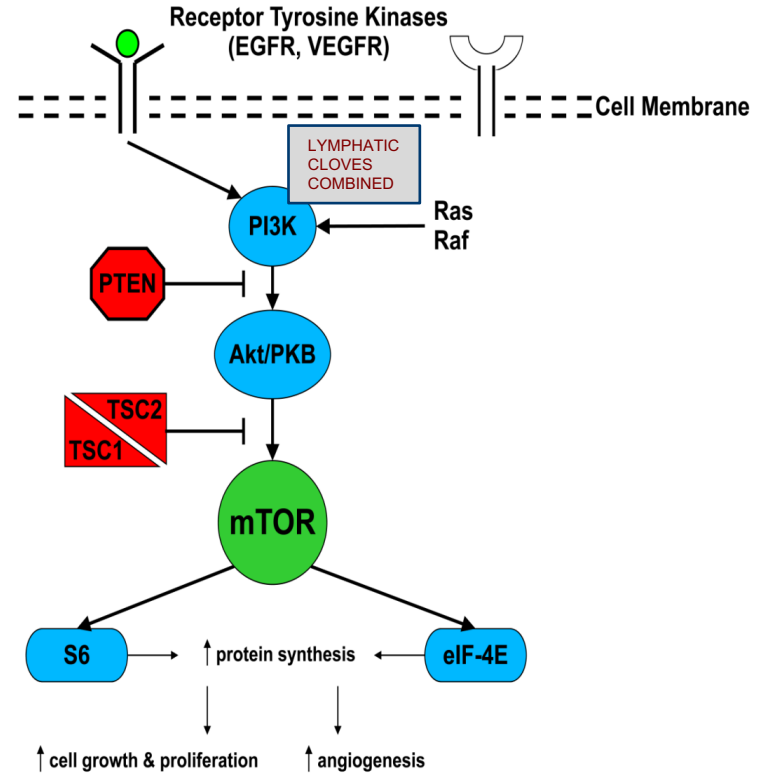
Case 1: a pain in the neck

- HPI: 2 year with chronic refractory right face/neck mixed LM with episodic swelling triggered by infection compromising airway
- First surgical debulking
- Rapid development of additional micro and macrocysts → additional sclerotherapy
- Adjuvant sirolimus oral therapy
- Second surgical debulking



Sirolimus (Rapamycin)

- Inhibitor of the mammalian target of rapamycin
- PI3K/AKT pathway critical to cell growth and governs normal vascular development
- Use has progressed from compassionate use, to phase I & II trials



Sirolimus References:

1. Blatt J, Stavas J, Moats-Staats B, Woosley J, Morrell DS. Treatment of childhood kaposiform hemangioendothelioma with sirolimus. *Pediatr Blood Cancer*. 2010;55(7):1396-8.
2. Hammill AM, Wentzel M, Gupta A, Nelson S, Lucky A, Elluru R, et al. Sirolimus for the treatment of complicated vascular anomalies in children. *Pediatr Blood Cancer*. 2011;57(6):1018-24.
3. Kai L, Wang Z, Yao W, Dong K, Xiao X. Sirolimus, a promising treatment for refractory Kaposiform hemangioendothelioma. *J Cancer Res Clin Oncol*. 2014;140(3):471-6.
4. McCormack FX, Inoue Y, Moss J, Singer LG, Strange C, Nakata K, et al. Efficacy and safety of sirolimus in lymphangioleiomyomatosis. *N Engl J Med*. 2011;364(17):1595-606.
5. Czechowicz JA, Long-Boyle JR, Rosbe KW, Mathes EF, Frieden IJ, Shimano KA. Sirolimus for management of complex vascular anomalies - A proposed dosing regimen for very young infants. *Int J Pediatr Otorhinolaryngol*. 2018;105:48-51.
6. Triana P, Dore M, Cerezo VN, Cervantes M, Sanchez AV, Ferrero MM, et al. Sirolimus in the Treatment of Vascular Anomalies. *Eur J Pediatr Surg*. 2017;27(1):86-90.
7. Mizuno T, Fukuda T, Emoto C, Mobberley-Schuman PS, Hammill AM, Adams DM, et al. Developmental pharmacokinetics of sirolimus: Implications for precision dosing in neonates and infants with complicated vascular anomalies. *Pediatr Blood Cancer*. 2017;64(8).
8. Gildener-Leapman JR, Rosenberg JB, Barmettler A. Proptosis Reduction Using Sirolimus in a Child With an Orbital Vascular Malformation and Blue Rubber Bleb Nevus Syndrome. *Ophthal Plast Reconstr Surg*. 2017;33(3S Suppl 1):S143-S6.
9. Erickson J, McAuliffe W, Blennerhassett L, Halbert A. Fibroadipose vascular anomaly treated with sirolimus: Successful outcome in two patients. *Pediatr Dermatol*. 2017;34(6):e317-e20.
10. Yesil S, Tanyildiz HG, Bozkurt C, Cakmakci E, Sahin G. Single-center experience with sirolimus therapy for vascular malformations. *Pediatr Hematol Oncol*. 2016;33(3):219-25.
11. Adams DM, Trenor CC, 3rd, Hammill AM, Vinks AA, Patel MN, Chaudry G, et al. Efficacy and Safety of Sirolimus in the Treatment of Complicated Vascular Anomalies. *Pediatrics*. 2016;137(2):e20153257.
12. Lackner H, Karastaneva A, Schwinger W, Benesch M, Sovinz P, Seidel M, et al. Sirolimus for the treatment of children with various complicated vascular anomalies. *Eur J Pediatr*. 2015;174(12):1579-84.
13. Trenor CC, 3rd. Sirolimus for refractory vascular anomalies. *Pediatr Blood Cancer*. 2011;57(6):904-5.

