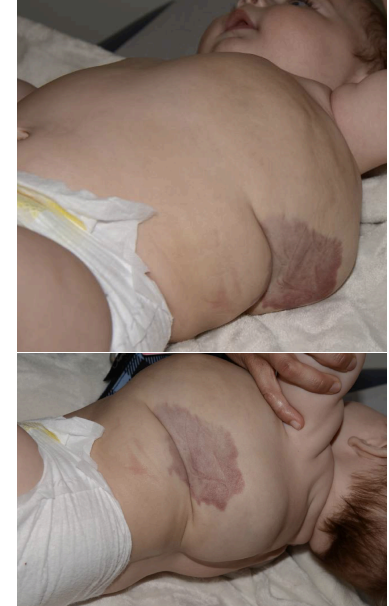
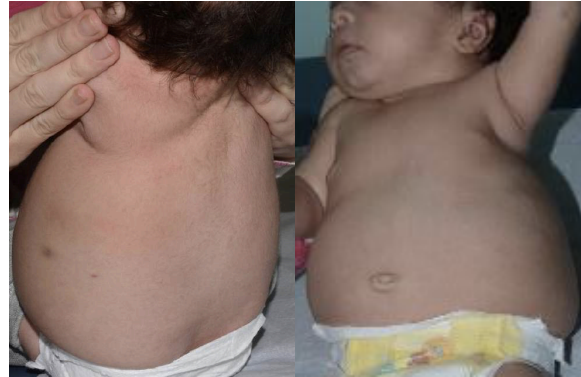
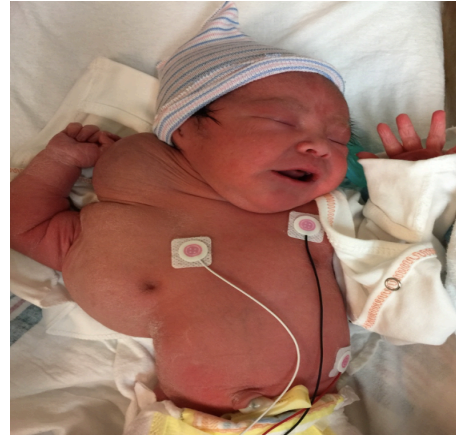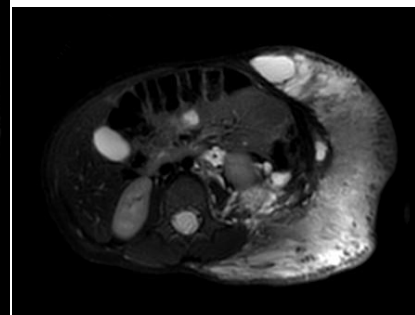
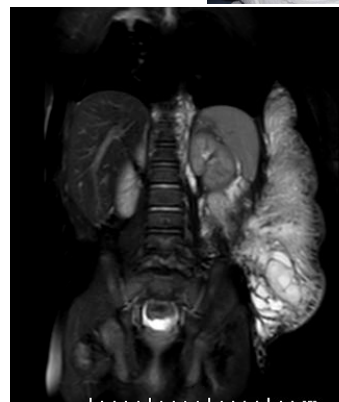
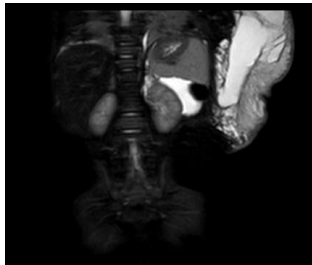
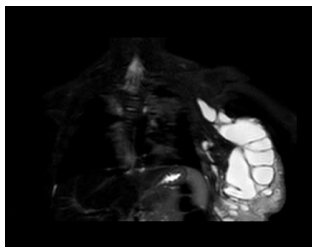
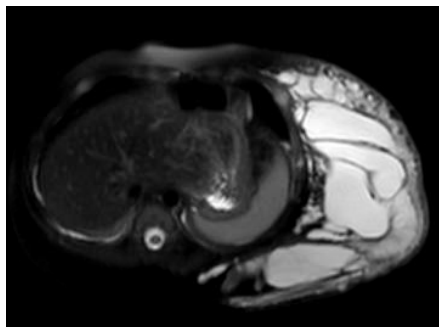
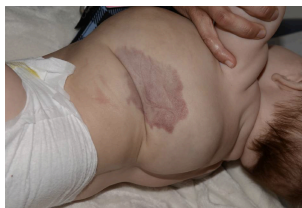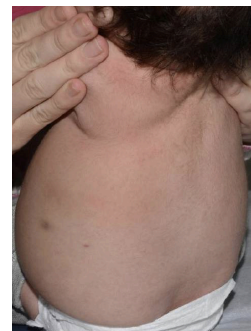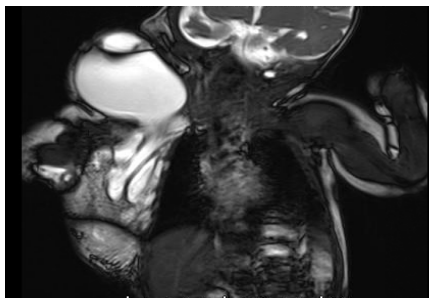
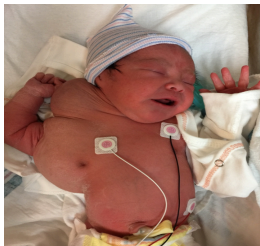## Case 2: Thorn in my side

- Infants born with chest wall masses
- No antenatal diagnoses
- Referred for evaluation



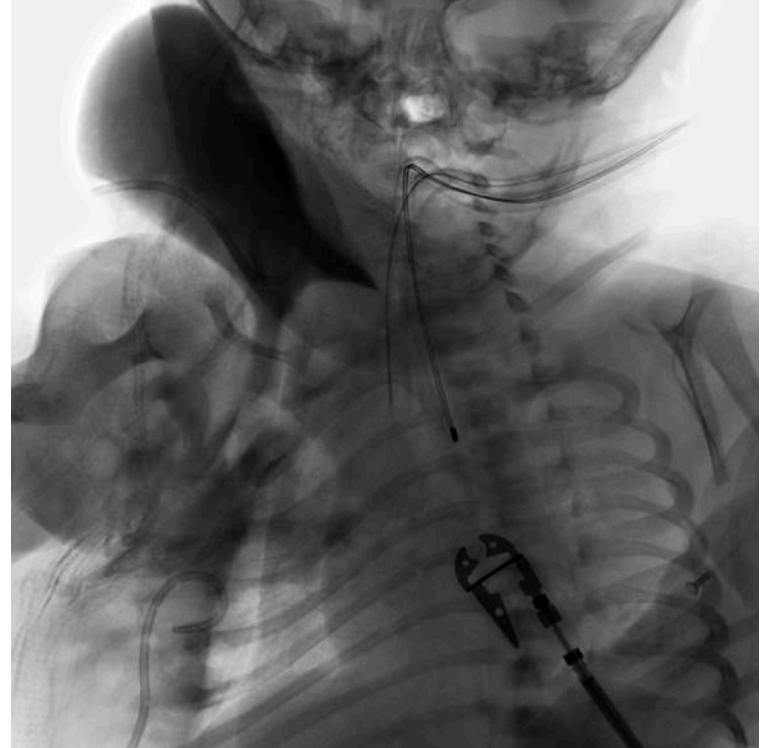**4. What is the proper diagnosis?**

**5. When is the right time to get imaging?**



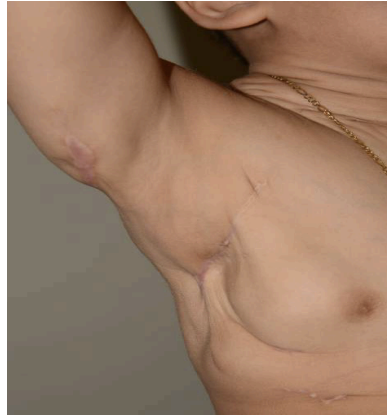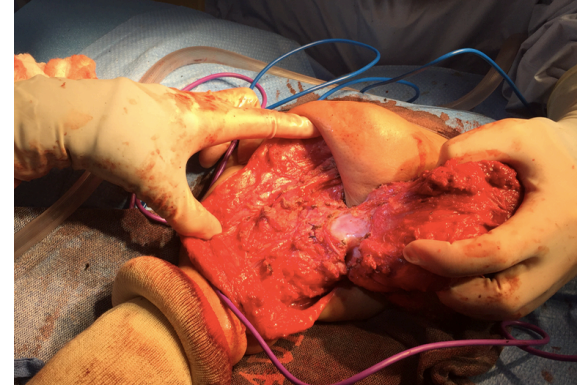
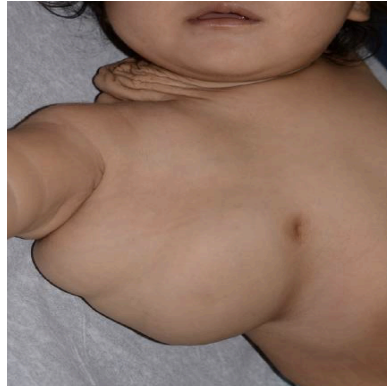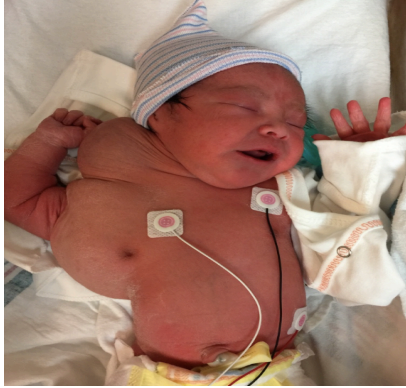## Sclerotherapy

- Macrocystic component
- Doxycycline
- Usually about 3 rounds

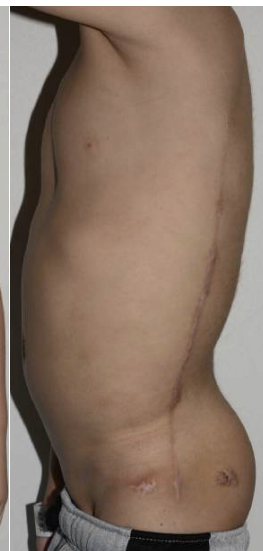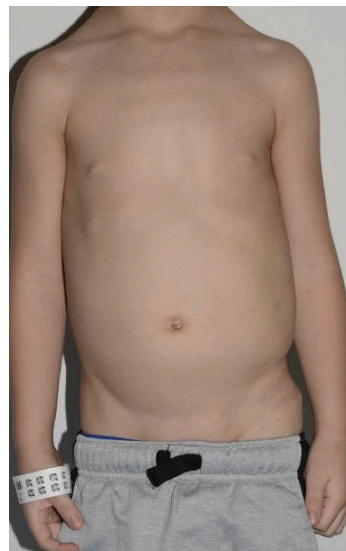
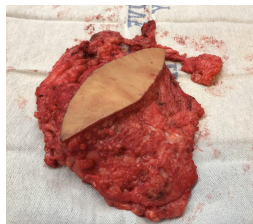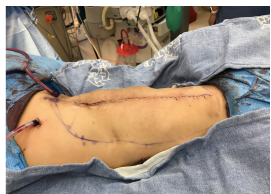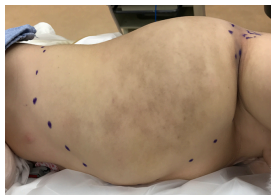


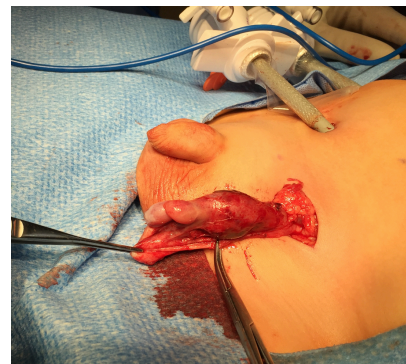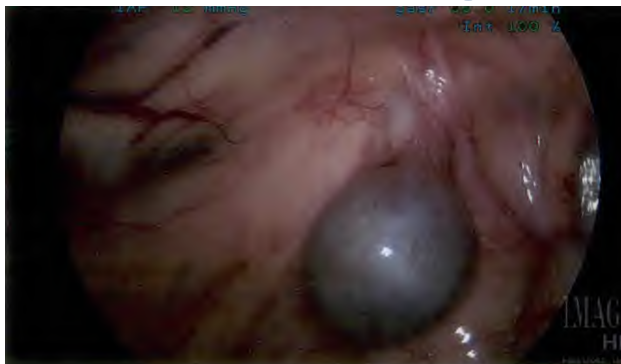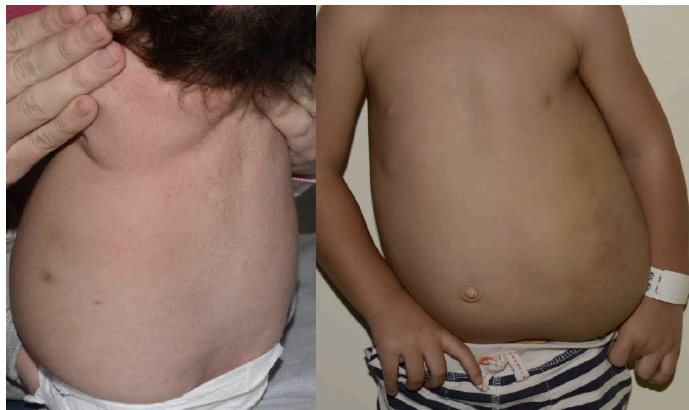## 6. What are this child's therapeutic options?

# Surgical Debulking



# Surgical Debulking: Detours



# Complications: Intralesional Infection

