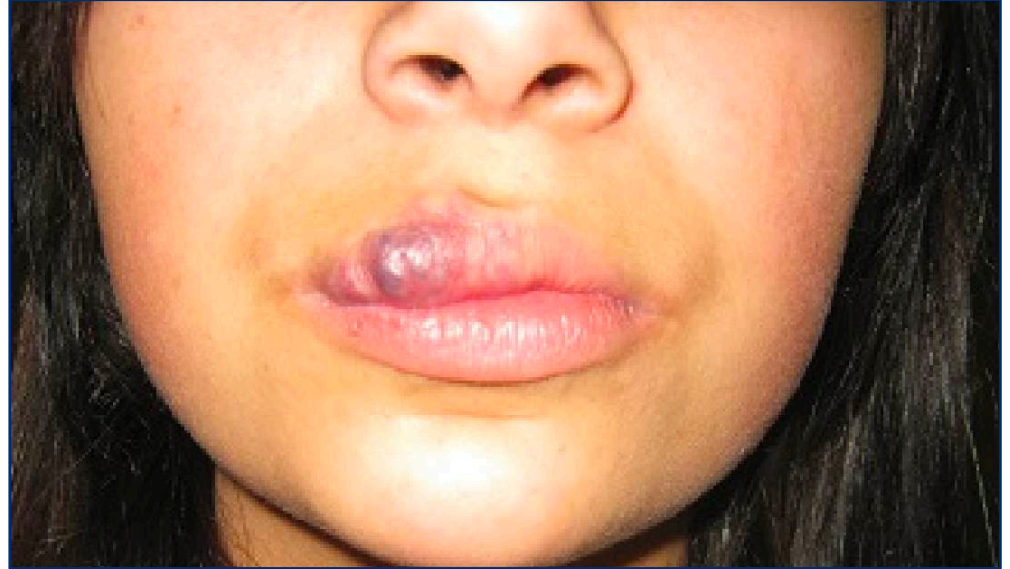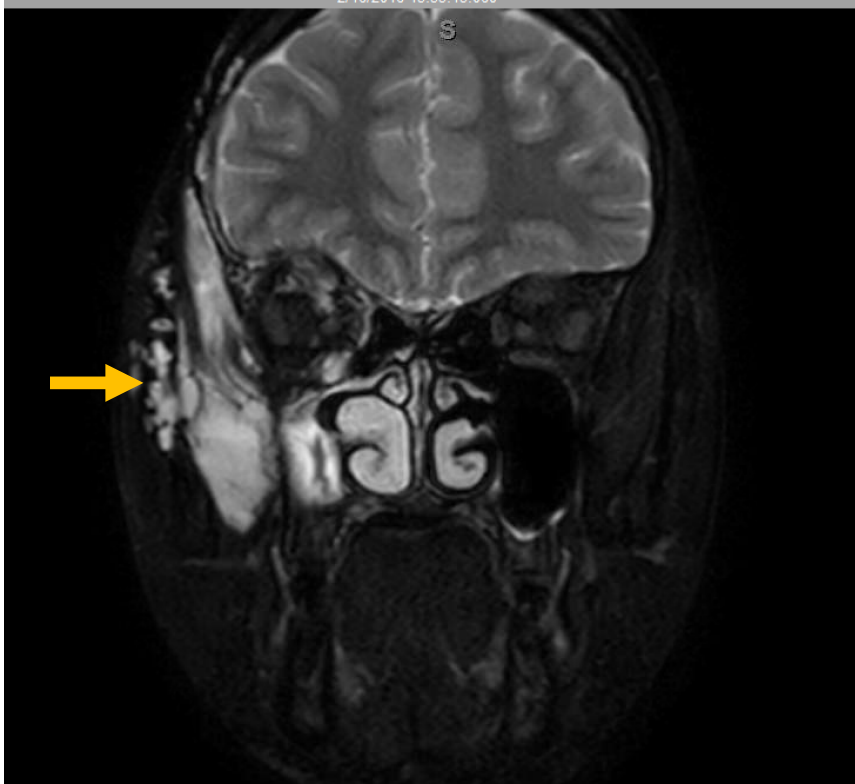


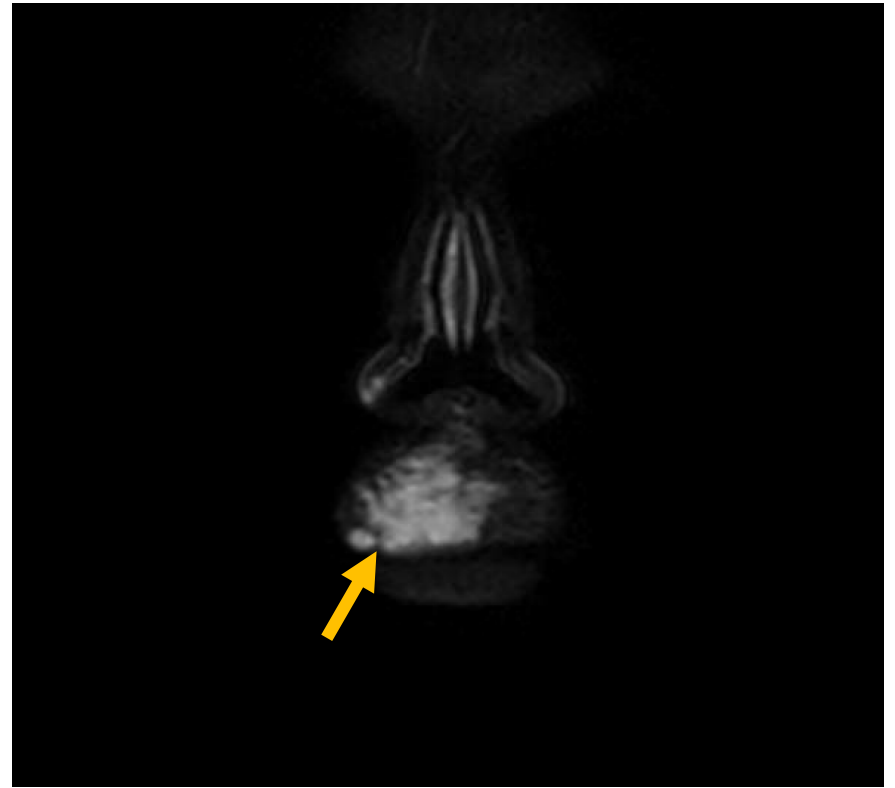
Case 2: a lip lesion

- 17-year-old female referred to your clinic with a history of multiple craniofacial venous malformations.
- Noted blue discoloration since infancy on right lip and eyelid.
- S/p previous attempt at surgical resection.





Coronal MRI of the face noting the right temporal VM



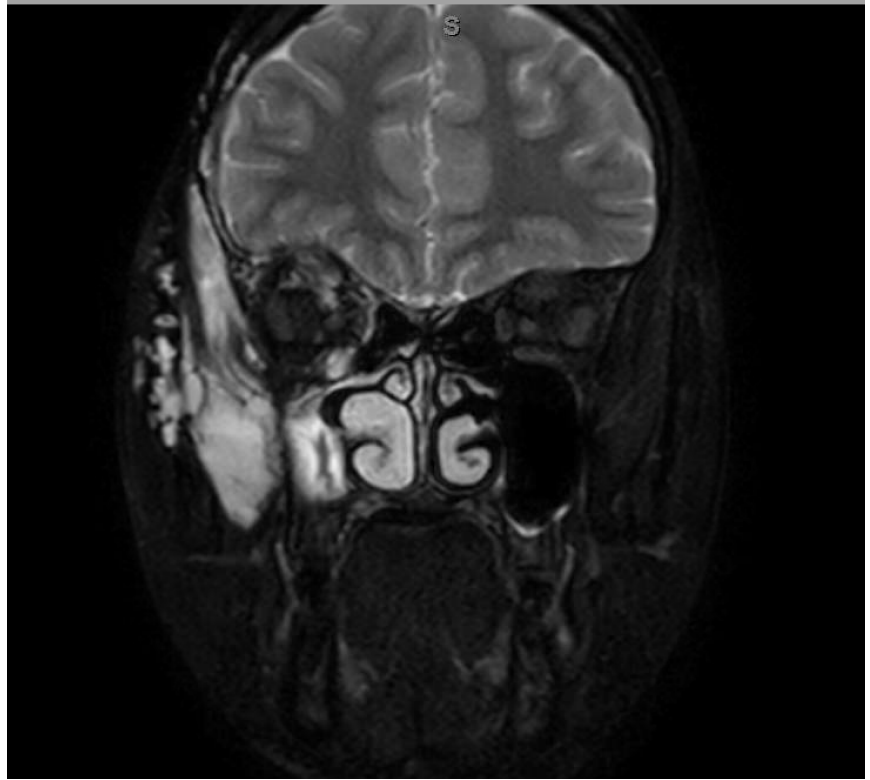
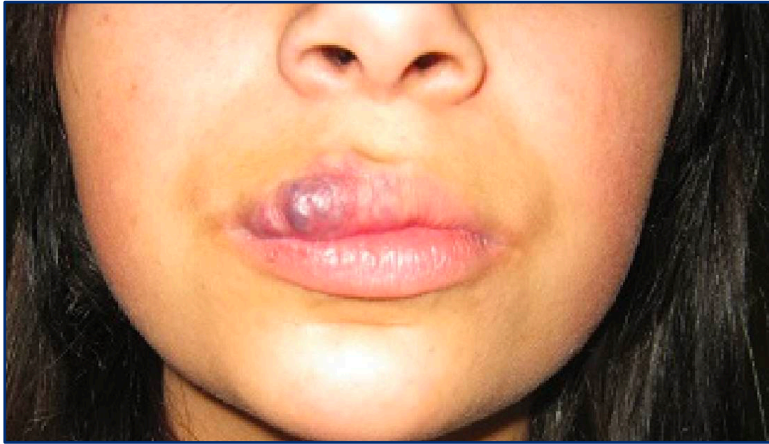Coronal MRI of the face noting the upper lip VM

Case 2: a lip lesion

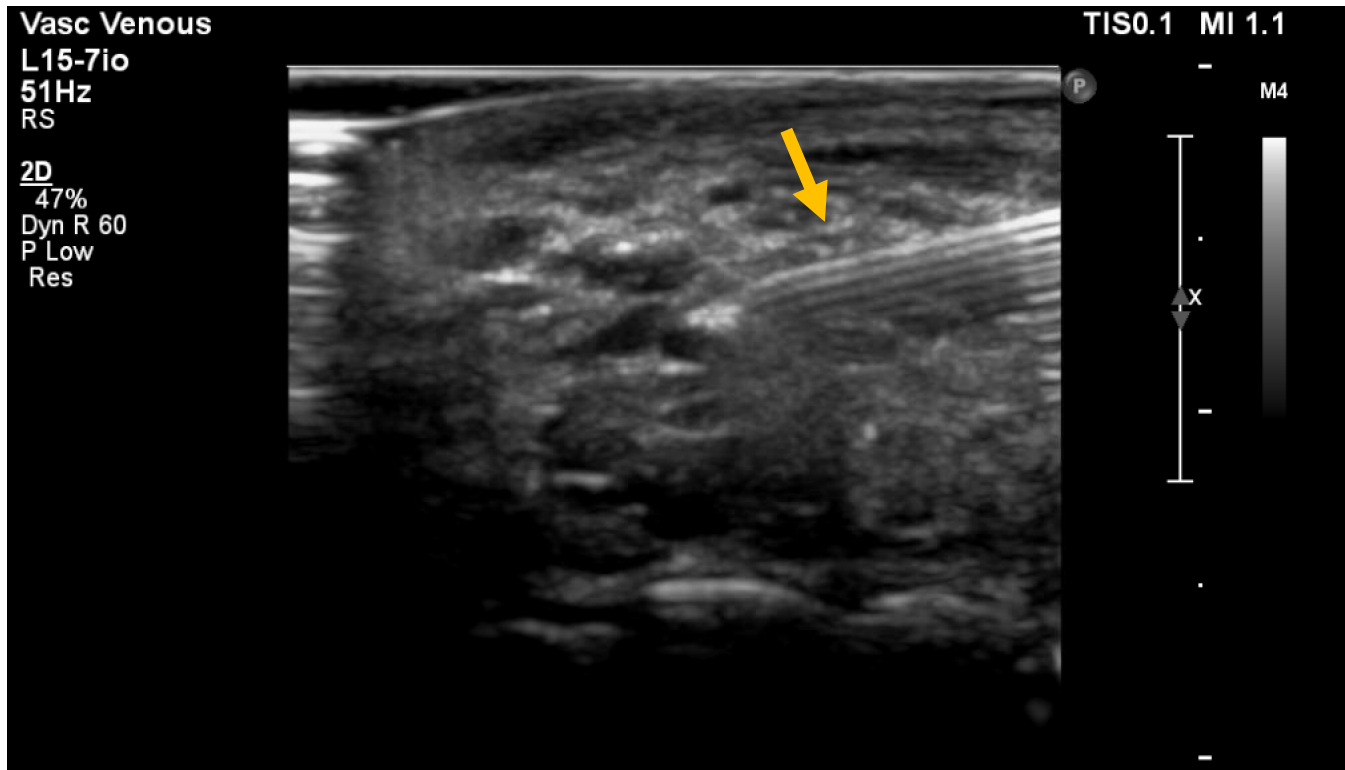
- 17-year-old female referred to your clinic with a history of multiple craniofacial venous malformations.
- Noted blue discoloration since infancy on right lip and eyelid.
- S/p previous attempt at surgical resection.

LAB EVALUATION	RESULTS	
D-dimer	0.27	Elevated
PT	14.4	Normal
aPTT	30.6	Normal
Fibrinogen	294	Normal

What are this child's therapeutic options?

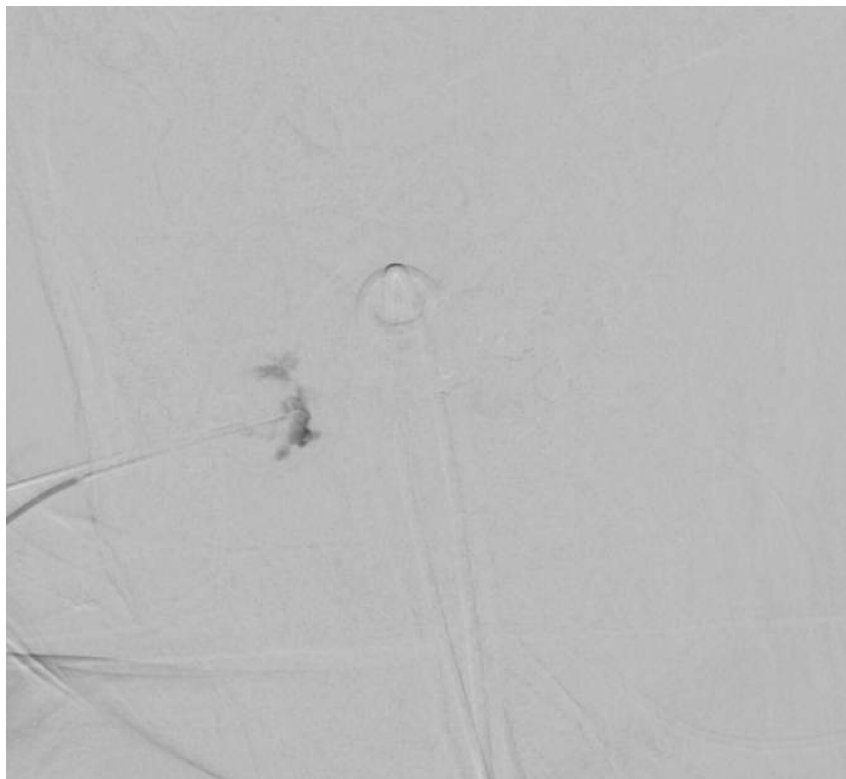


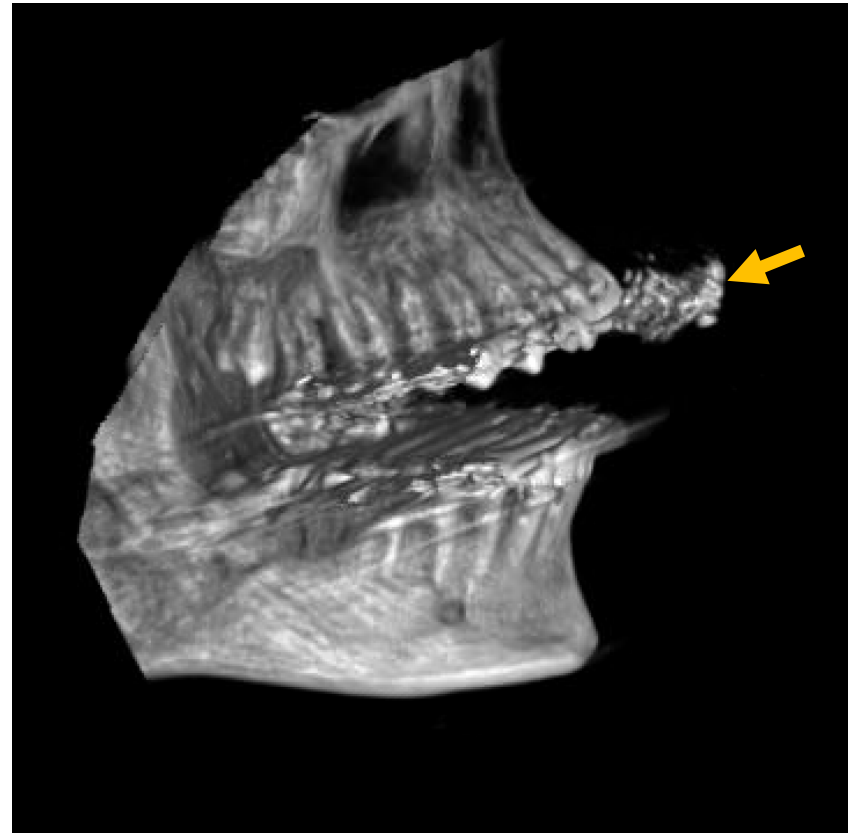
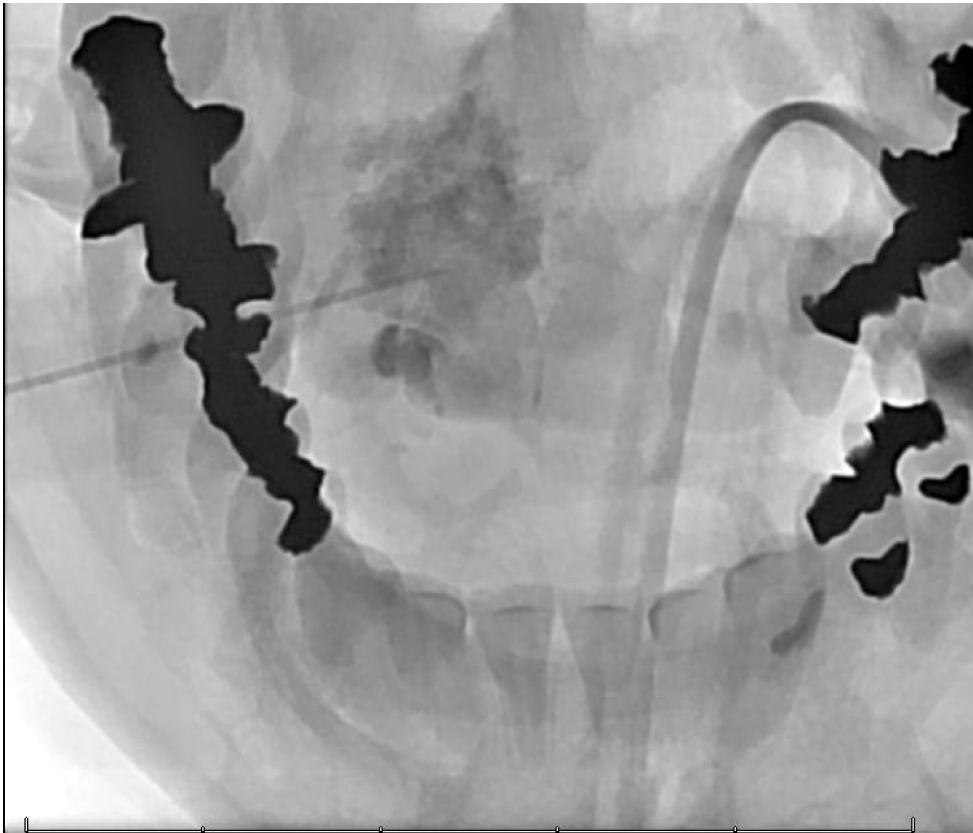
Should this patient receive periprocedural anticoagulation?



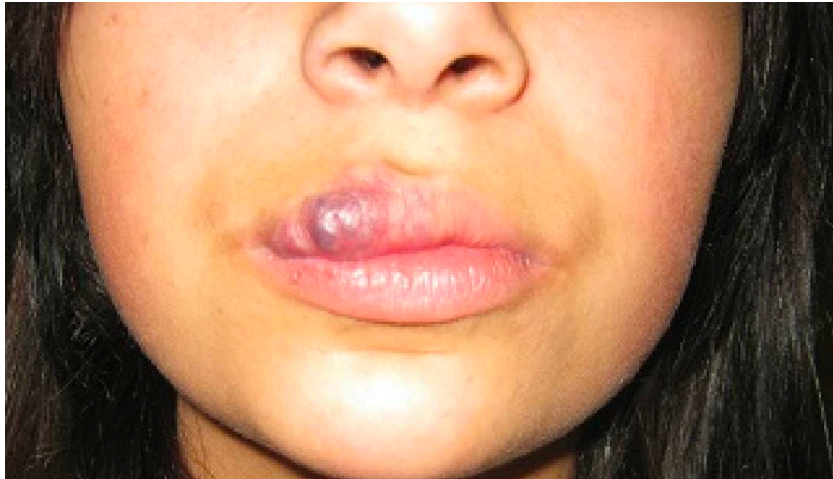Ultrasound used to guide needle into the venous lakes of the venous malformation.

Digital Subtraction Angiogram of venous malformation





Before



After

