

Transition of Care

Dr. Andrea Bischoff

The 65th Workshop for the Surgical Treatment
of Colorectal Problems in Children



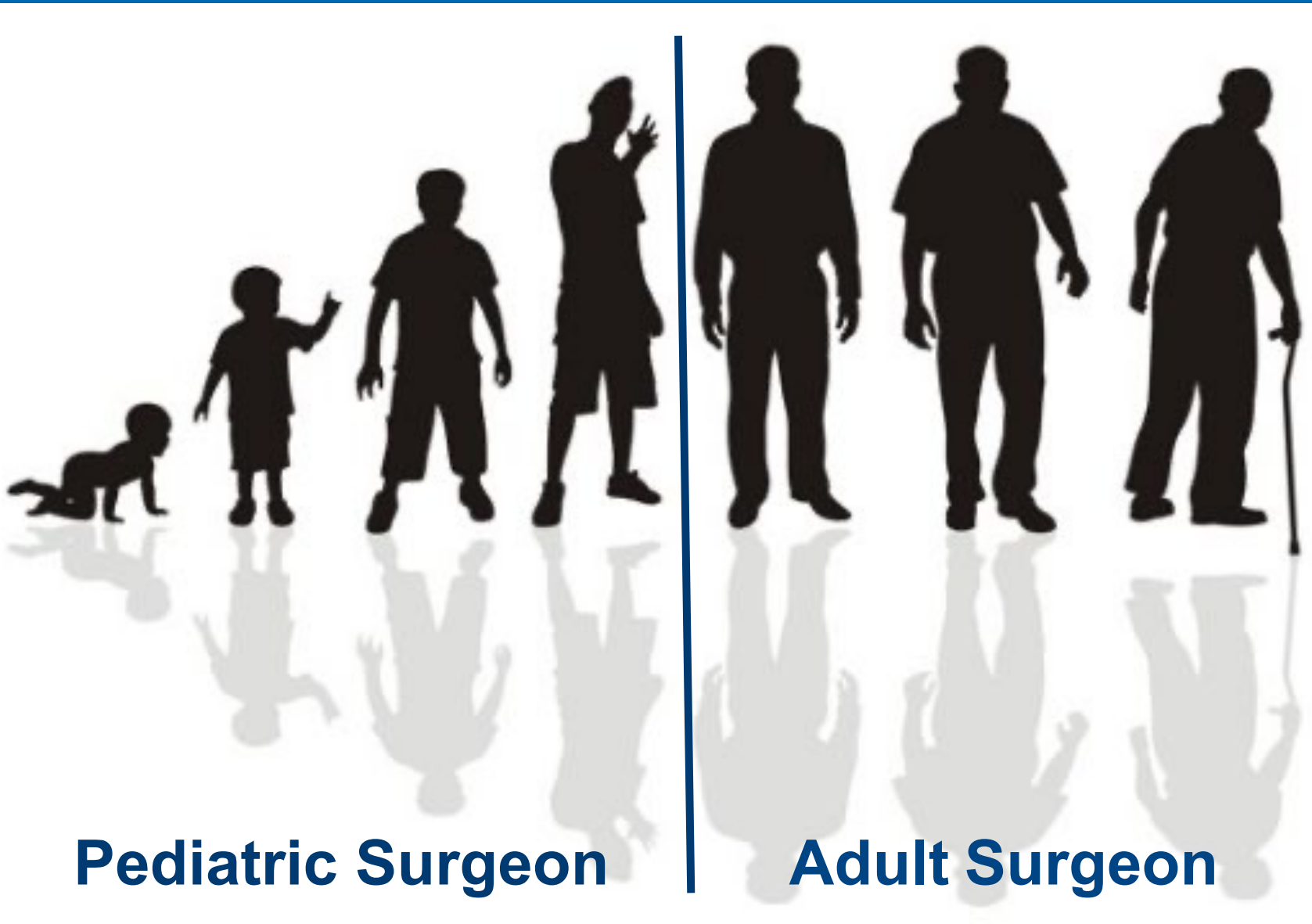
Children's Hospital Colorado
Here, it's different.™

INTERNATIONAL CENTER FOR
**COLORECTAL AND
UROGENITAL CARE**



Children's Hospital Colorado
Here, it's different.™

INTERNATIONAL CENTER FOR
**COLORECTAL AND
UROGENITAL CARE**



Pediatric Surgeon

Adult Surgeon



Children's Hospital Colorado
Here, it's different.™

INTERNATIONAL CENTER FOR
**COLORECTAL AND
UROGENITAL CARE**

Database Review



88 patients that
were treated when
they were >18 yo



Main Needs

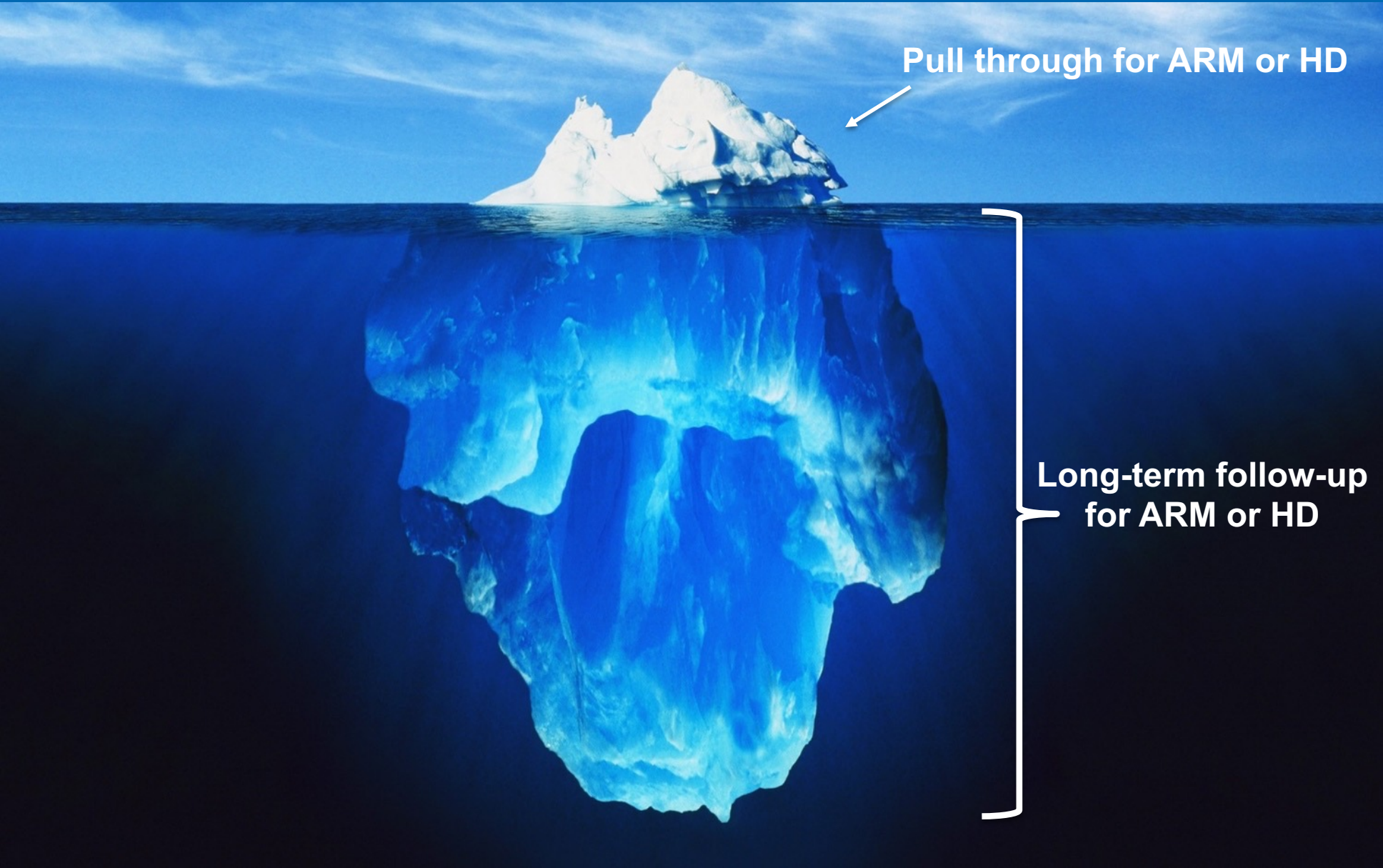
- Complications from previous surgeries (rectal mislocation, recurrent fistula)
- Undiagnosed congenital anomaly
- Rectal prolapse
- Fecal incontinence / Bowel Management
- Gynecologic, urologic, and reproductive concerns



Surgical Interventions

- PSARP or re-do PSARP
- Rectal prolapse repair
- Continent appendicostomies
- Presacral mass resection
- Vaginoplasties
- Mitrofanoff





Pull through for ARM or HD

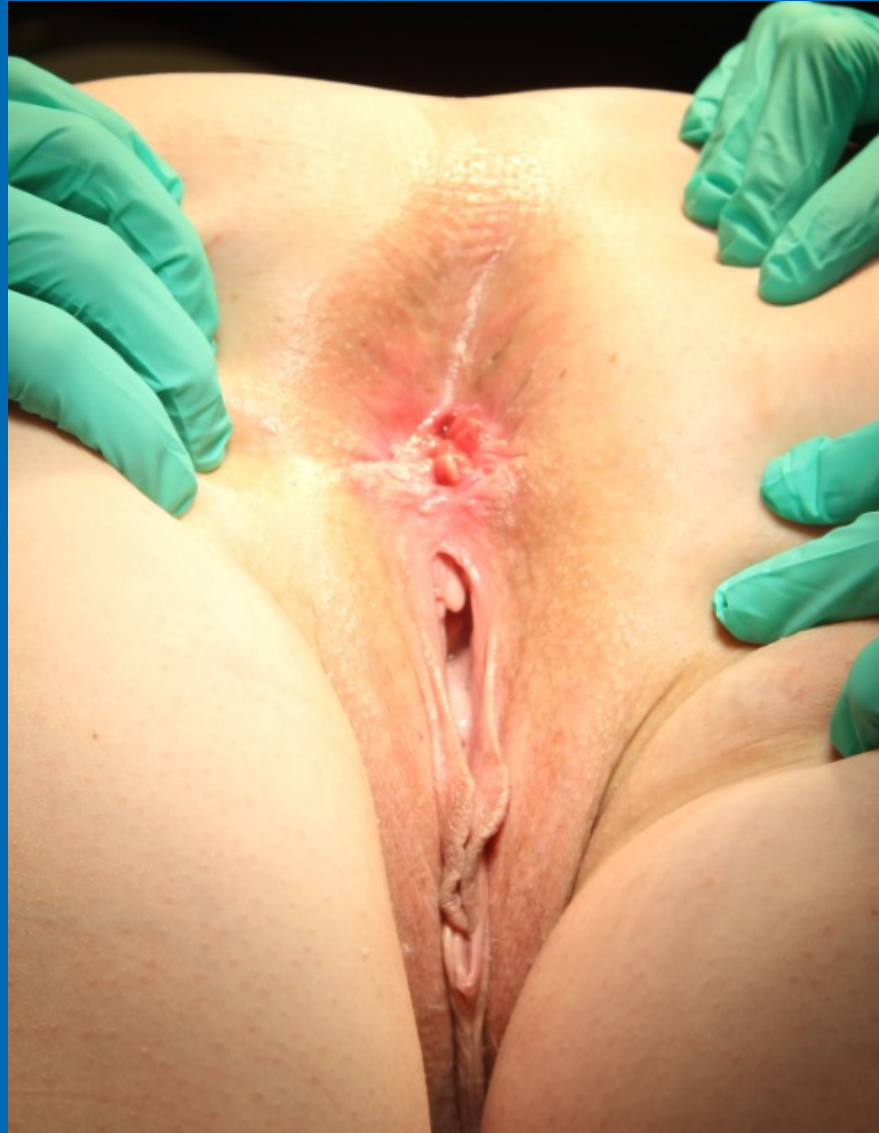Long-term follow-up
for ARM or HD



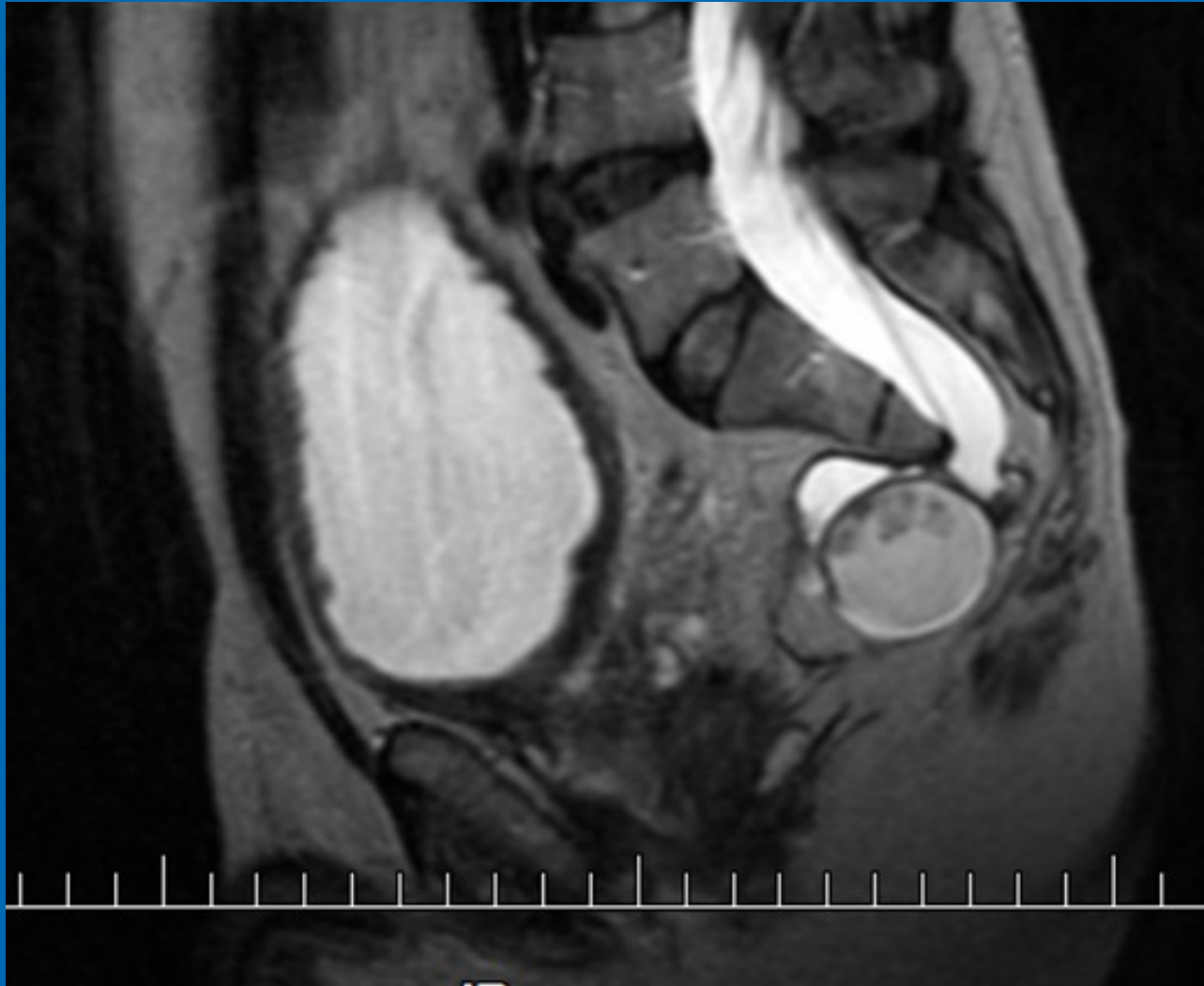
Children's Hospital Colorado

Here, it's different.™

45 yo recto-perineal fistula



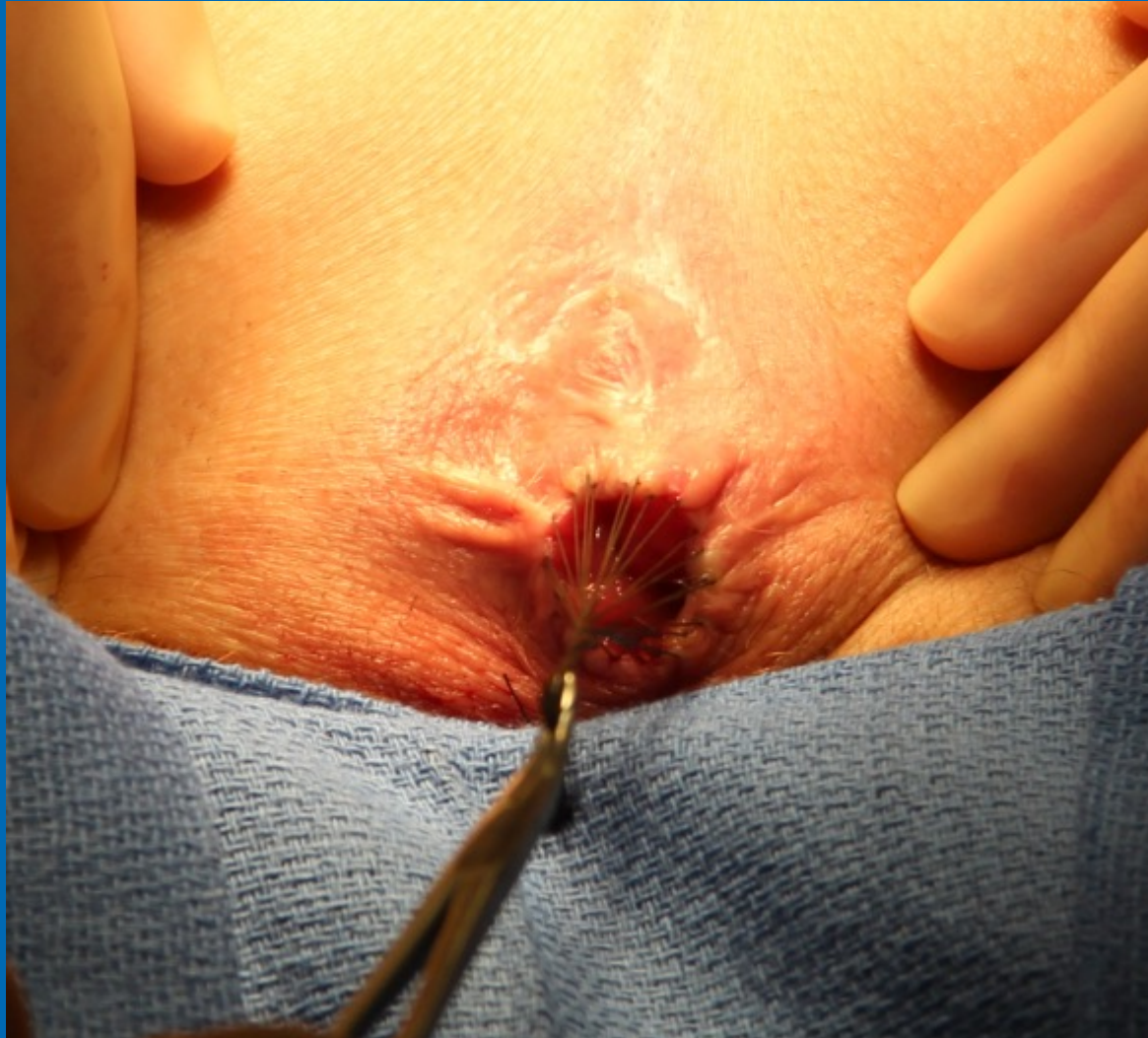51 yo



Children's Hospital Colorado
Here, it's different.™

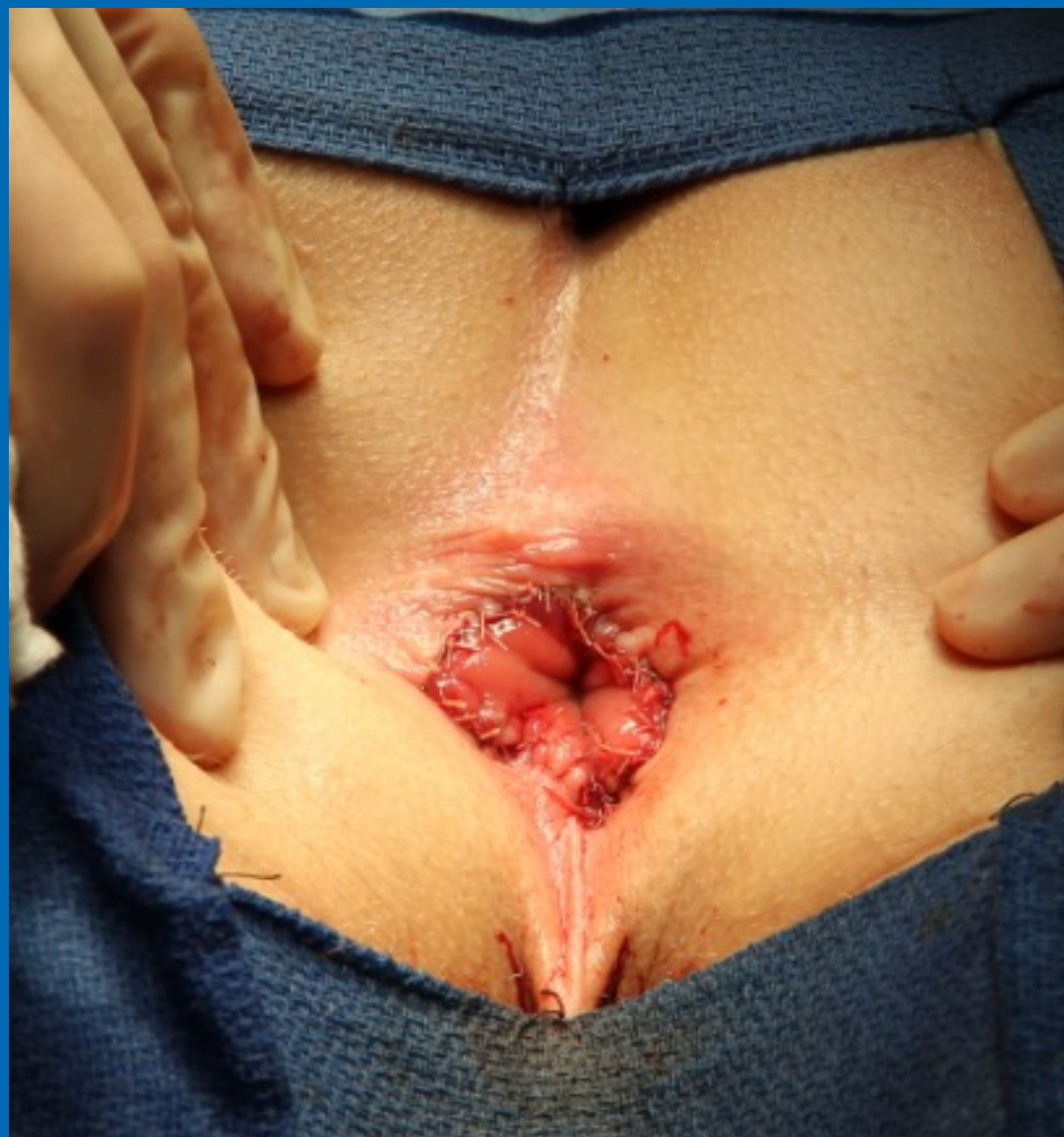INTERNATIONAL CENTER FOR
**COLORECTAL AND
UROGENITAL CARE**

43 yo, rectal prolapse



Children's Hospital Colorado
Here, it's different.™

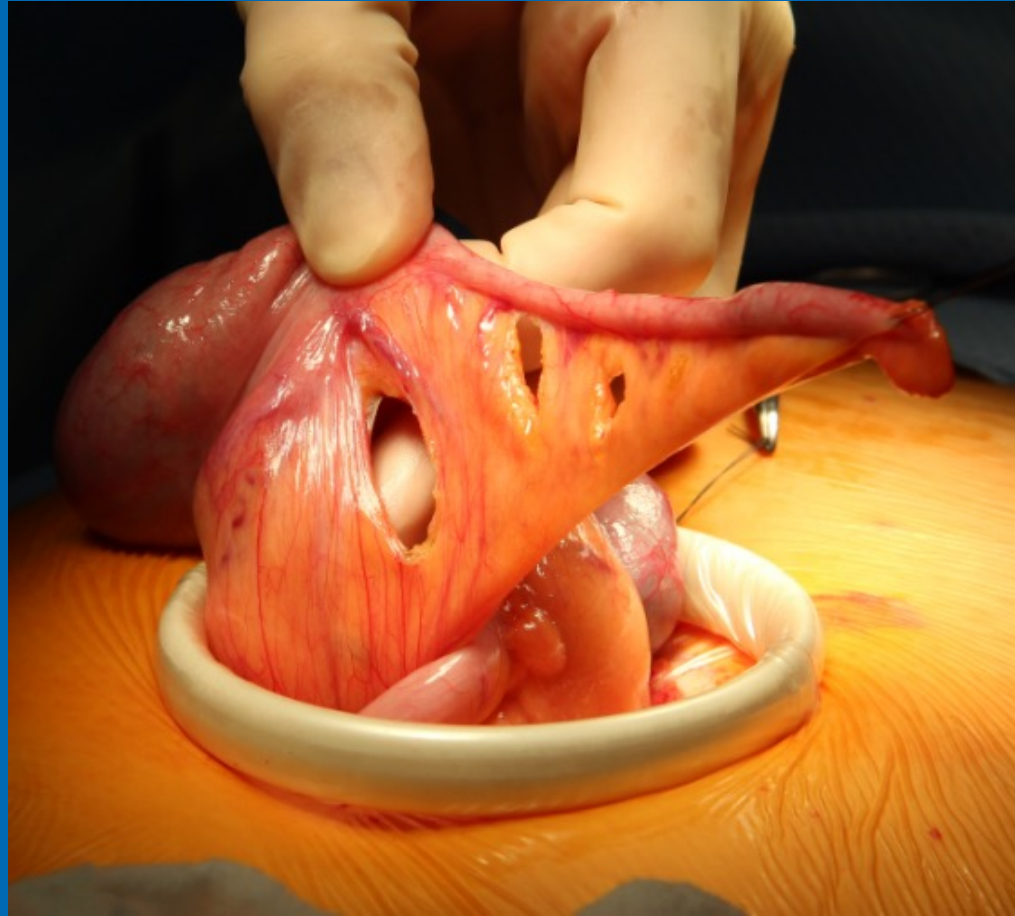
INTERNATIONAL CENTER FOR
**COLORECTAL AND
UROGENITAL CARE**

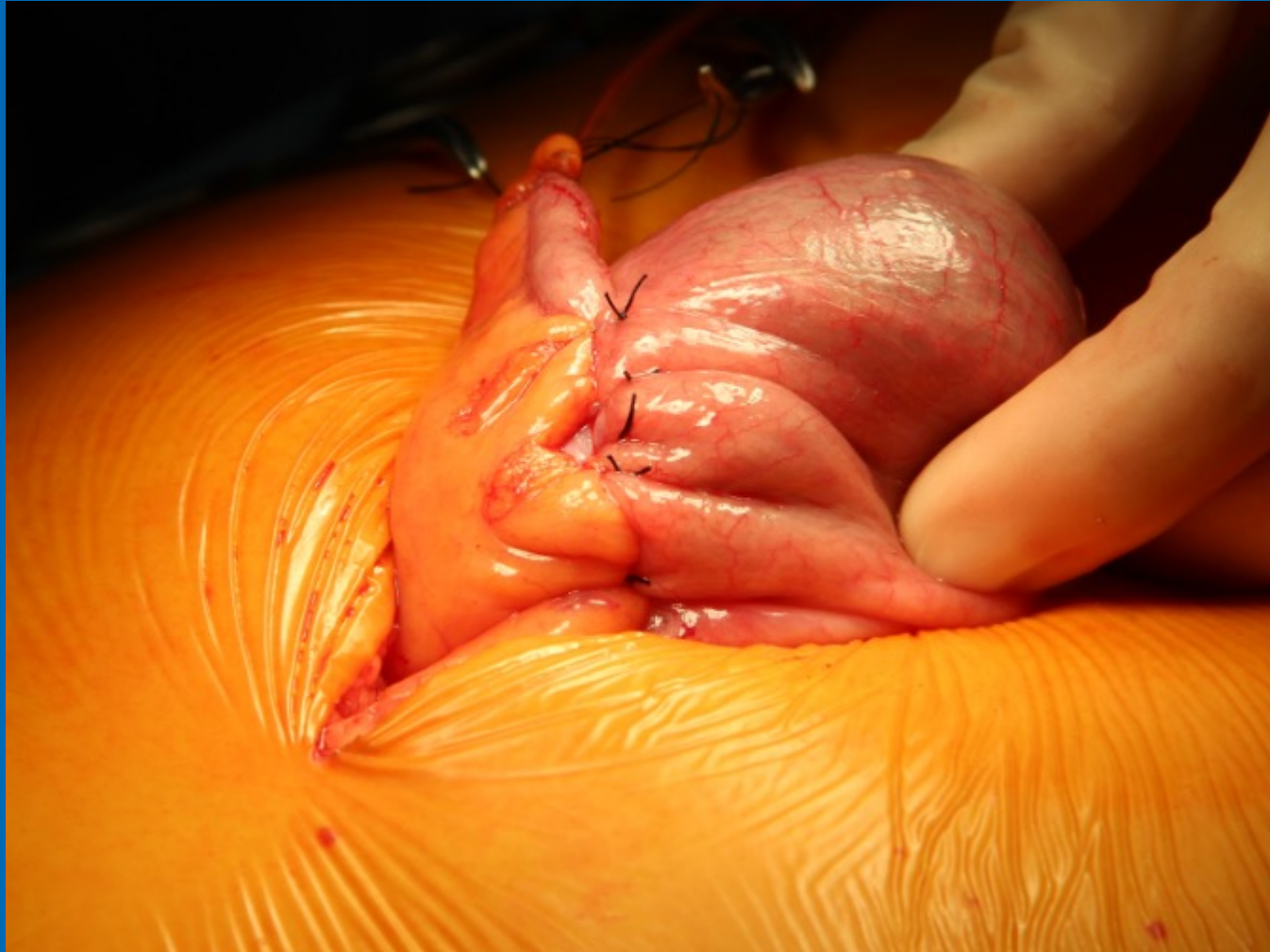

Children's Hospital Colorado
Here, it's different.™

INTERNATIONAL CENTER FOR
**COLORECTAL AND
UROGENITAL CARE**
UROGENITAL CARE

64 yo with fecal incontinence

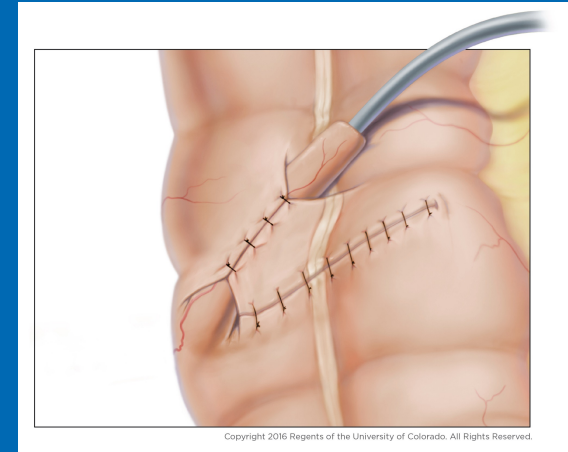
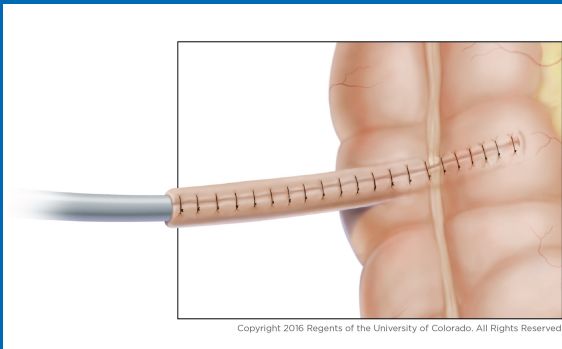
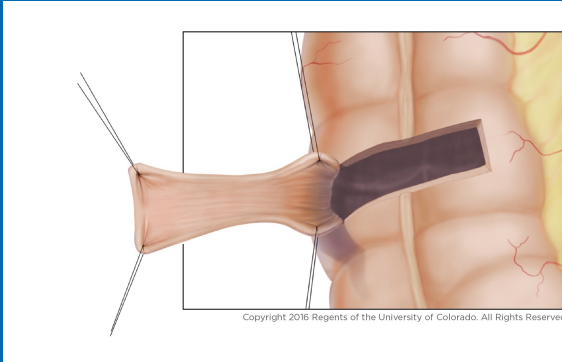
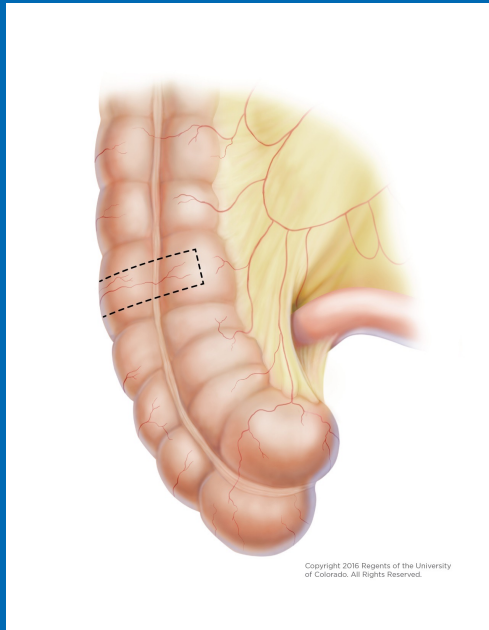




Children's Hospital Colorado
Here, it's different.™

INTERNATIONAL CENTER FOR
**COLORECTAL AND
UROGENITAL CARE**

52 yo male patient No appendix!



26 yo male born with an anorectal malformation

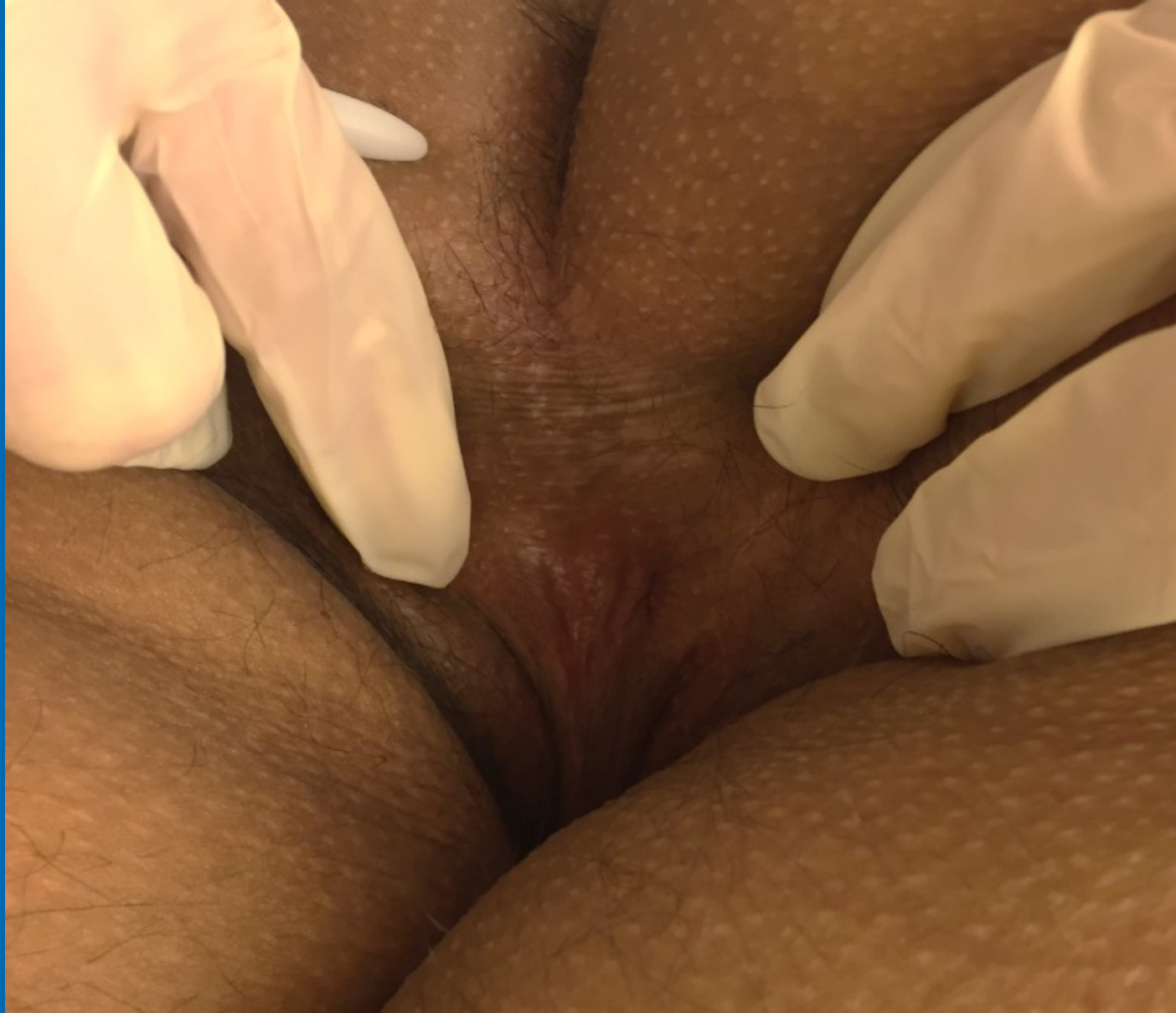Terminal stoma

“Born without a colon”

End stage renal disease, currently on hemodialysis, wait list for kidney transplant

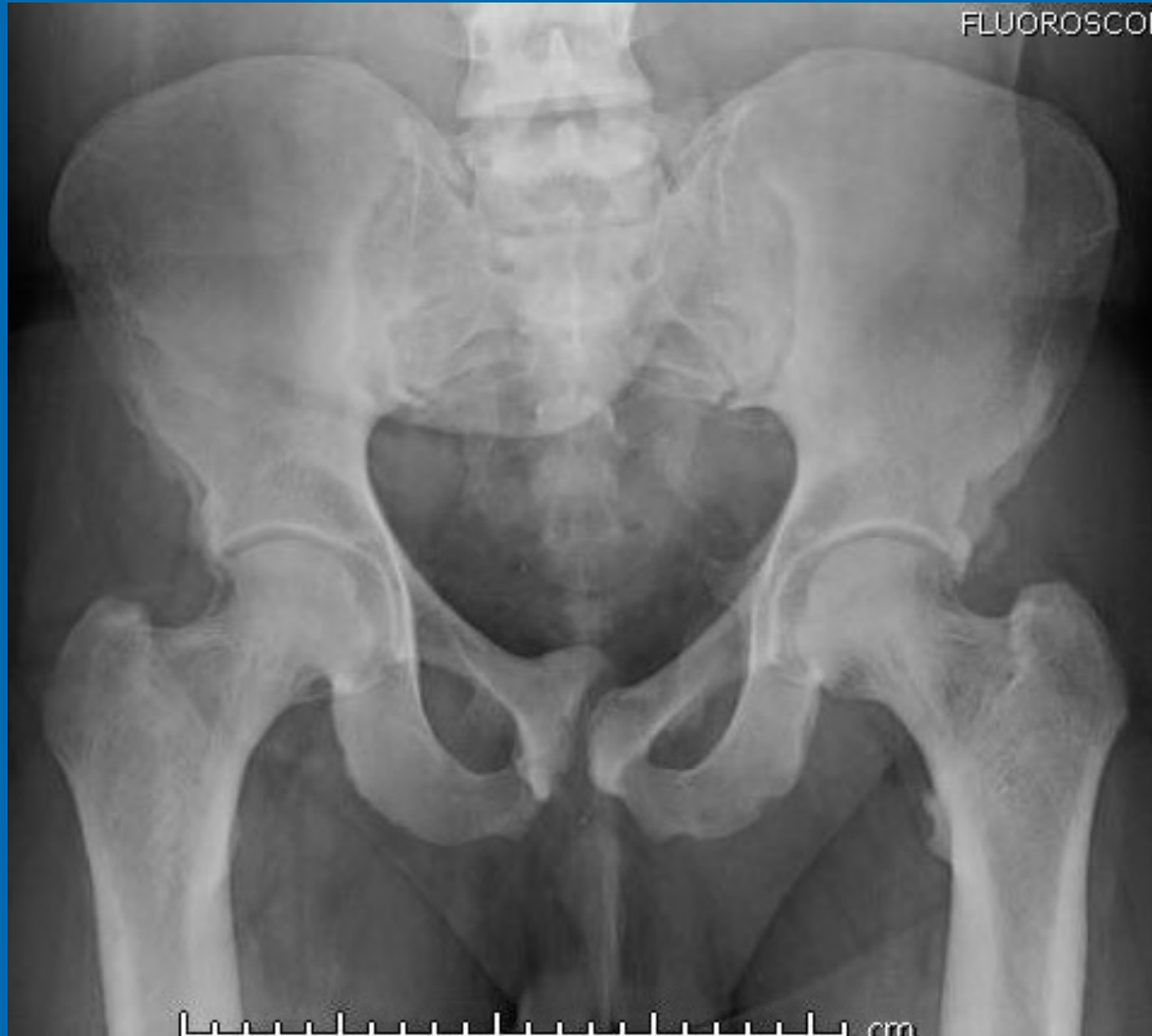He wants to know if he is a candidate for a stoma pullthrough





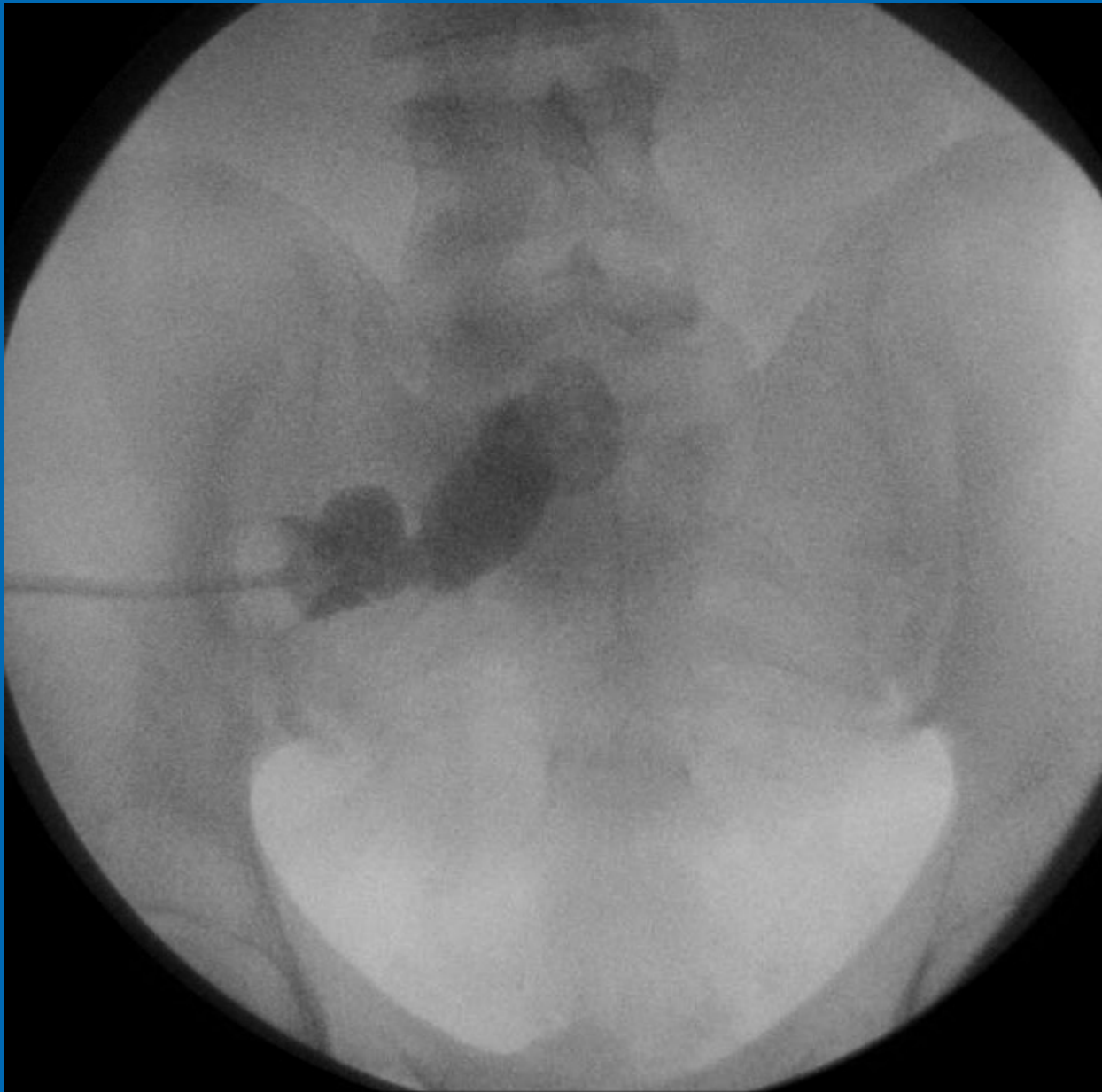
Children's Hospital Colorado
Here, it's different.™

INTERNATIONAL CENTER FOR
**COLORECTAL AND
UROGENITAL CARE**



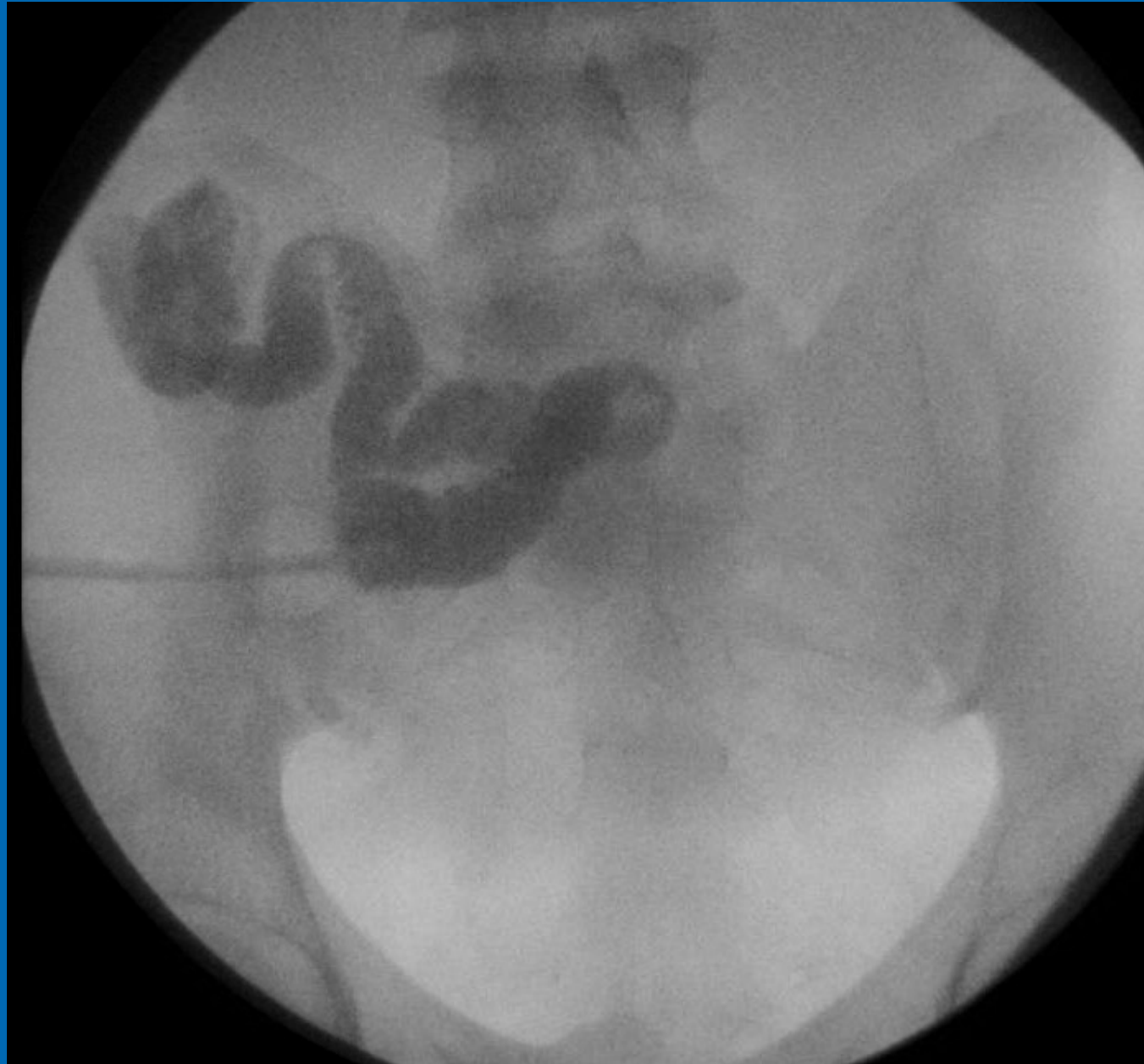Children's Hospital Colorado
Here, it's different.™

INTERNATIONAL CENTER FOR
**COLORECTAL AND
UROGENITAL CARE**



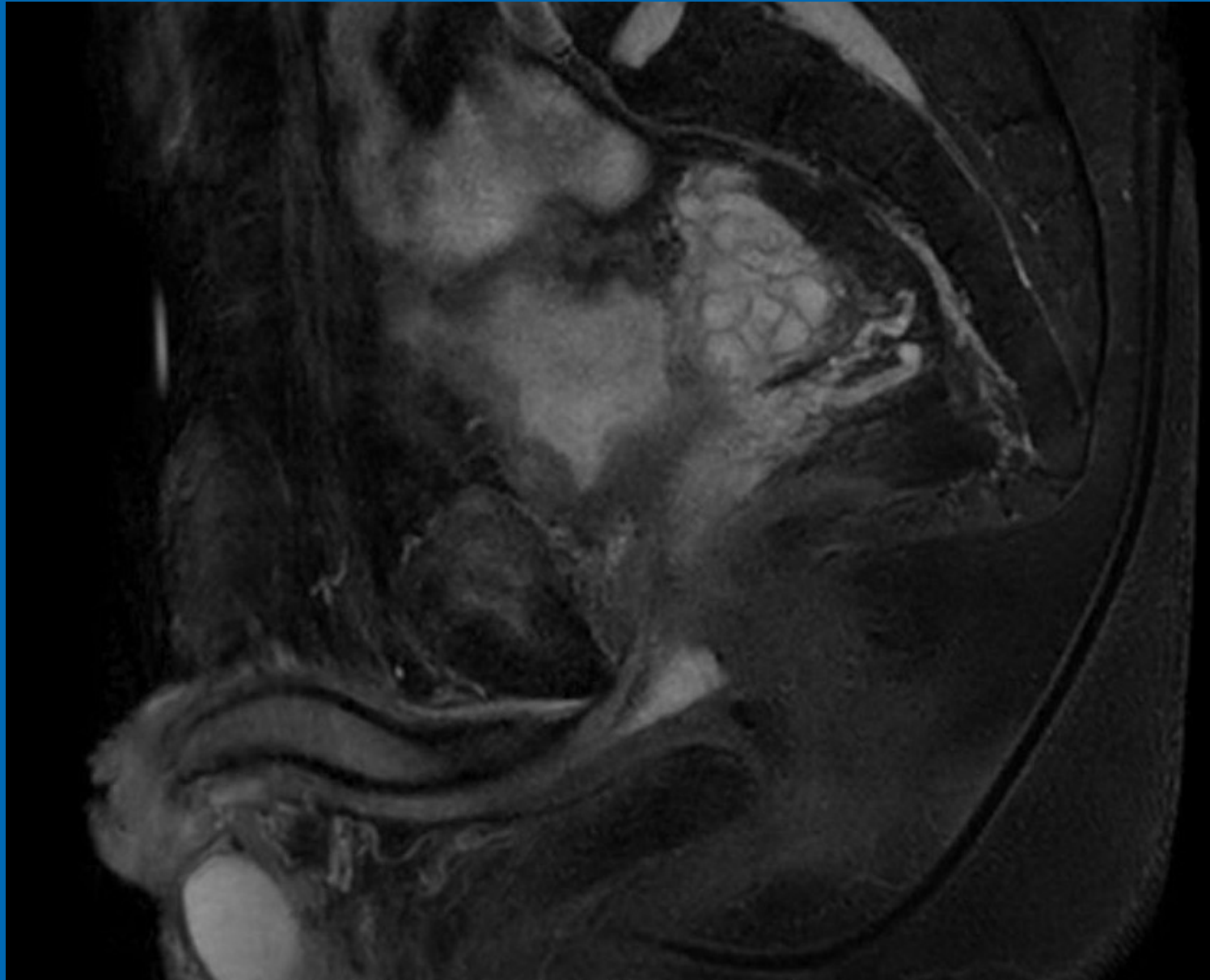
Children's Hospital Colorado
Here, it's different.™

INTERNATIONAL CENTER FOR
**COLORECTAL AND
UROGENITAL CARE**



Children's Hospital Colorado
Here, it's different.™

INTERNATIONAL CENTER FOR
**COLORECTAL AND
UROGENITAL CARE**



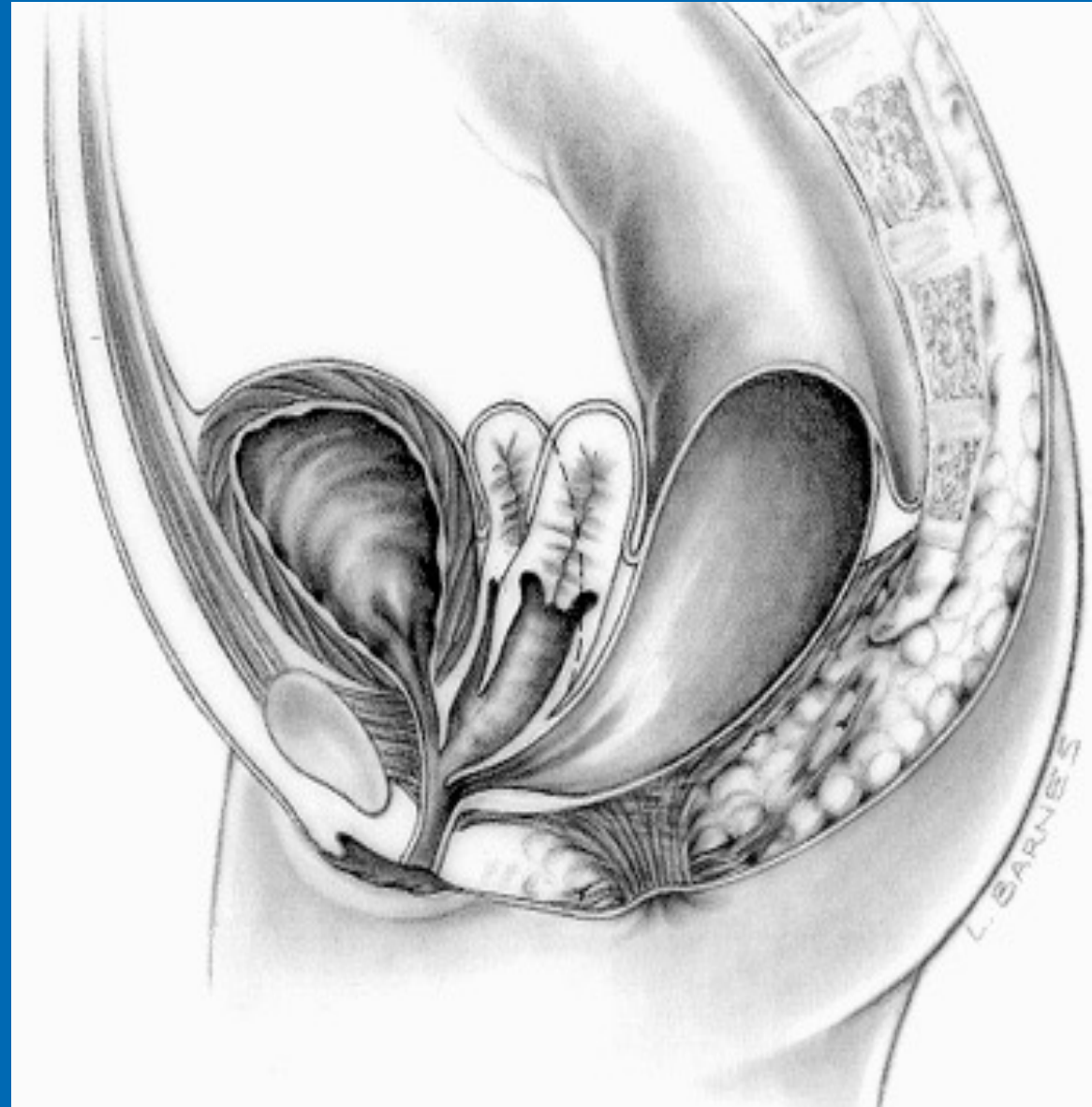
Children's Hospital Colorado
Here, it's different.™

INTERNATIONAL CENTER FOR
**COLORECTAL AND
UROGENITAL CARE**

Patients that are born without the anus cannot have an ileo-anal pullthrough.



Papanicolaou Test



Children's Hospital Colorado
Here, it's different.™

INTERNATIONAL CENTER FOR
**COLORECTAL AND
UROGENITAL CARE**

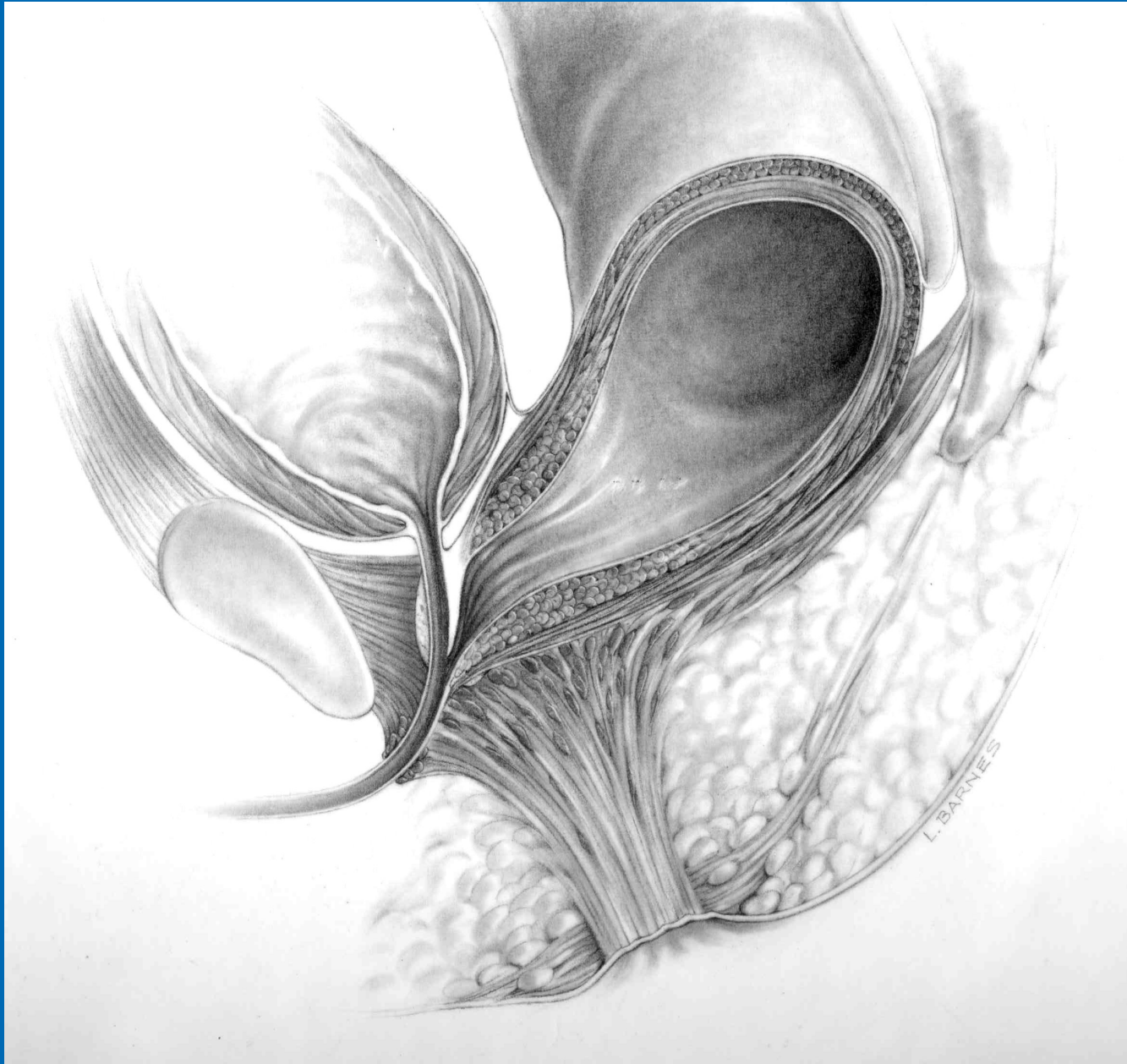
Mode of delivery in patients previously operated:

Examine the perineum

Associated anomalies

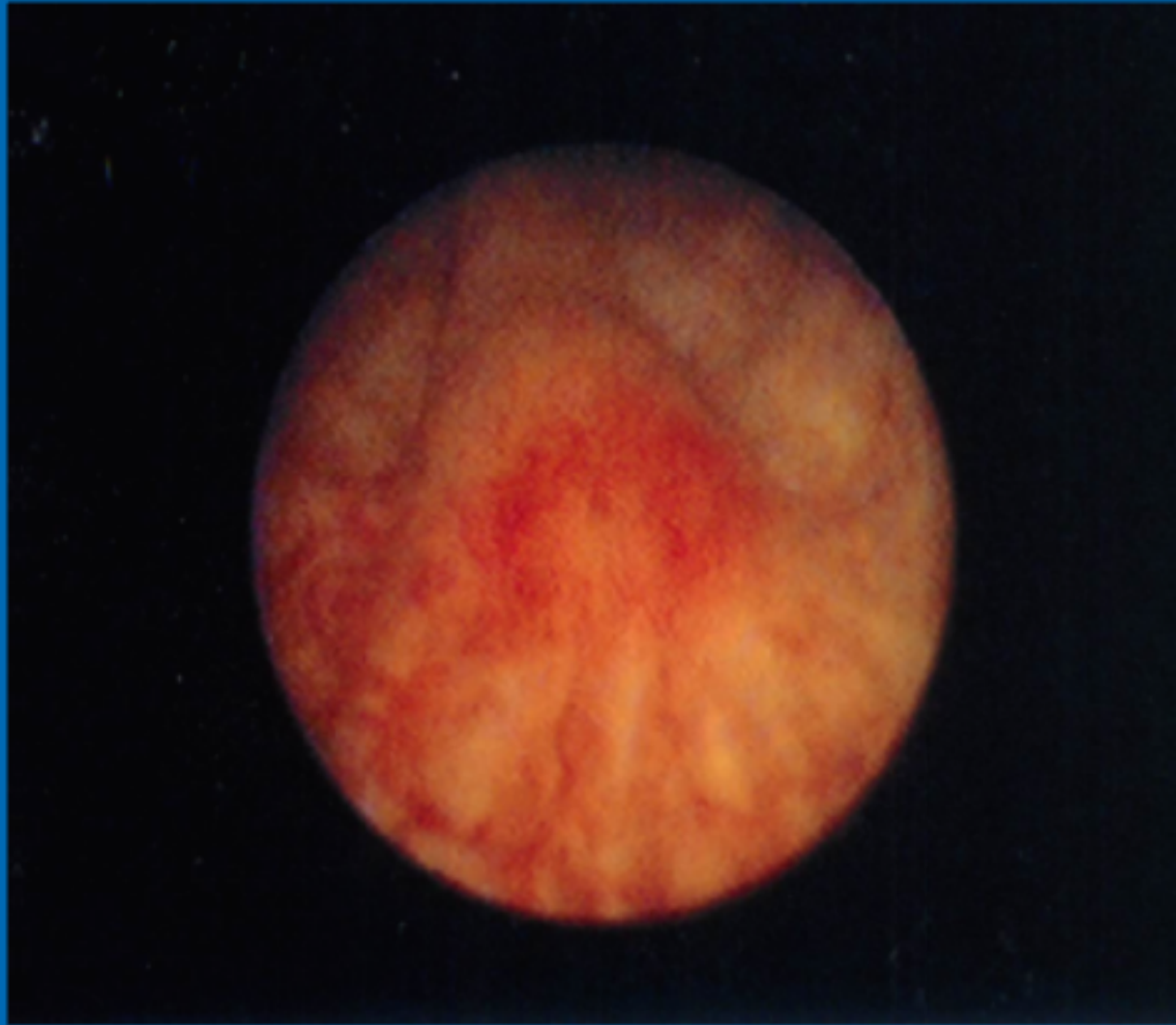
Previous abdominal operations





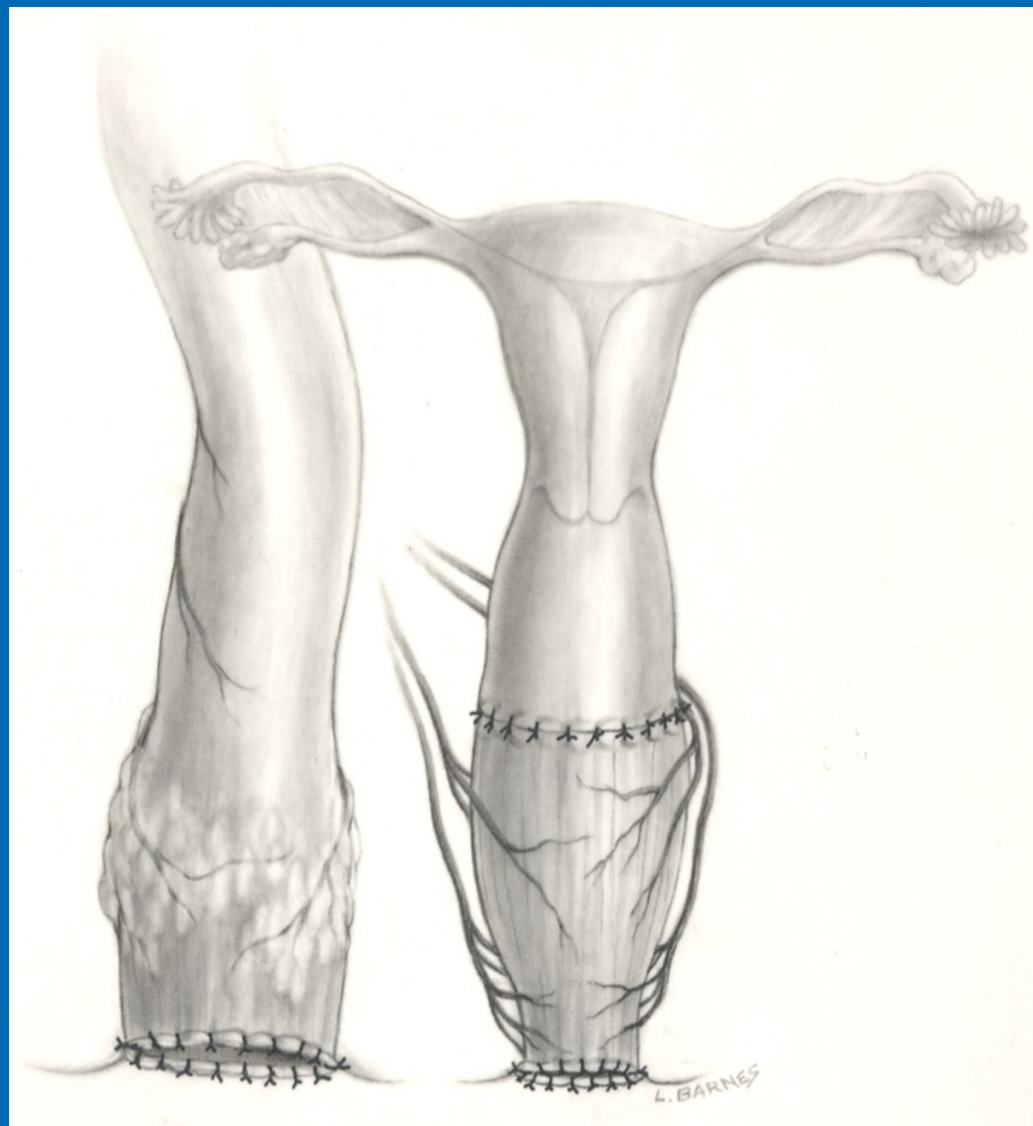
Children's Hospital Colorado
Here, it's different.™

INTERNATIONAL CENTER FOR
**COLORECTAL AND
UROGENITAL CARE**



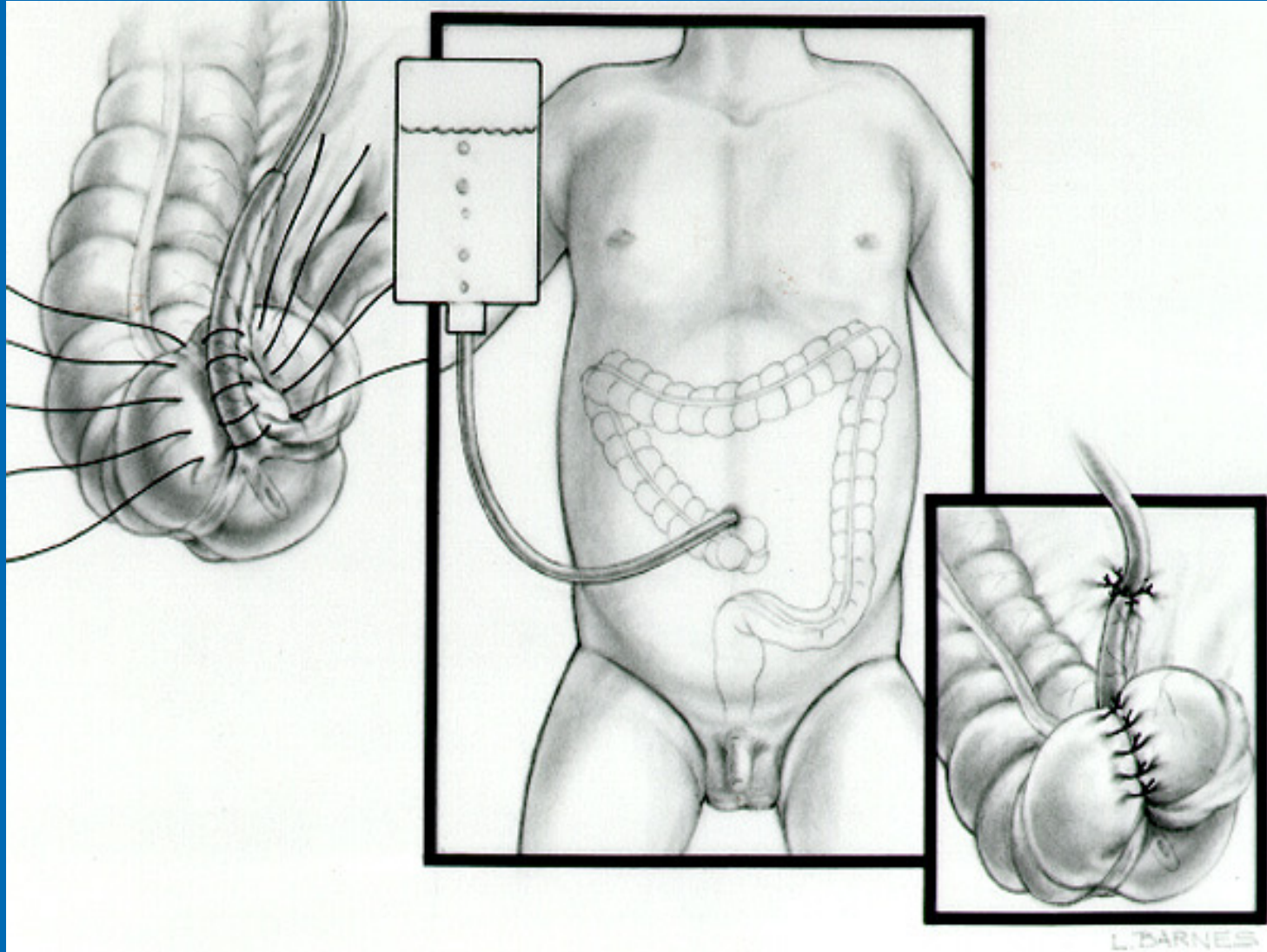
Children's Hospital Colorado
Here, it's different.™

INTERNATIONAL CENTER FOR
**COLORECTAL AND
UROGENITAL CARE**



Children's Hospital Colorado
Here, it's different.™

INTERNATIONAL CENTER FOR
**COLORECTAL AND
UROGENITAL CARE**



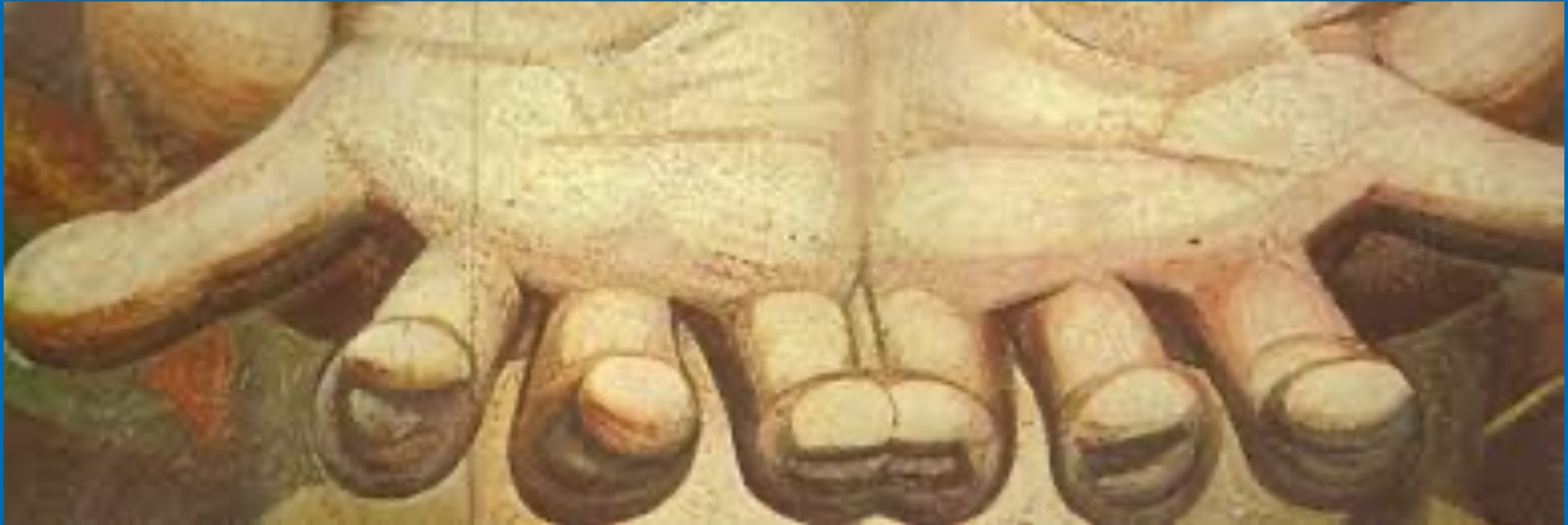Children's Hospital Colorado
Here, it's different.™

INTERNATIONAL CENTER FOR
**COLORECTAL AND
UROGENITAL CARE**



Children's Hospital Colorado
Here, it's different.™

INTERNATIONAL CENTER FOR
**COLORECTAL AND
UROGENITAL CARE**



Andrea.Bischoff@cuanschutz.edu



Doctors Pena Bischoff



@DrsPenaBischoff



PENABISCHOFF



Children's Hospital Colorado
Here, it's different.™

INTERNATIONAL CENTER FOR
**COLORECTAL AND
UROGENITAL CARE**