

# Case #3

---

Andrea Bischoff

09/20/2018

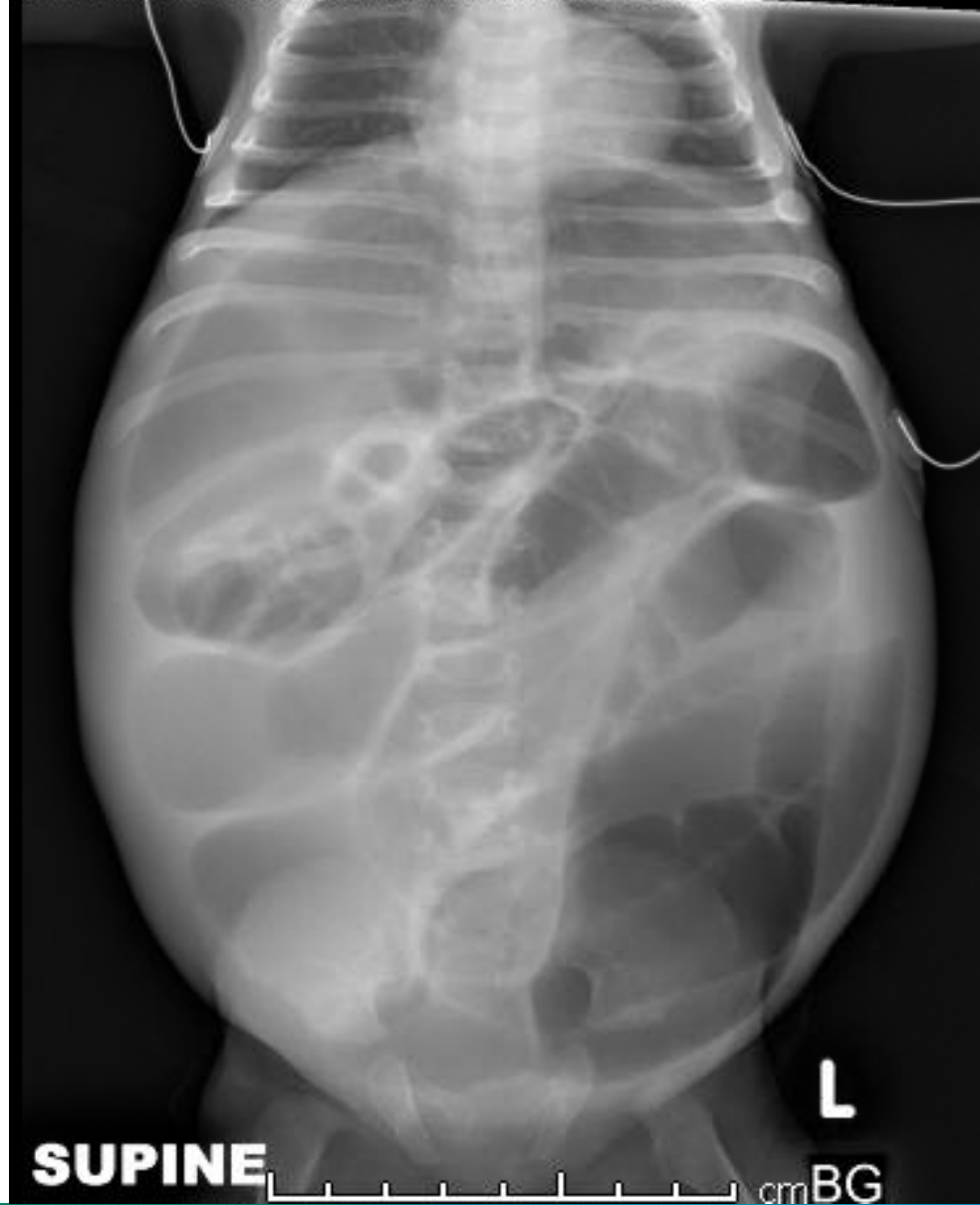

Children's Hospital Colorado

INTERNATIONAL CENTER FOR  
**COLORECTAL AND  
UROGENITAL CARE**



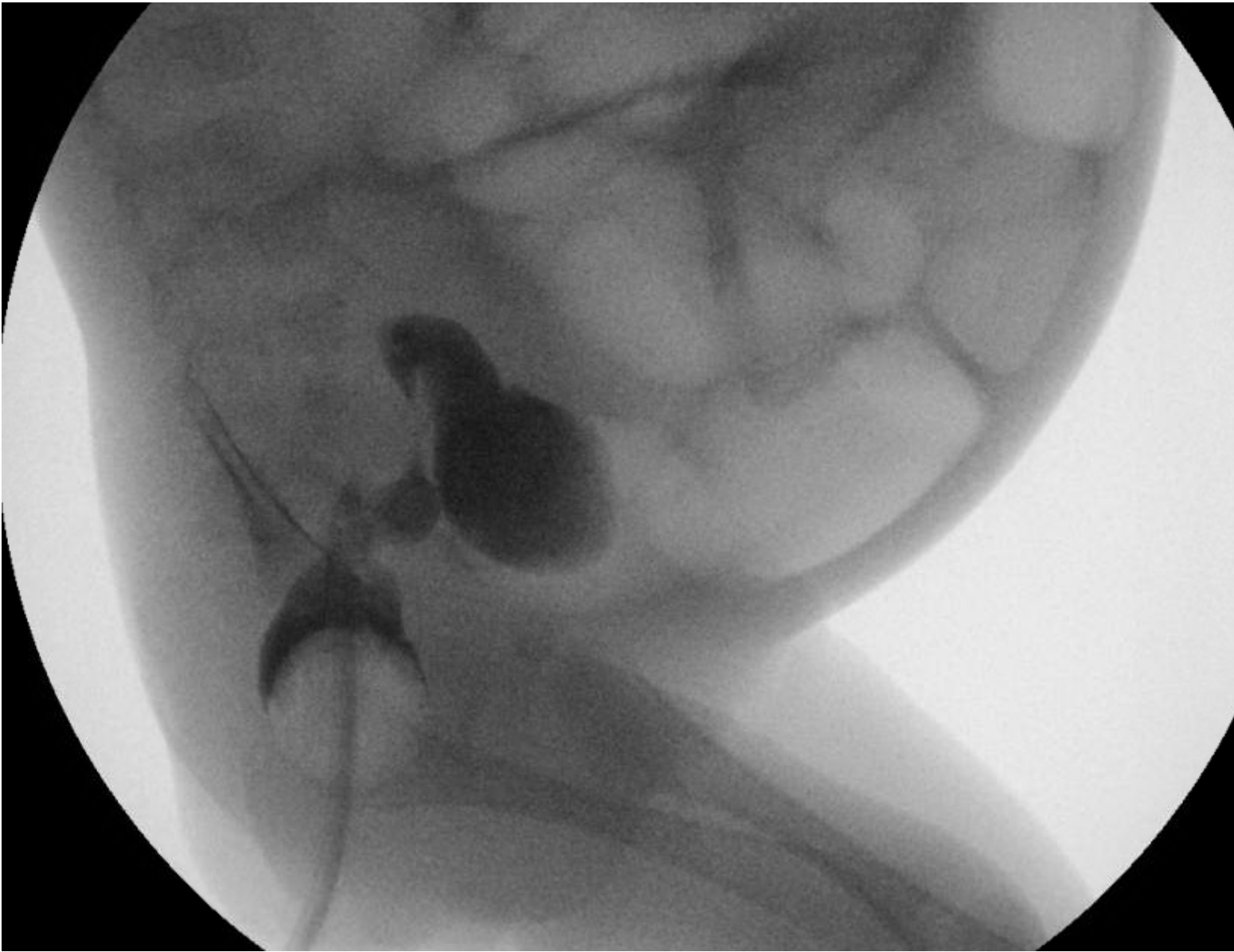
3 mo female patient with Trisomy  
21 and failure to thrive

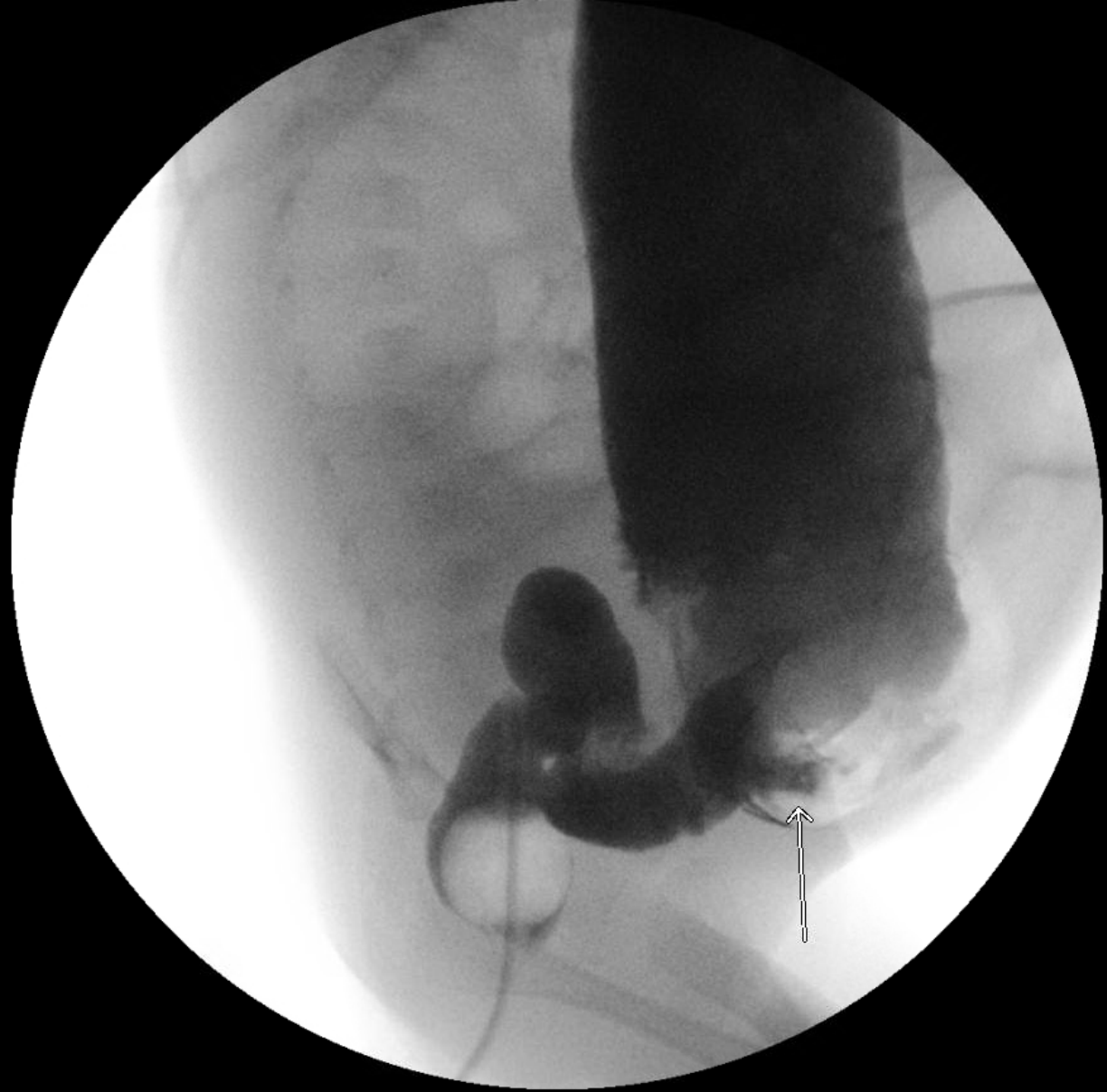


# Based on this X-ray, what would be your next step?



1. Rectal irrigations
2. Rectal biopsy
3. Contrast enema
4. Exploratory laparotomy
5. I don't know

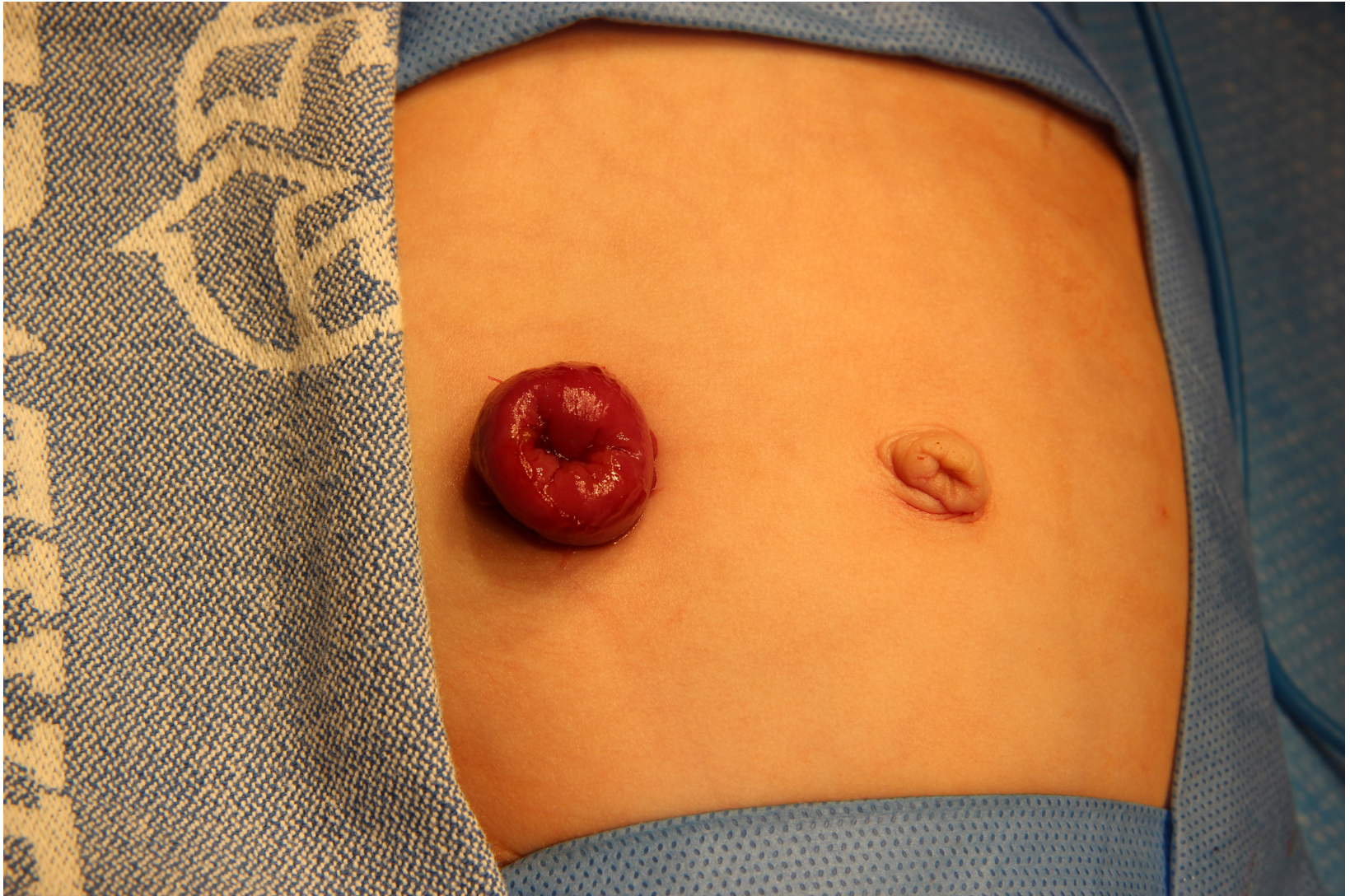



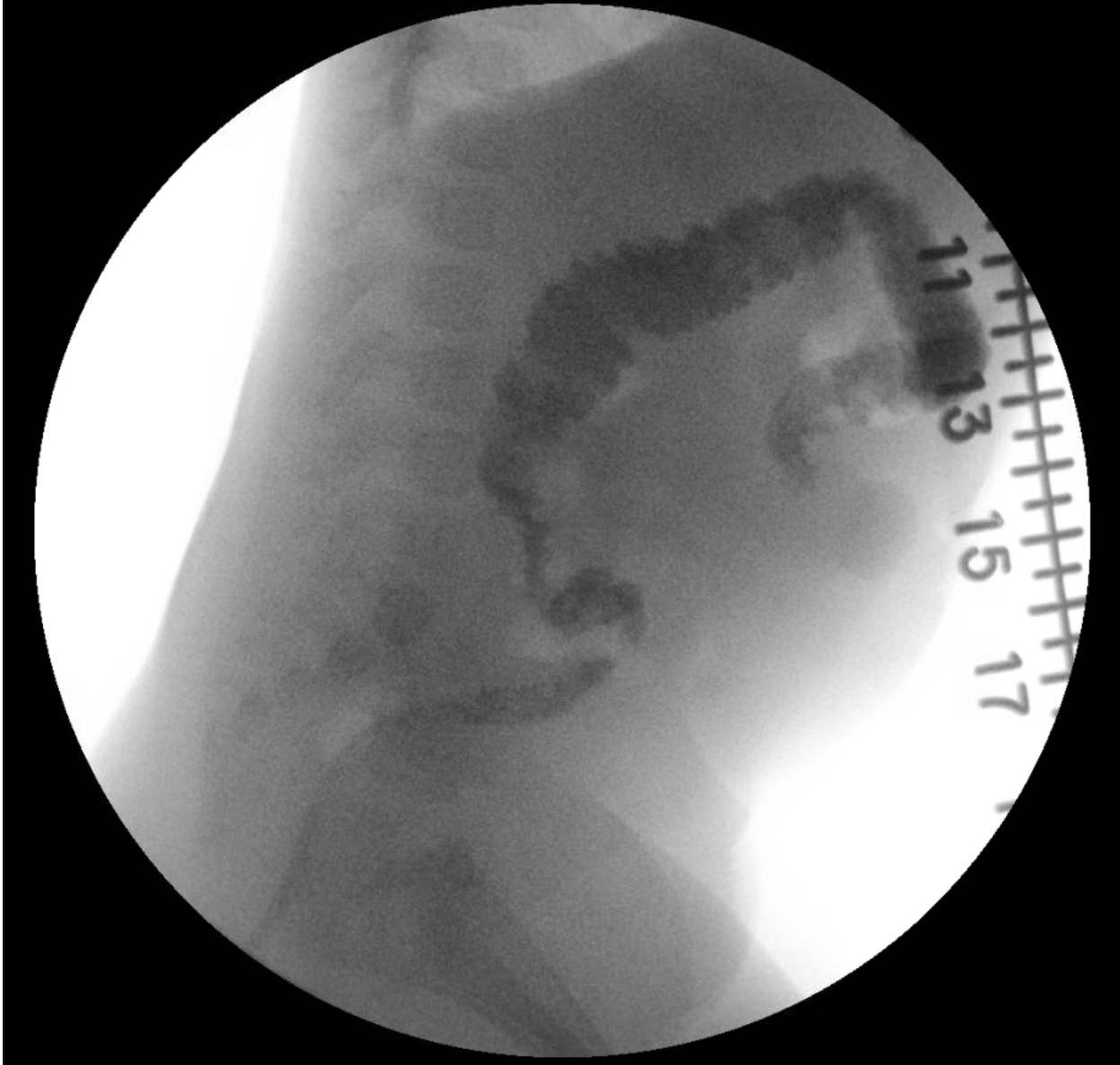# Would you attempt a primary pullthrough in this case?

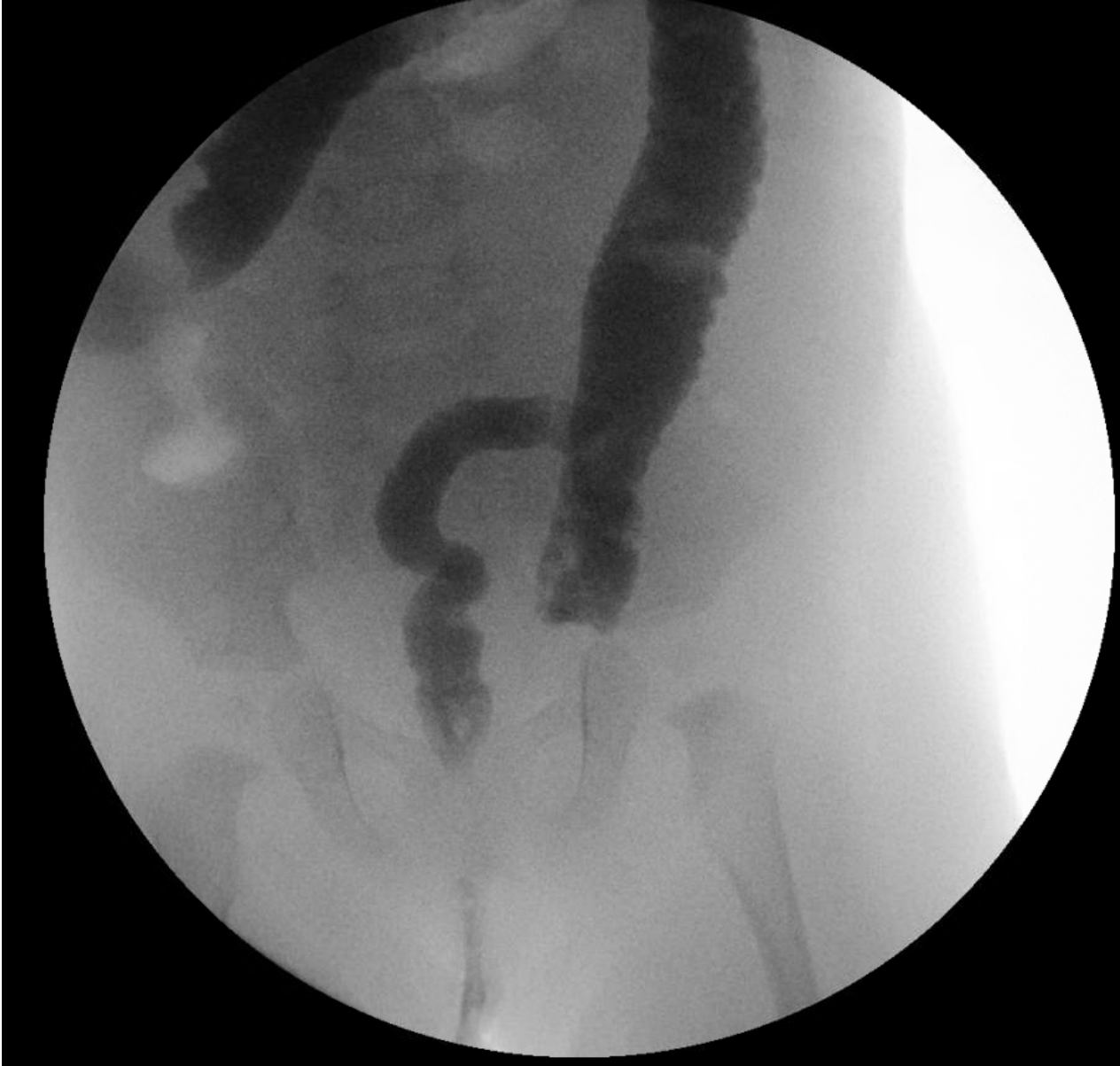

1. Yes
2. No
3. I don't know

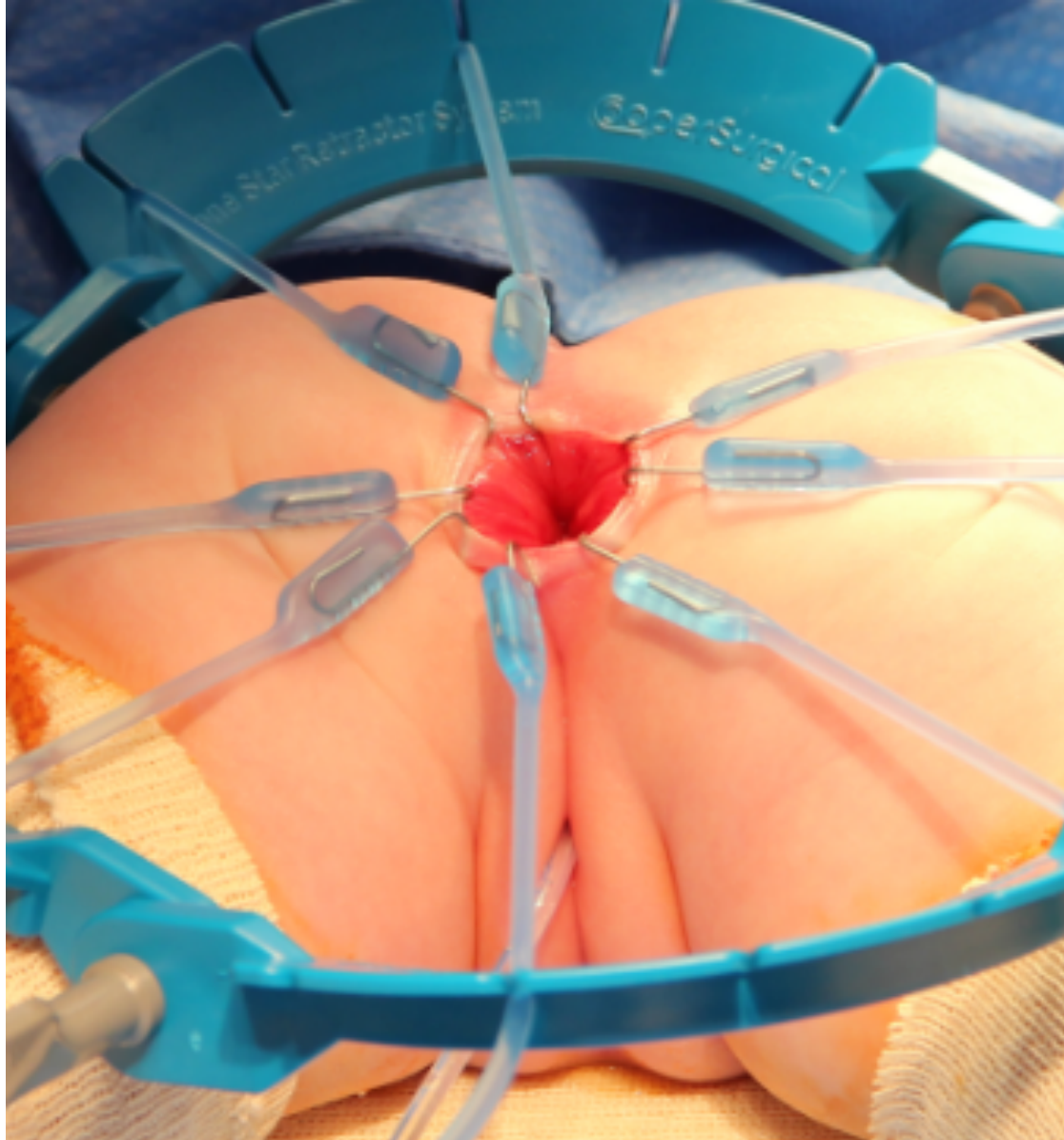







INTERNATIONAL CENTER FOR  
**COLORECTAL AND  
UROGENITAL CARE**



INTERNATIONAL CENTER FOR  
**COLORECTAL AND  
UROGENITAL CARE**



