

Case #4

Andrea Bischoff

09/20/2018

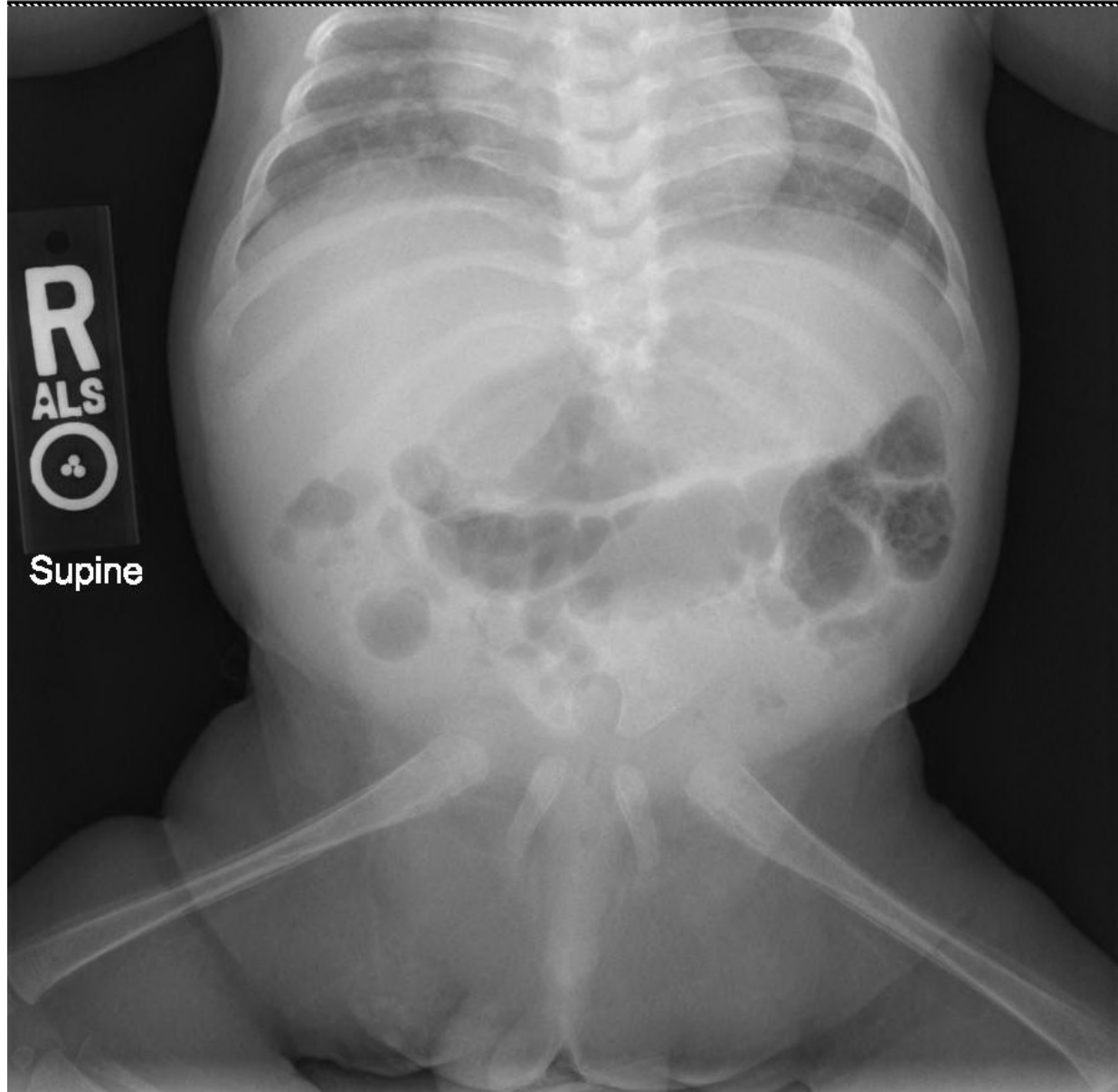


Children's Hospital Colorado

INTERNATIONAL CENTER FOR
**COLORECTAL AND
UROGENITAL CARE**



Newborn male with a recto-perineal fistula



What would you call this anomaly?



1. Sacral agenesis
2. Caudal regression
3. I don't know

What is the prognosis for bowel control in this case of recto-perineal fistula?

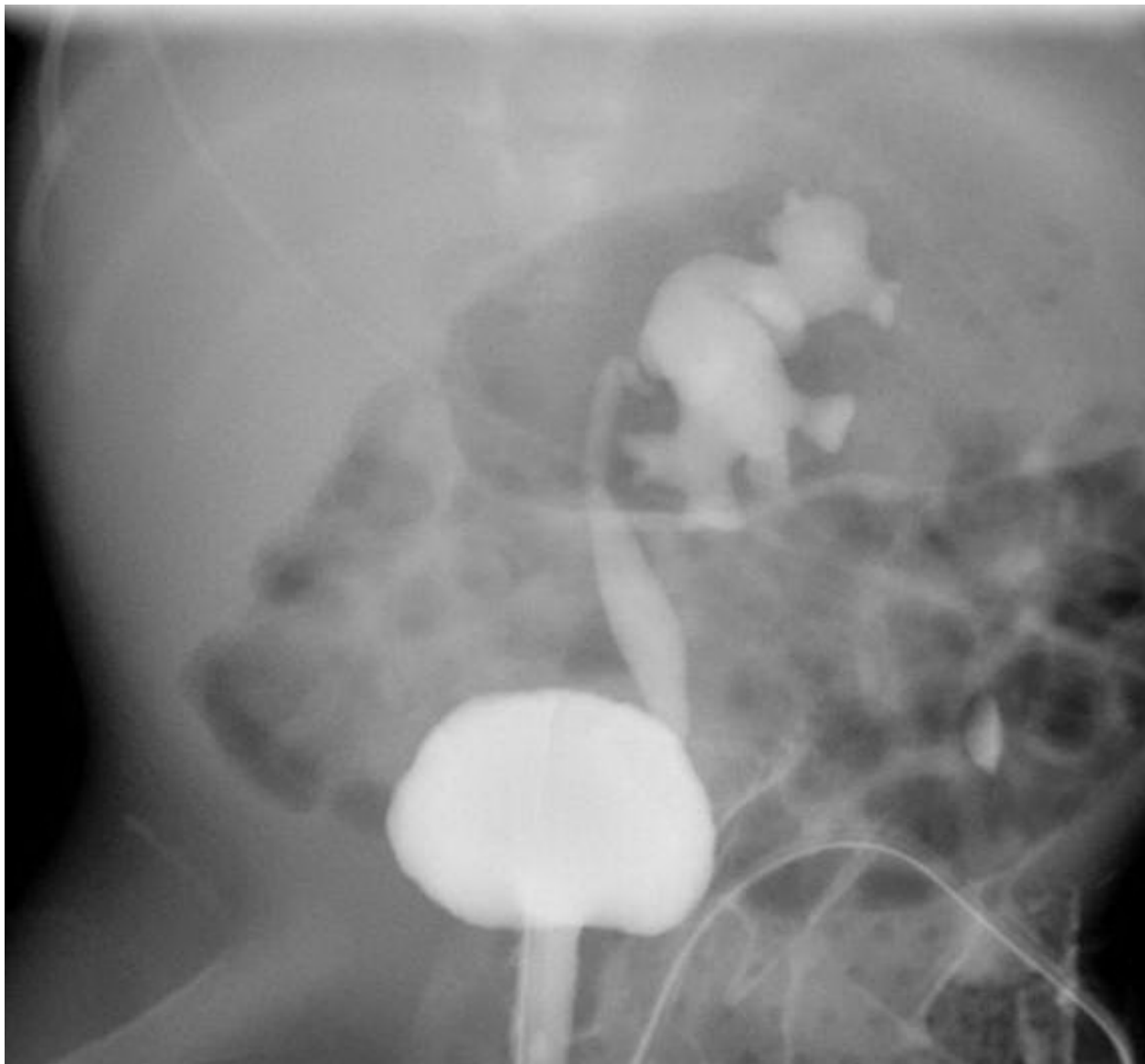


1. Good
2. Poor
3. It depends on if he has good midline groove and good muscle contraction (sphincters)
4. I don't know

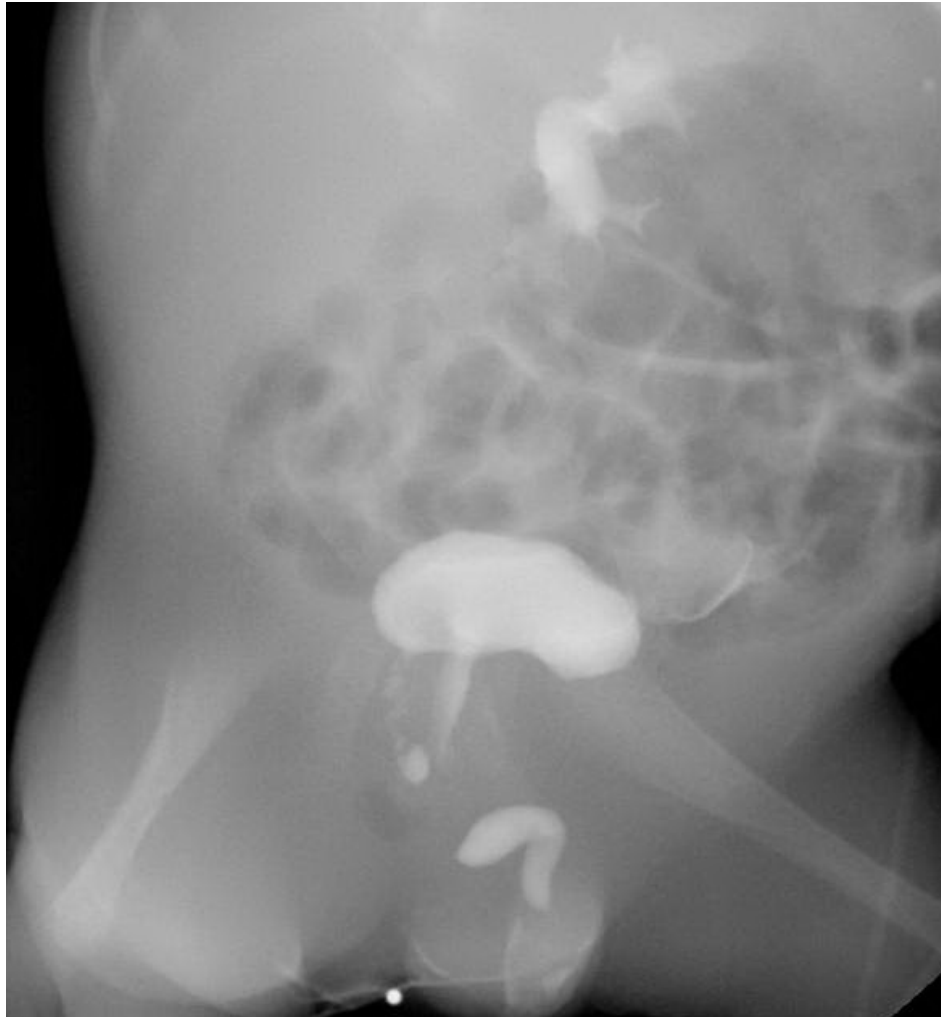Patient is stooling without problems, what would you do?



1. Temporary colostomy prior to PSARP
2. PSARP without colostomy
3. Permanent colostomy due to poor prognosis
4. I don't know



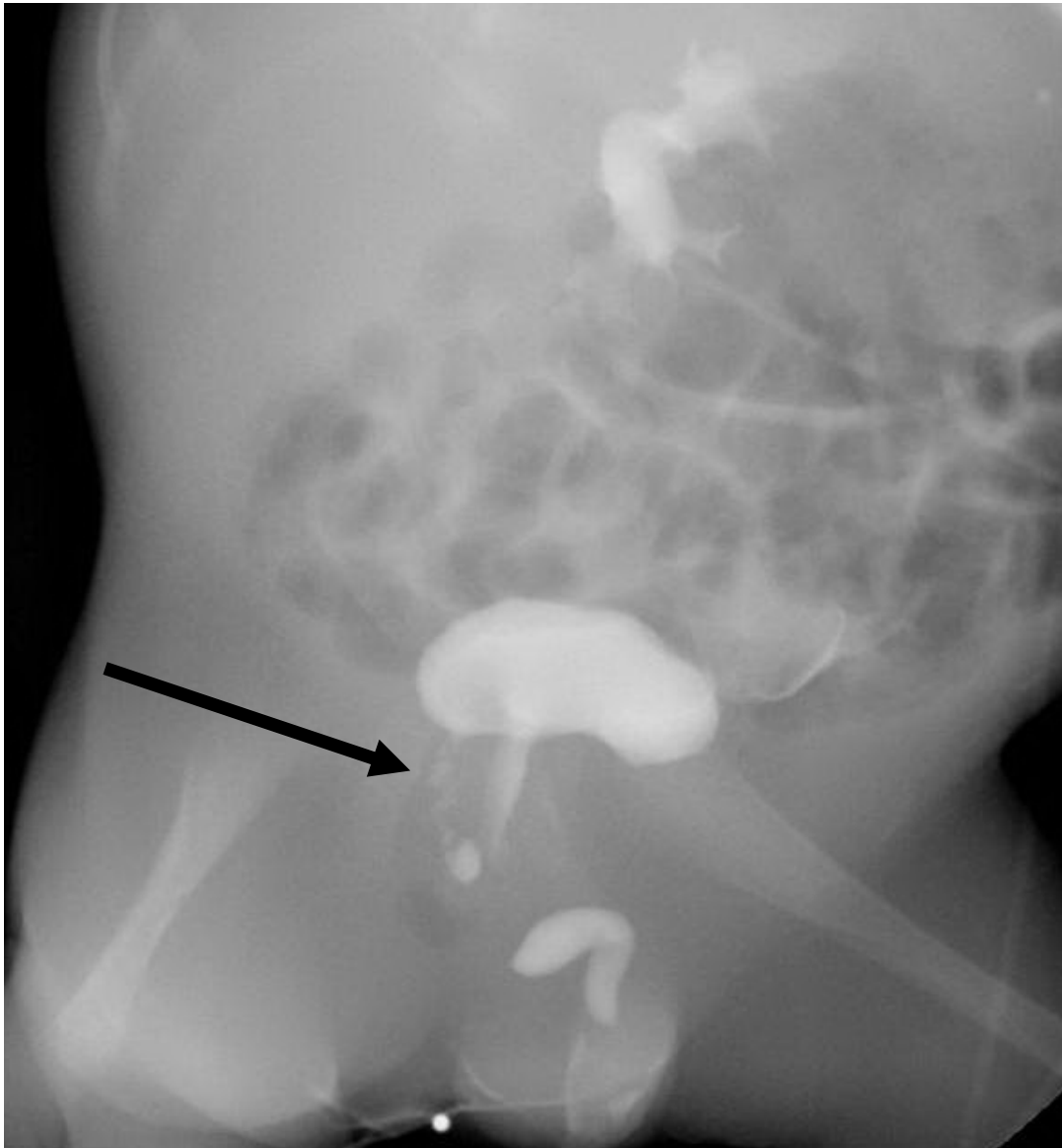
What do you see in this image?

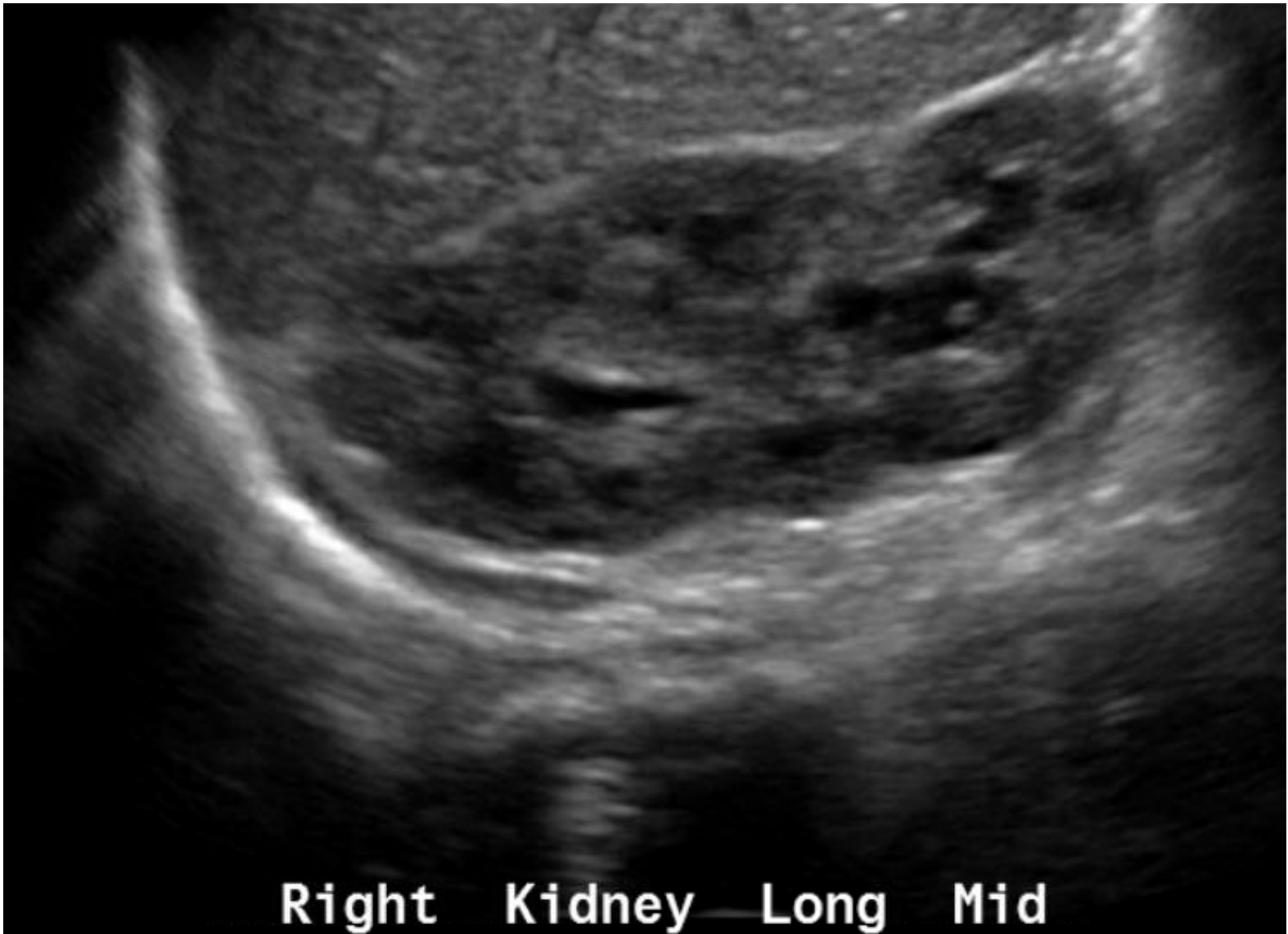



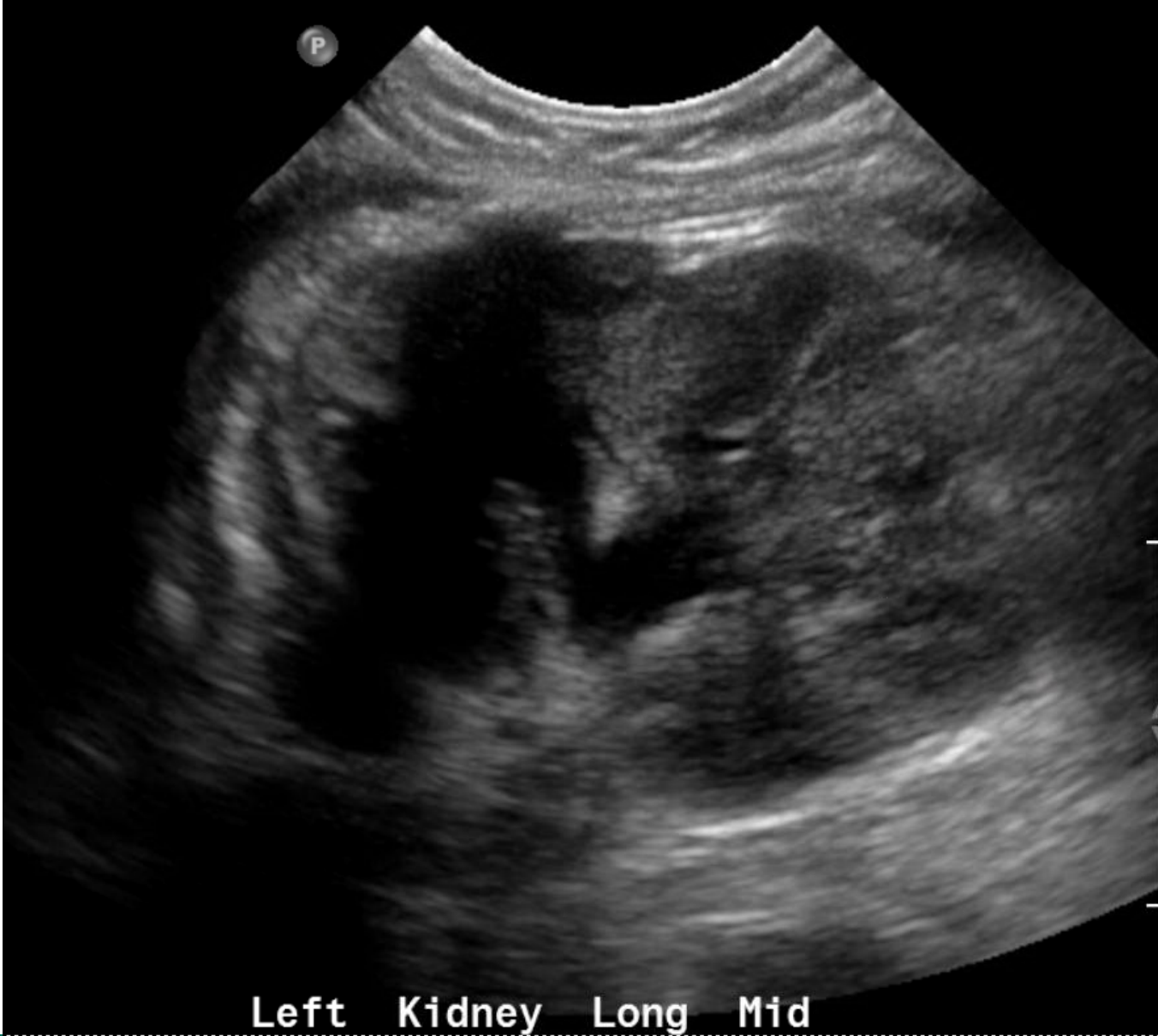What do you see in this image?

1. Vesico-ureteral reflux
2. Seminal vesical reflux
3. All of the above
4. I don't know





Right Kidney Long Mid



Left Kidney Long Mid

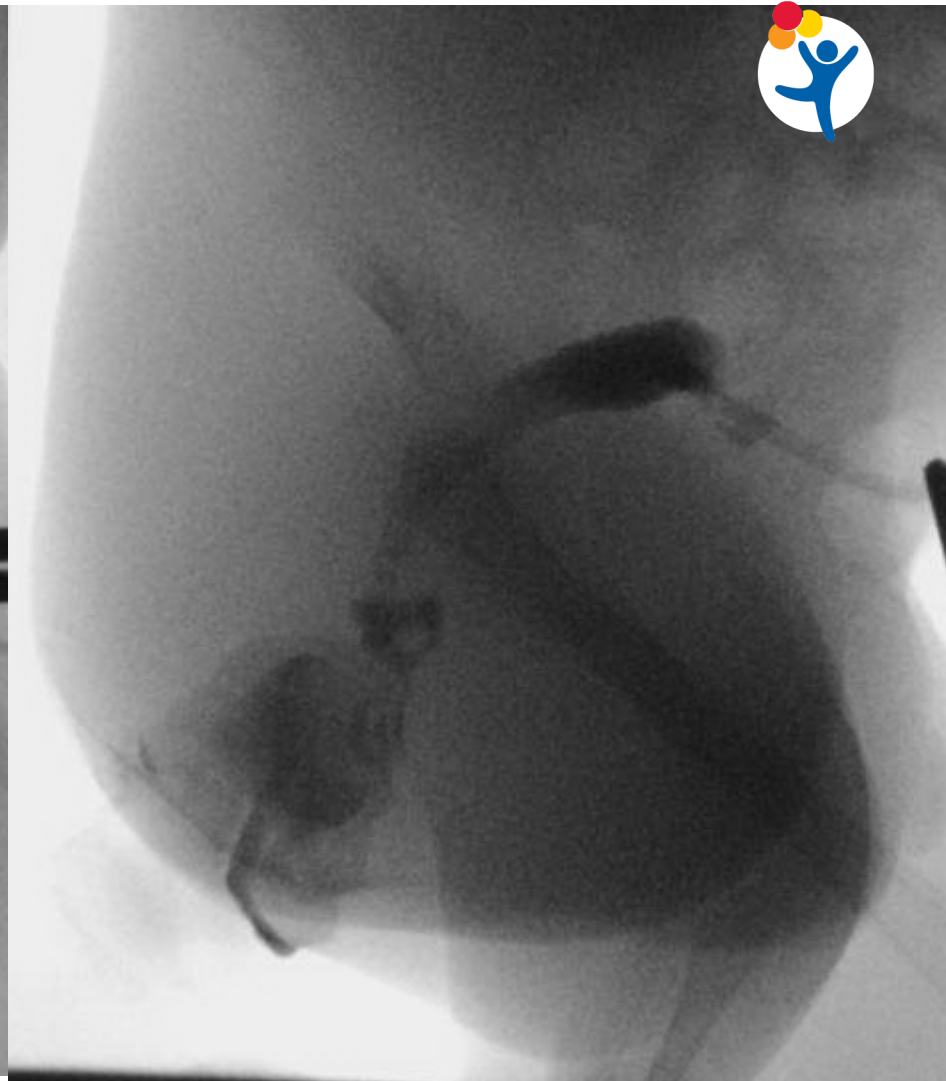
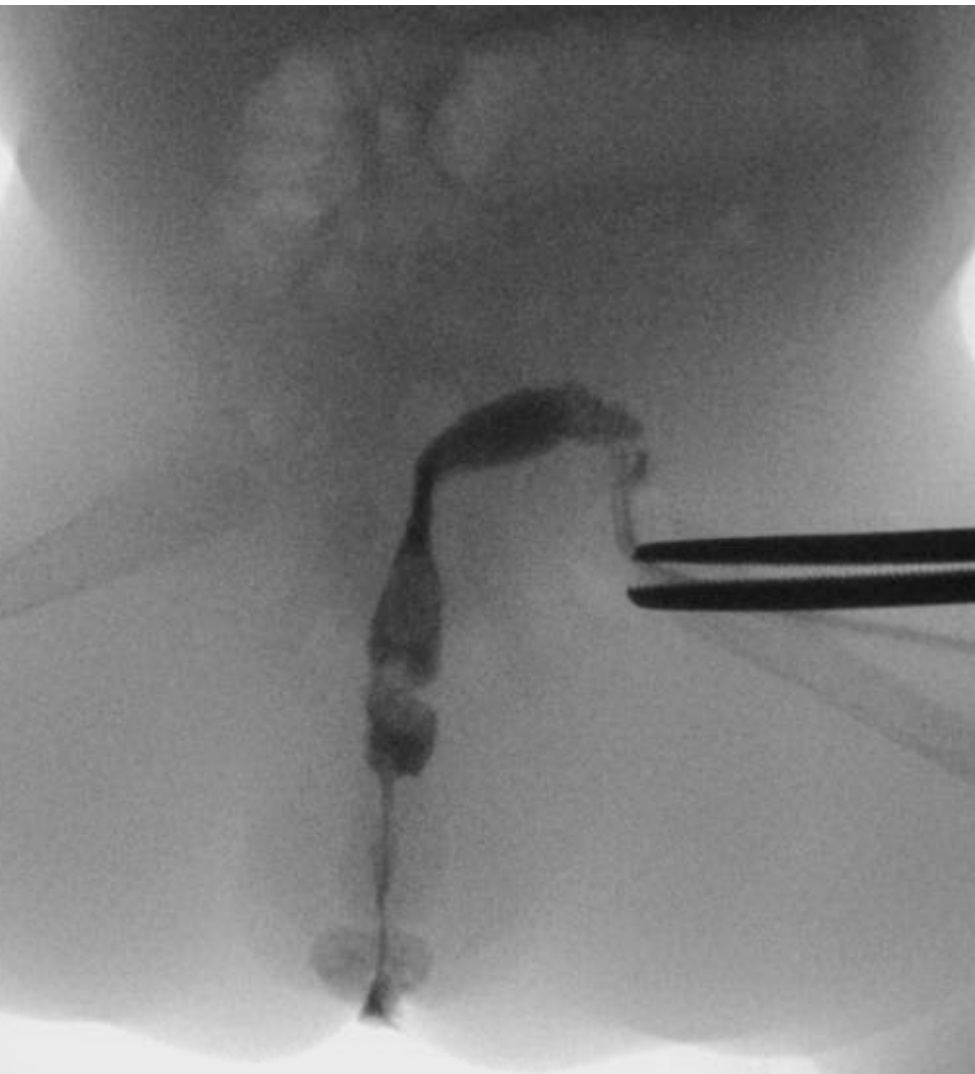

- Patient underwent divided colostomy and vesicostomy and then transferred care to us.
- Unable to adapt stoma bag and having severe skin problems at stoma site.



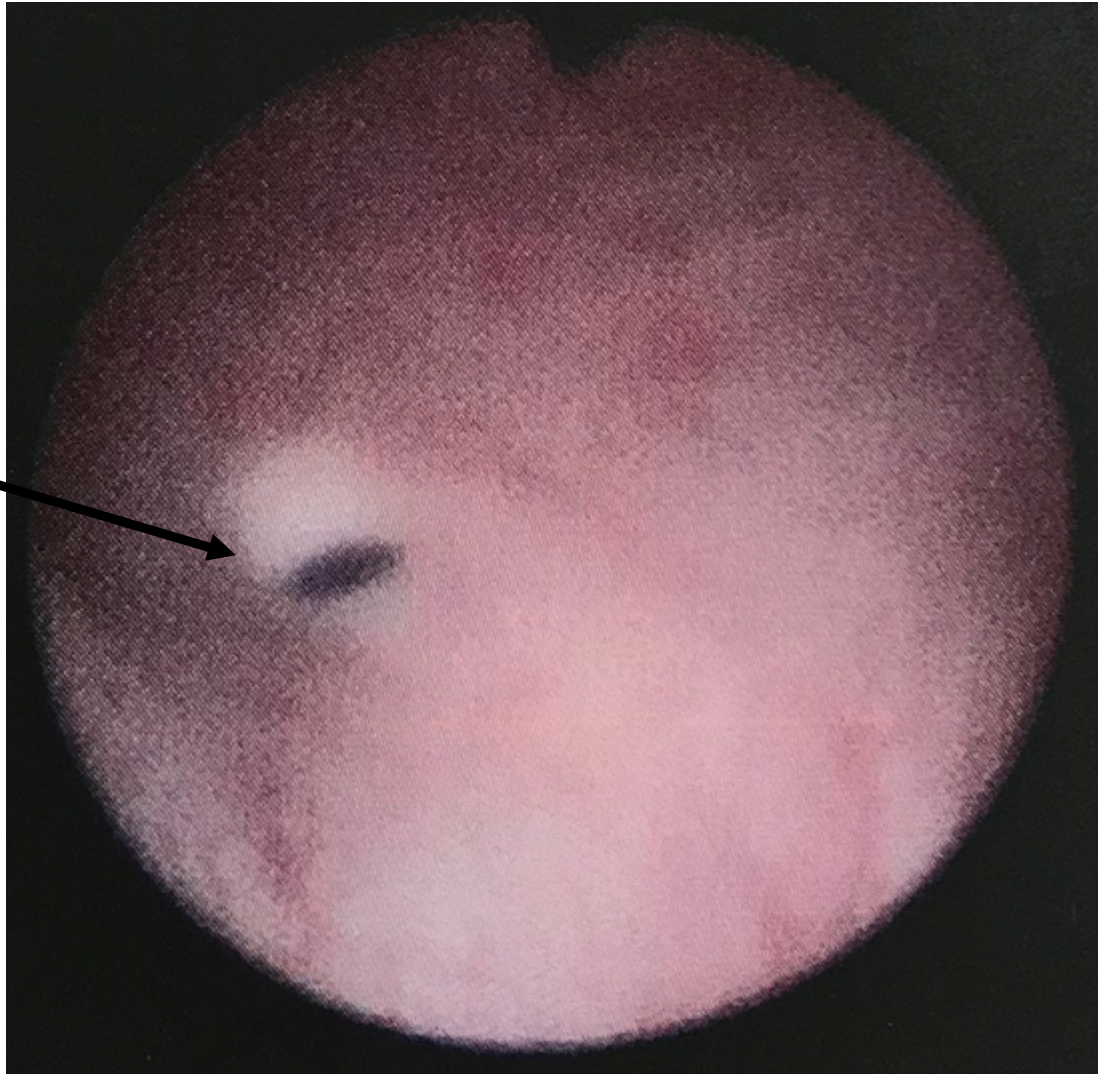
What would you do?

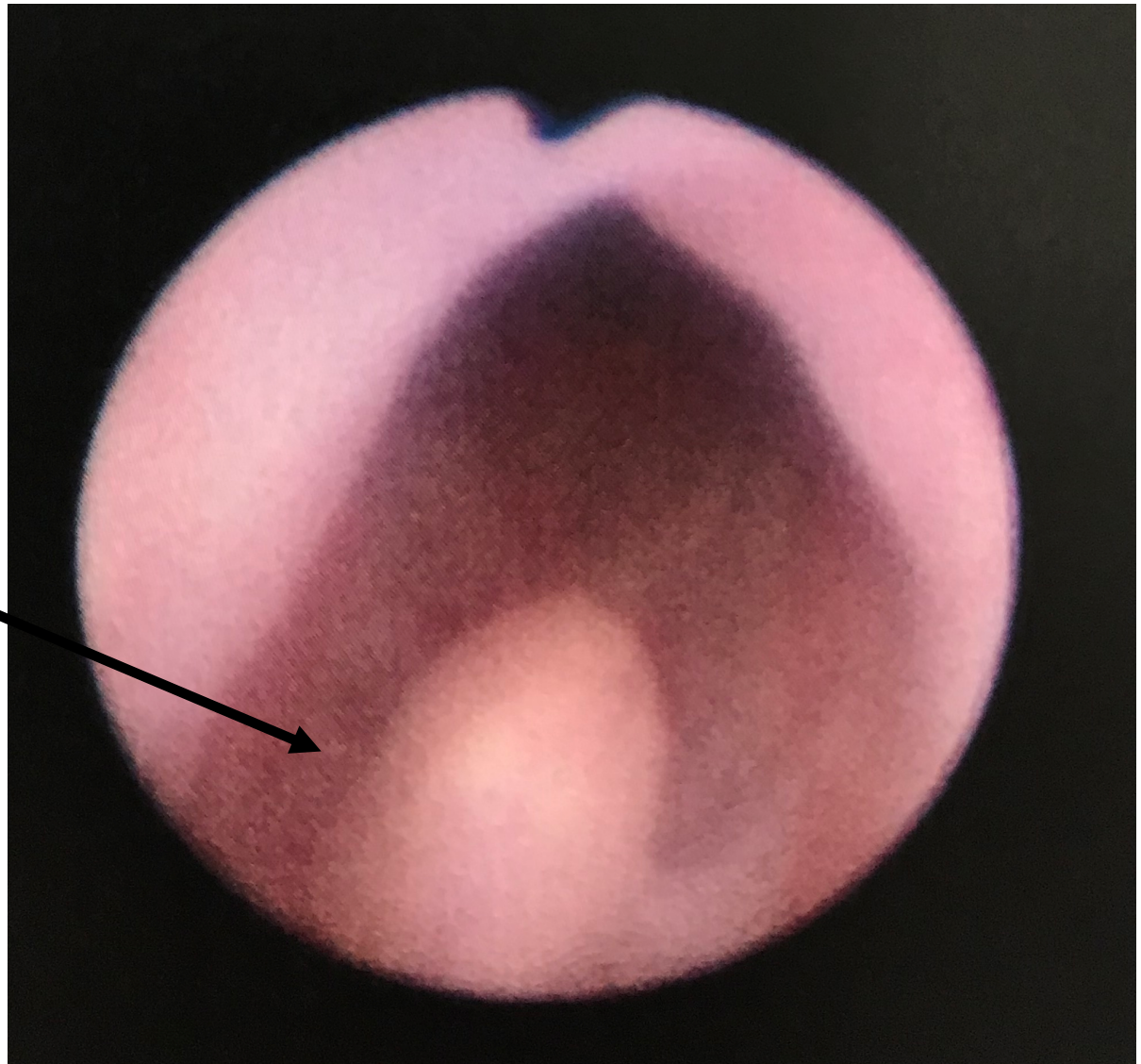
1. PSARP and colostomy closure, stool in the diaper until 3 yo, then start him on bowel management
2. Revise the colostomy
3. Discuss with the family options, advantages and disadvantages.





- Right UO





Verumontanum
inside the bladderneck



