

# The Anal Canal in Hirschsprung

Alberto Peña, MD

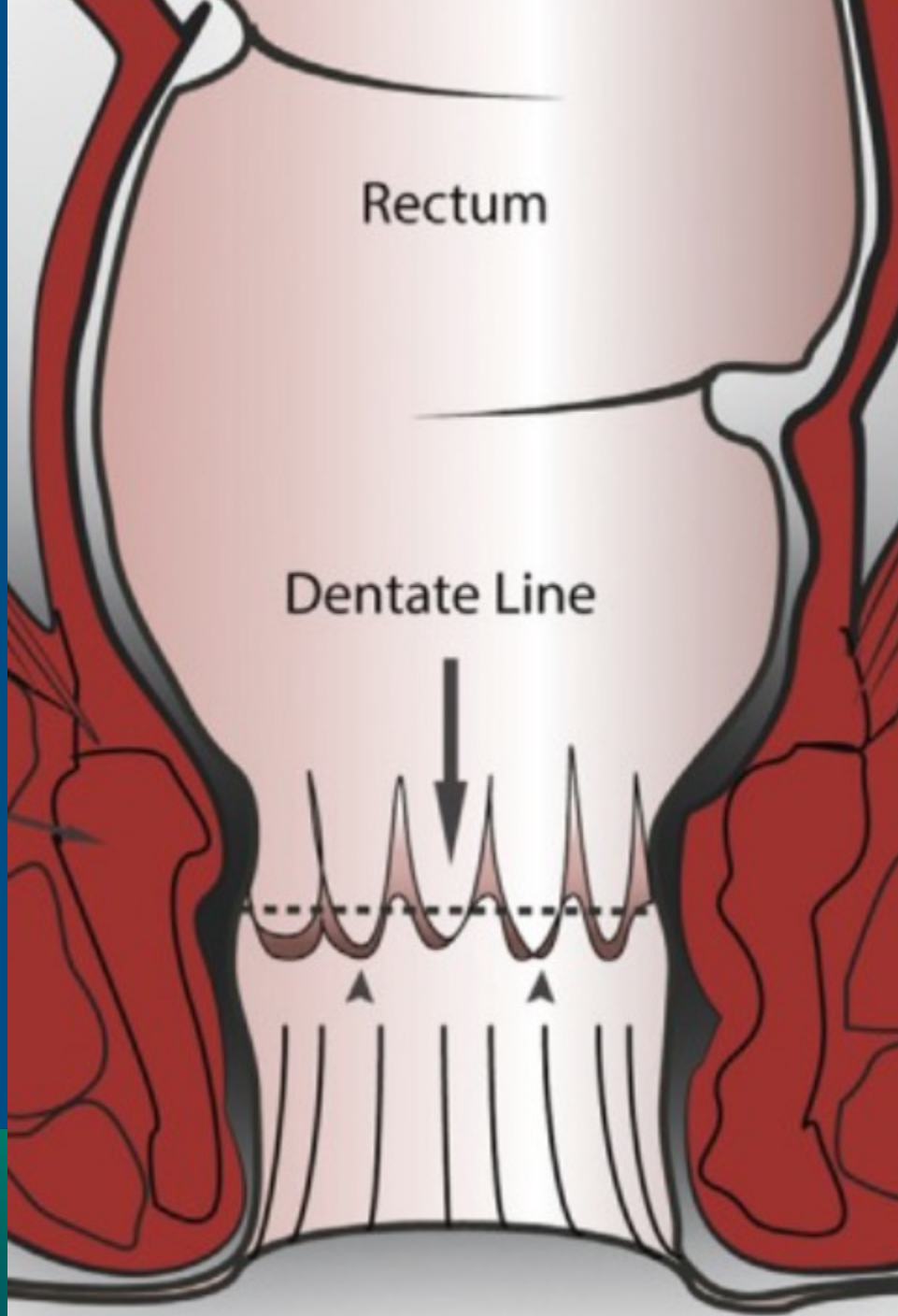
---

Hirschsprung Course, August 12<sup>th</sup> – 13<sup>th</sup>, 2021

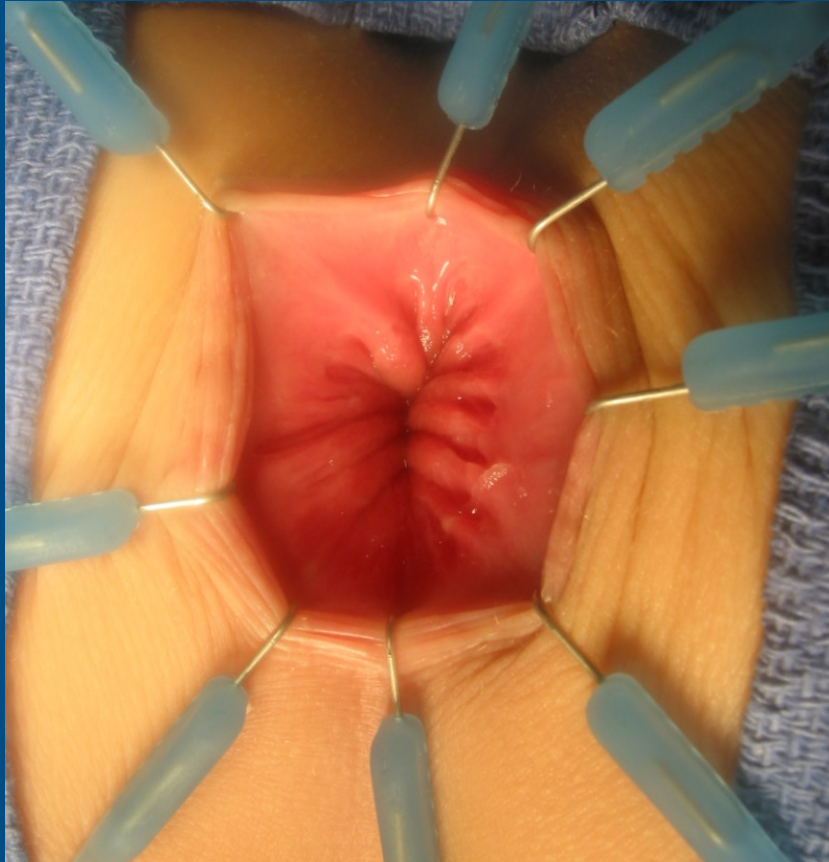


Children's Hospital Colorado

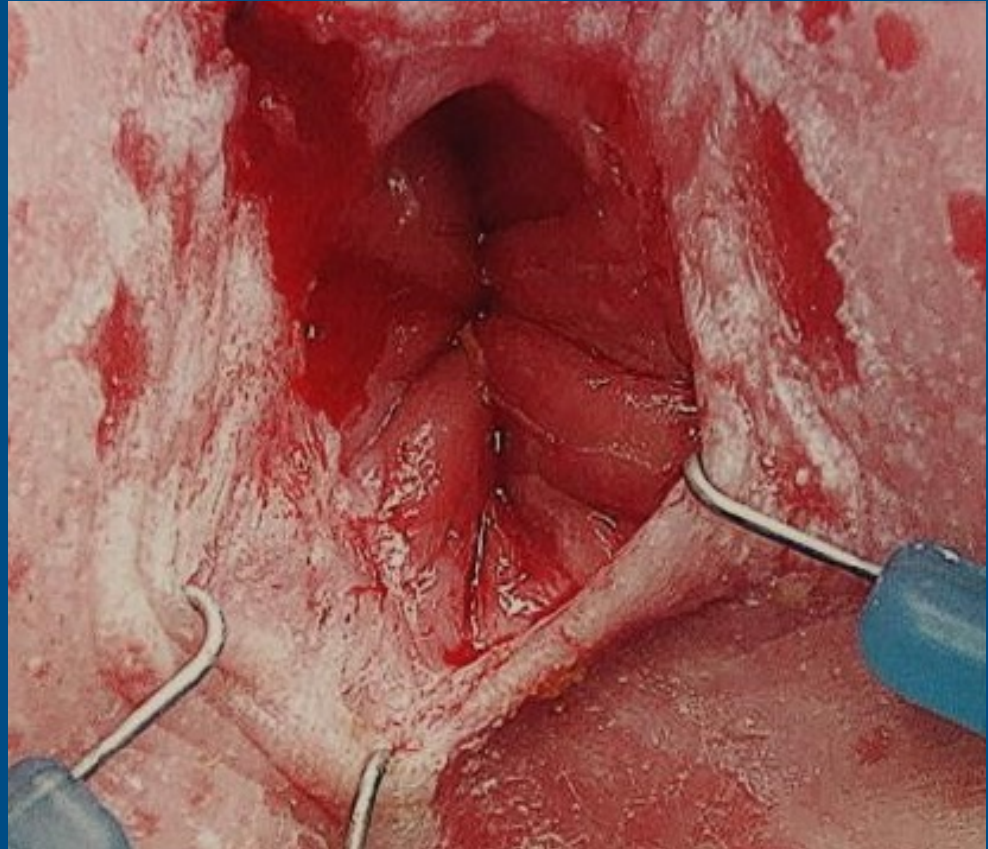
INTERNATIONAL CENTER FOR  
**COLORECTAL AND  
UROGENITAL CARE**



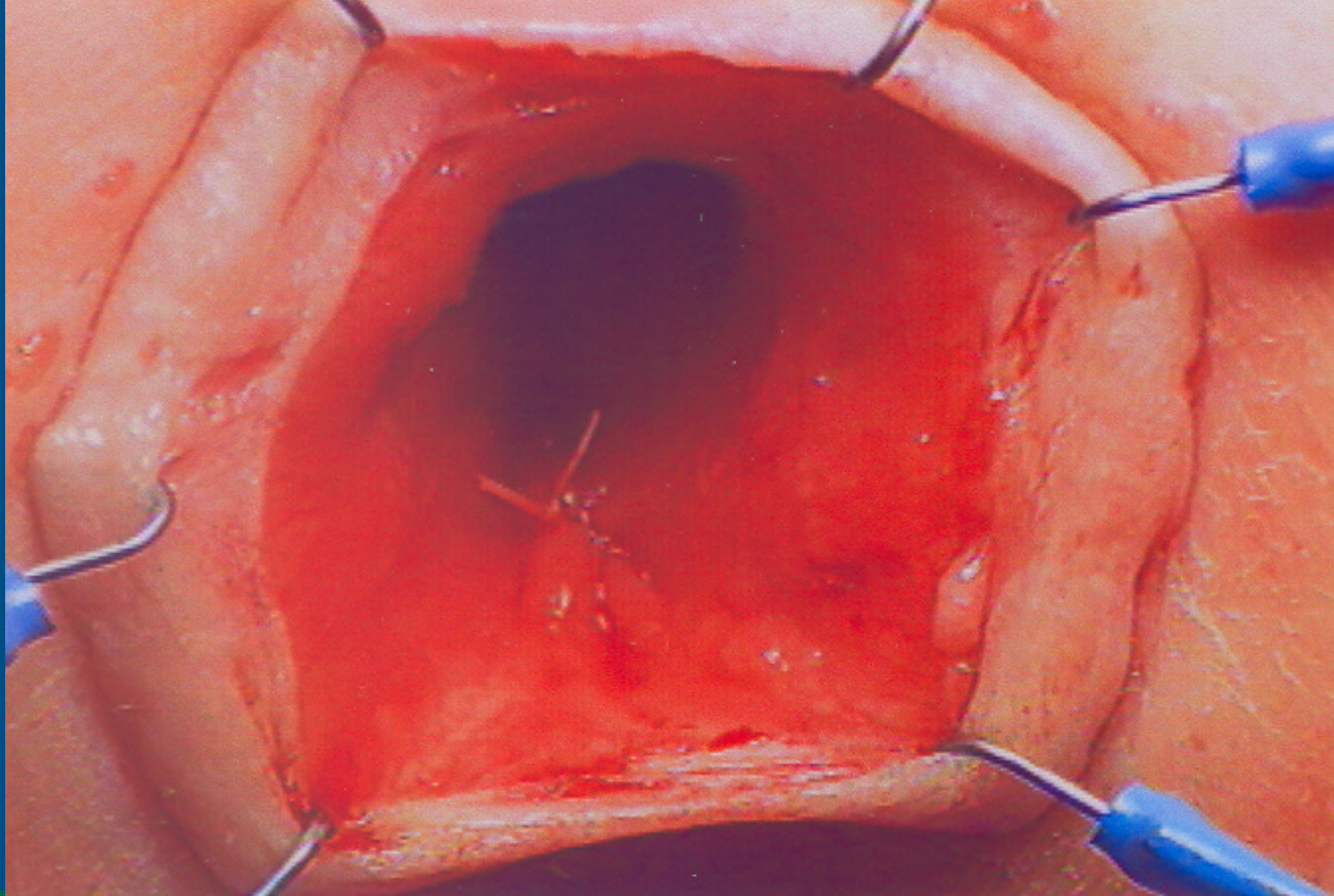
# Normal anal canal



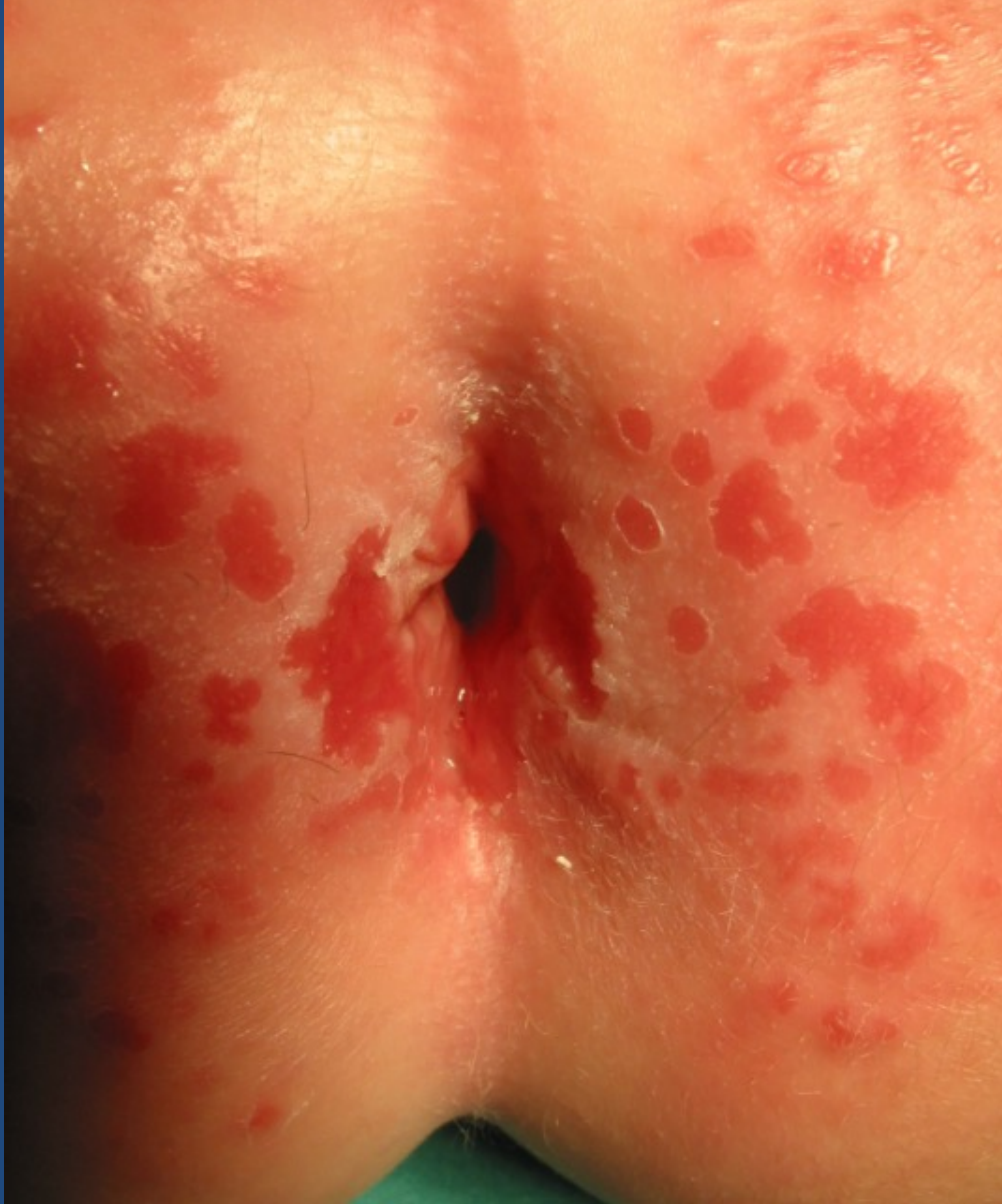# Damaged anal canal



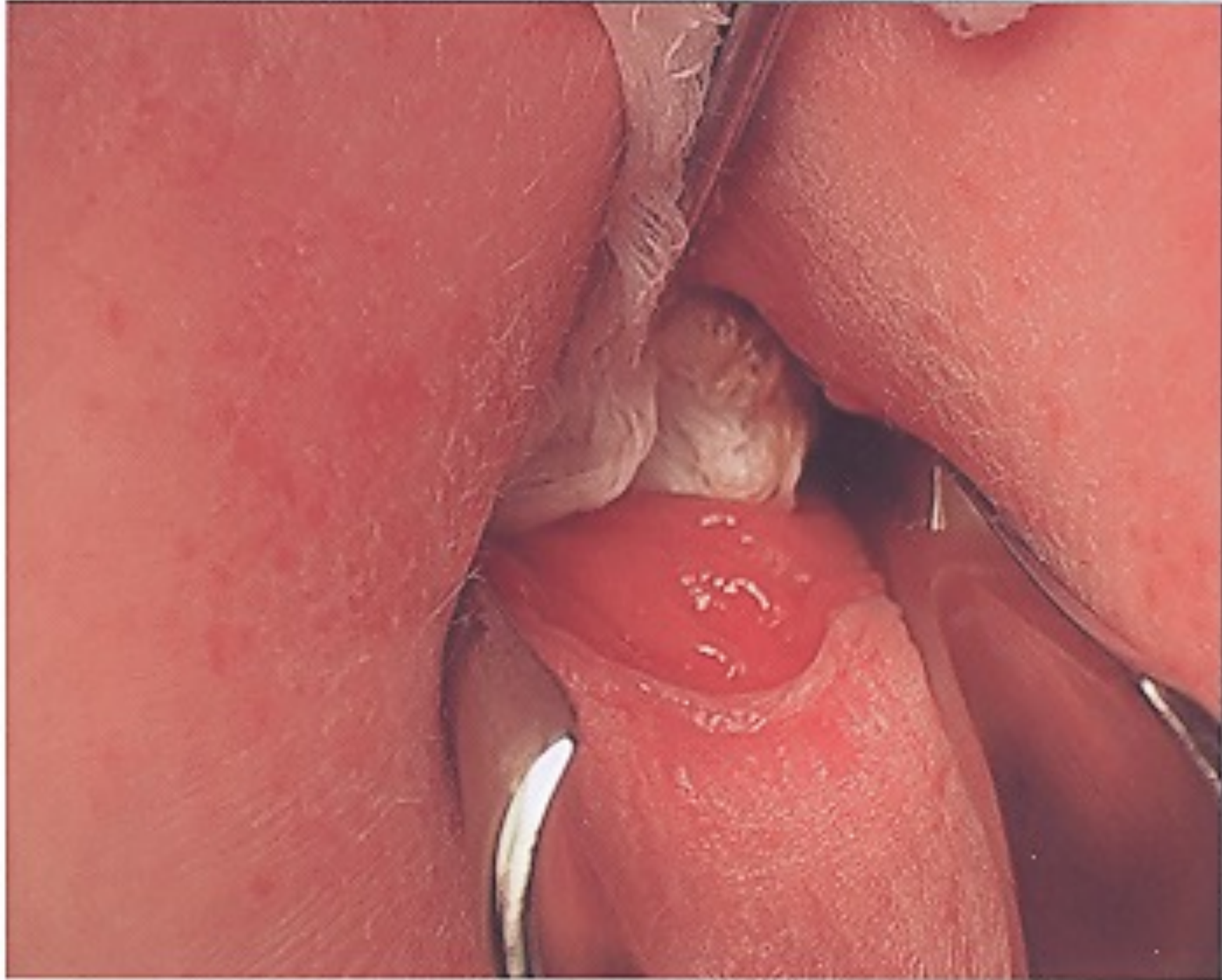


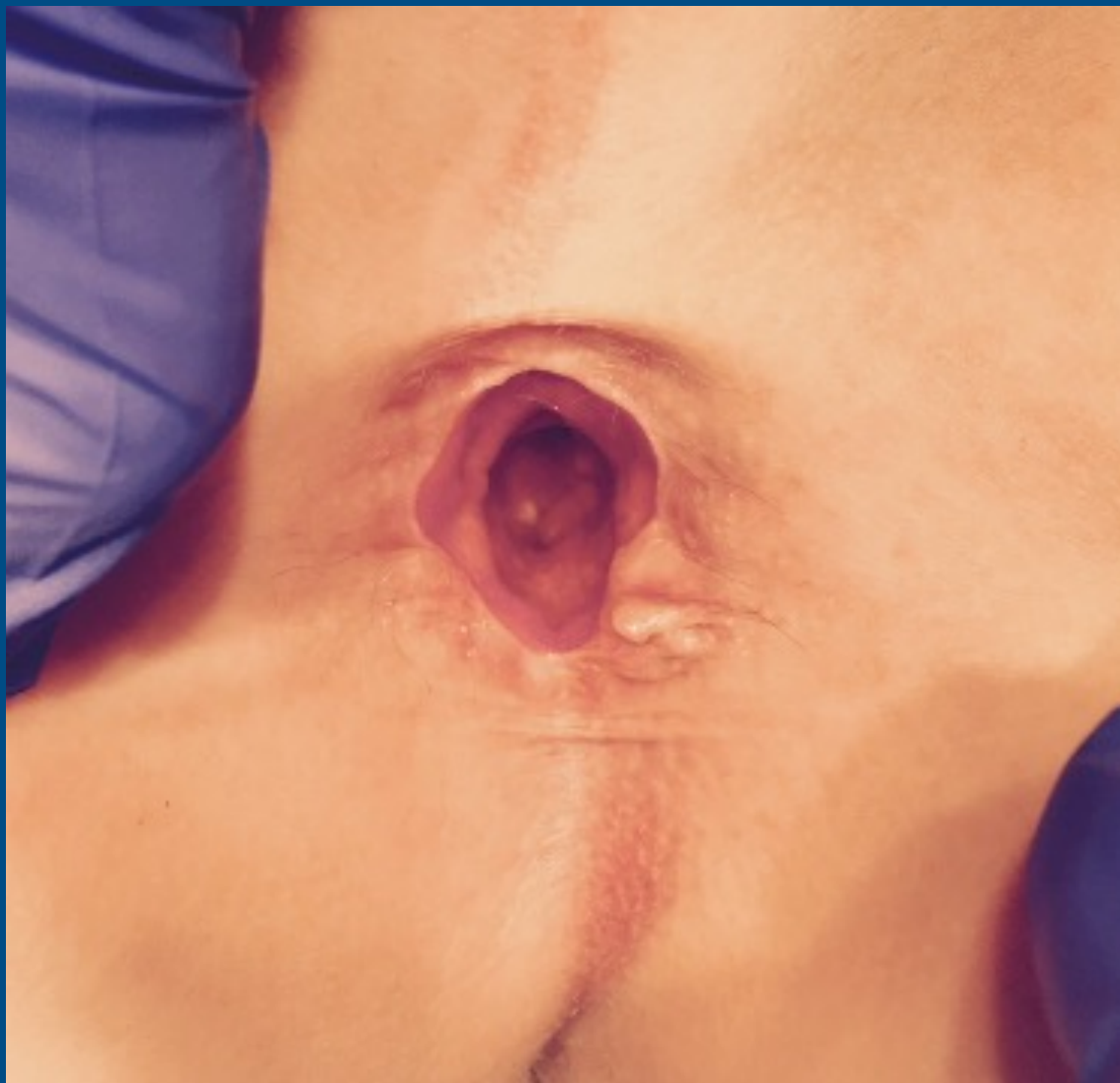

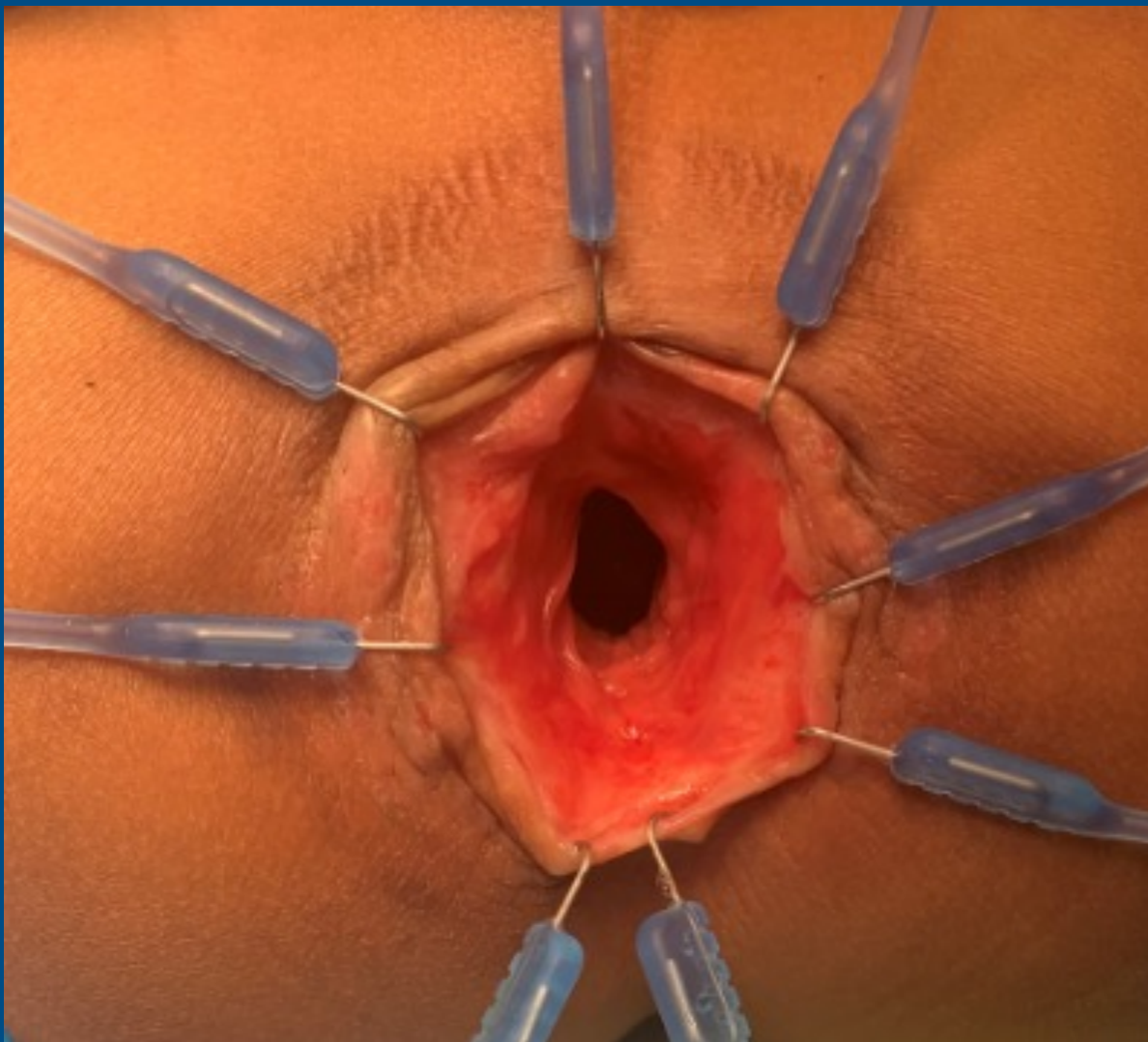
INTERNATIONAL CENTER FOR  
**COLORECTAL AND  
UROGENITAL CARE**





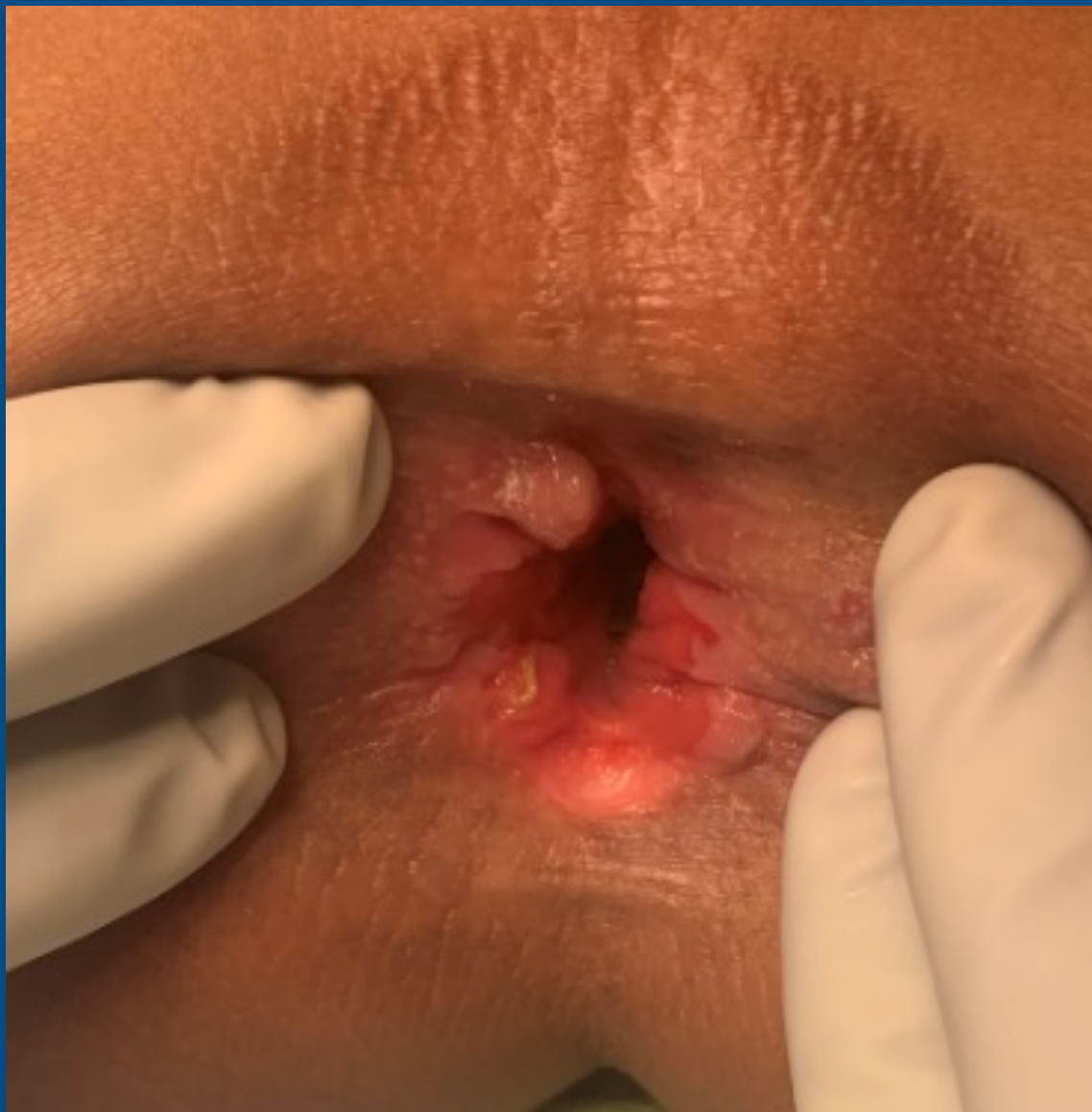





INTERNATIONAL CENTER FOR  
**COLORECTAL AND  
UROGENITAL CARE**





# Appendicostomy and Neo-Appendicostomy

Alberto Peña, MD

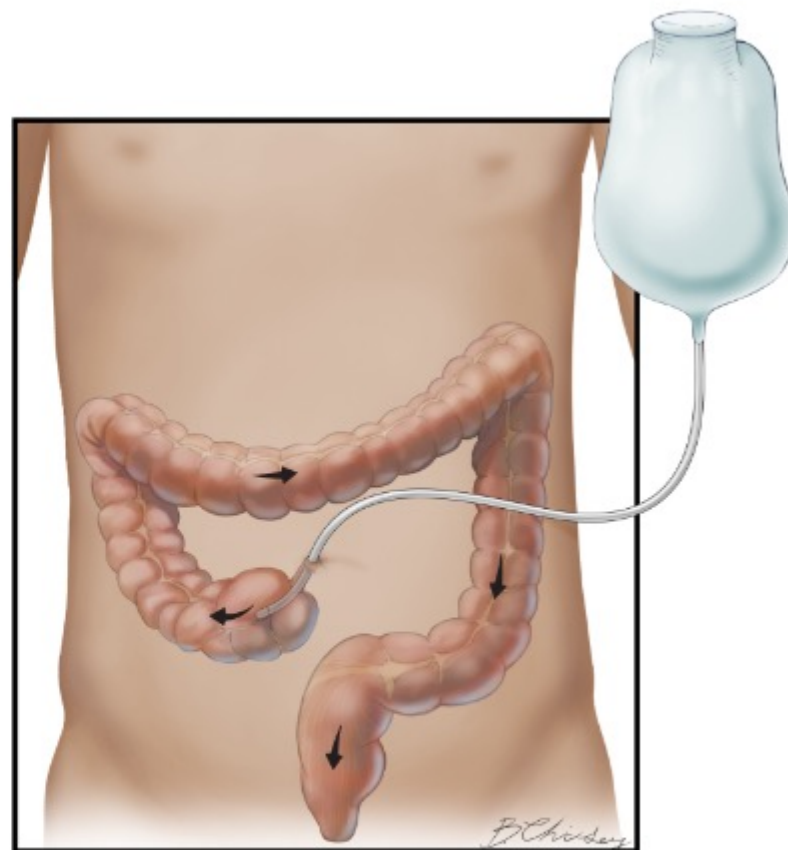
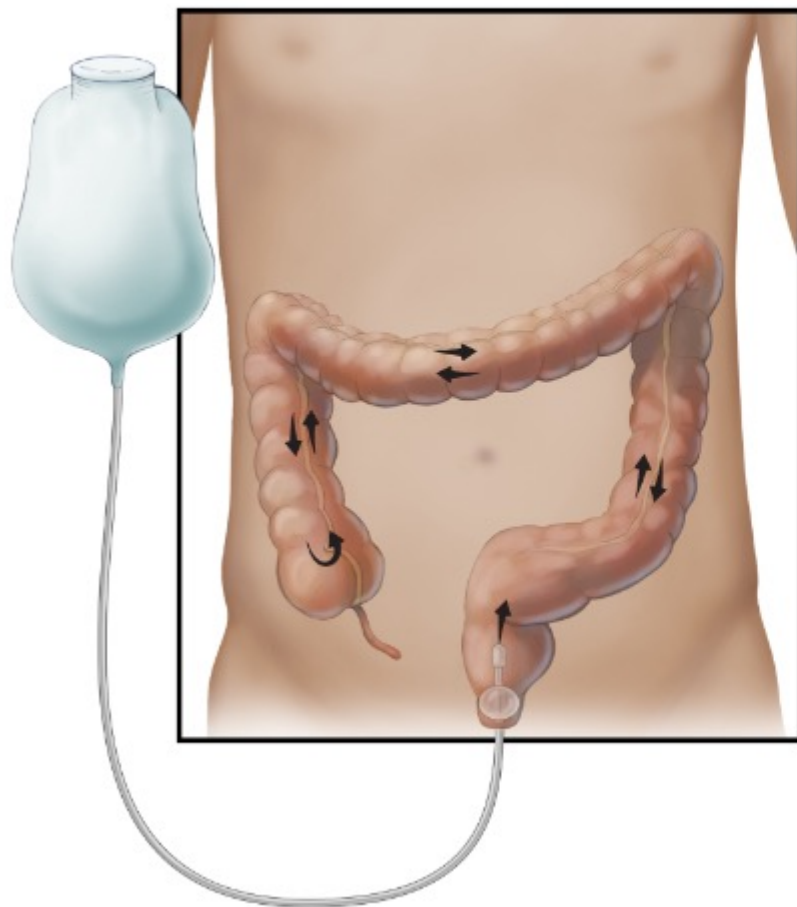
---

Hirschsprung Course, August 12<sup>th</sup> – 13<sup>th</sup>, 2021



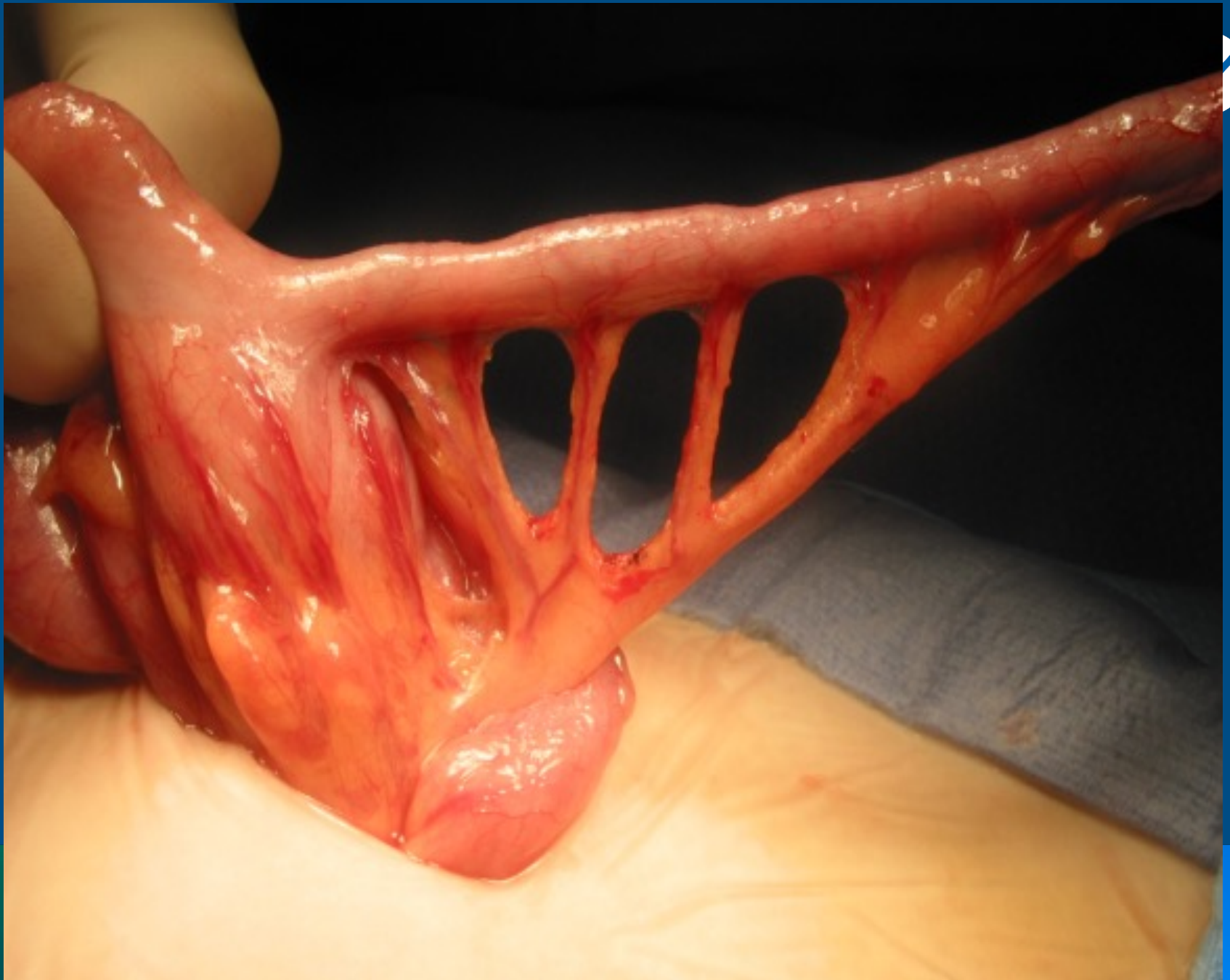
Children's Hospital Colorado

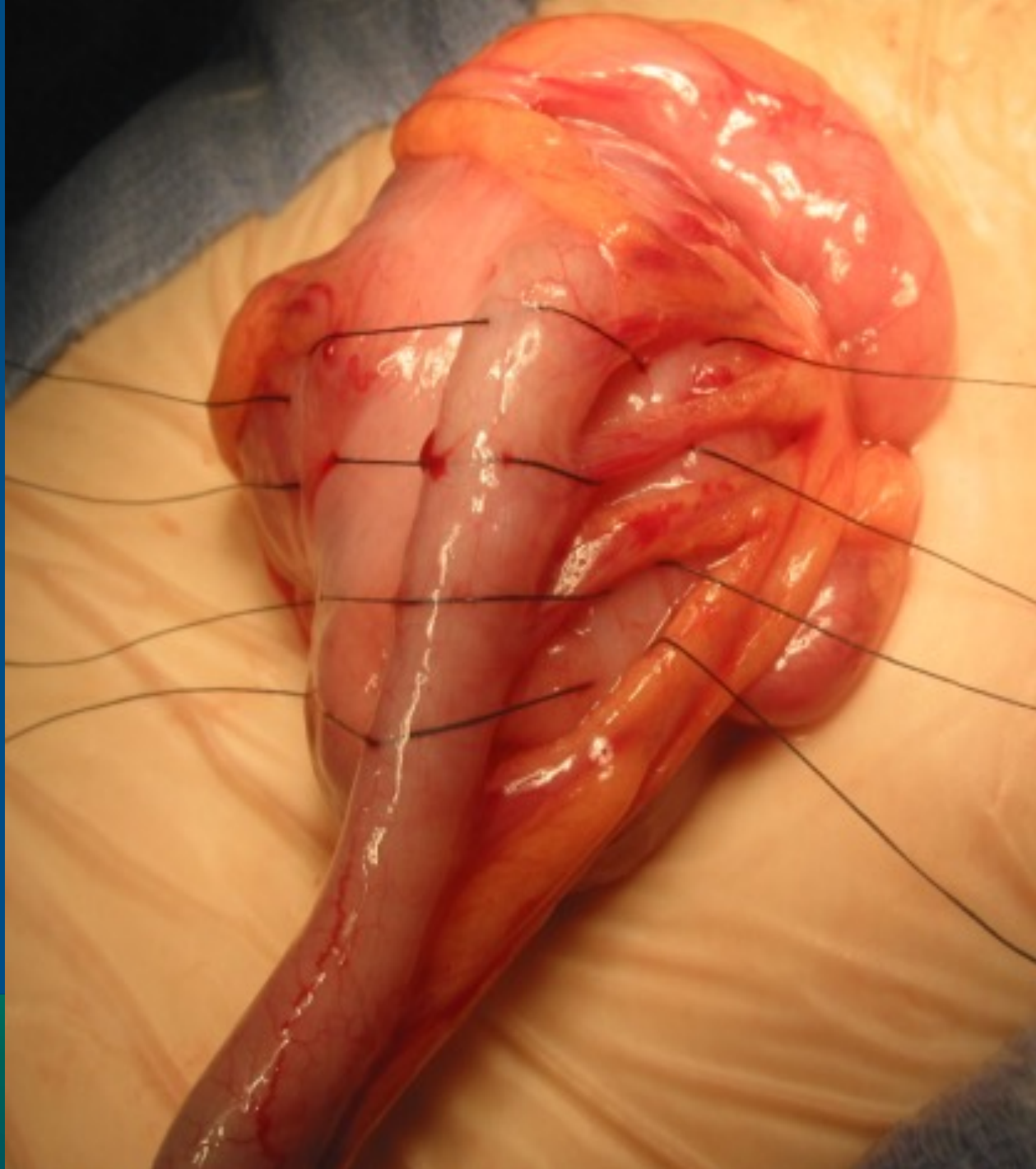
INTERNATIONAL CENTER FOR  
**COLORECTAL AND  
UROGENITAL CARE**



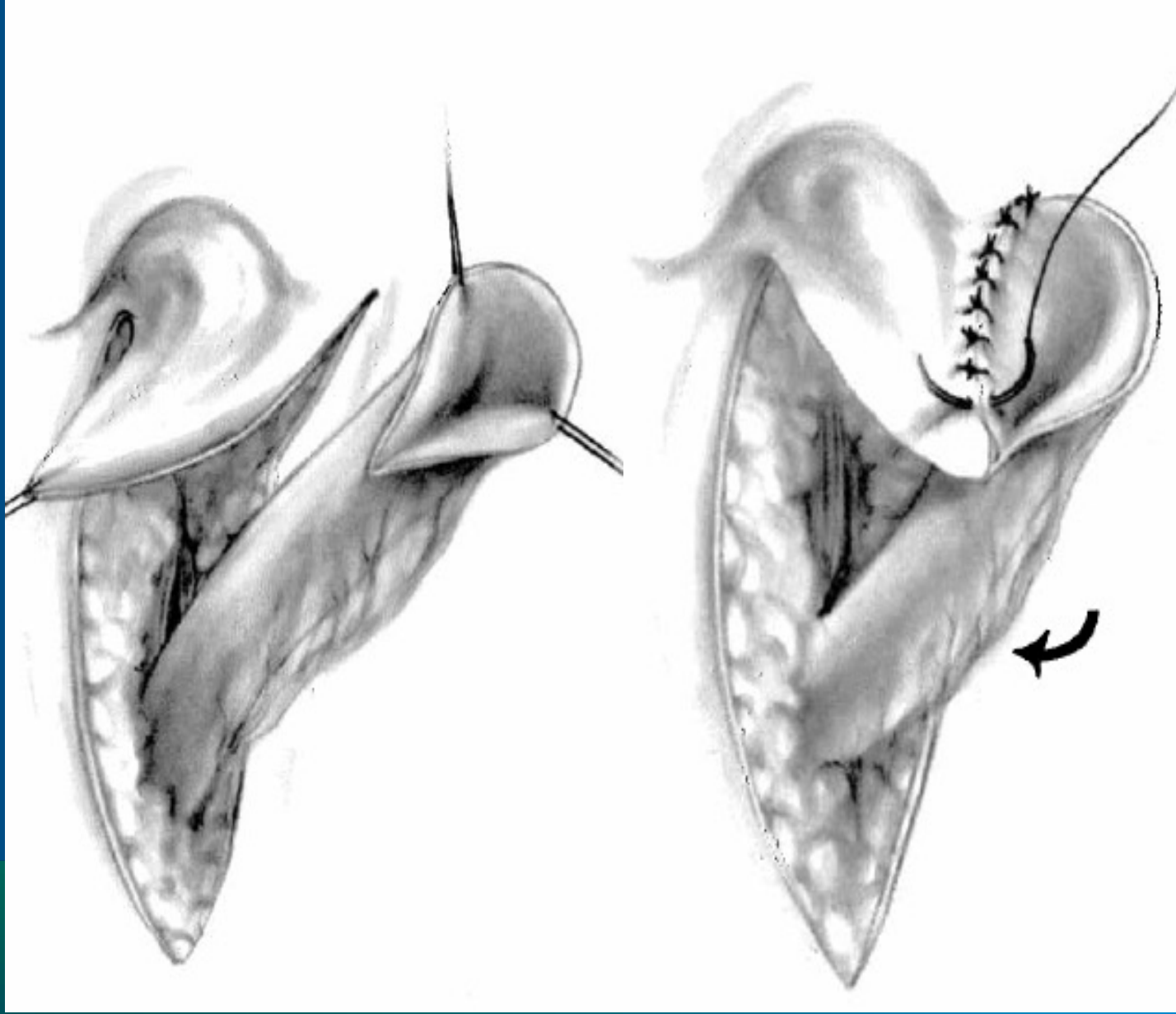
Illustrations Copyright 2017 Regents of the University of Colorado.  
All Rights Reserved. Illustrations created by Berrien Chidsey.



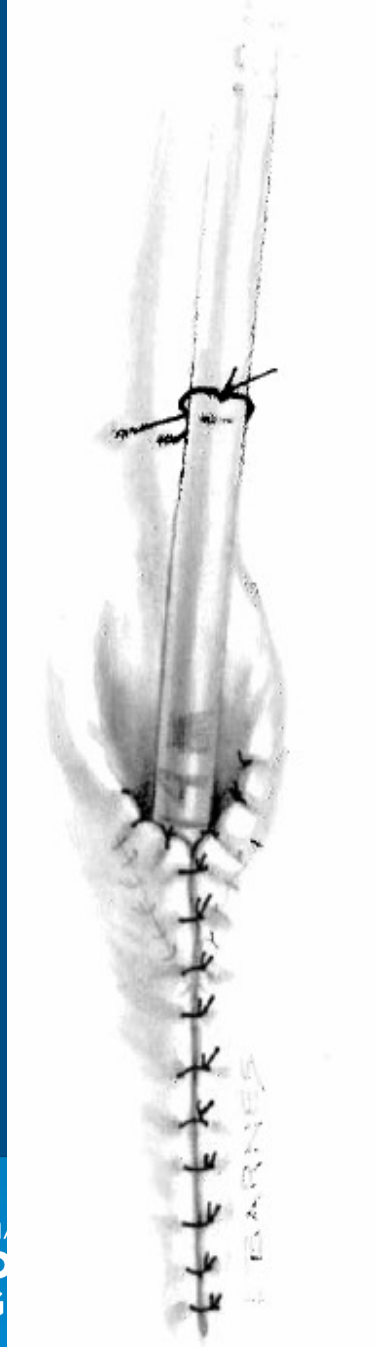



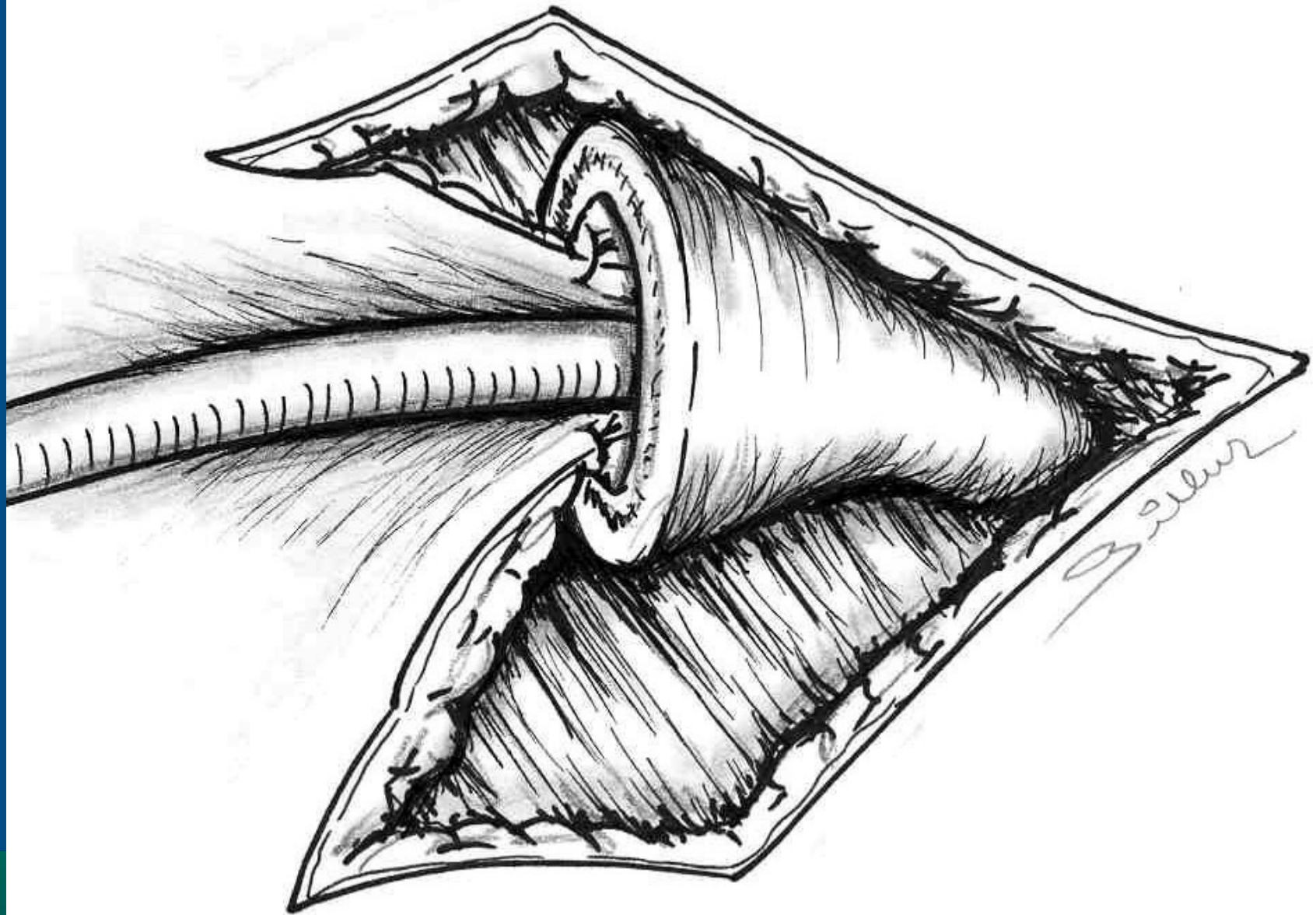
CENTER FOR  
**FETAL AND**  
**NEONATAL CARE**

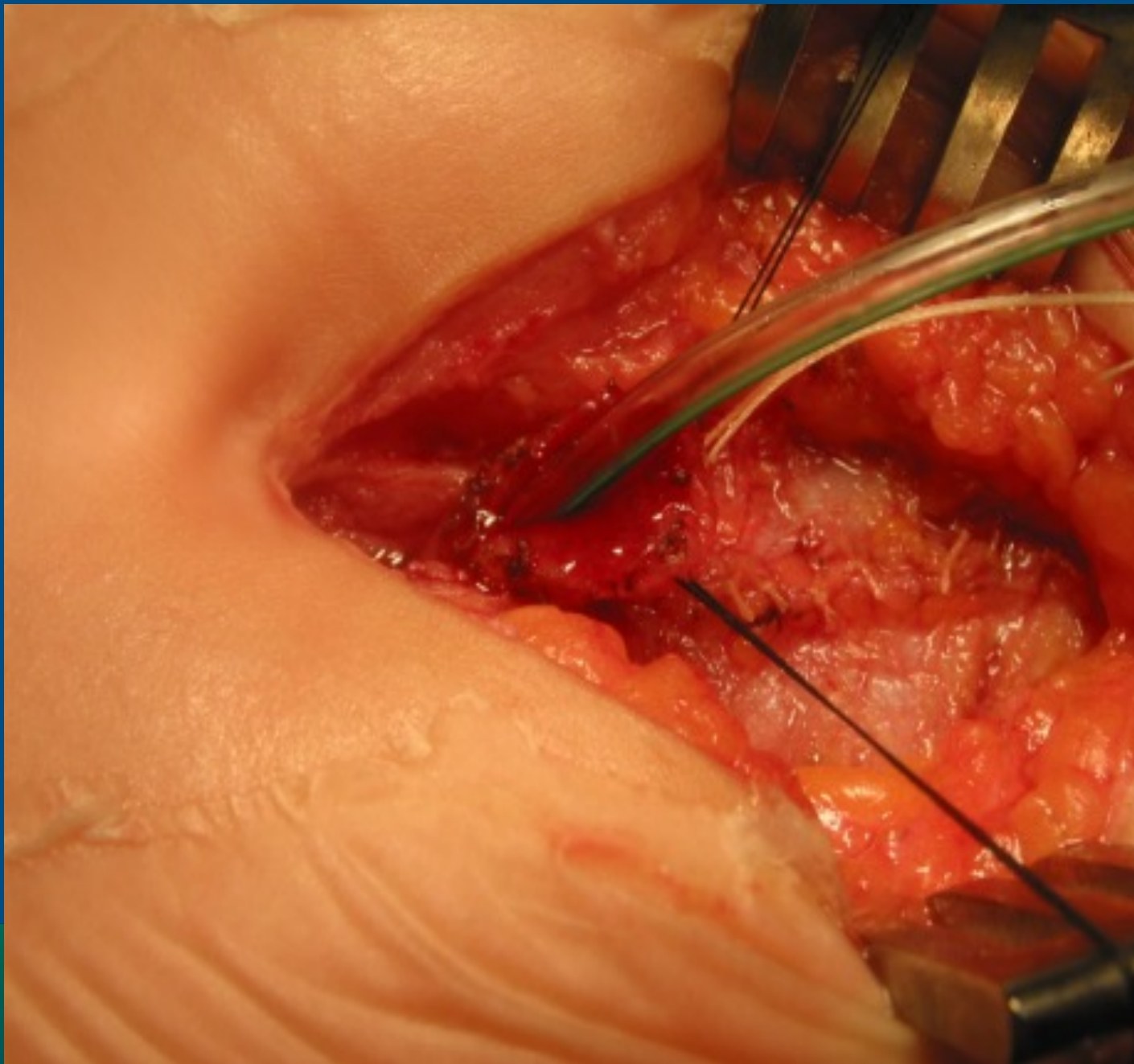


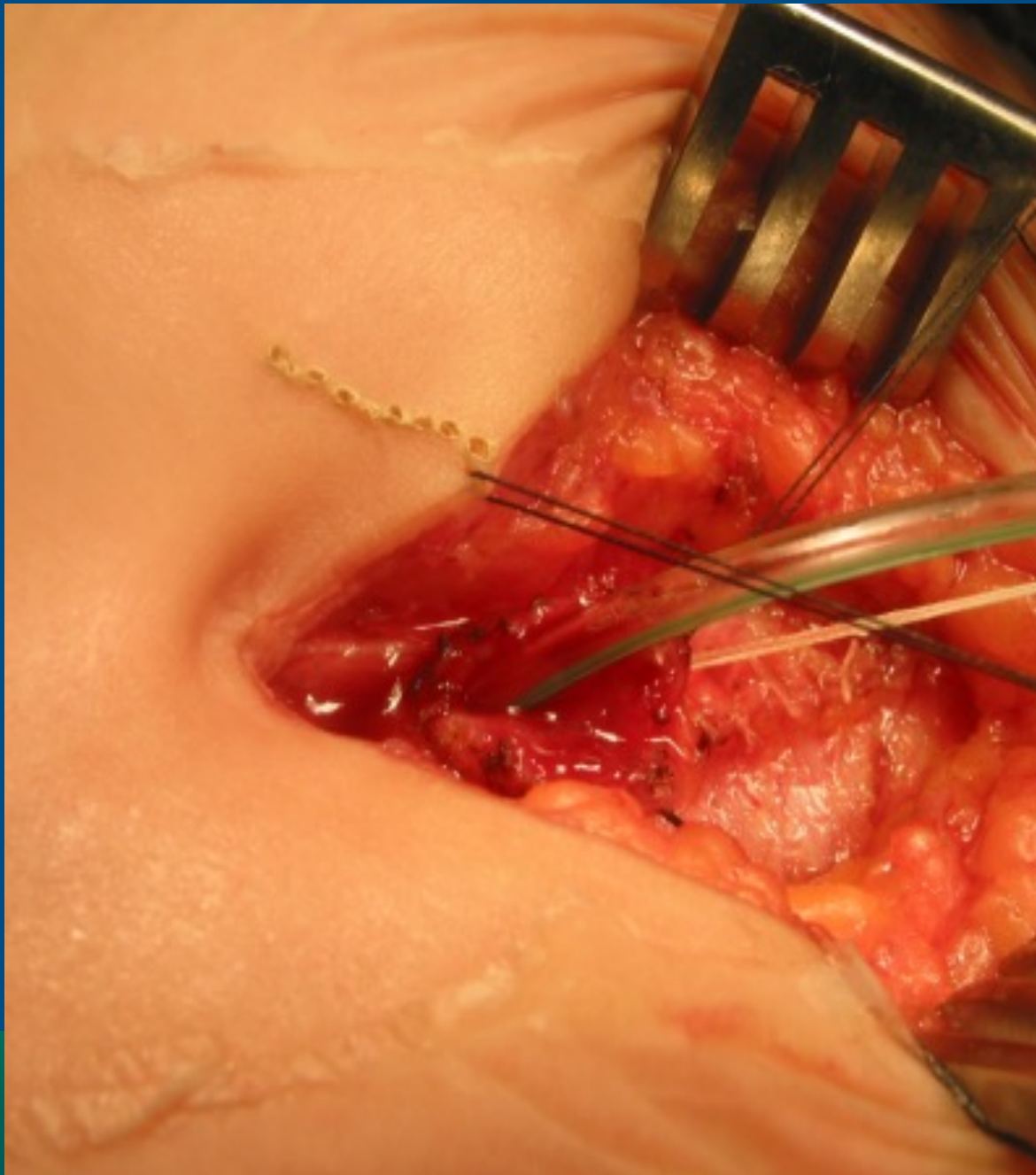
200





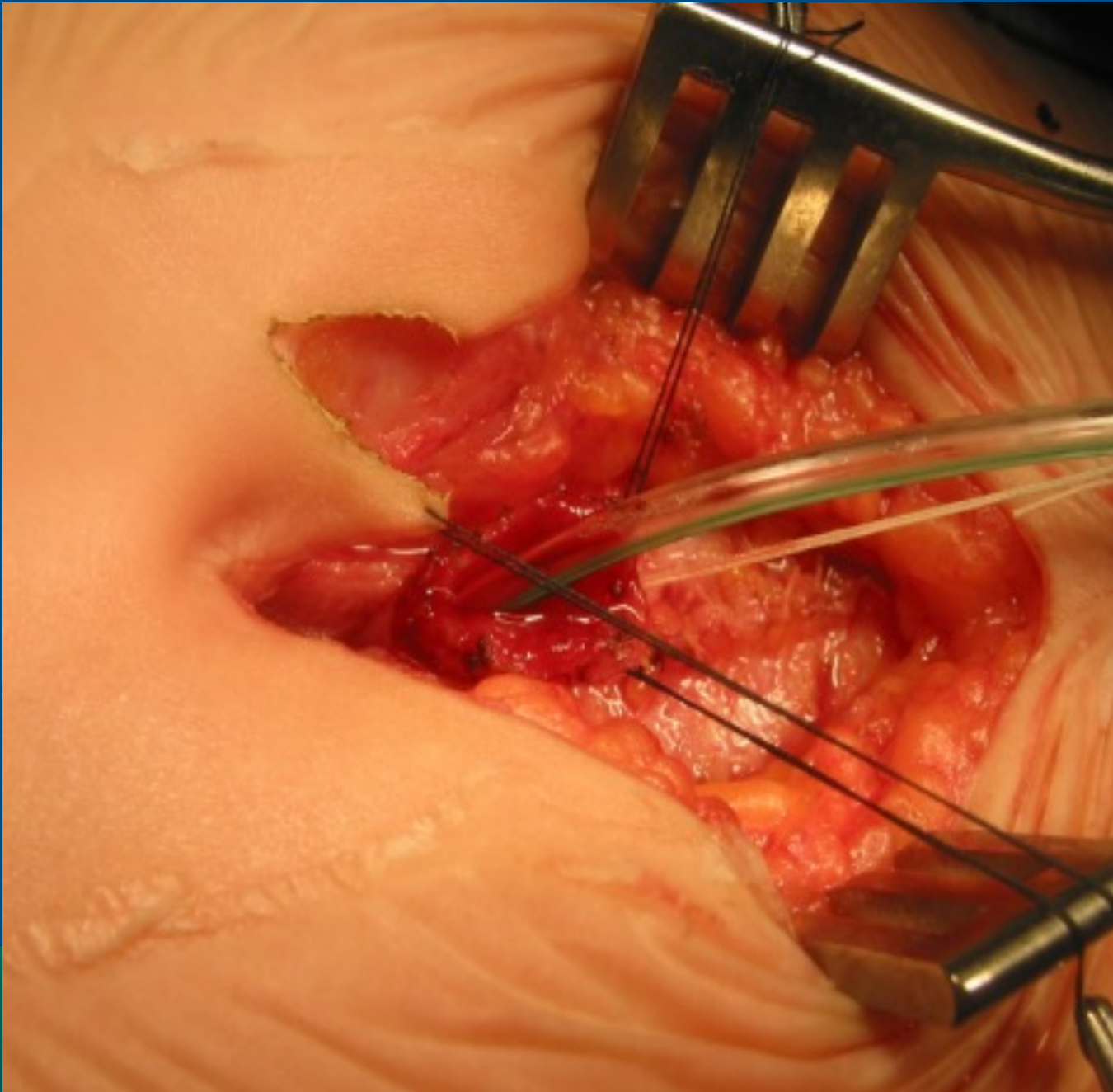


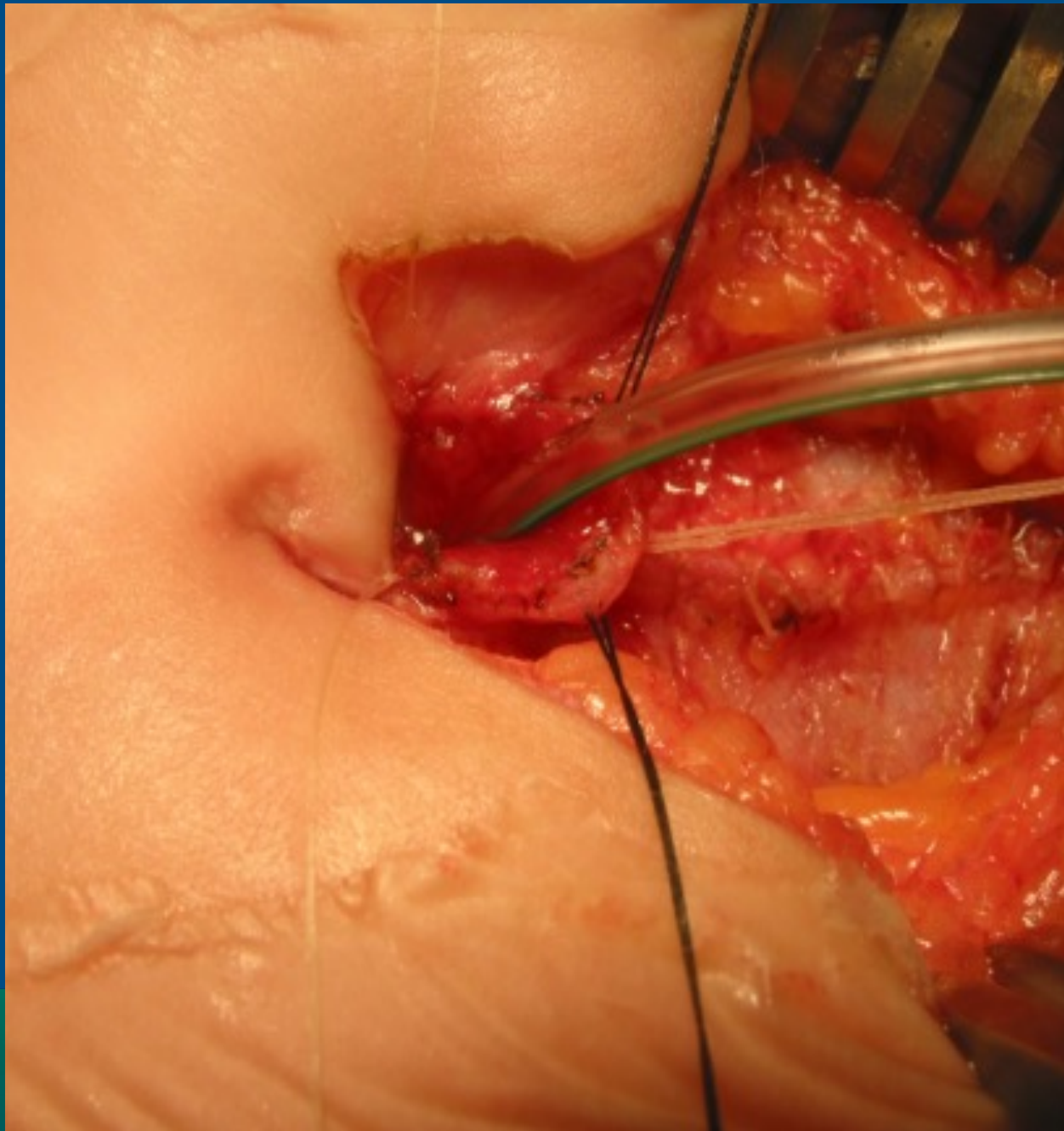


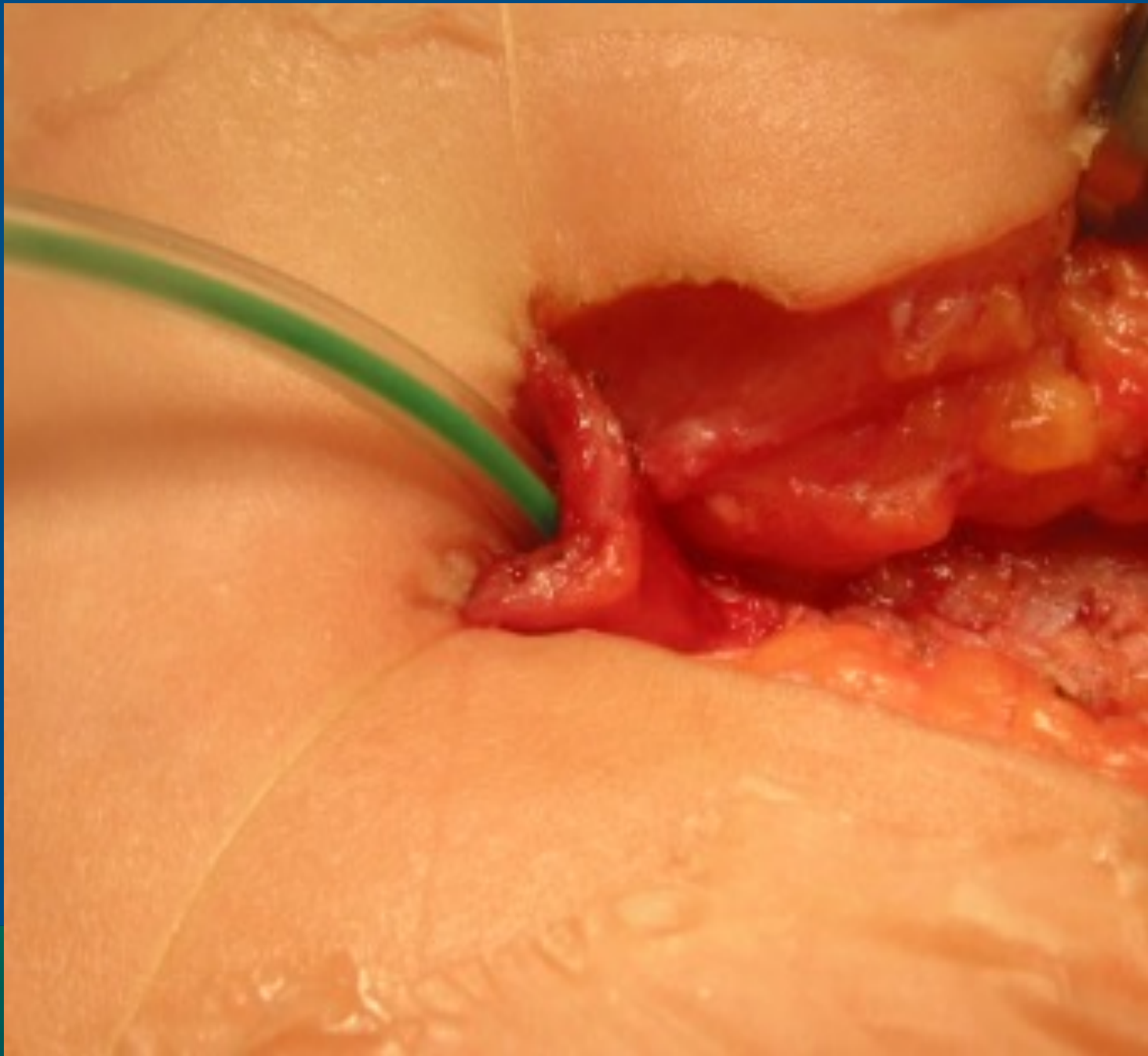


NATIONAL CENTER FOR  
**RECTAL AND  
ANAL CARE**

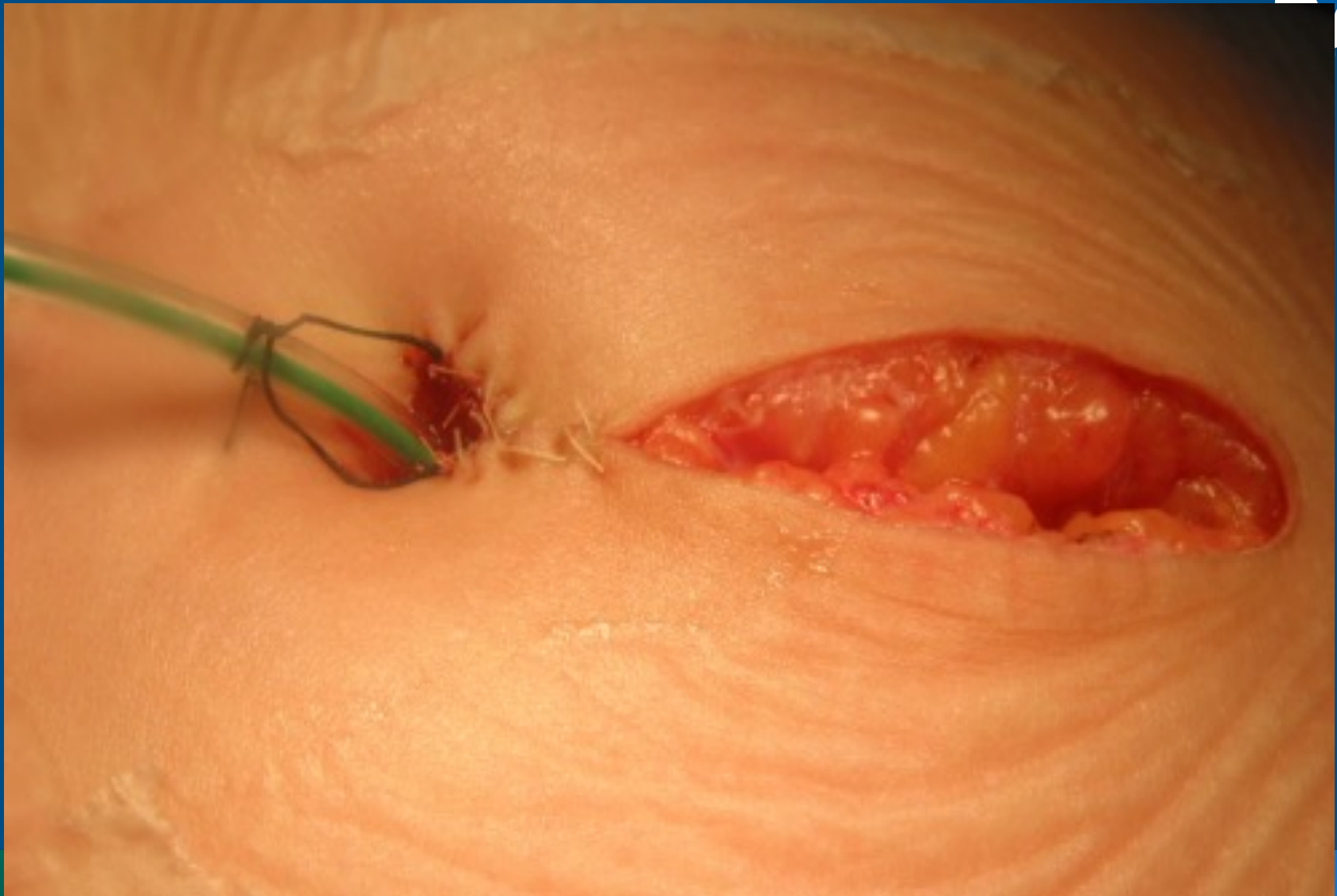




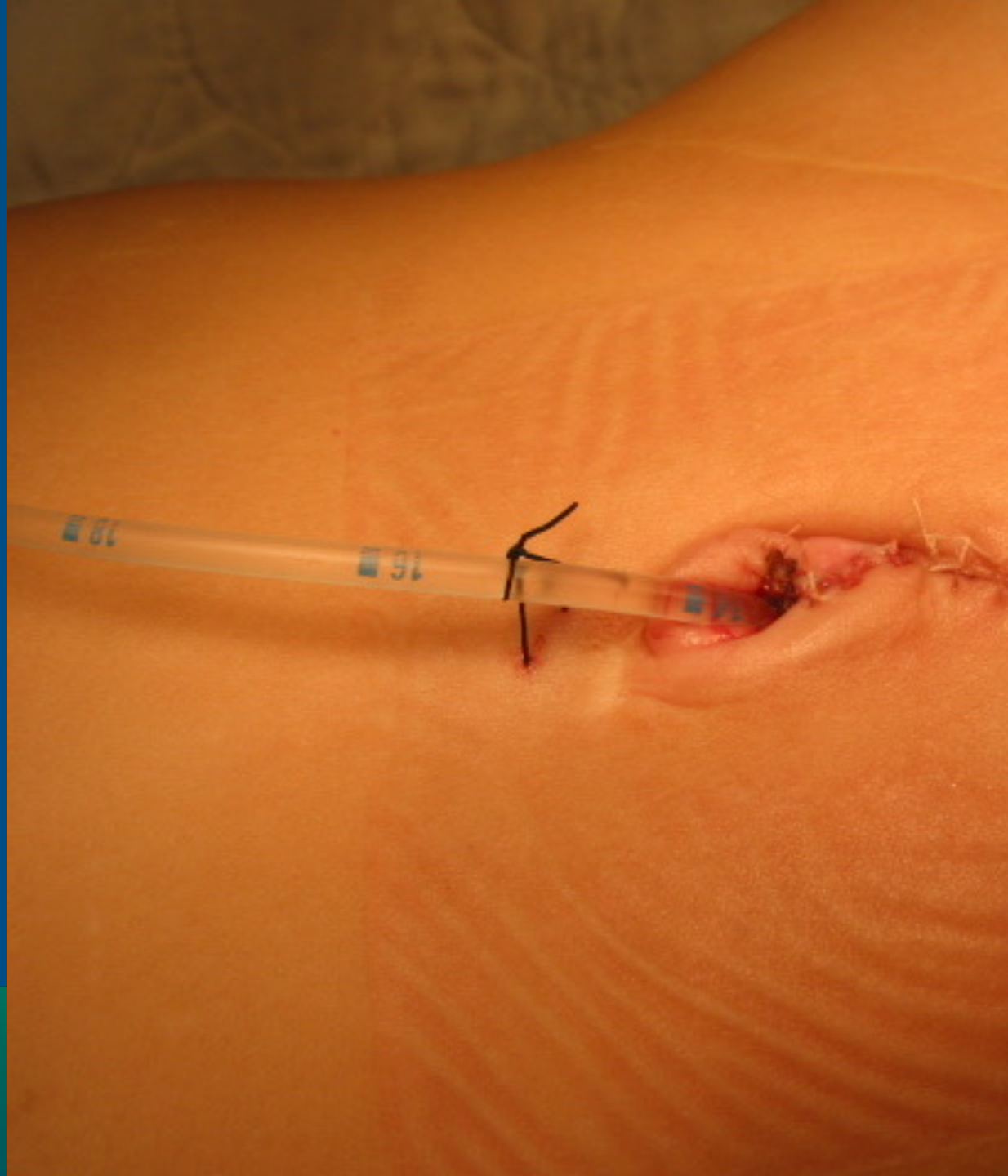

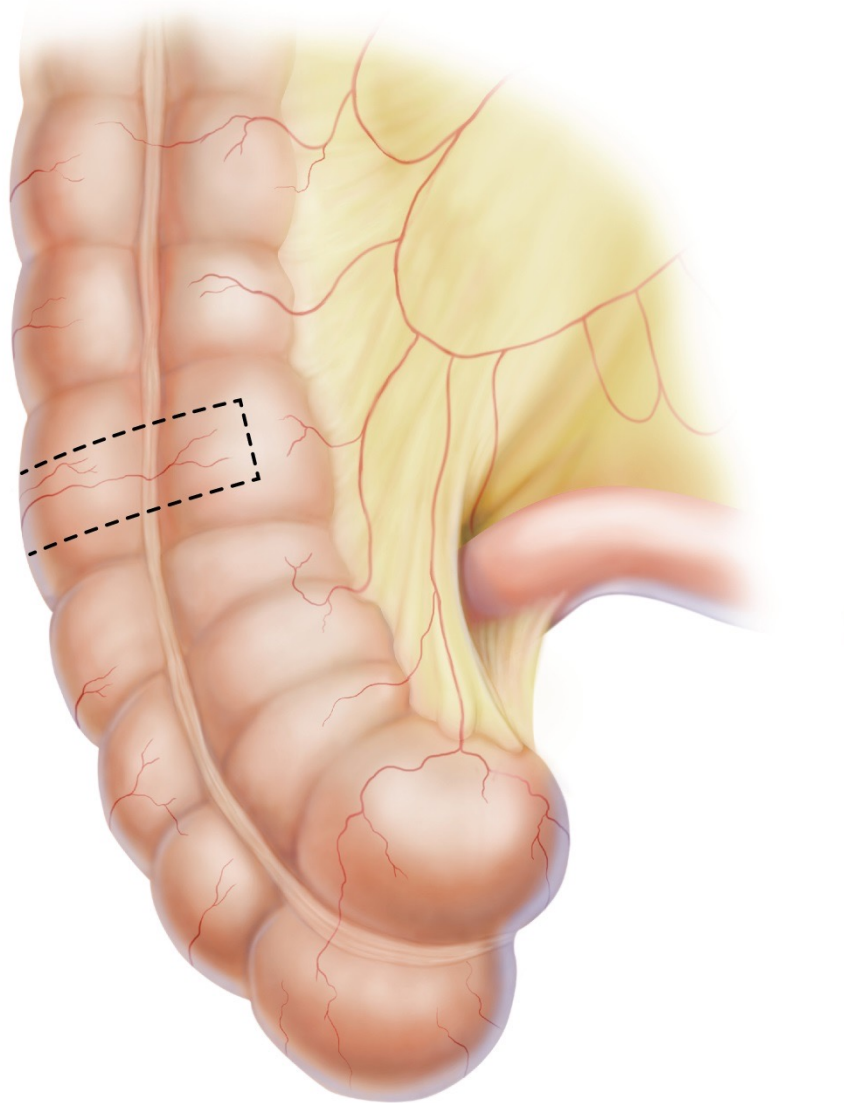






INTERNATIONAL CENTER FOR  
**COLORECTAL AND  
UROGENITAL CARE**

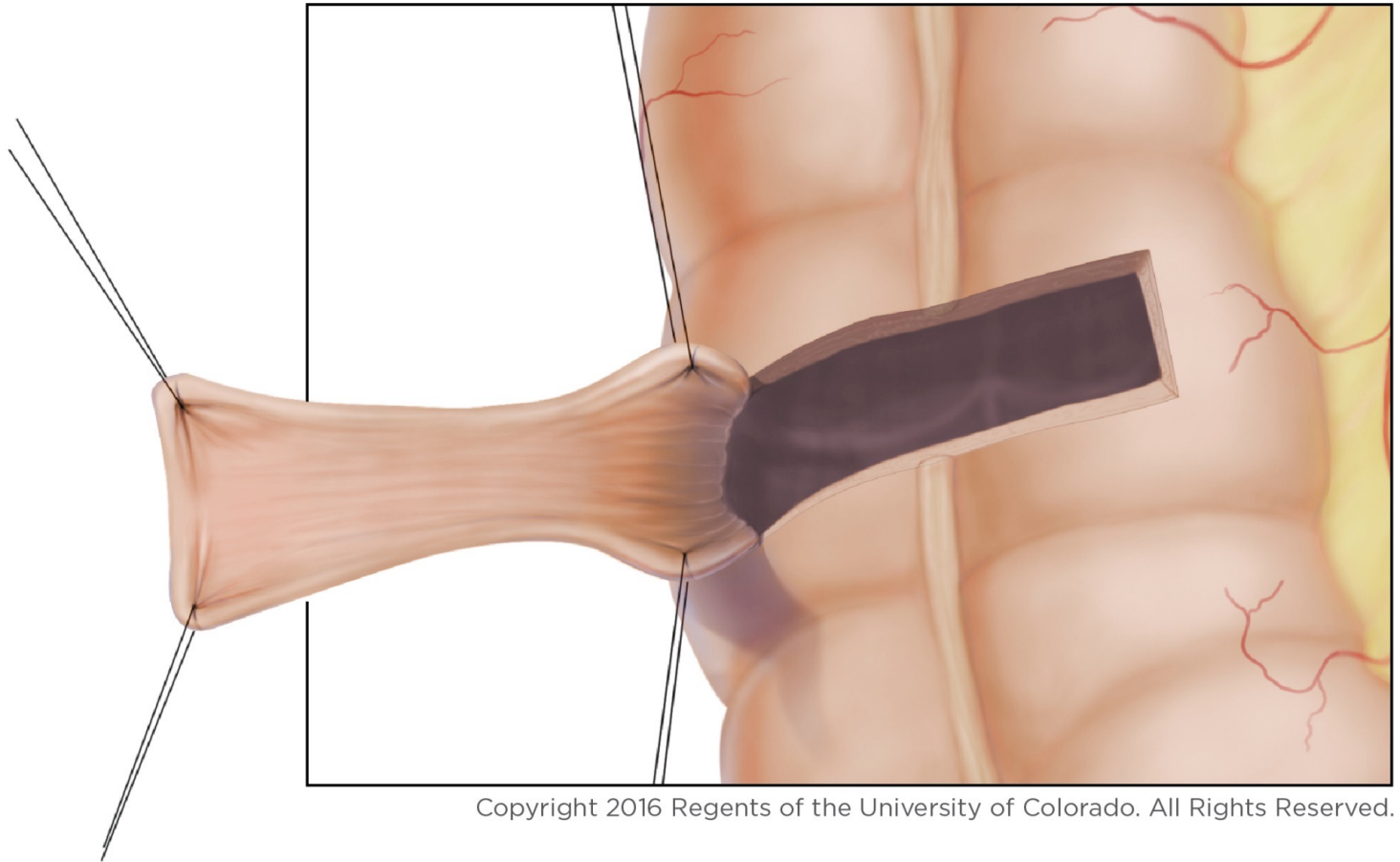




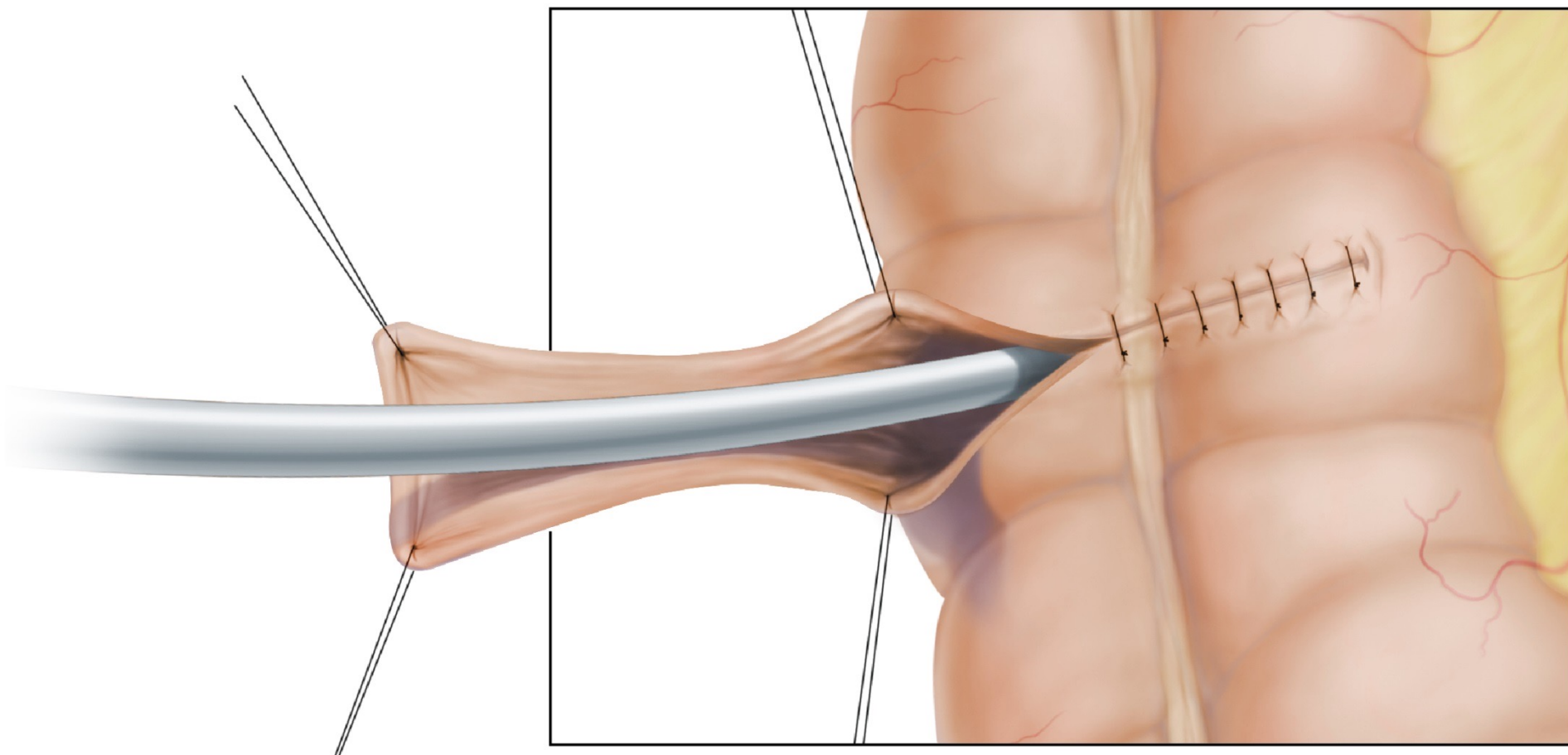
Copyright 2016 Regents of the University  
of Colorado. All Rights Reserved.

ONAL CENTER FOR  
**SPECTAL AND**  
**MENTAL CARE**

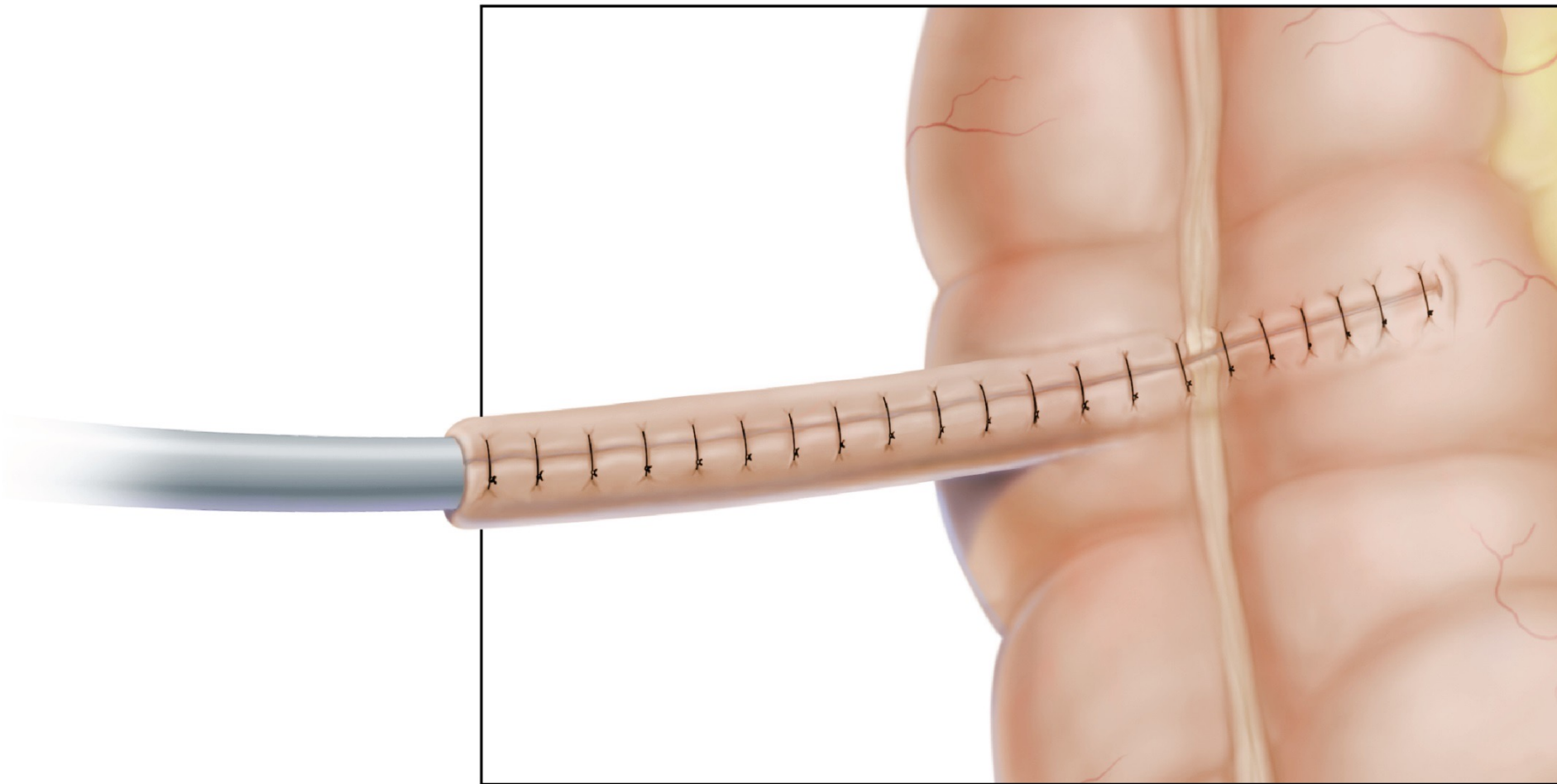




Copyright 2016 Regents of the University of Colorado. All Rights Reserved.

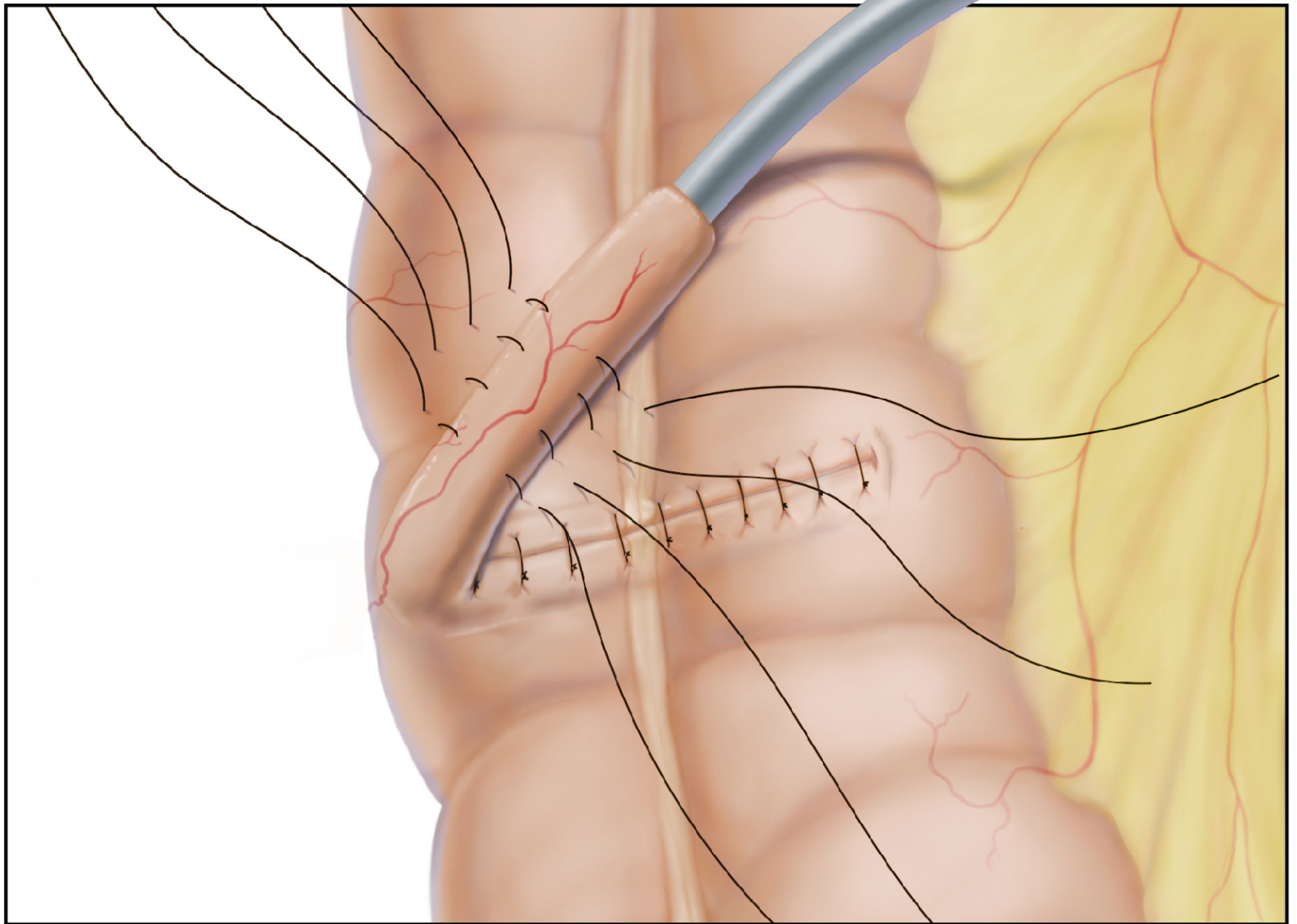


Copyright 2016 Regents of the University of Colorado. All Rights Reserved.

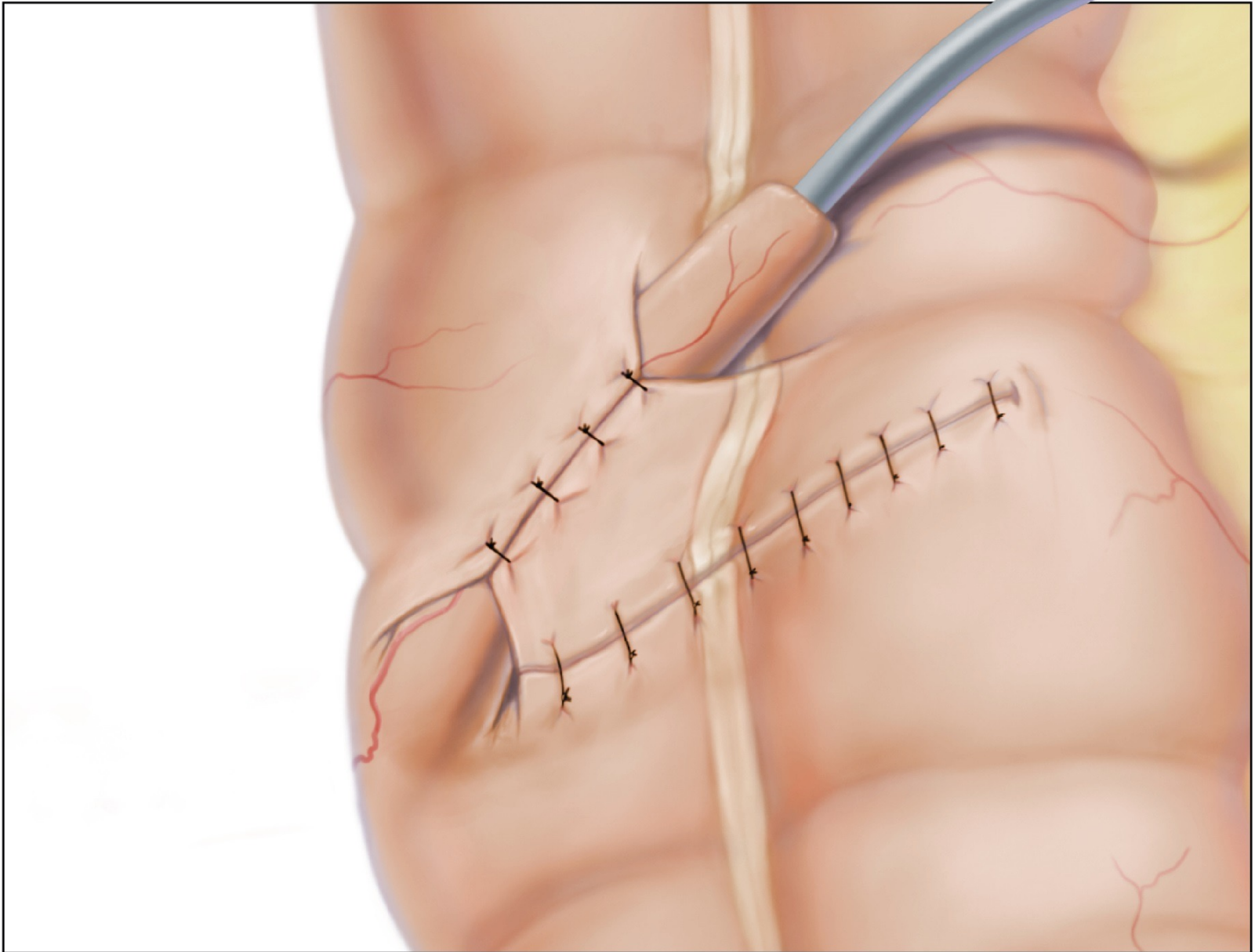


Copyright 2016 Regents of the University of Colorado. All Rights Reserved.

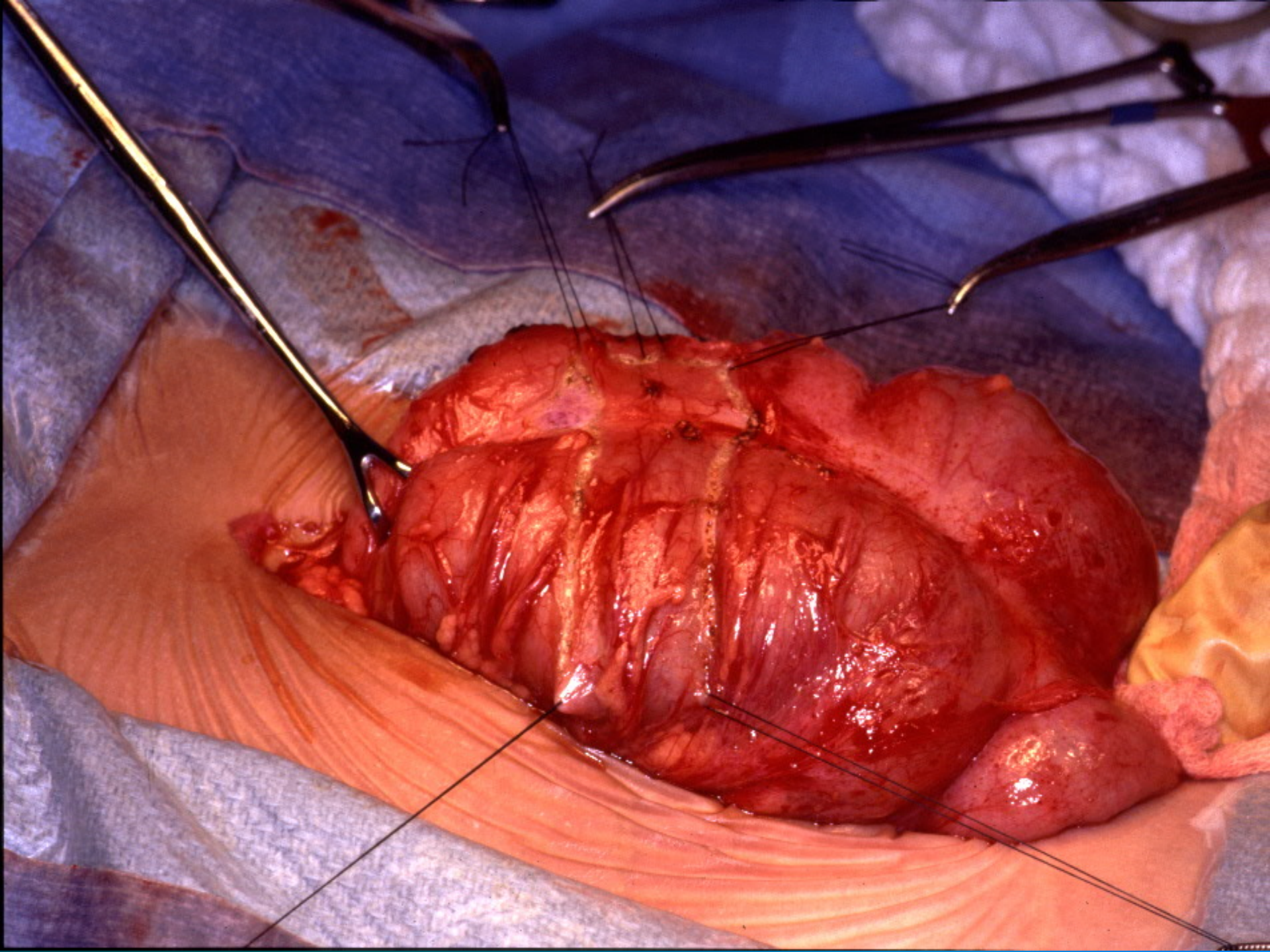




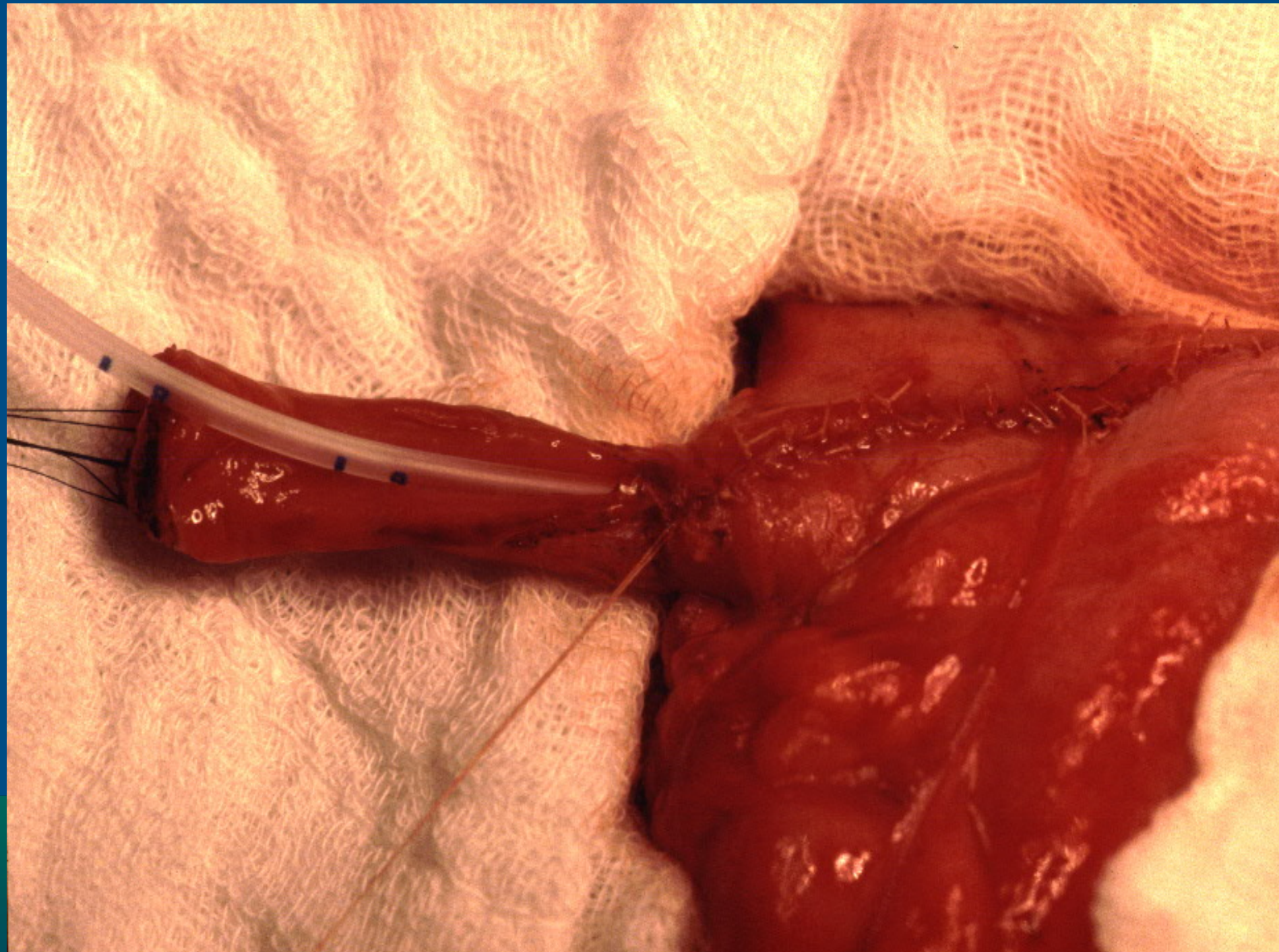
Copyright 2016 Regents of the University of Colorado. All Rights Reserved.



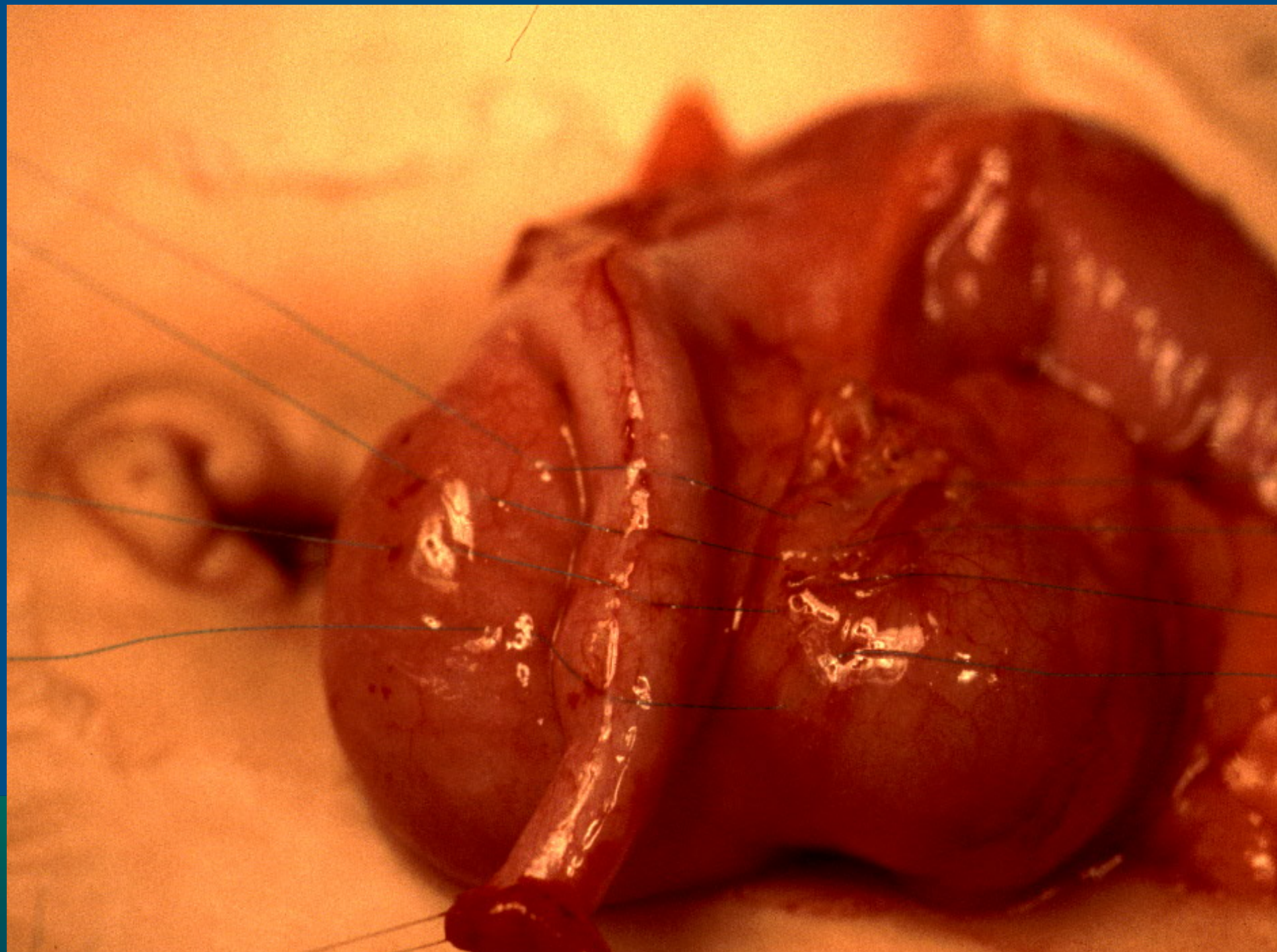




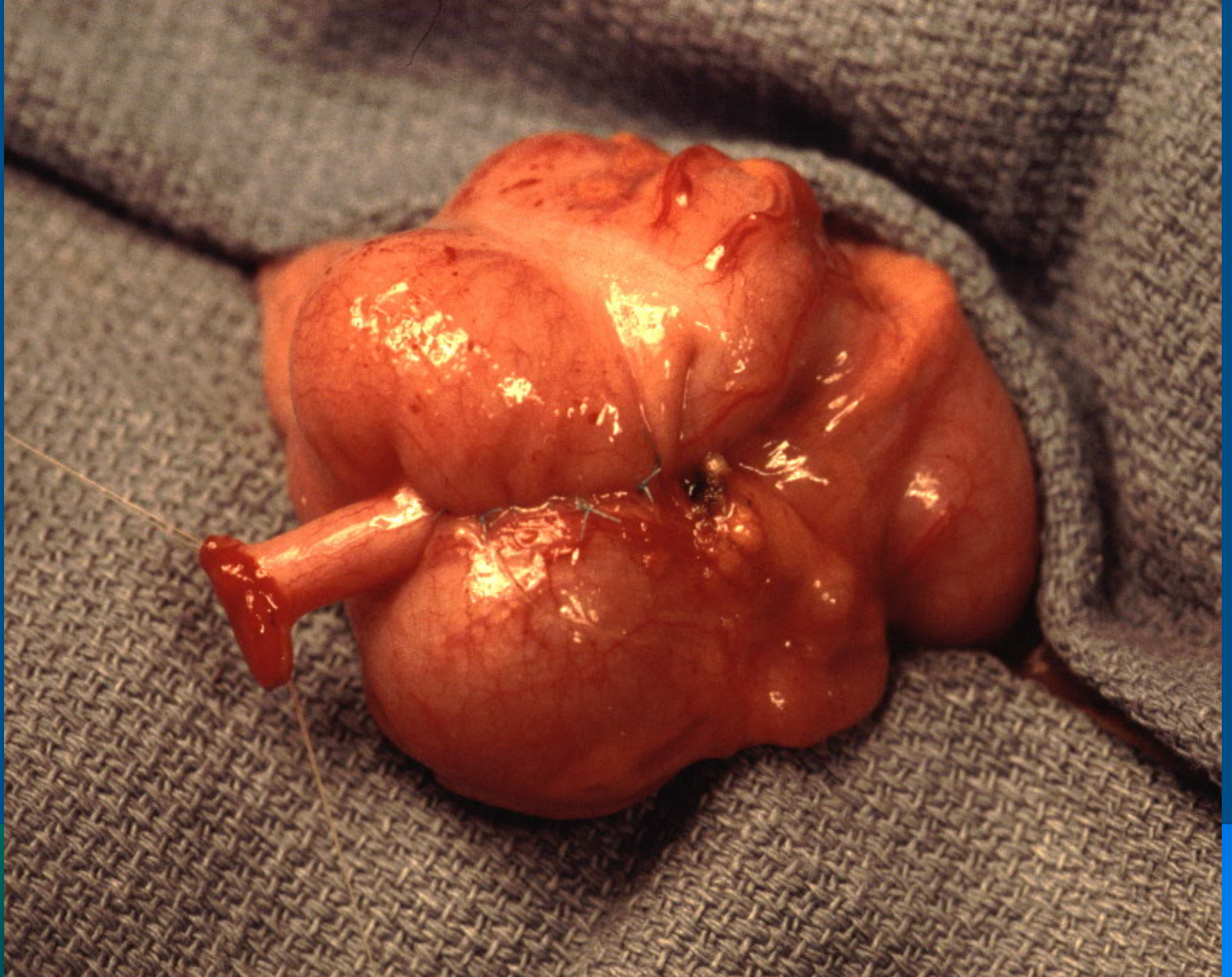















# Thank you!