

Unrepaired Imperforate Anus in a 9-Year-Old Child with Down Syndrome



Sani Yamout MD
Pediatric Surgeon
Kaiser Permanente
Oakland, CA

Case History

- 9-year-old born in Philippines (11/28/2008)
- Trisomy 21 with AV canal
- Colostomy at birth (double barrel)
- Abd surgery via RUQ incision at 4 days of life (? Duodenal atresia)
- Moved to USA 2014
- Repair of AV canal in 2015 (LCPH Stanford, CA)
 - Residual pulmonary HTN

Exam

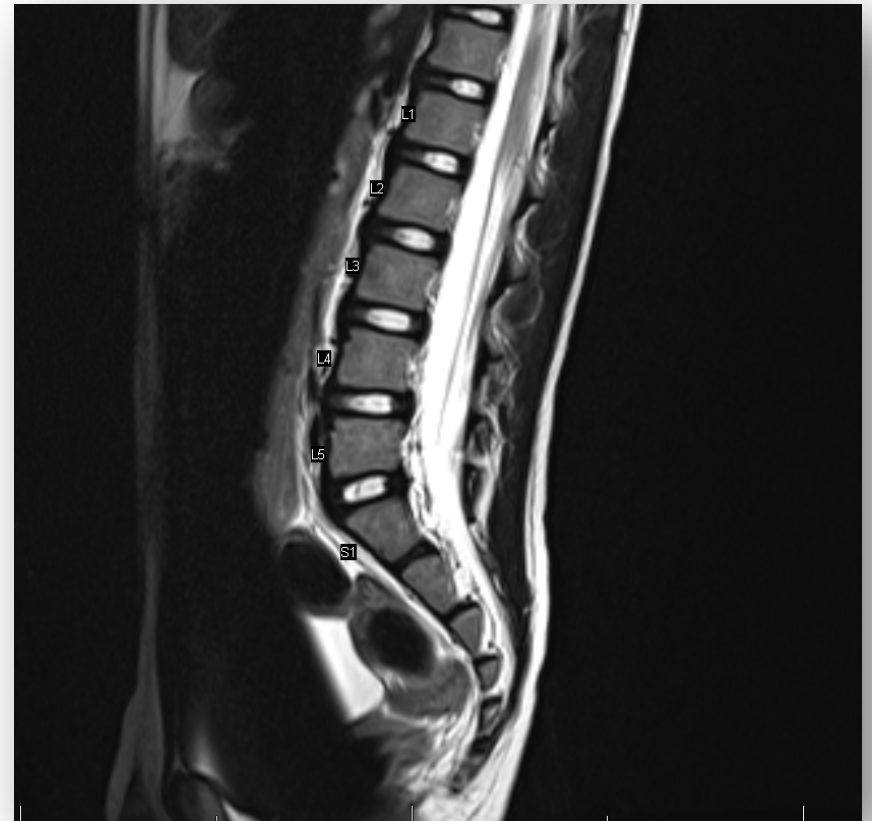
- RUQ incision
- Double barrel colostomy
- Well formed anal dimple with no identifiable fistula in perineum

Workup

- **Echo**
- MRI spine:
 - borderline low conus (L2-L3 level)
 - No segmental abnormalities
- U/S kidney normal
- Colostogram:

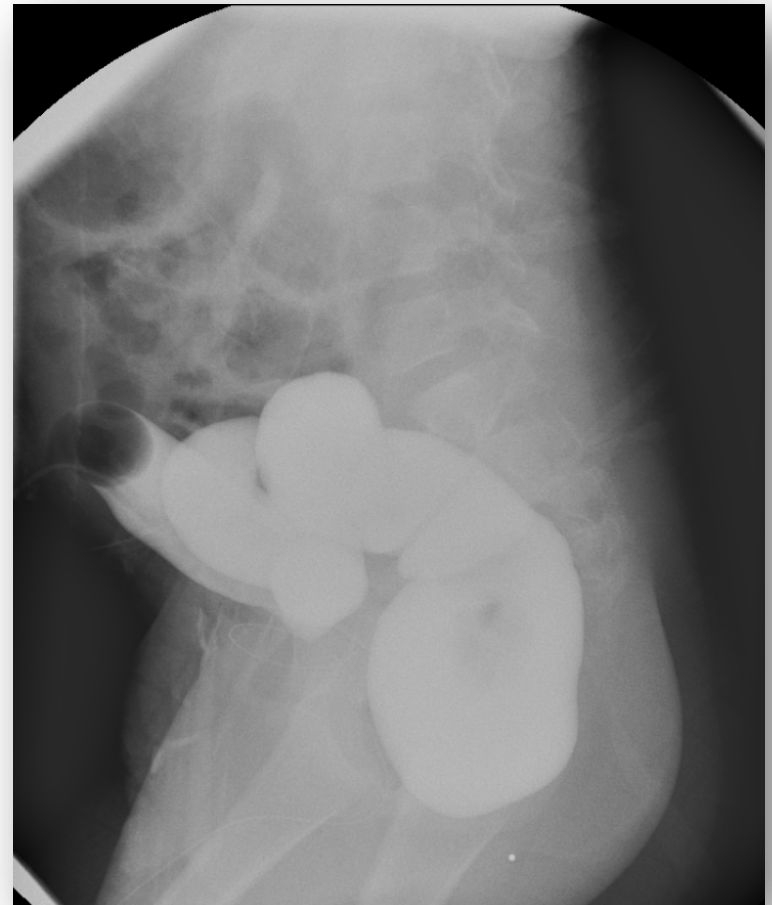
Workup

- Echo
- **MRI spine:**
 - **borderline low conus (L2-L3 level)**
 - **No segmental abnormalities**
- U/S kidney normal
- Colostogram:

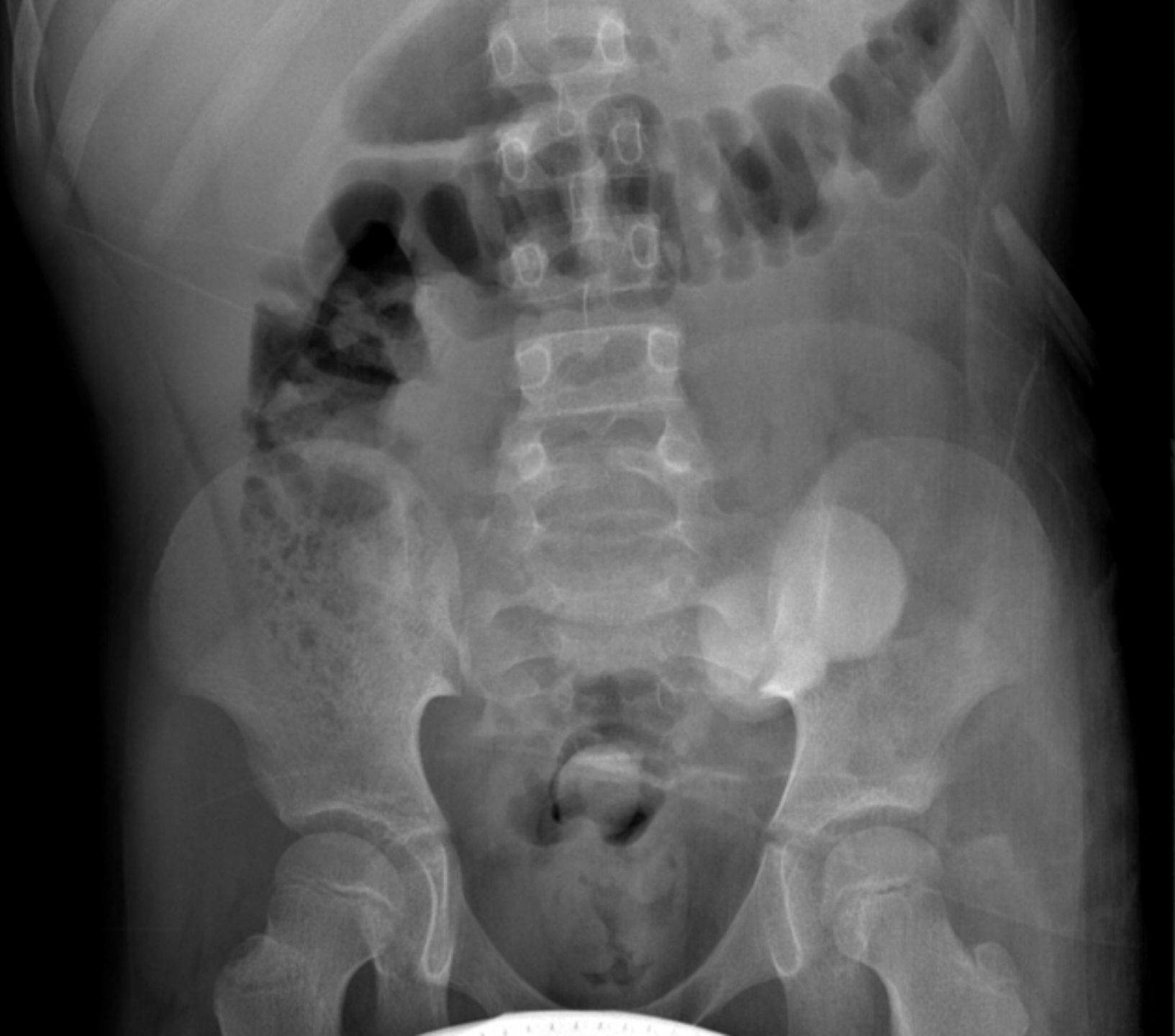

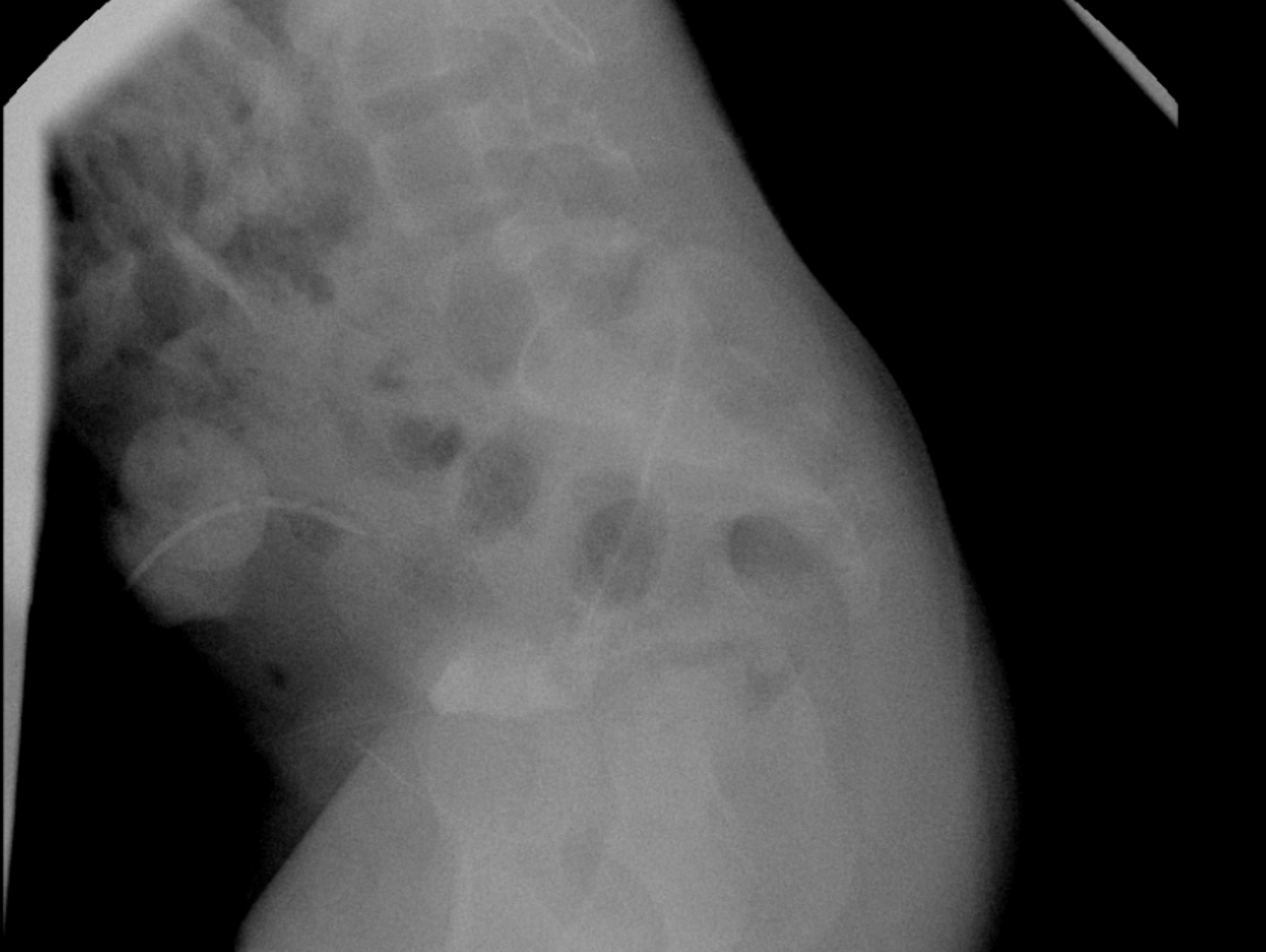
Workup

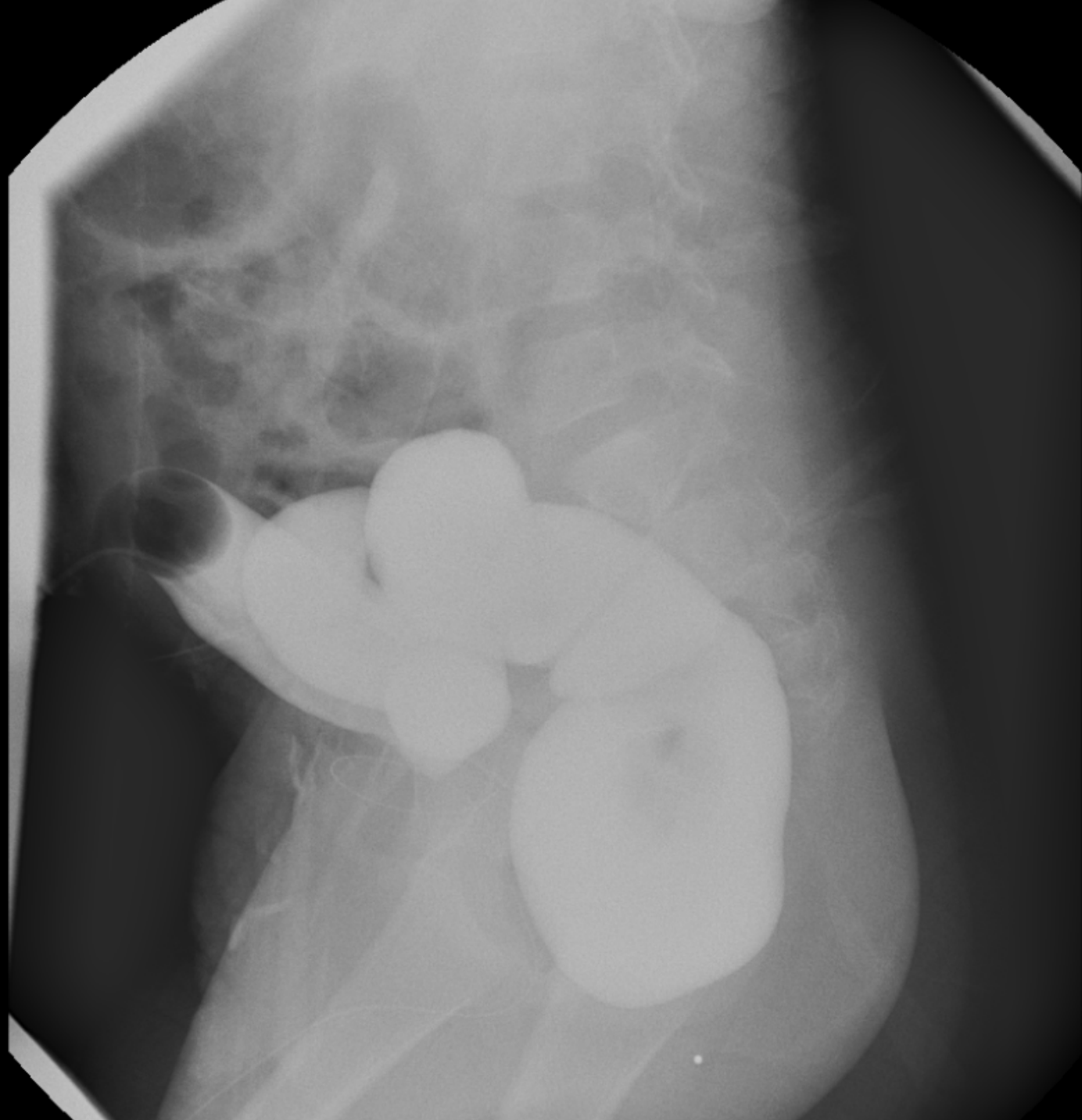
- Echo:
- MRI spine:
 - borderline low conus (L2-L3 level)
 - No segmental abnormalities
- U/S kidney normal
- **Colostogram:**



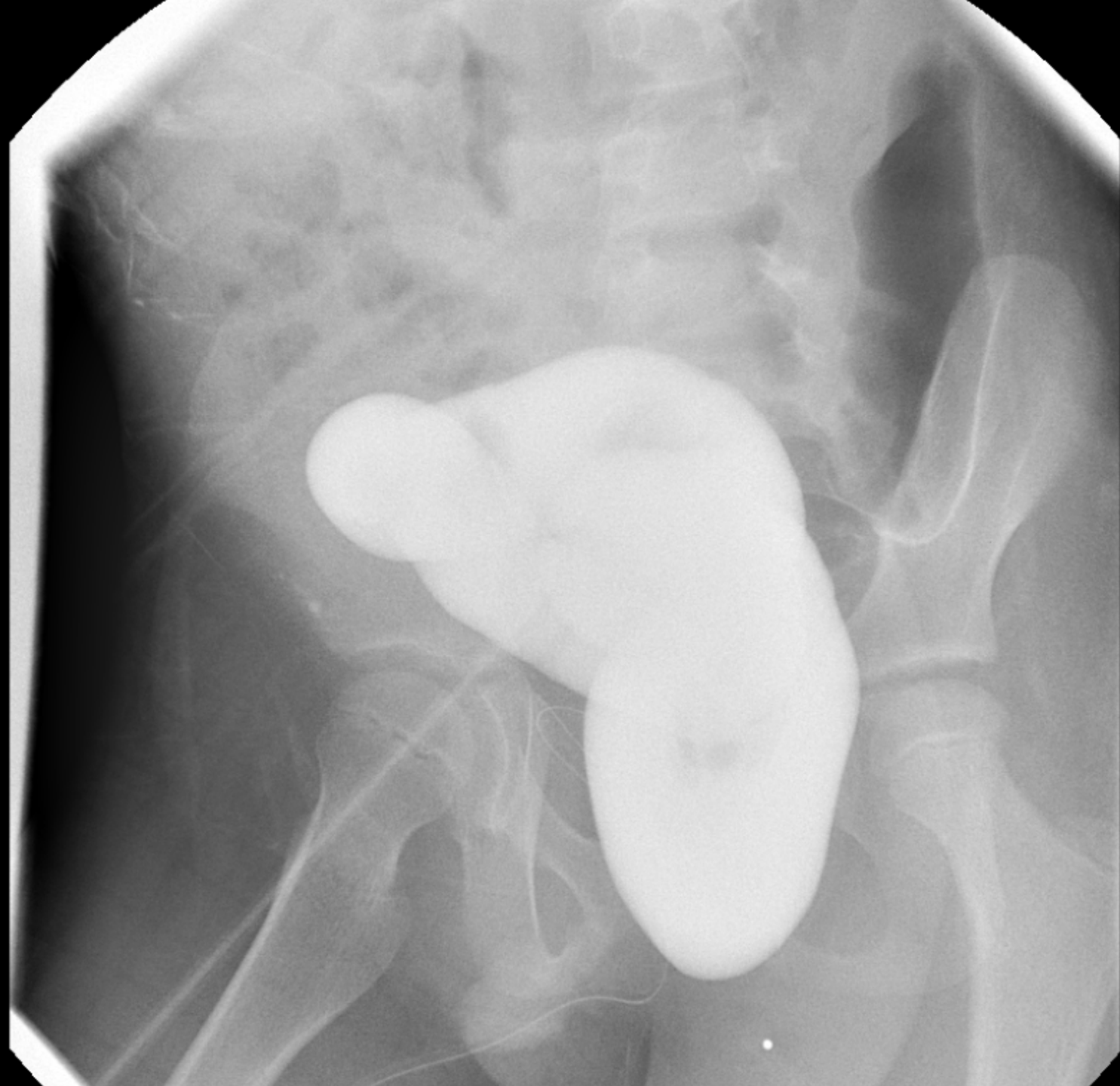R
BAR







H: 30 %



Challenges

- Child with Down Syndrome who will need to learn to be “potty trained” at 9 years of age
- Risk/Benefit discussion
 - Higher operative risk due to cardiac condition and pulmonary HTN
 - Unclear potential for continence

Treatment Options

- Do nothing
 - Colostomy functioning well
 - Colostomy simple to take care
- PSARP and repair of true imperforate anus
 - Higher risk patient
 - What is potential for continence?
 - If incontinent and needs to be made artificially clean, what is better having a colostomy or needing ante-grade enemas to be administered by parents possibly for life

Questions

- Would anyone strongly recommend doing nothing?
- Would anyone taper the rectum at the time of repair