

Case # 4

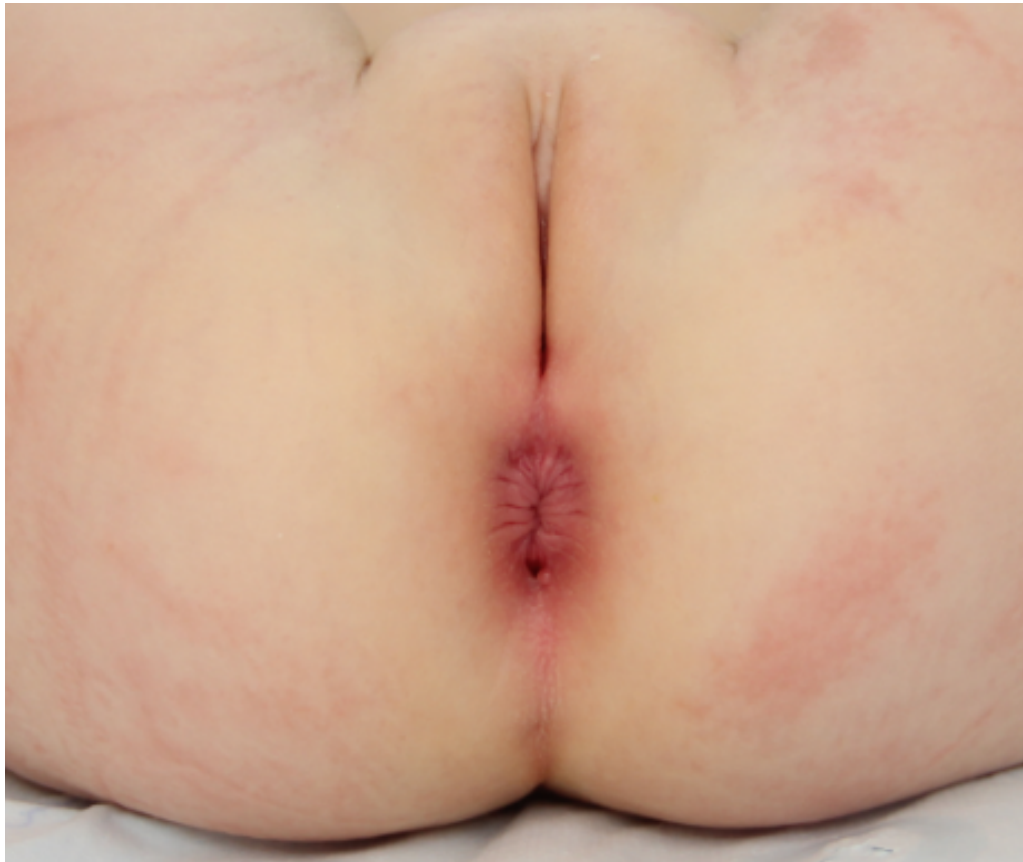08/22/2018



Children's Hospital Colorado

INTERNATIONAL CENTER FOR
**COLORECTAL AND
UROGENITAL CARE**

2 yo female patient



What is your diagnosis?

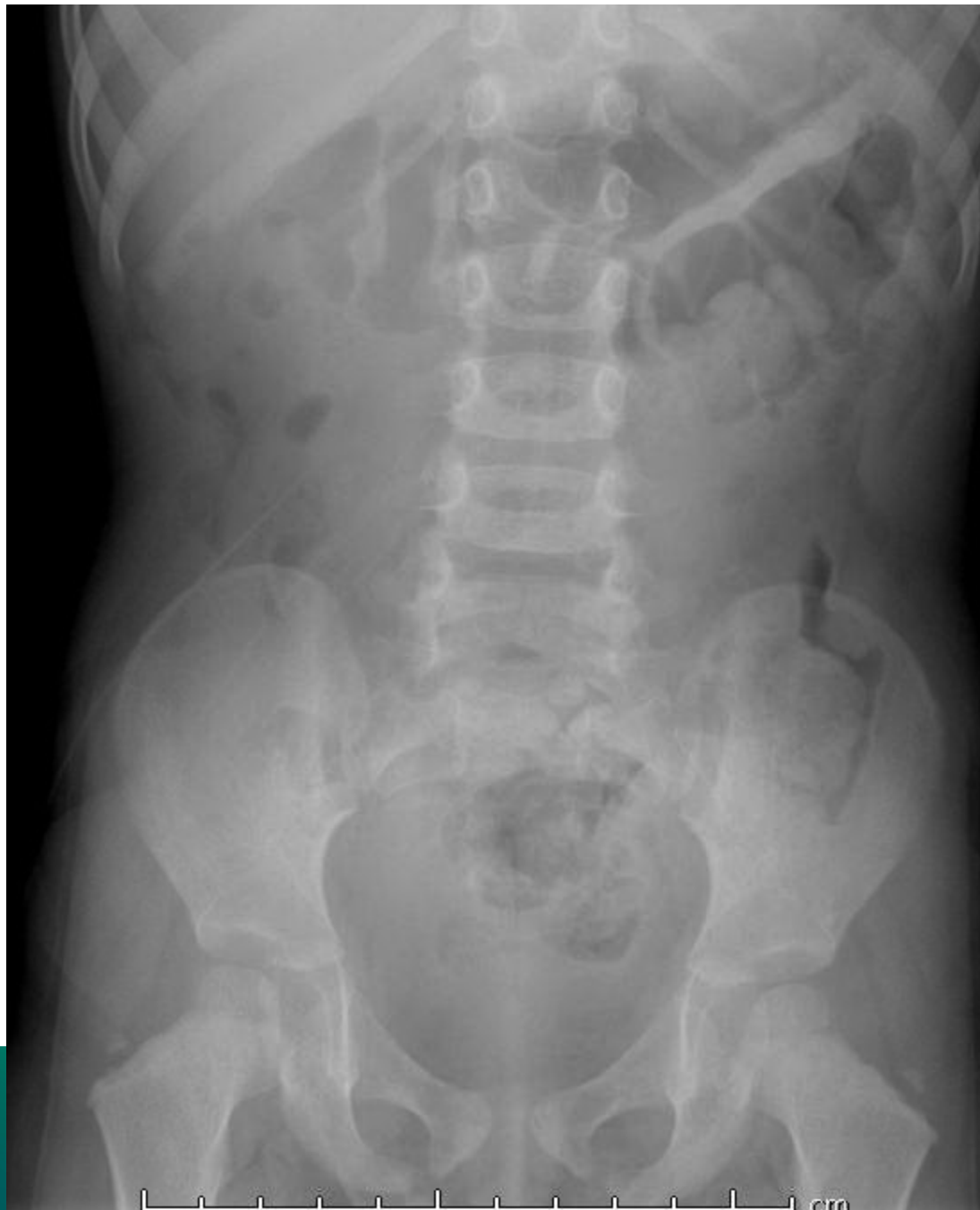

1. Recto-perineal fistula
2. Anal duplication
3. Rectal duplication
4. I don't know

Which studies would you like to order?



1. Sacral X-ray AP
2. Pelvic and spinal MRI
3. Contrast study
4. More than one option
5. I don't know



IONAL CENTER FOR
RECTAL AND
INITIAL CARE

MRI



- No tethered cord
- No presacral mass

What would you do?



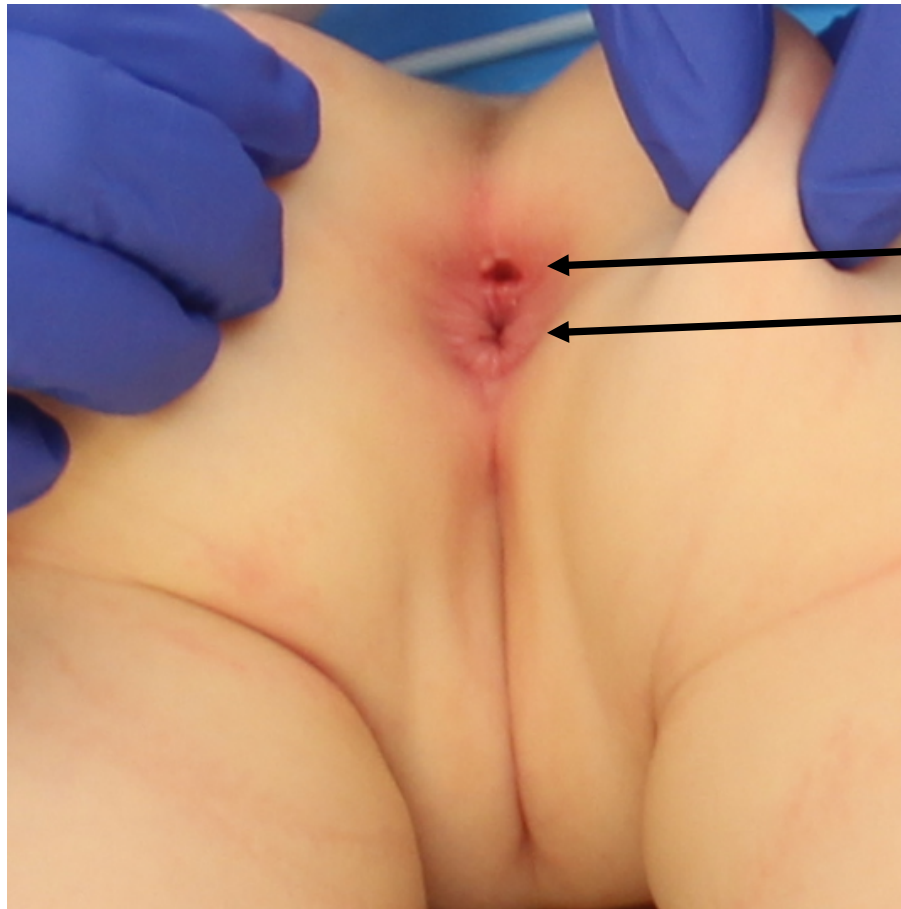
1. Nothing, conservative management
2. Offer a resection

Would you do a bowel prep prior to
the operation?



1. Yes
2. No
3. I don't know

Prone Position



Duplication

Anus



