

Case # 5

08/22/2018



Children's Hospital Colorado

INTERNATIONAL CENTER FOR
**COLORECTAL AND
UROGENITAL CARE**

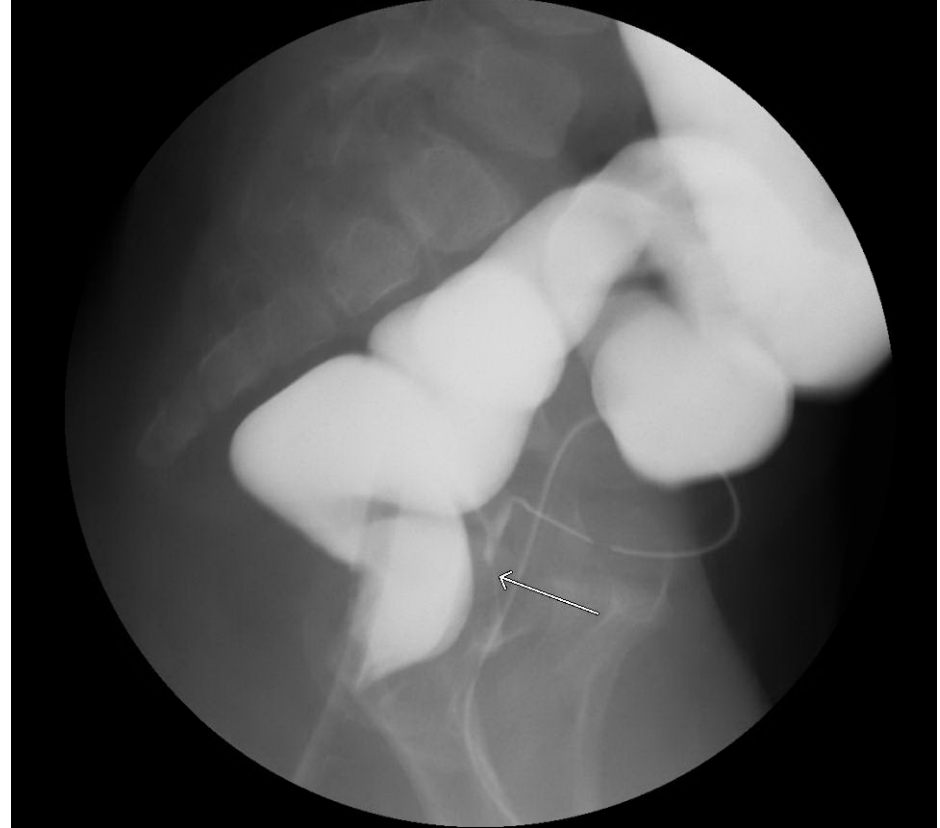
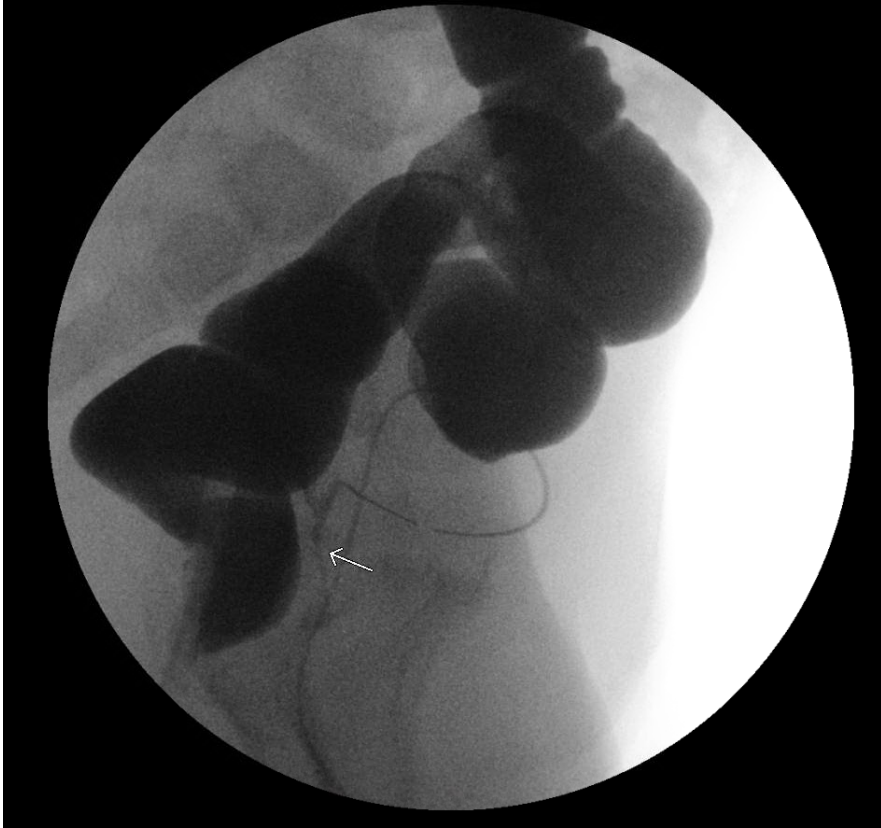


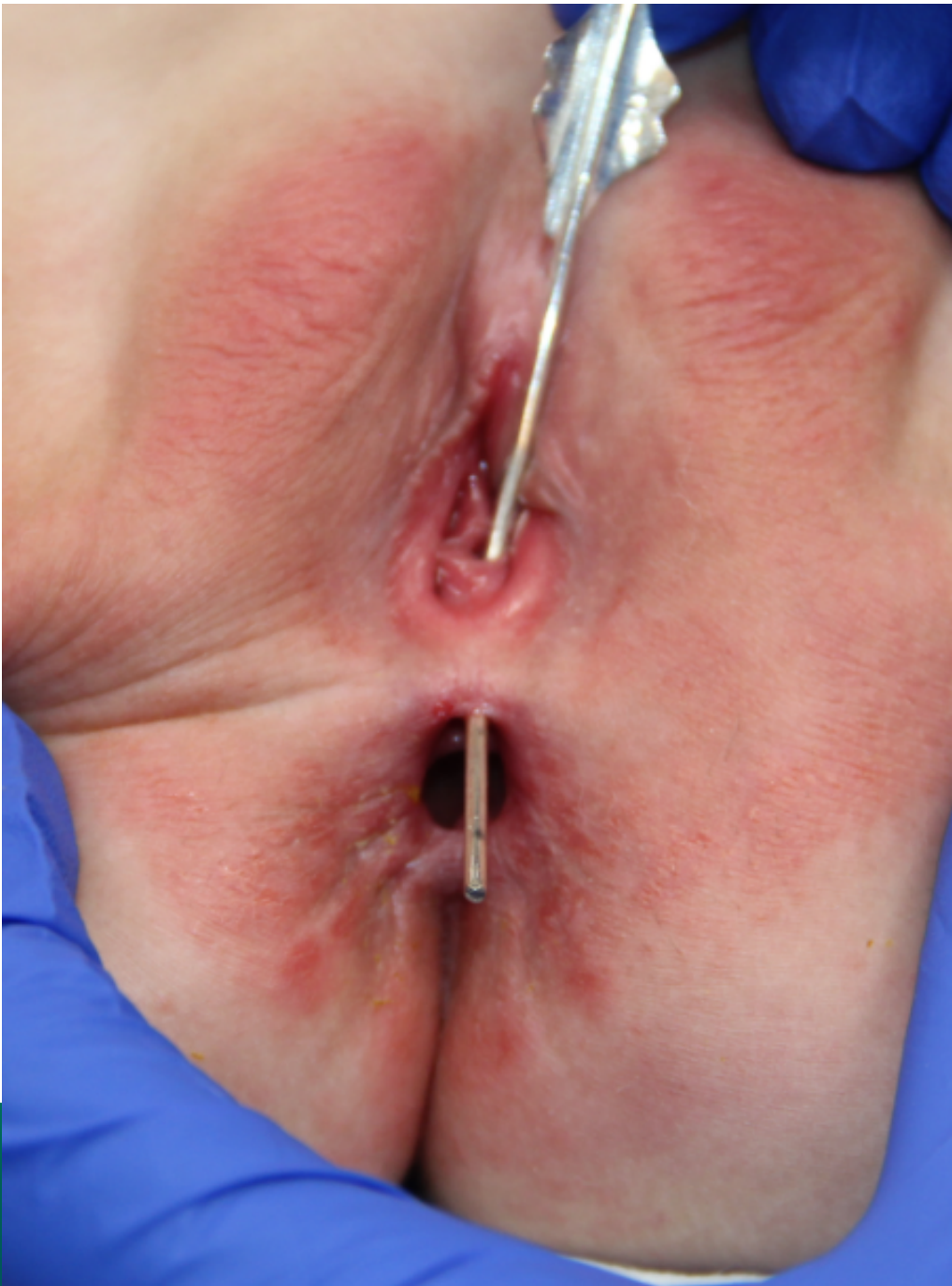
- 1 yo female patient with history of stool coming through the vagina

What would you do?



1. Nothing, the chance of a true recto-vaginal fistula with normal anus is very low
2. Examination under anesthesia
3. Contrast enema
4. Offer an operation
5. I don't know





INTERNATIONAL CENTER FOR
**COLORECTAL AND
UROGENITAL CARE**



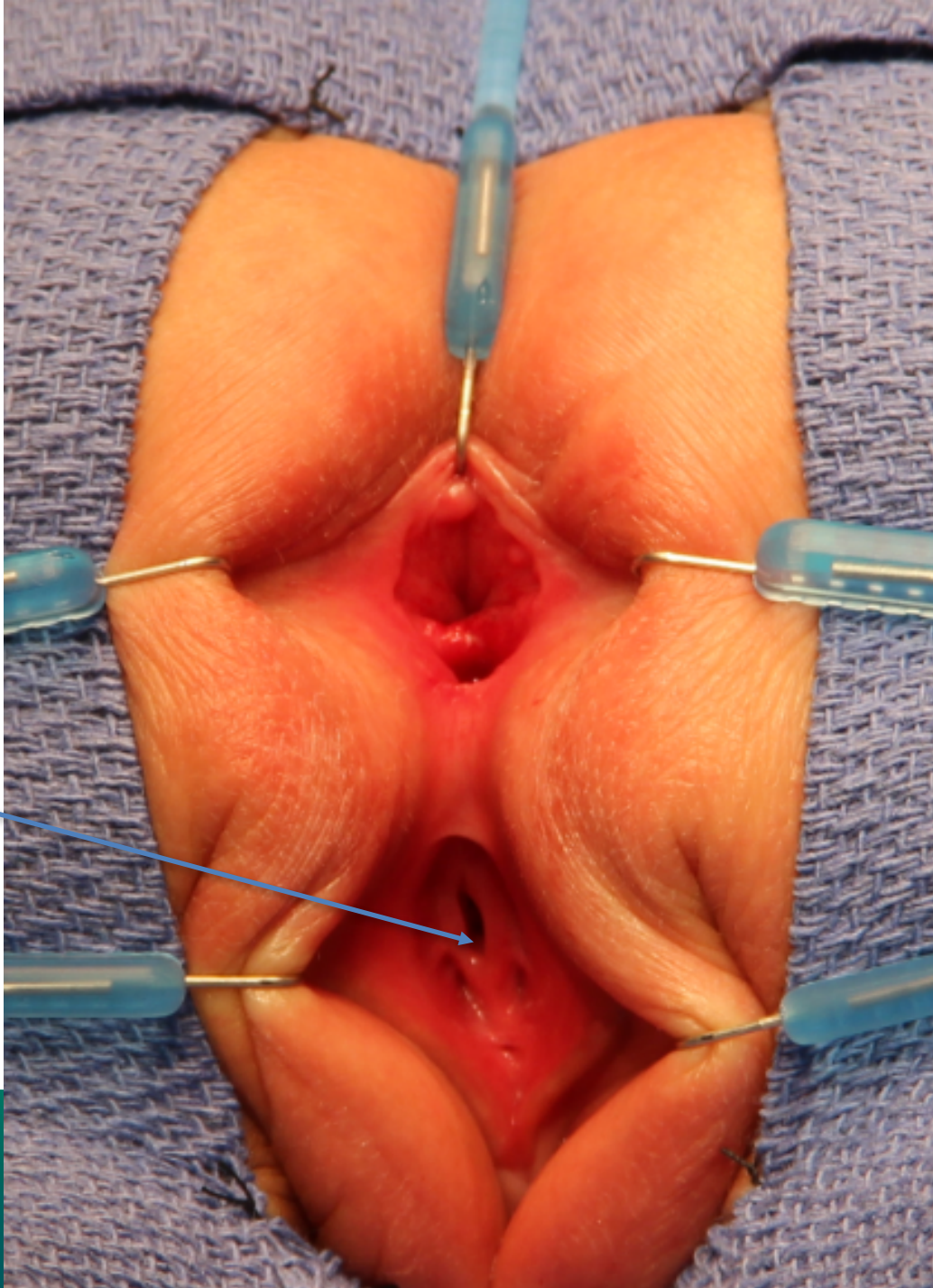
Would you do a colostomy?

1. Yes
2. No

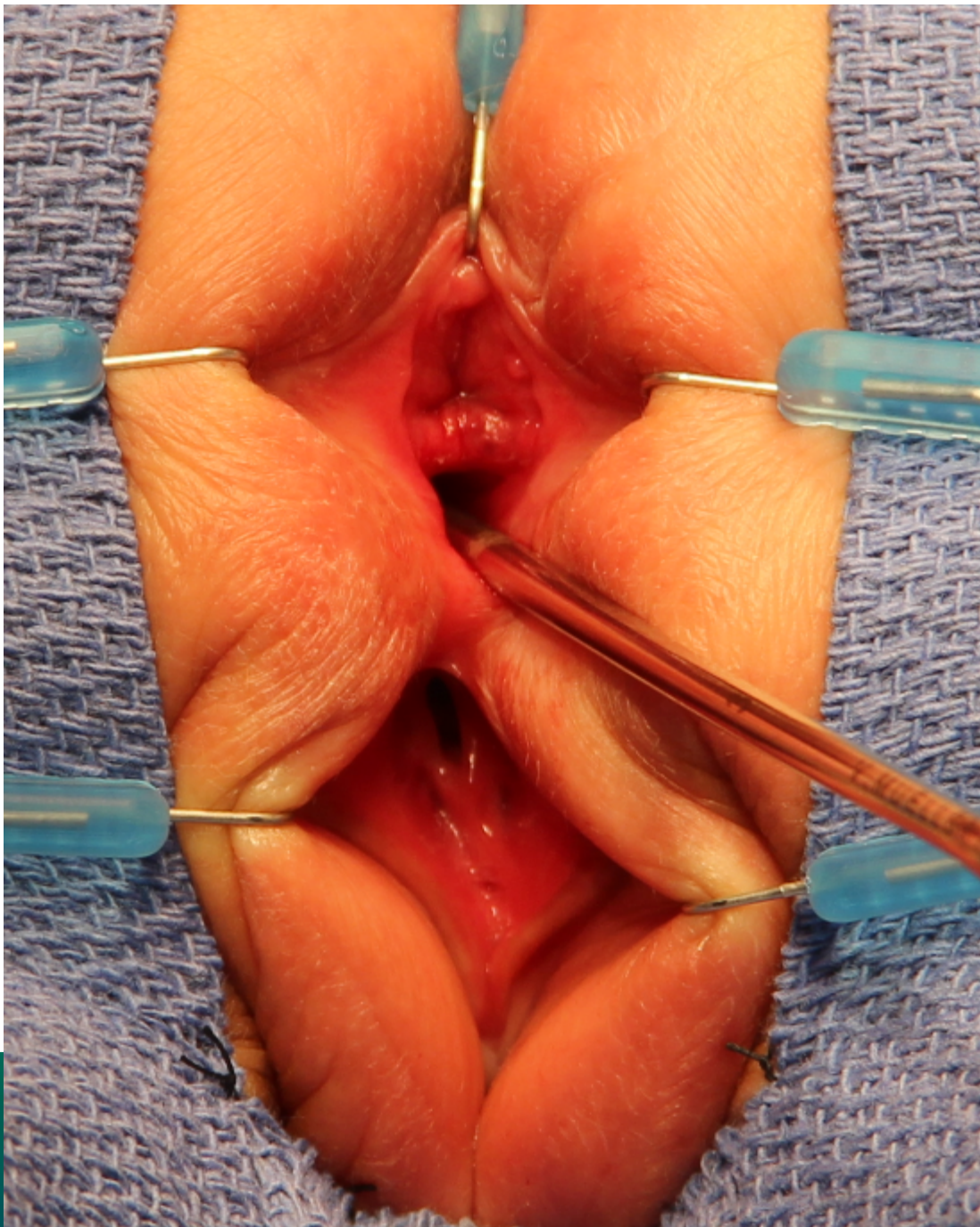
If you don't do a colostomy, would you do a bowel prep in this case?



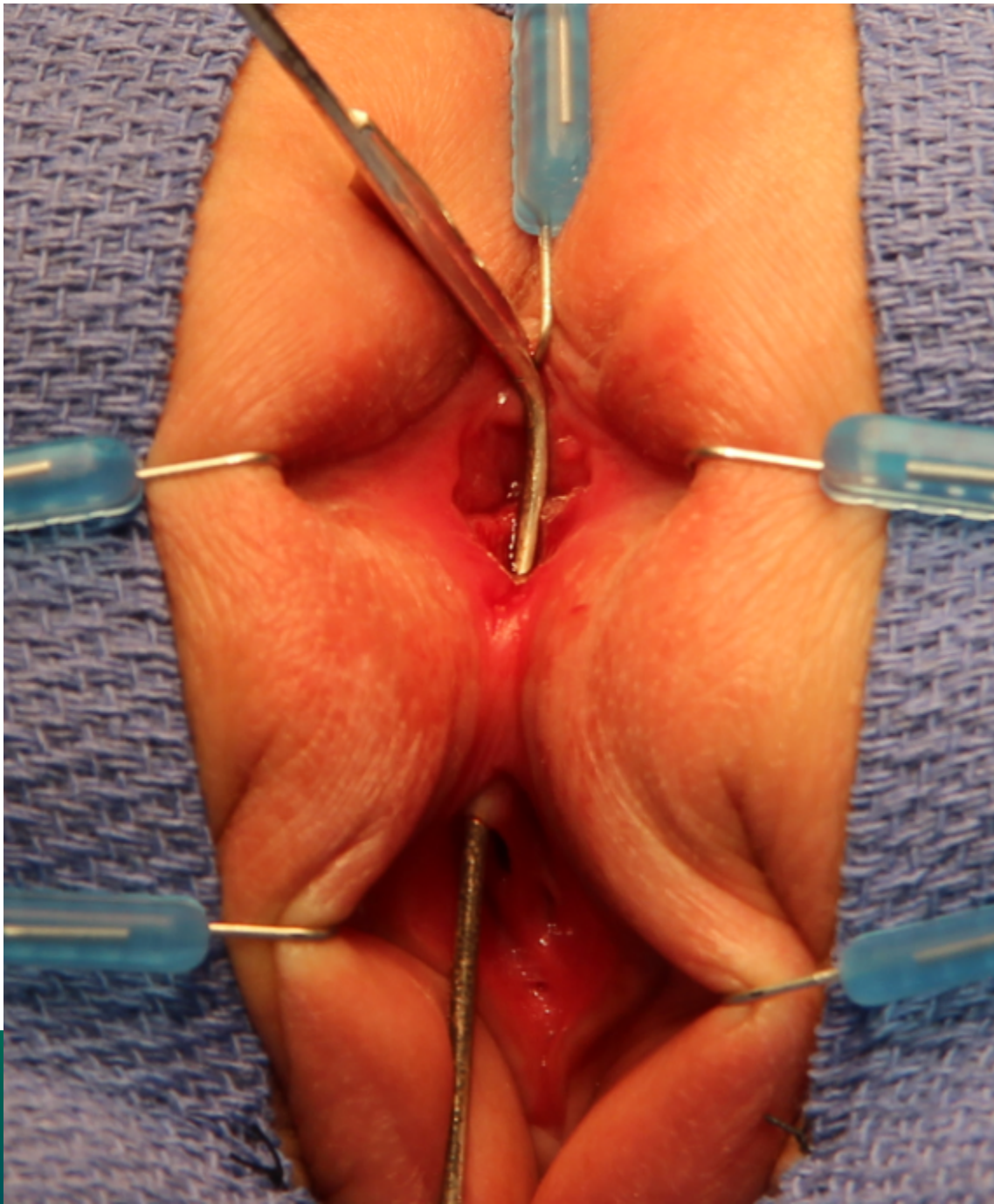
1. Yes
2. No



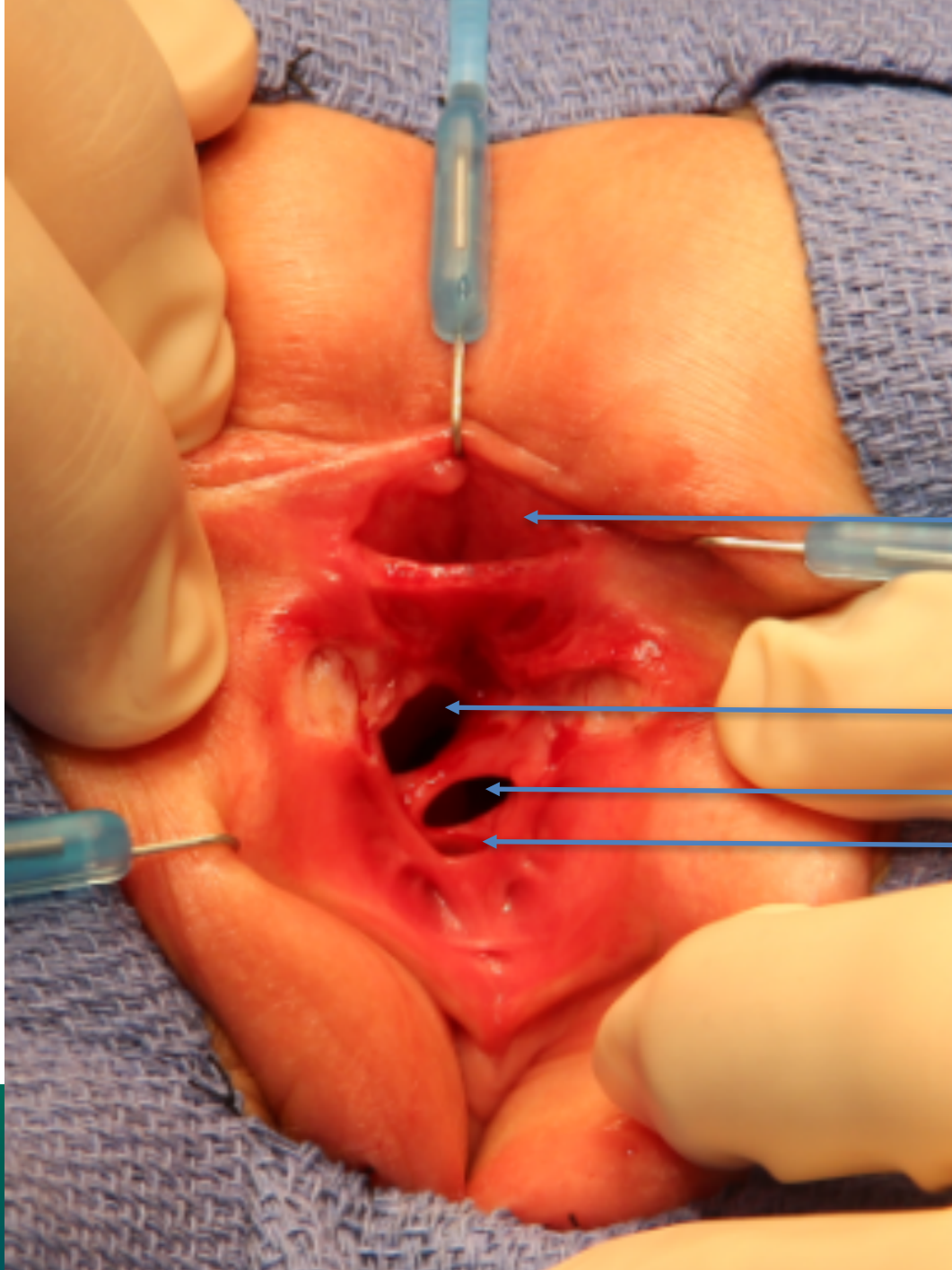
hypospadiac
urethra



INTERNATIONAL CENTER FOR
**COLORECTAL AND
UROGENITAL CARE**



INTERNATIONAL CENTER FOR
**COLORECTAL AND
UROGENITAL CARE**

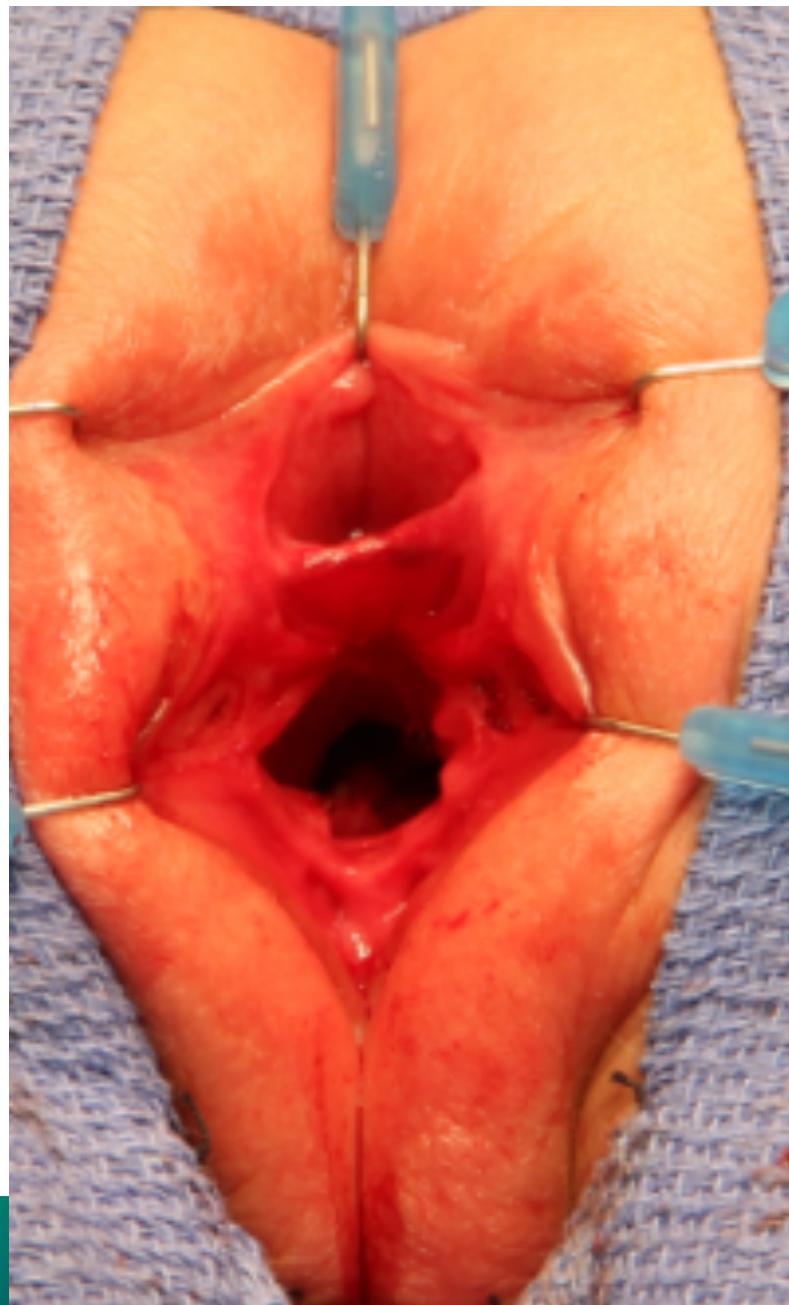


anus

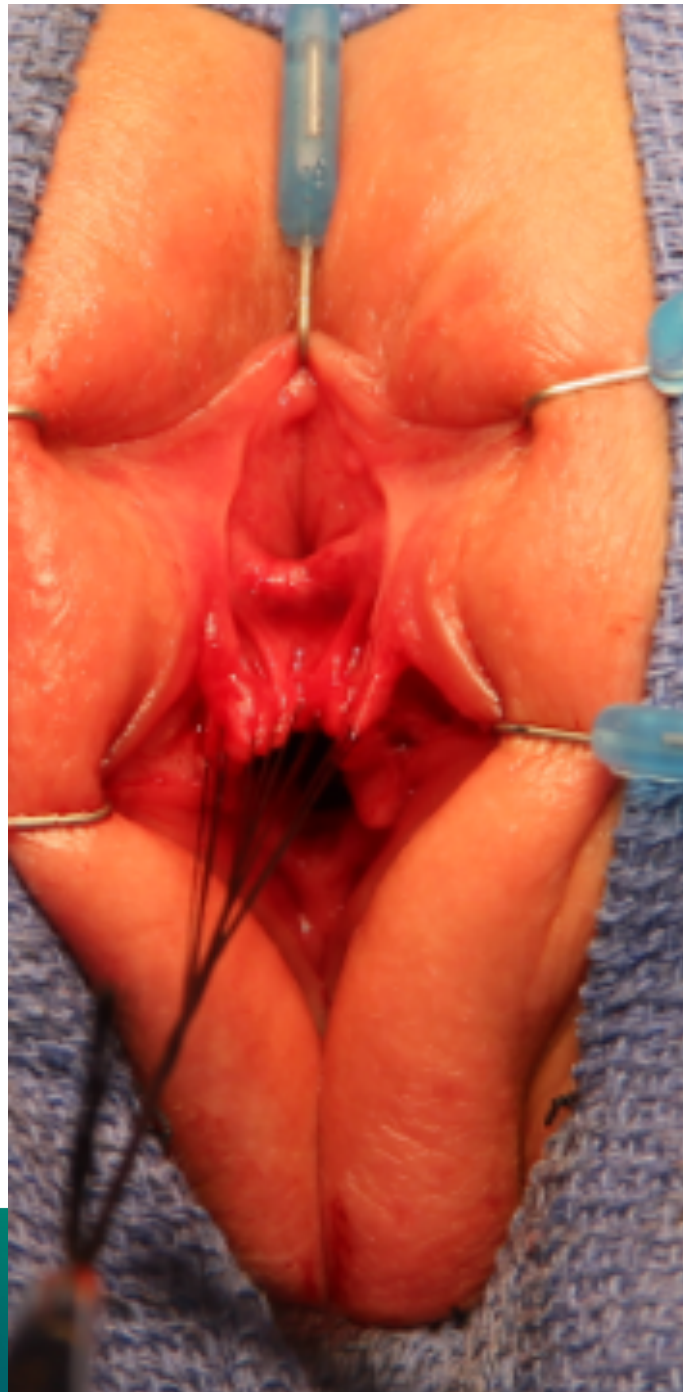
vagina

vagina

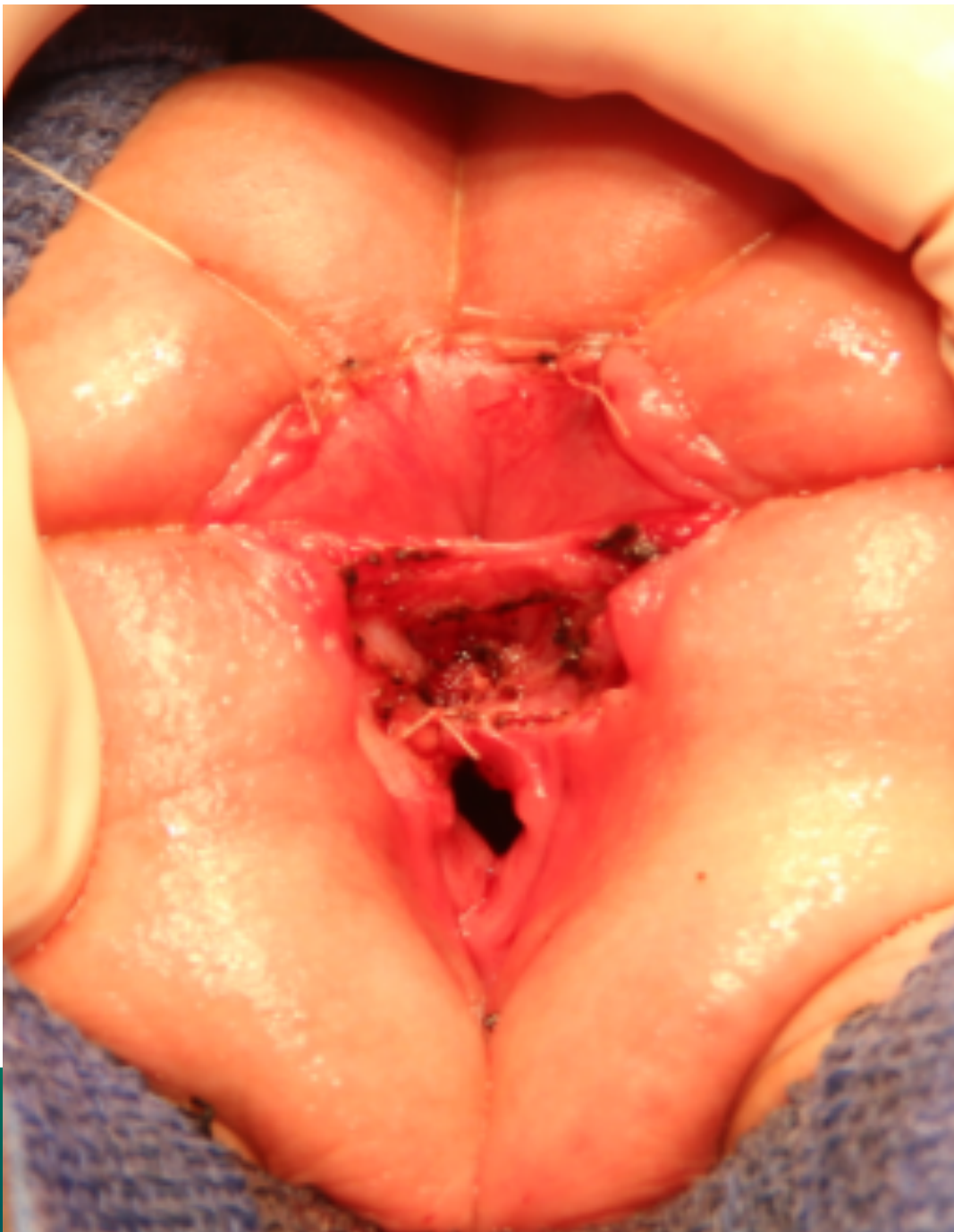
urethra

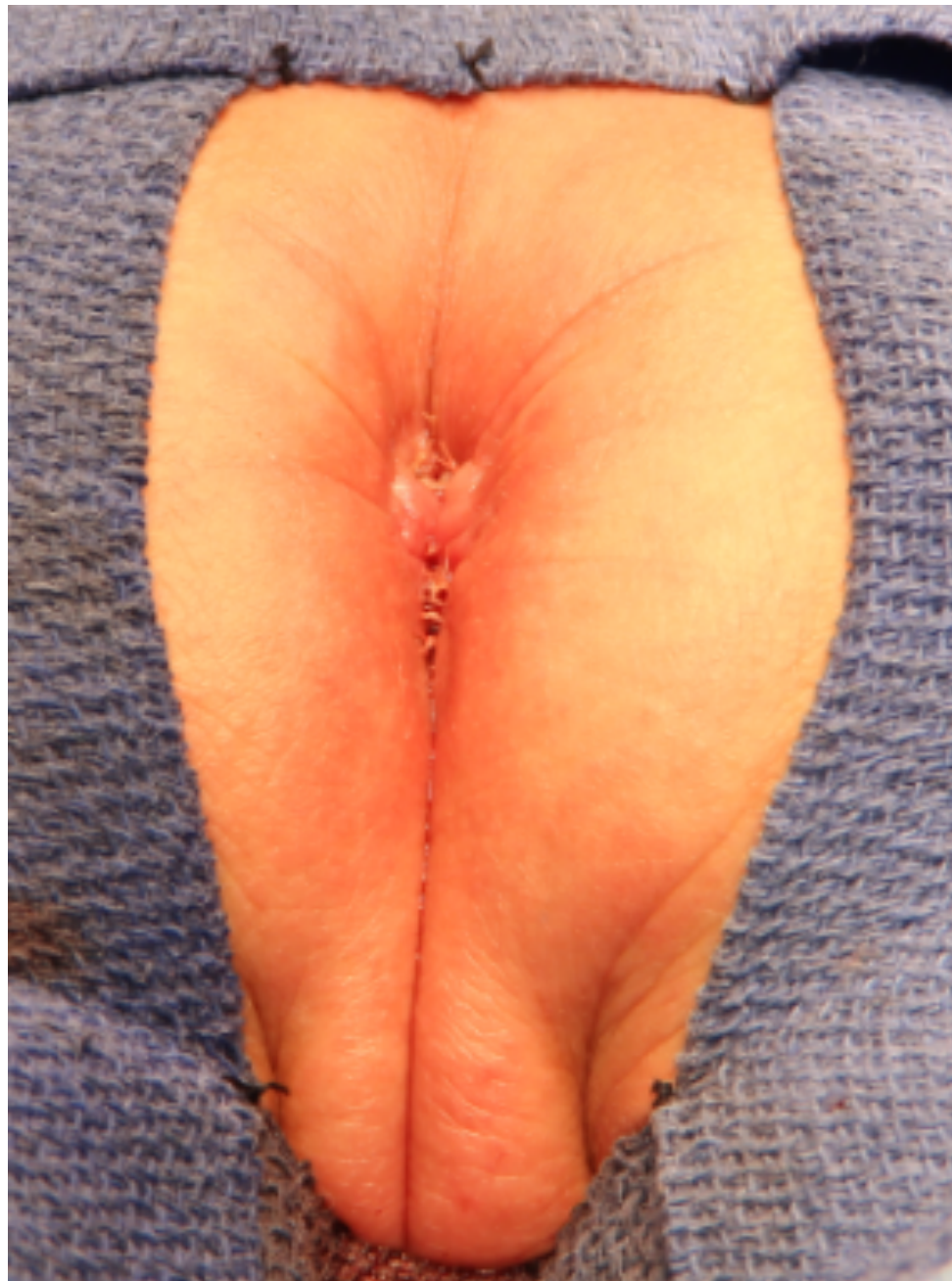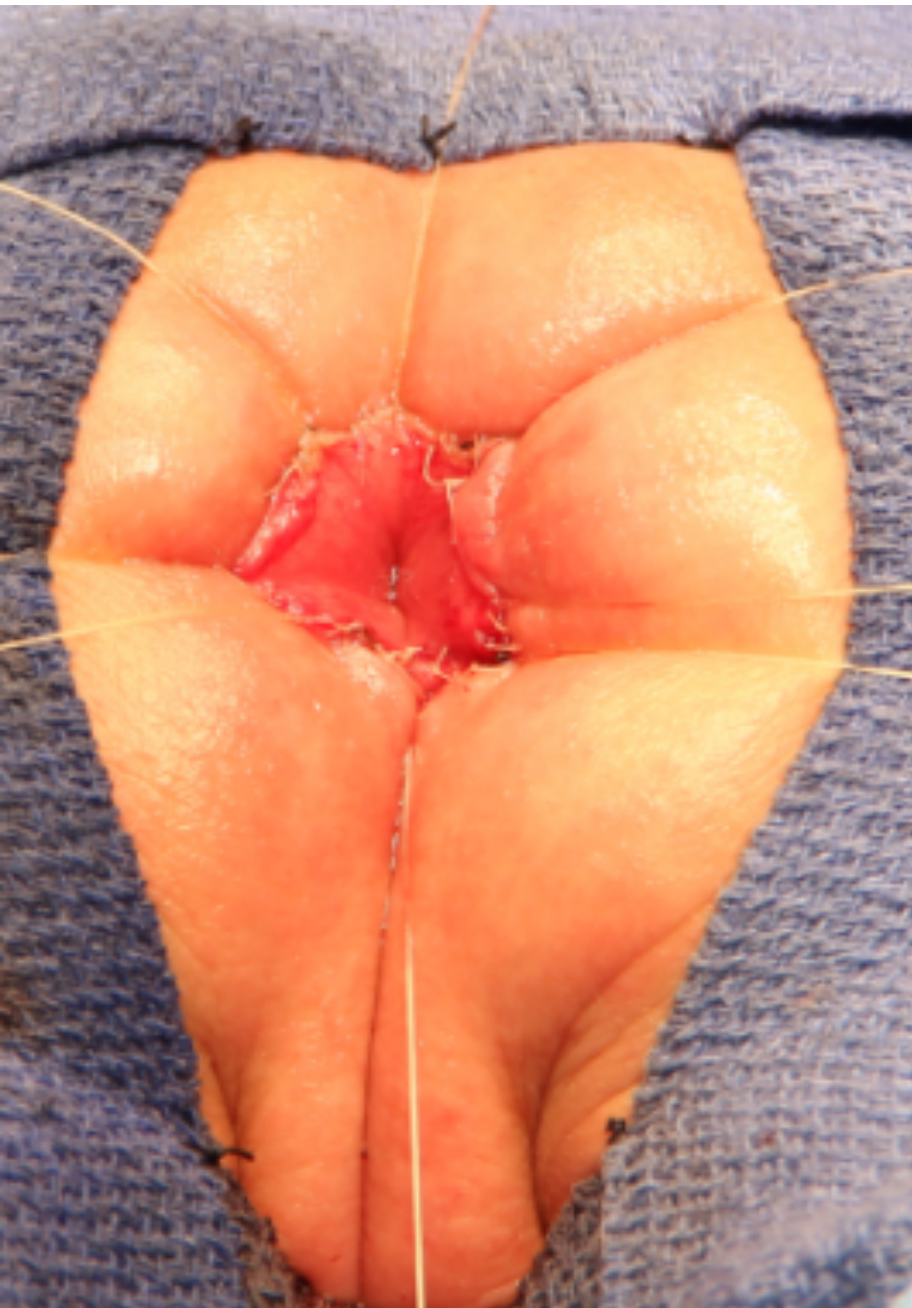


INTERNATIONAL CENTER FOR
**COLORECTAL AND
UROGENITAL CARE**



INTERNATIONAL CENTER FOR
**COLORECTAL AND
UROGENITAL CARE**







Our Next International Colorectal Web Meeting will be on September 20th, 2018

