

# Case # 4

---

01/25/2018

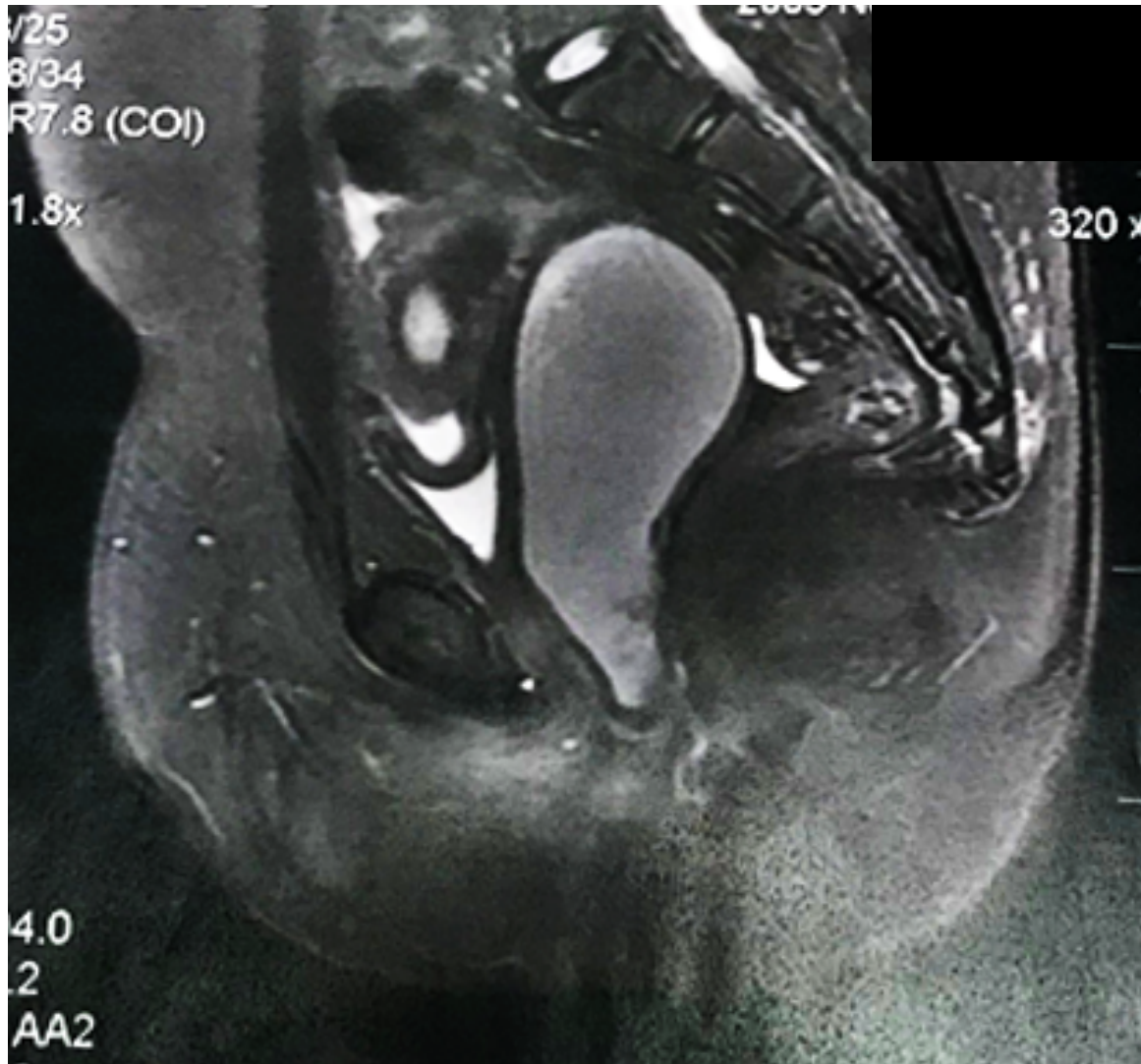


Children's Hospital Colorado

INTERNATIONAL CENTER FOR  
**COLORECTAL AND  
UROGENITAL CARE**



- 11 yo female patient with 2- week history of abdominal pain
- She went to the Emergency Room
- CT scan was ordered to rule out appendicitis



# What is your diagnosis?




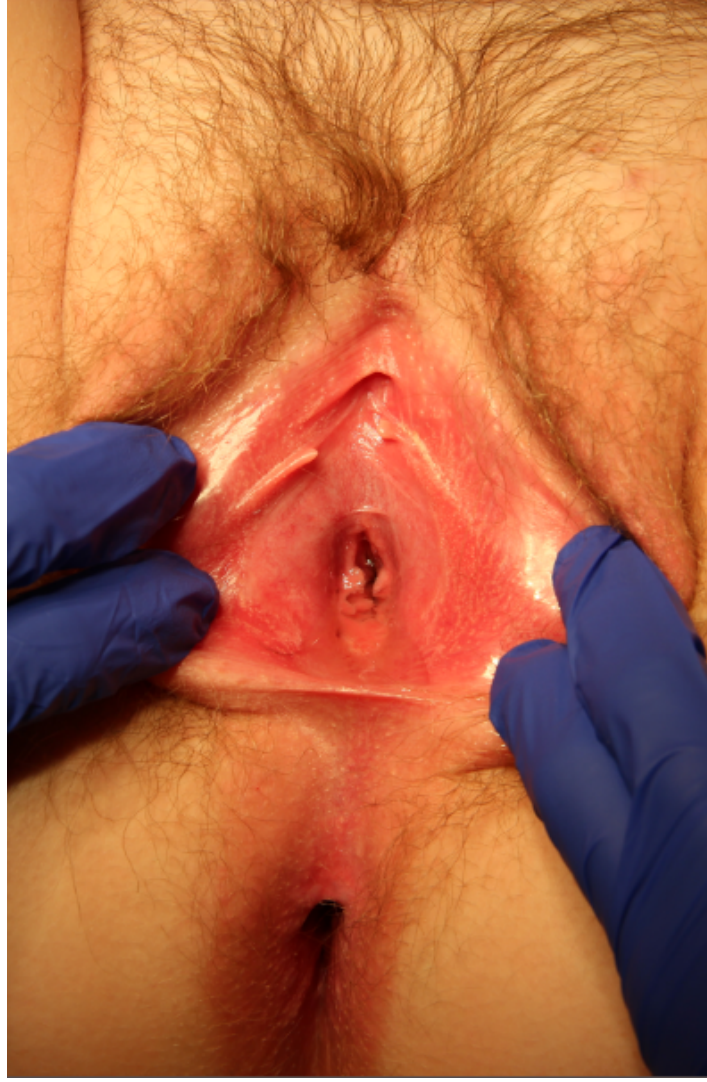1. Imperforate hymen
2. Distal vaginal atresia
3. I don't know

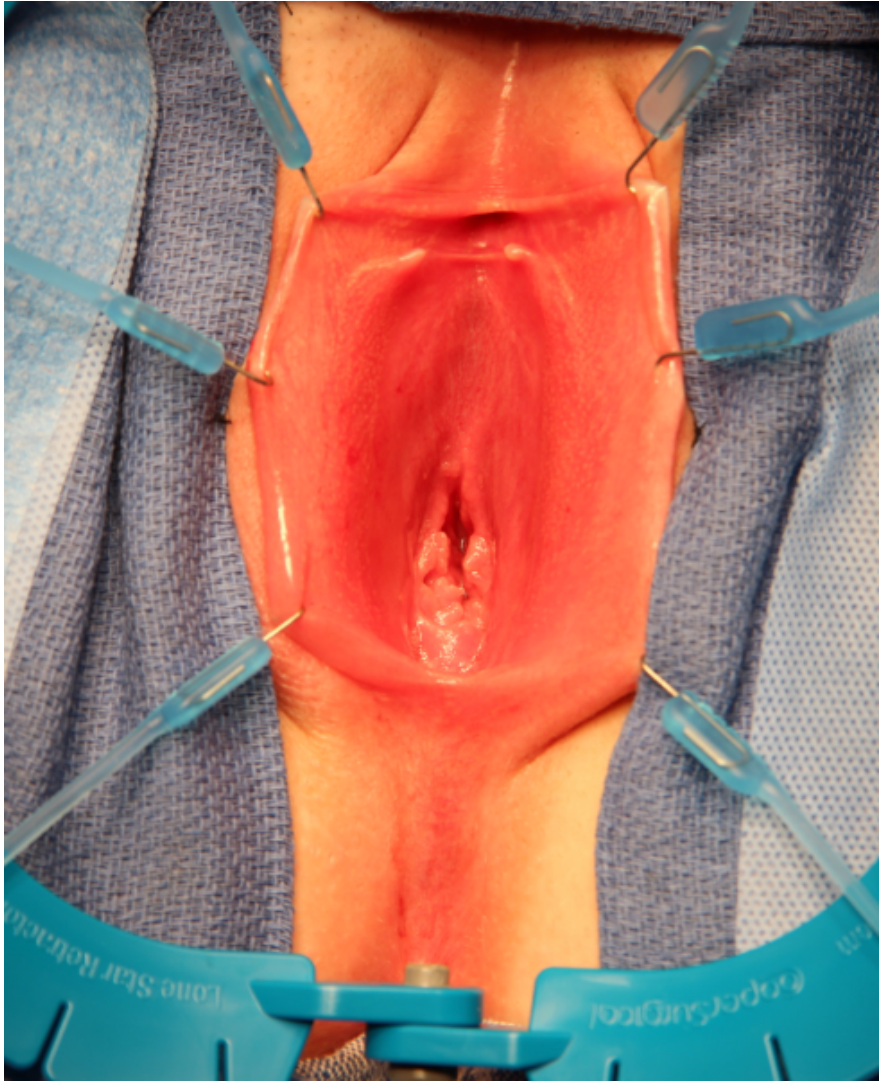

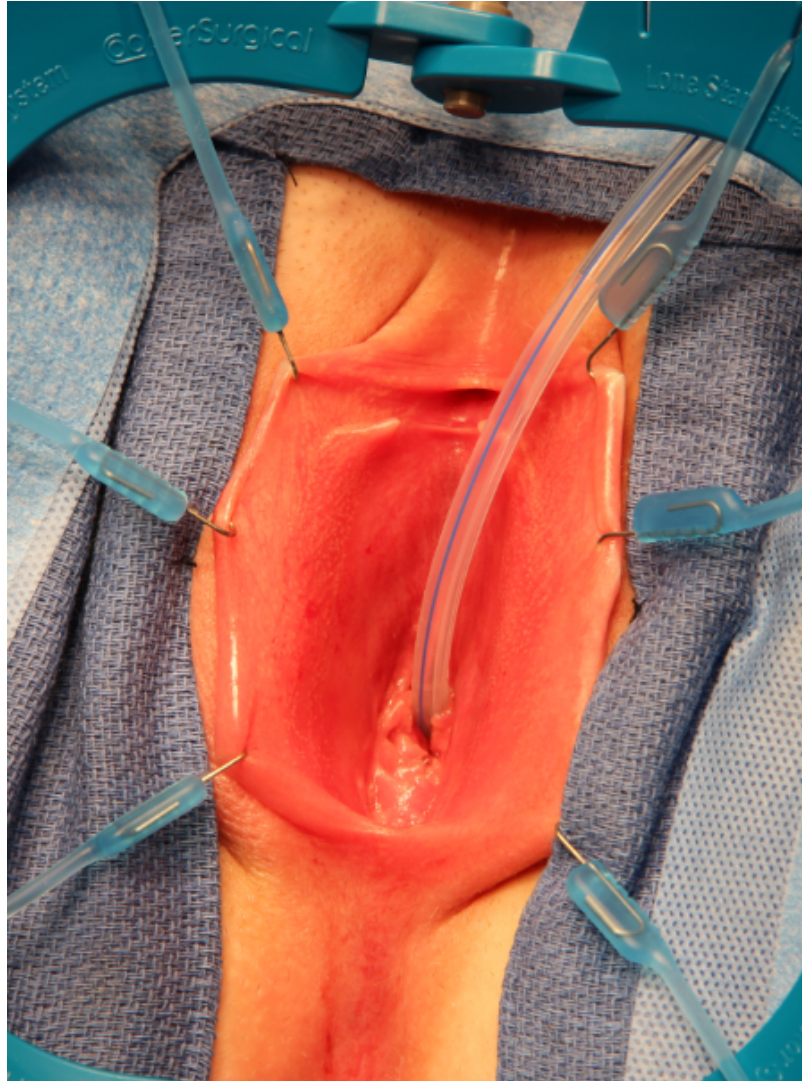


- Went to the OR for imperforate hymen
- During repair, urine was seen, and the procedure was aborted

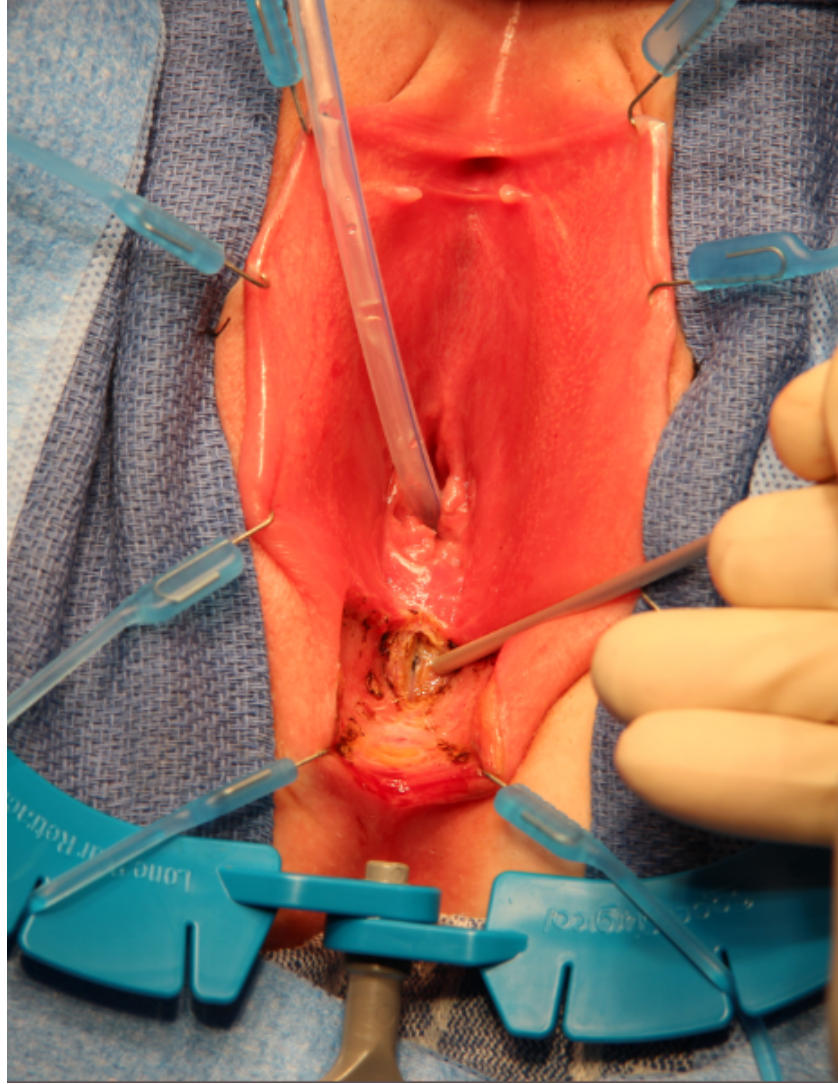
- Transferred to a children's hospital 
- Laparoscopic drainage of the vagina with later tube removal and attempted failed menstrual suppression
- Reinsertion of drainage tube and referred to Children's Colorado



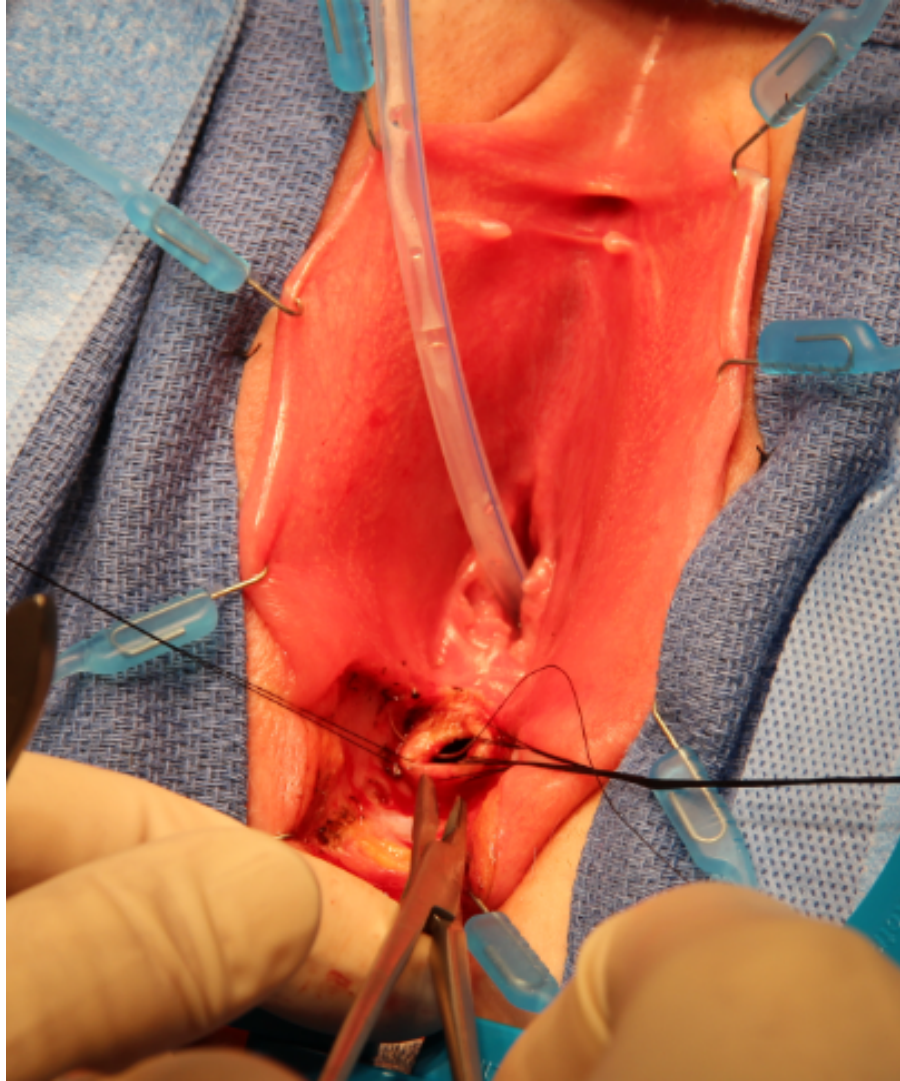


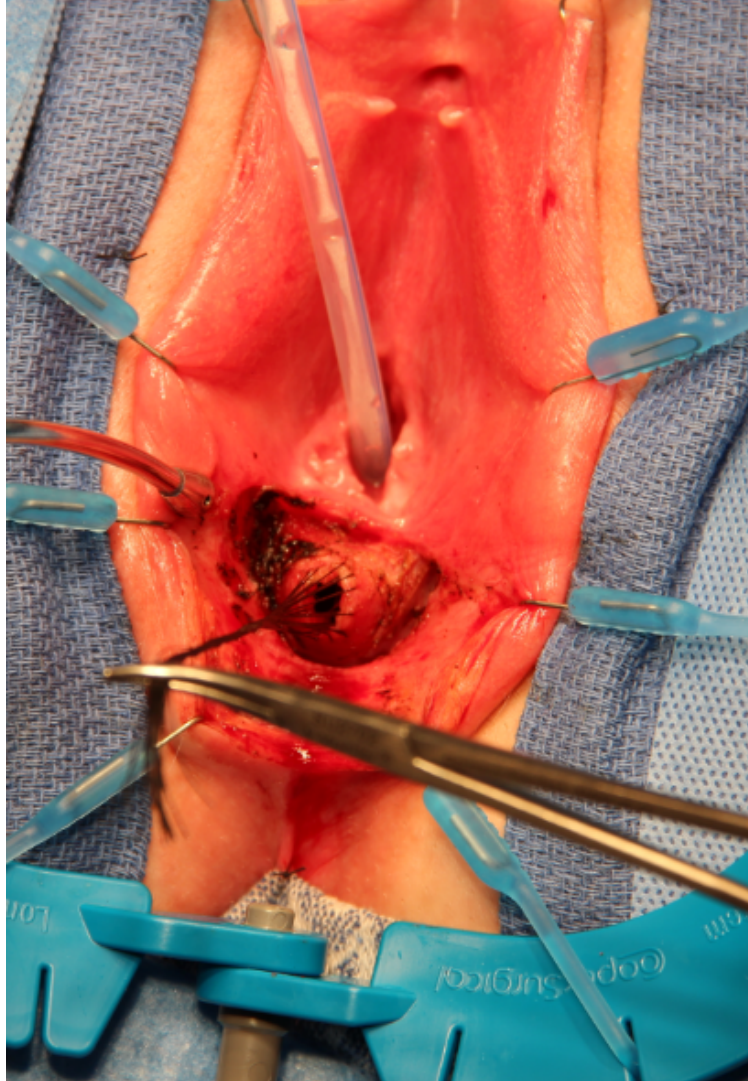


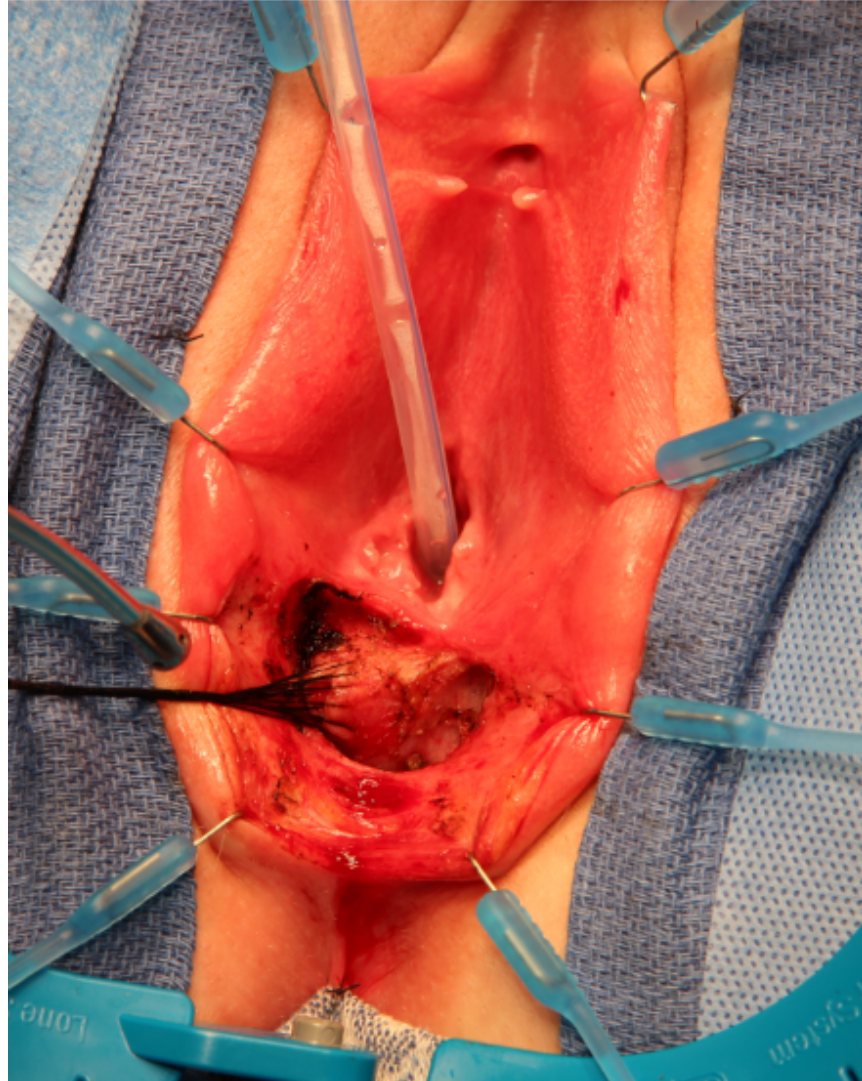




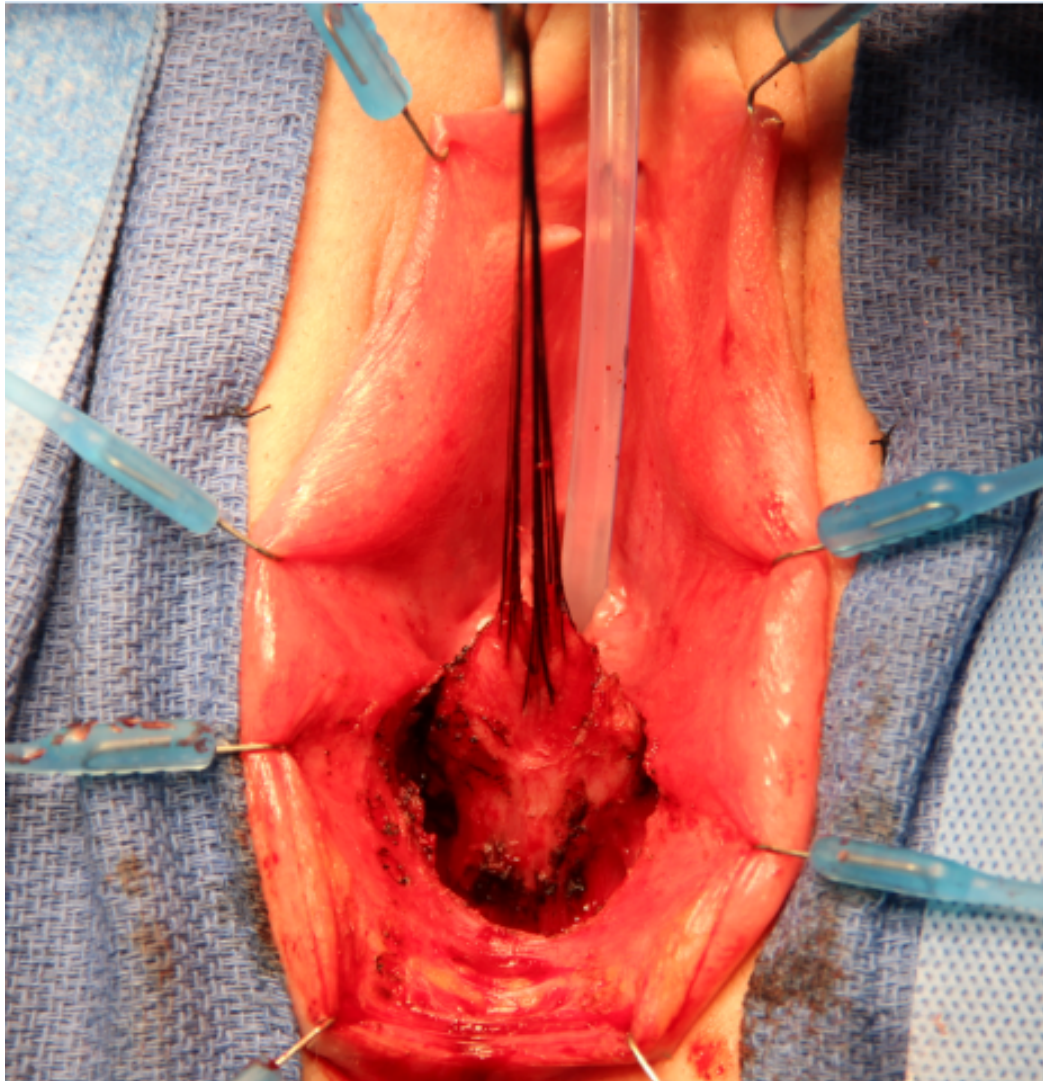


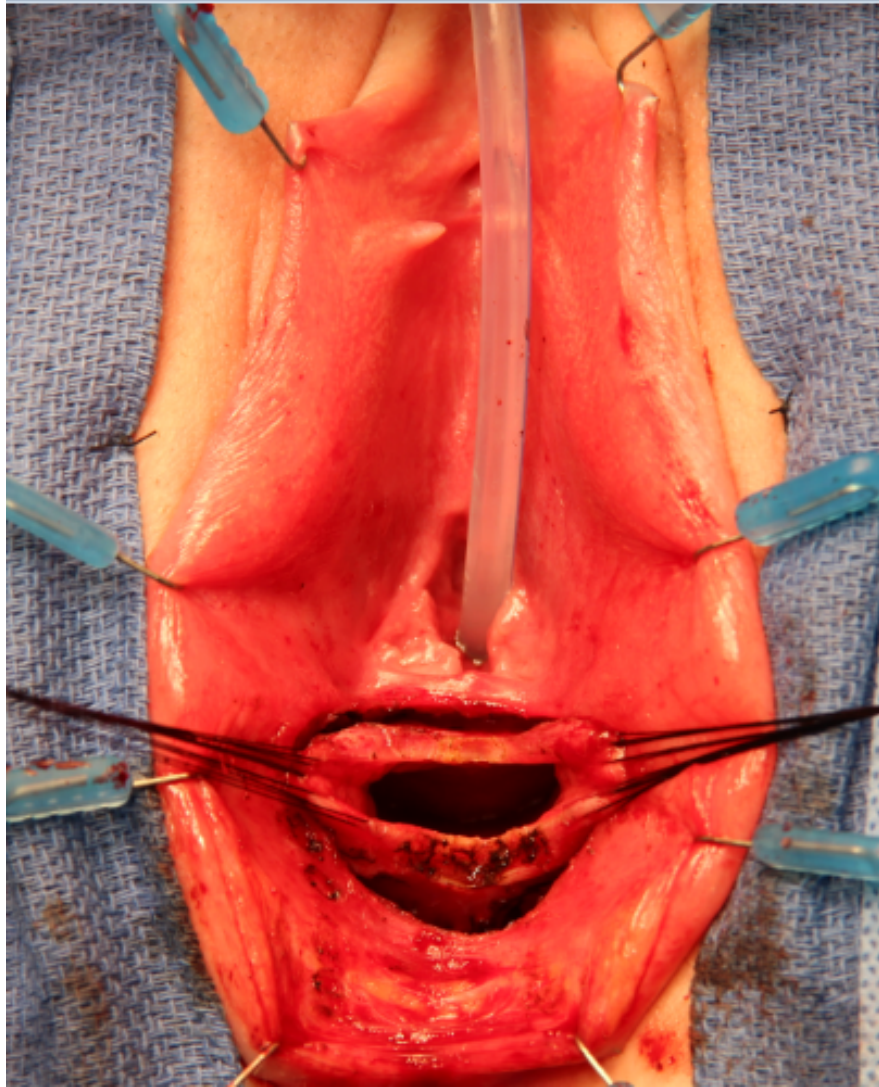


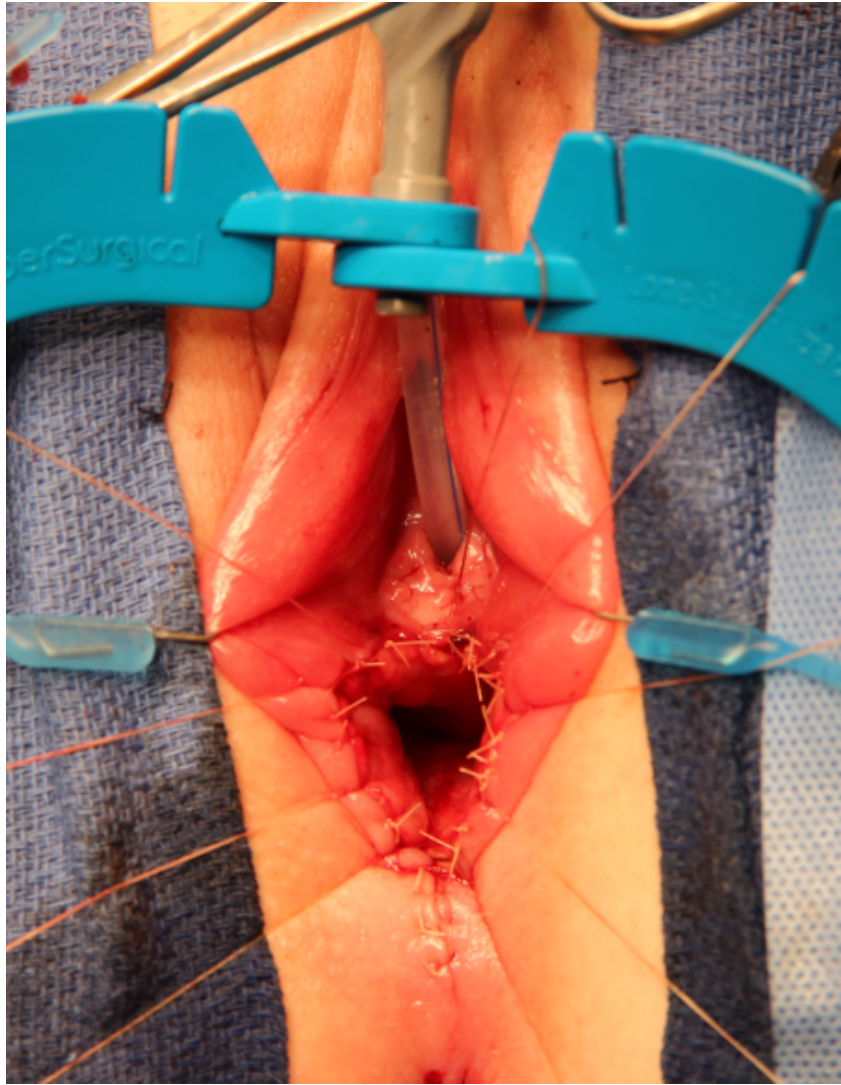




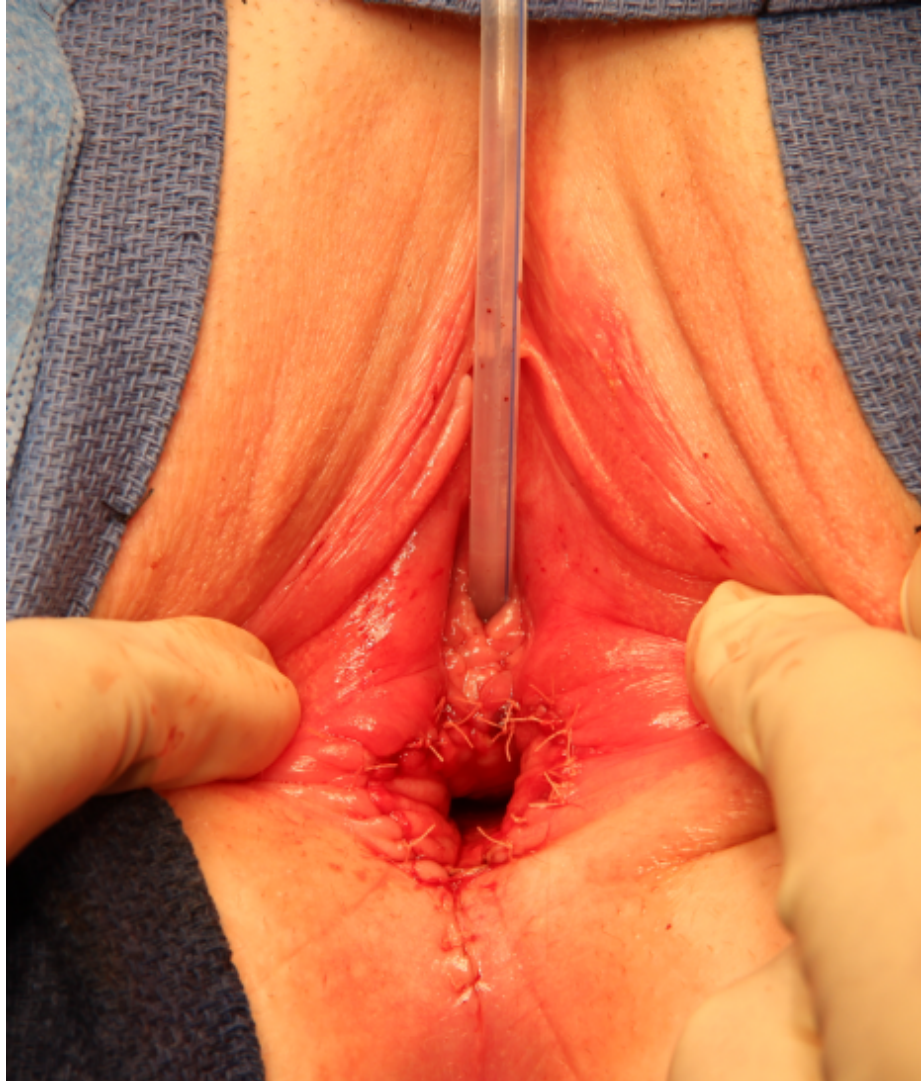











# Follow up



1 month post-op:

- Patient is doing well
- Menstruating