

Case # 5

Andrea Bischoff, MD

04/19/2018

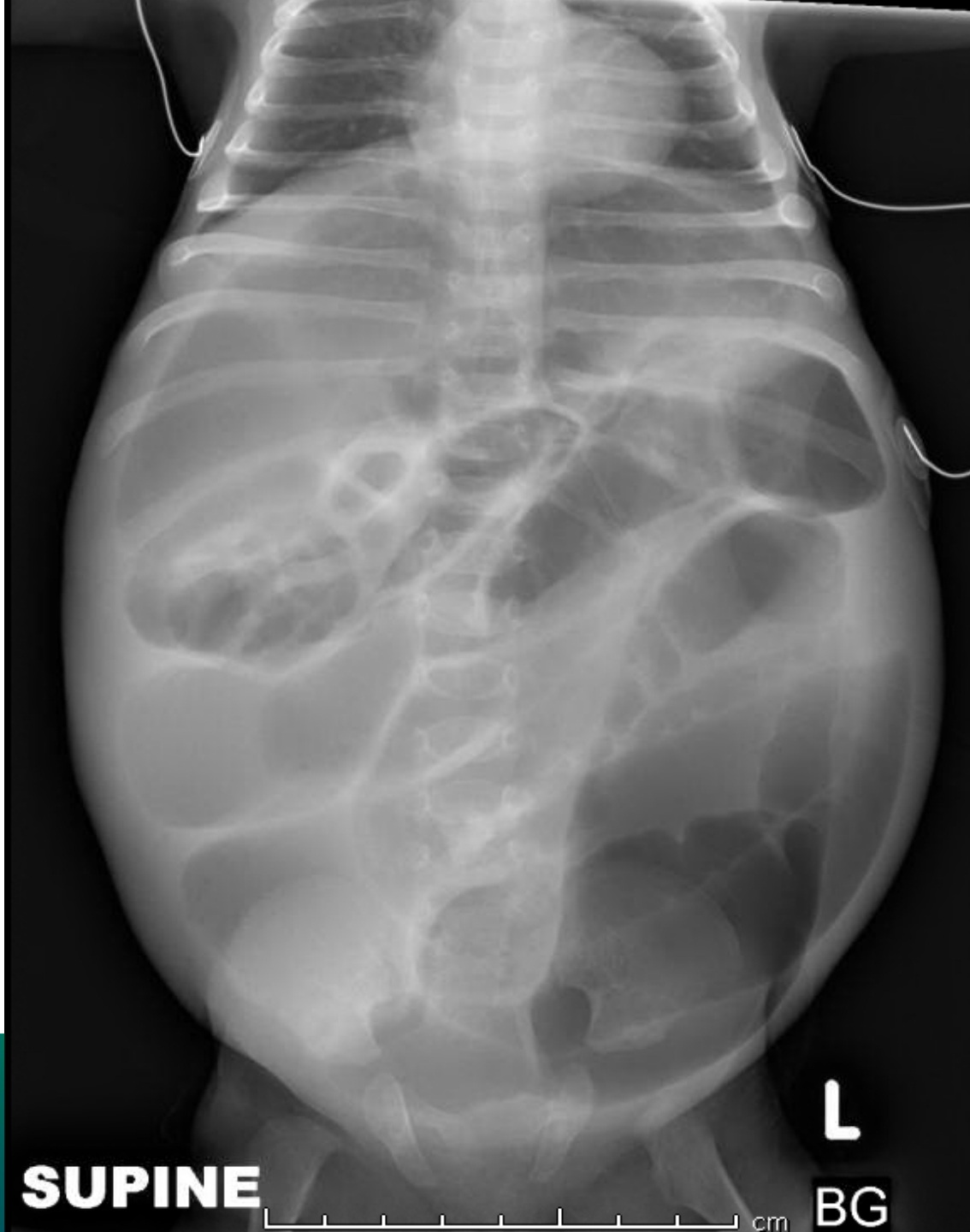


Children's Hospital Colorado

INTERNATIONAL CENTER FOR
**COLORECTAL AND
UROGENITAL CARE**



- 3 mo, female patient born with trisomy 21
- 2.5 kg
- Presented to the emergency room with emesis and abdominal distension



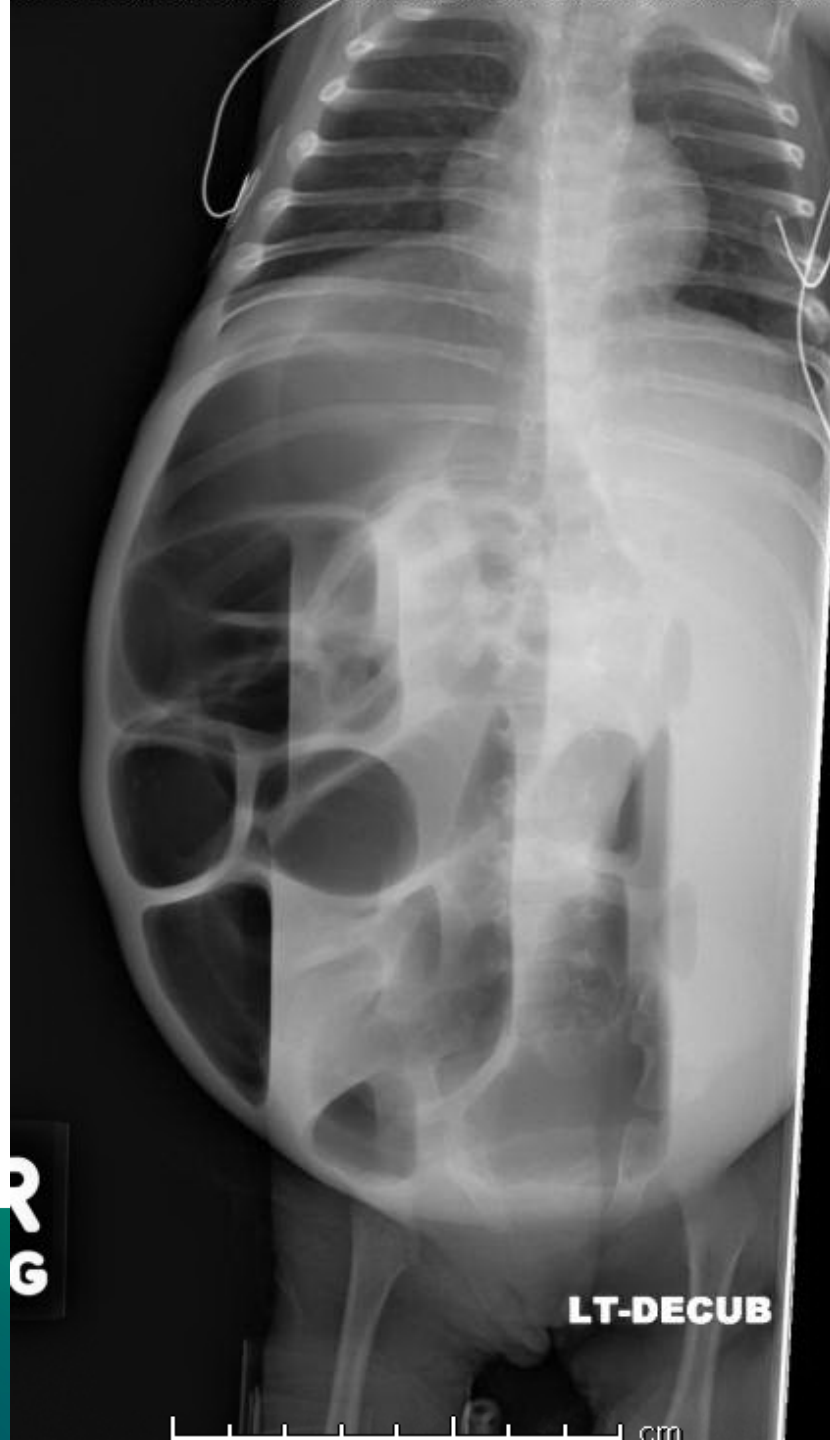SUPINE

L

BG

cm

NATIONAL CENTER FOR
**RECTAL AND
HOSPITAL CARE**

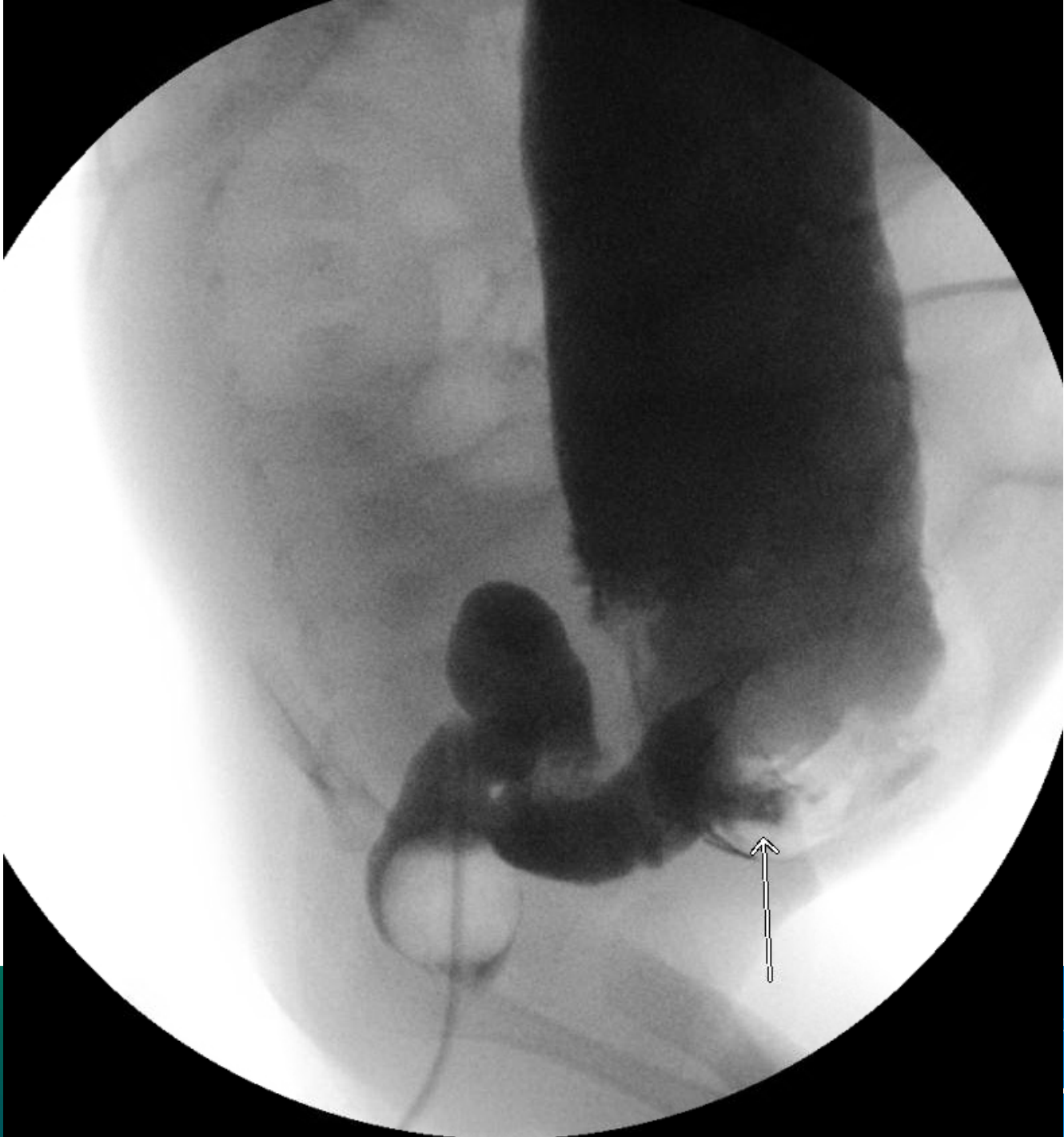


INTERNATIONAL CENTER FOR
**COLORECTAL AND
UROGENITAL CARE**

What would you do next?



1. Rectal irrigation, NG tube, IV fluids
2. Rectal biopsy
3. Contrast enema
4. Exploratory laparotomy
5. I don't know



What is the diagnosis?



1. Idiopathic constipation
2. Hypothyroidism with constipation
3. Hirschsprung
4. Bowel obstruction
5. I don't know

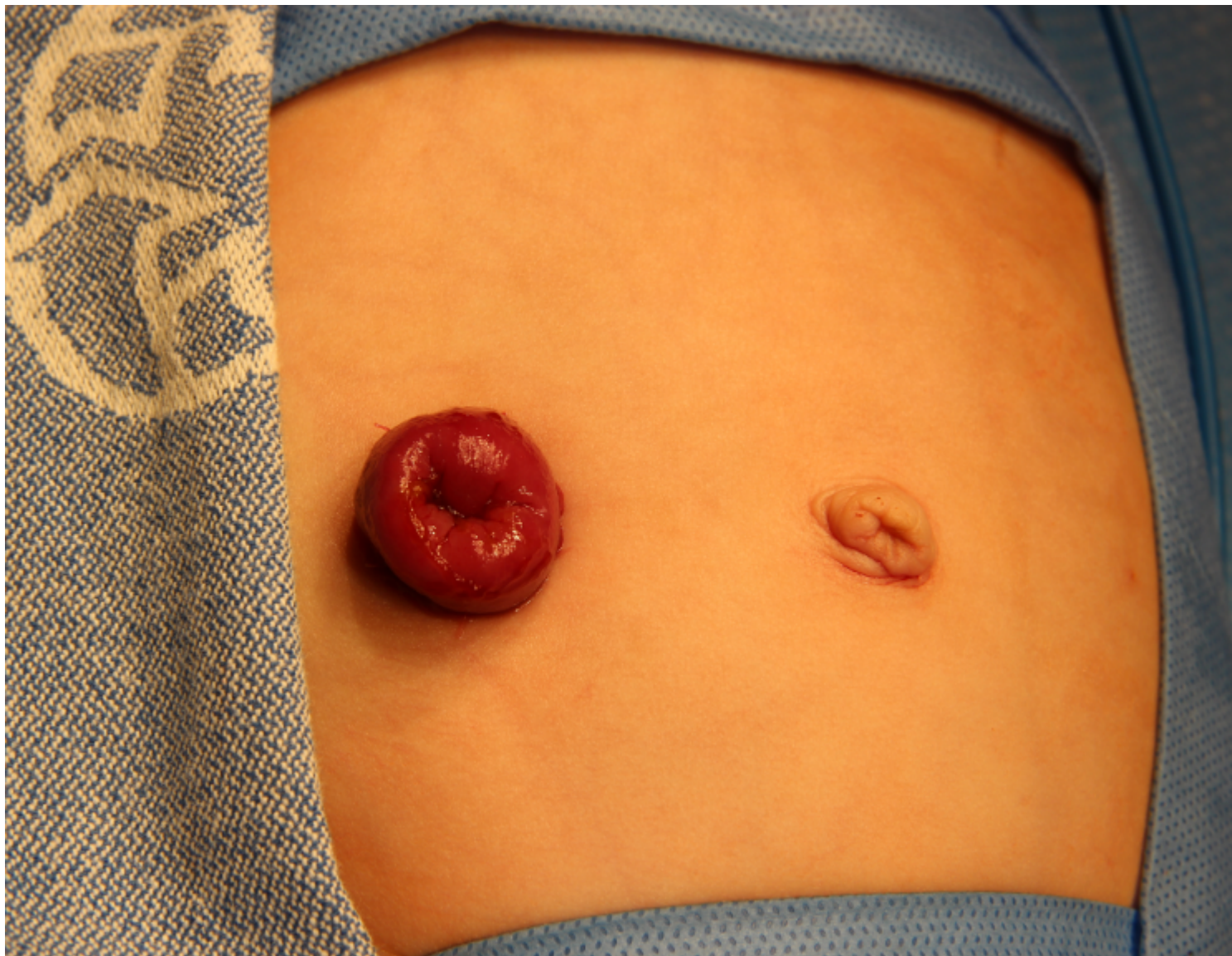

- Underwent suction rectal biopsy:
 - No ganglion cells
 - Abnormal calretinin

What would you do next?



1. Primary transanal pull through
2. Primary laparoscopic assisted pull through
3. Colostomy
4. I don't know





Our Next International Colorectal Web Meeting will be on May 17th, 2018

