

# Case # 4

---

06/22/2017

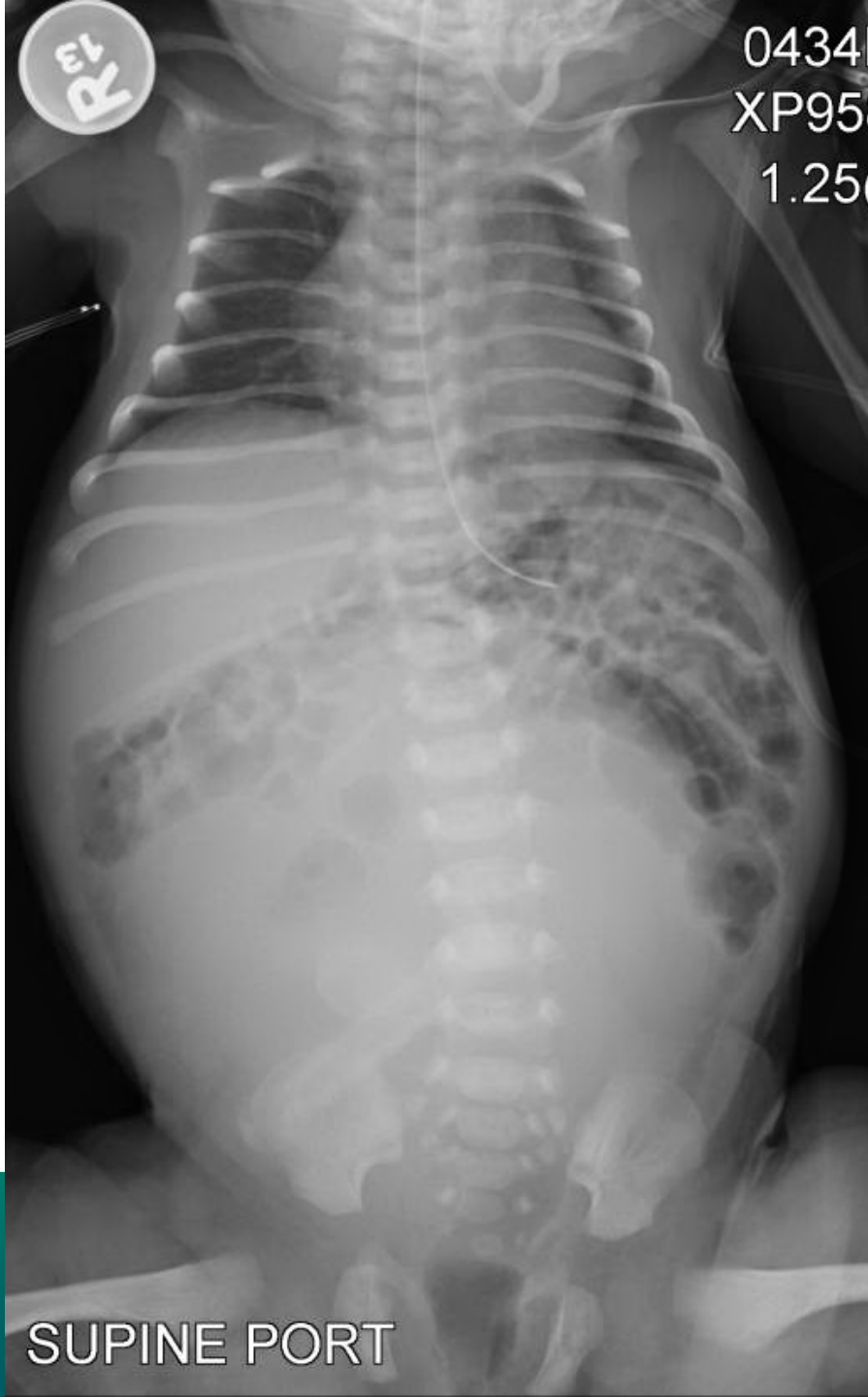

Children's Hospital Colorado

INTERNATIONAL CENTER FOR  
**COLORECTAL AND  
UROGENITAL CARE**



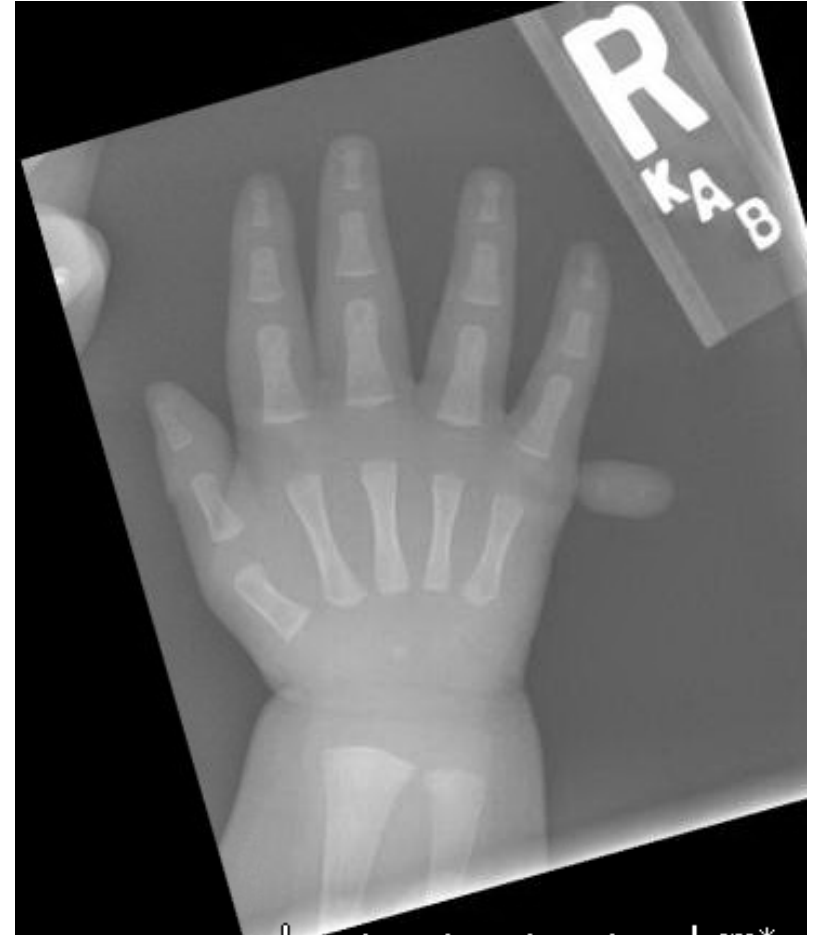
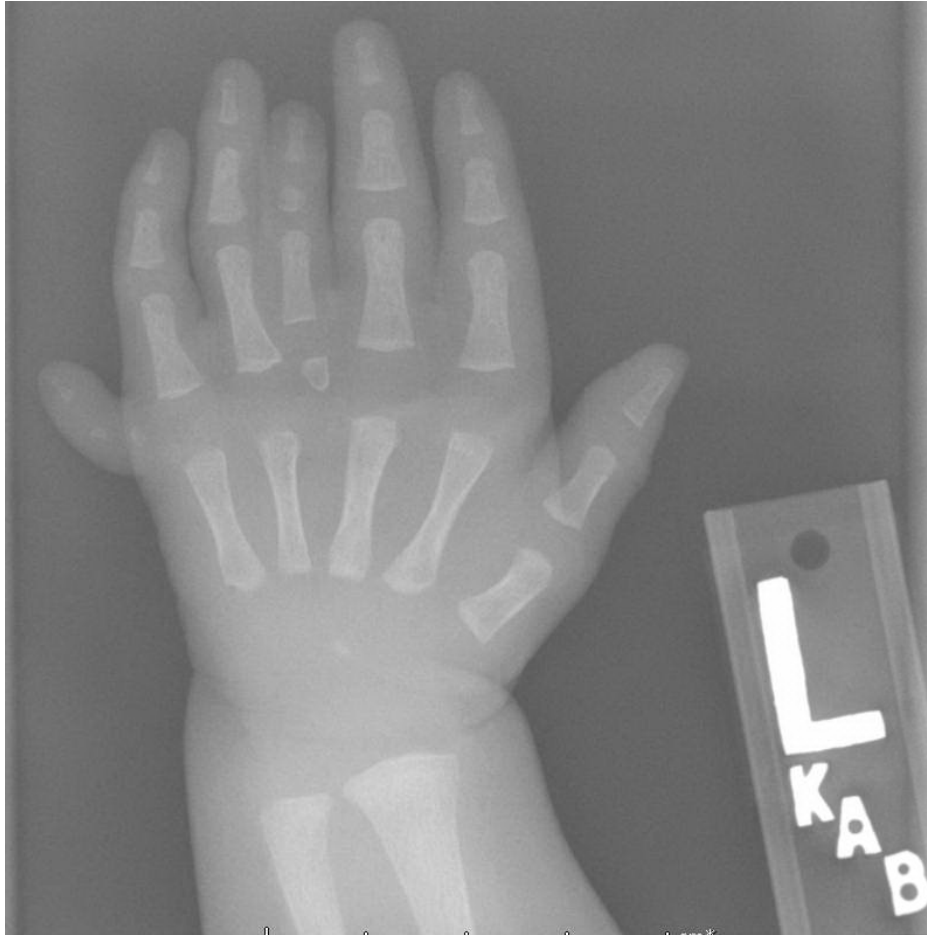
- 1 yo, female patient, born with atresia of the distal vagina.
  - Atrial septum defect and anomalous venus return
  - Left hydronephrosis



SUPINE PORT

INTERNATIONAL CENTER FOR  
**COLORECTAL AND  
PROGENITAL CARE**

# Polydactyly



TIS: 0.7  
TIB: 0.7  
MI: 1.2  
≈

Sagittal  
SPINE

LUMBAR

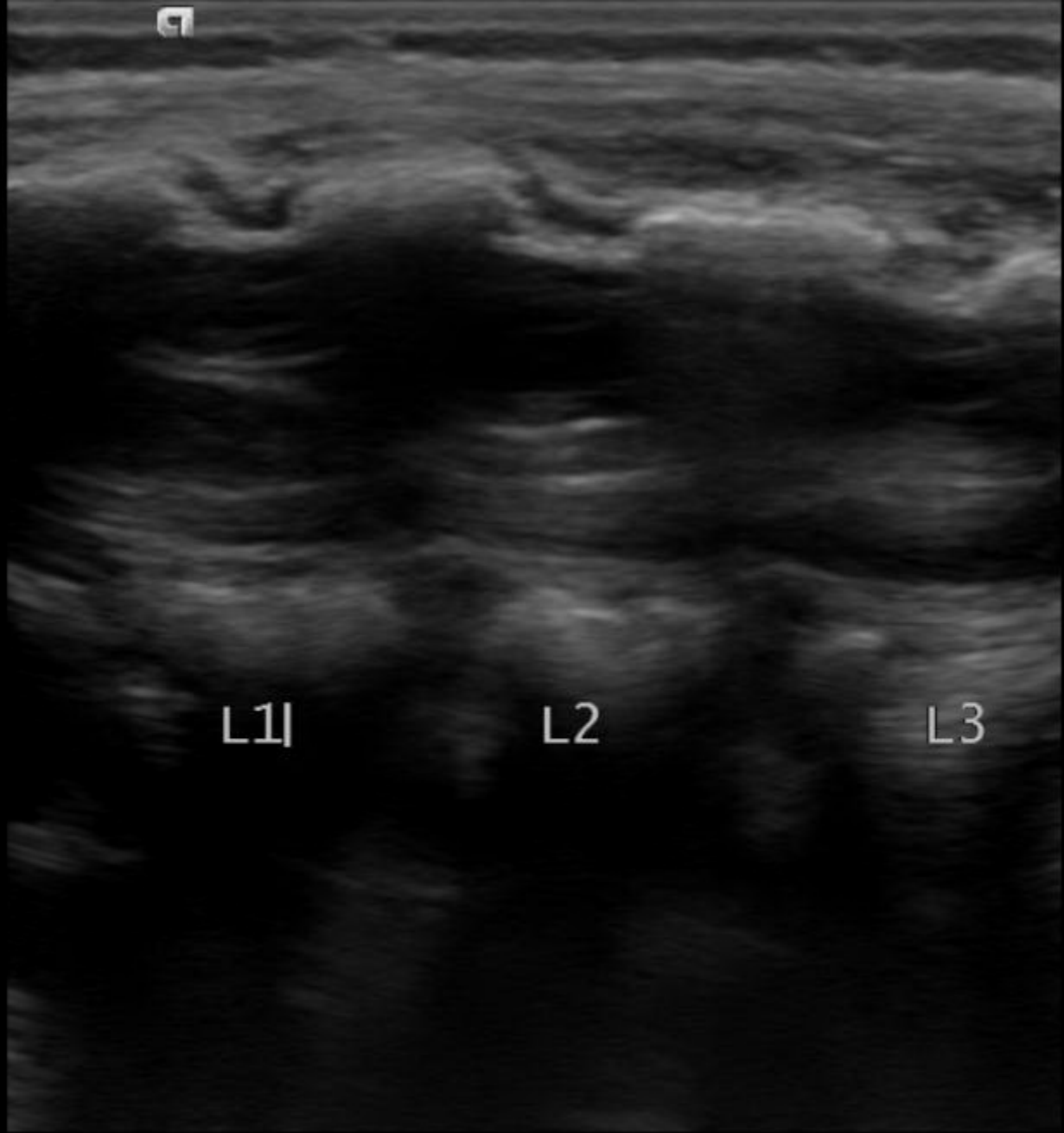
L1

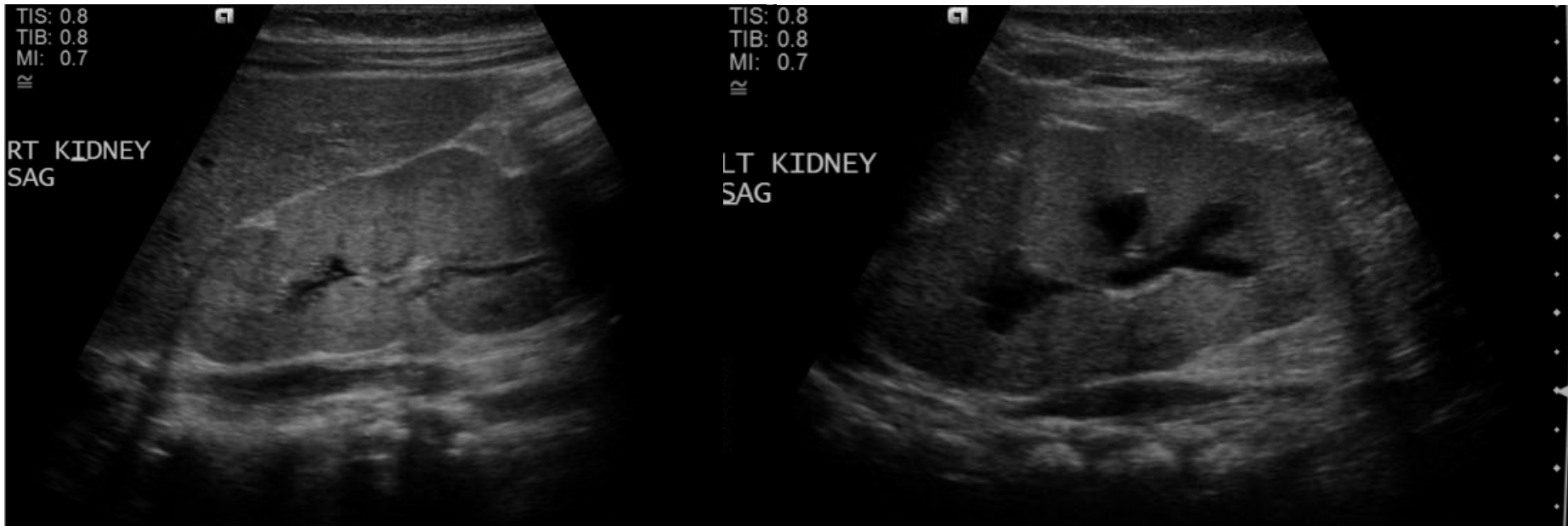L2

L3

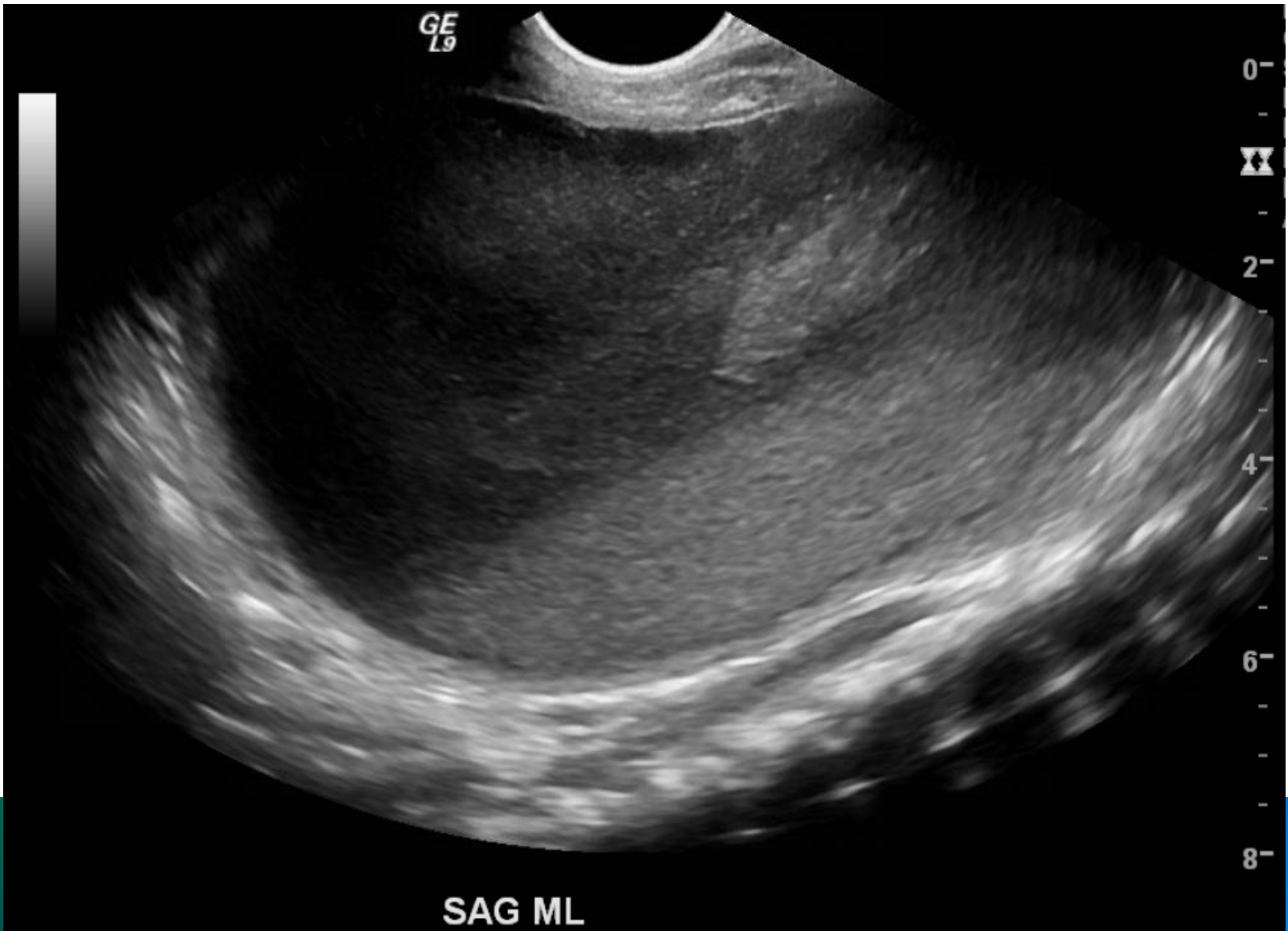
CONUS L1-L2

29fps





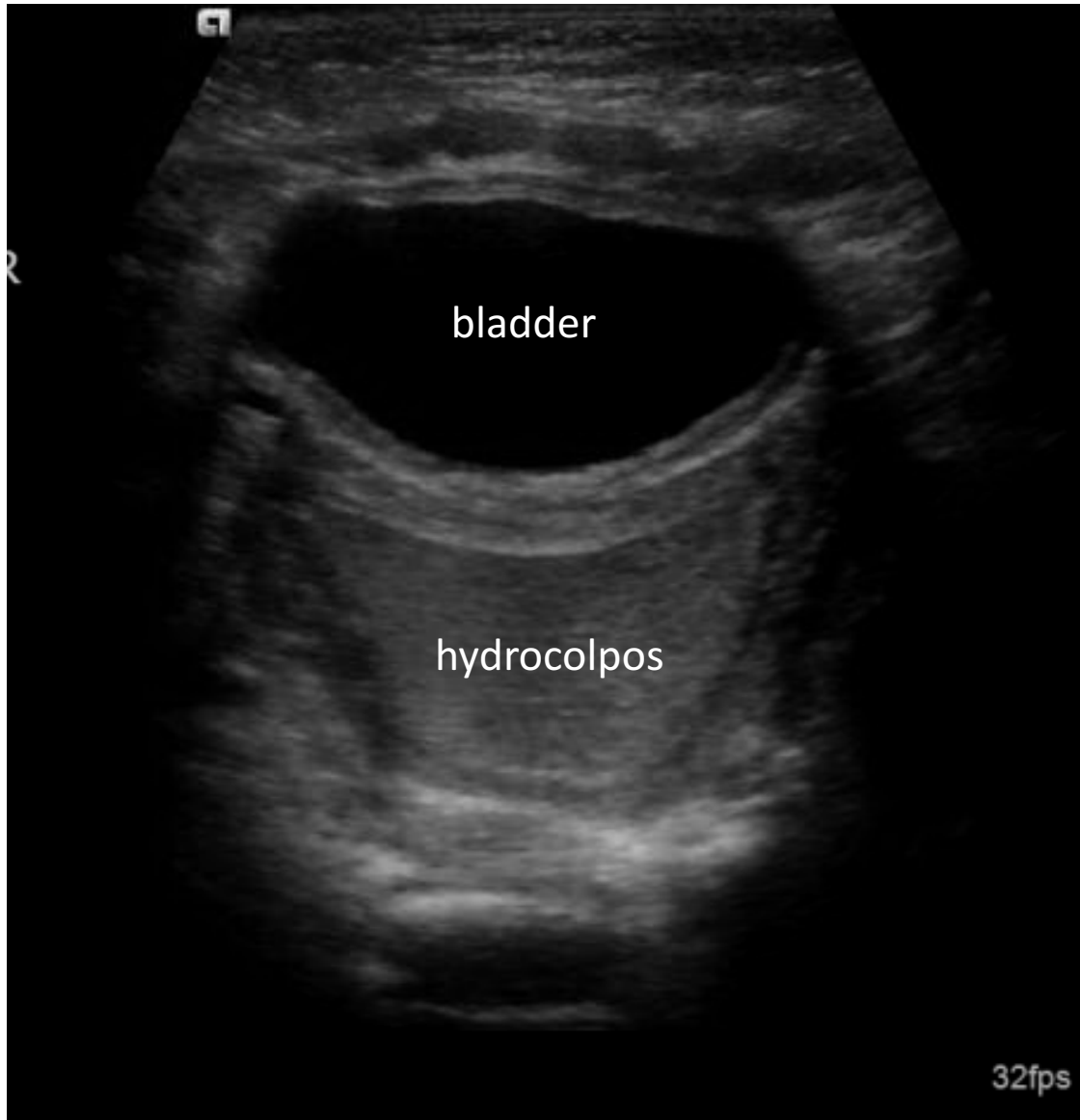
# At Birth





- Percutaneous drainage of hydrocolpos (400 ml)
- 1 month later the catheter came out
- Reaccumulation of the hydrocolpos





TIS: 0.5  
TIB: 0.5  
MI: 1.2

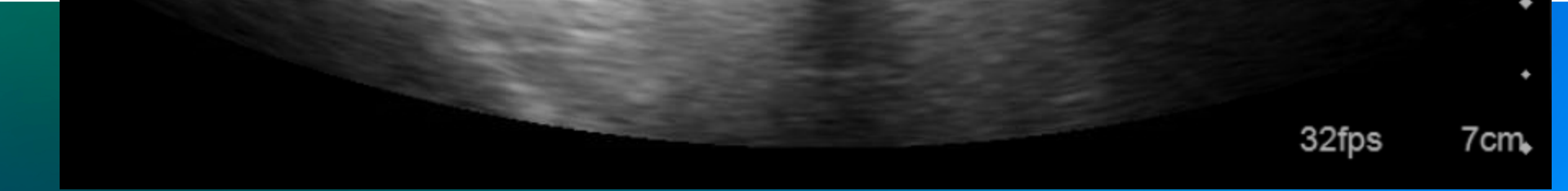
BLADDER  
TRANS  
ML\_

bladder

hydrocolpos

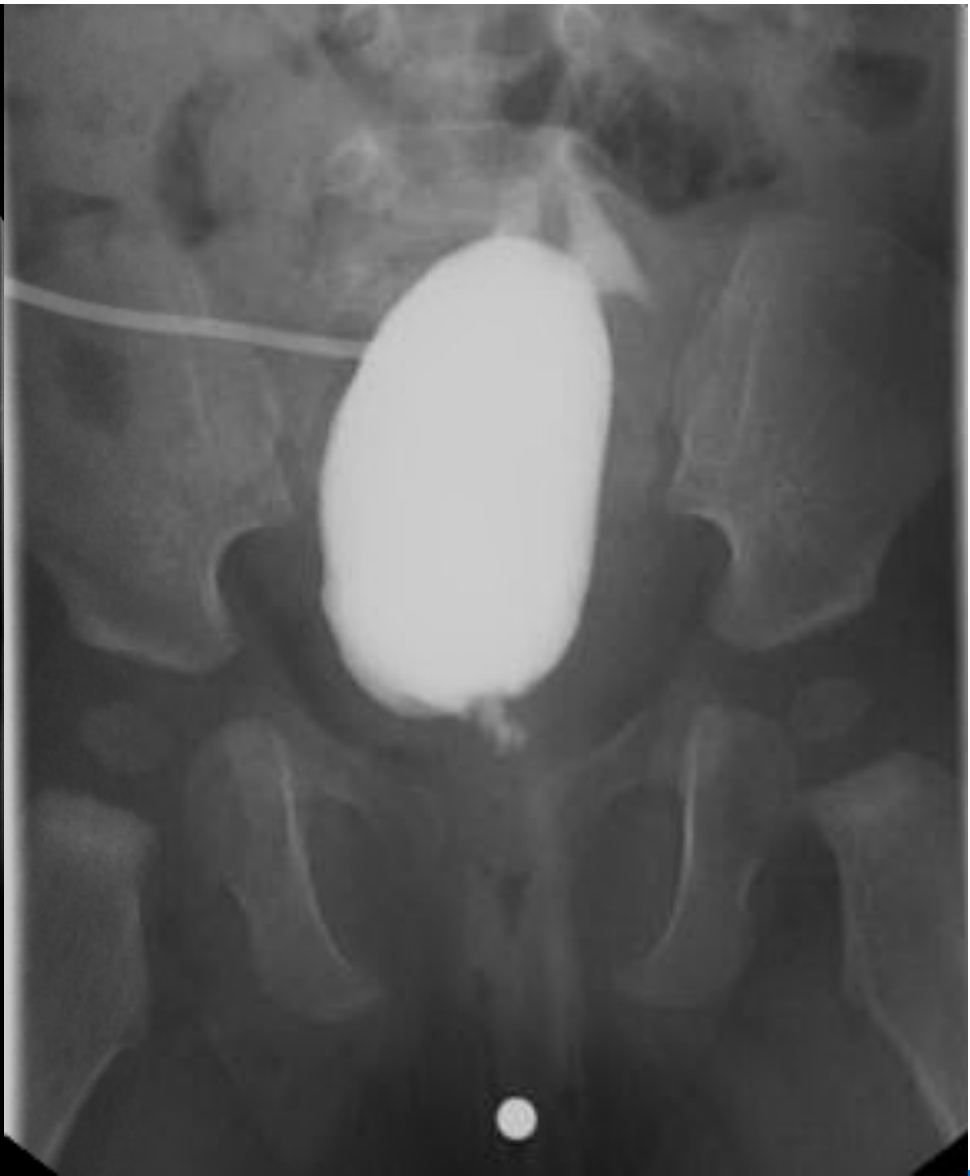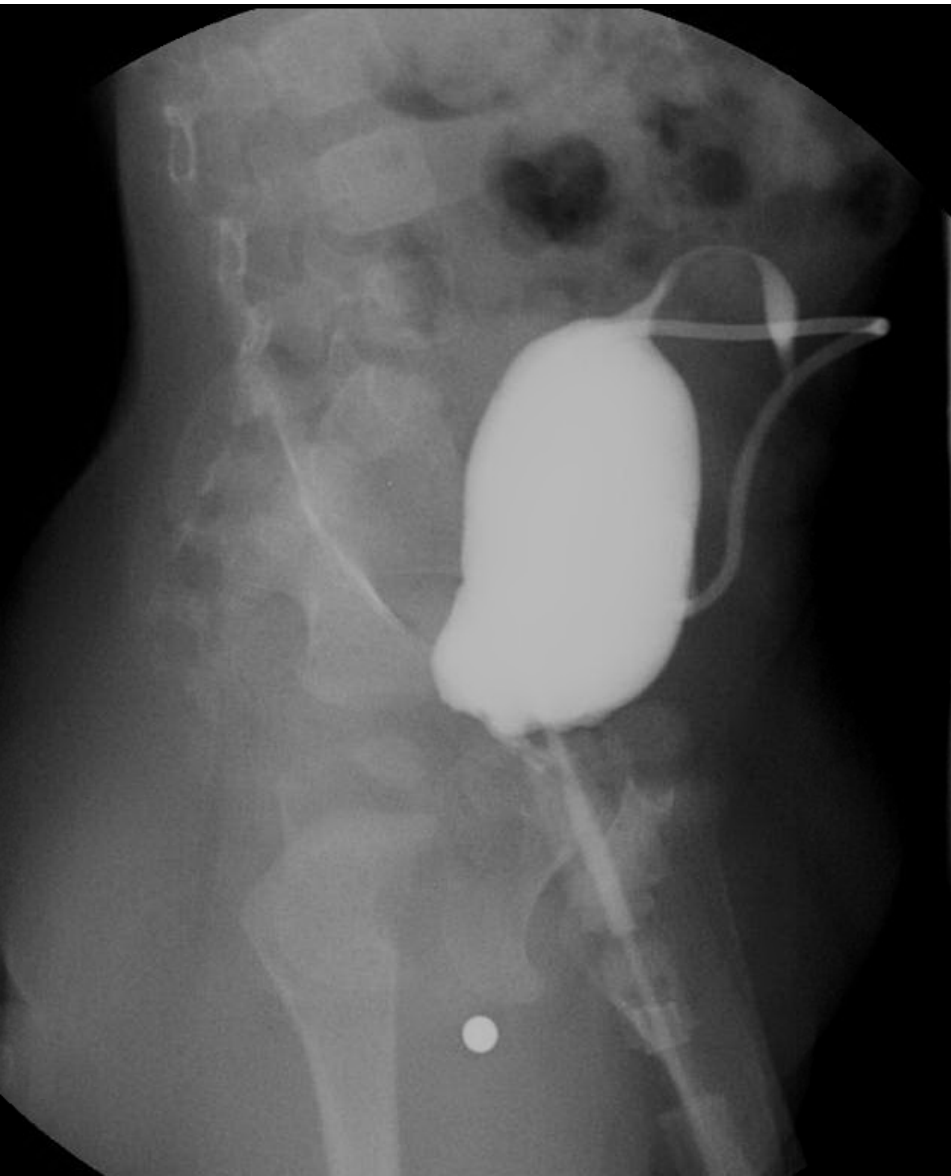
32fps

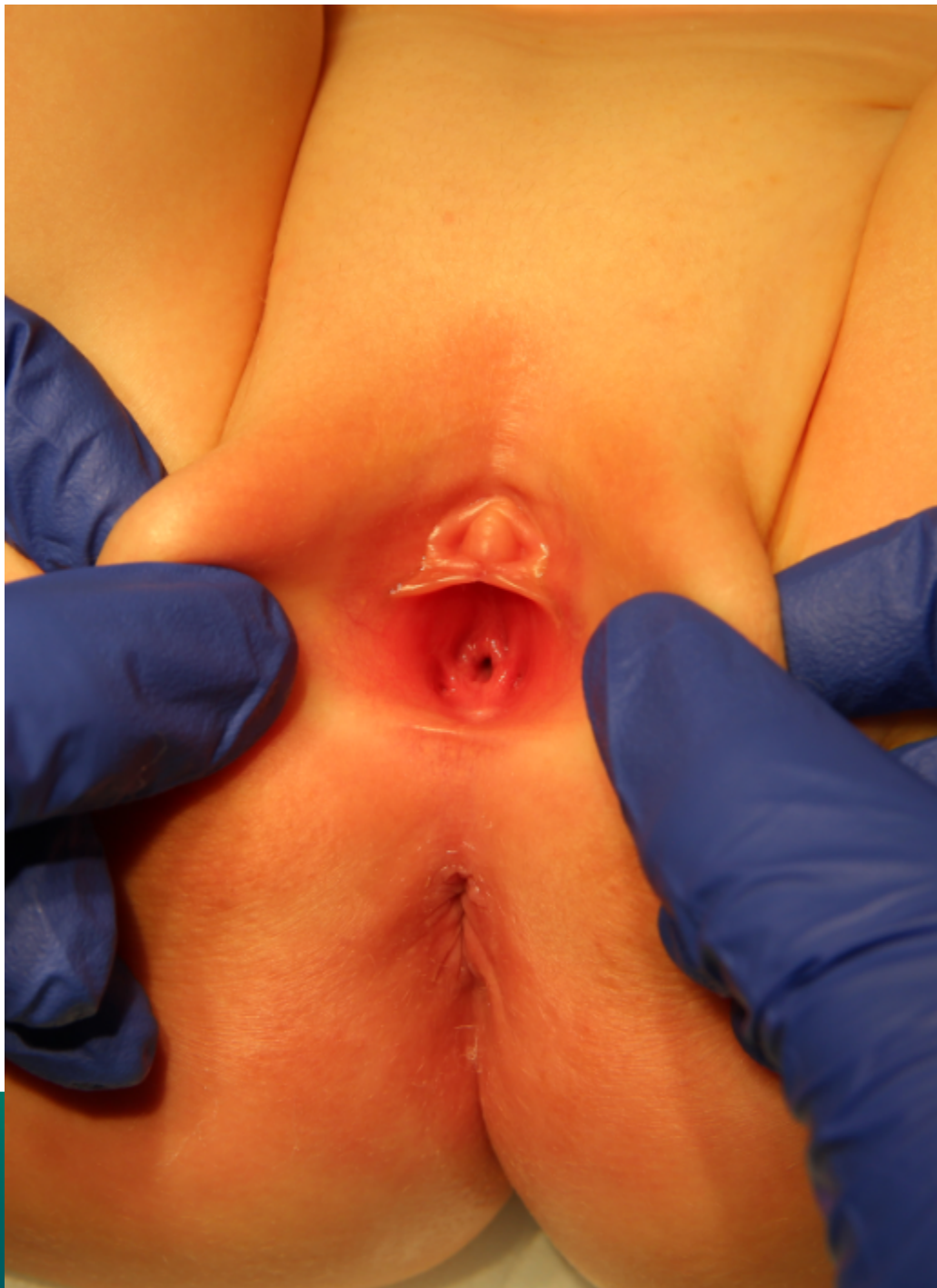7cm



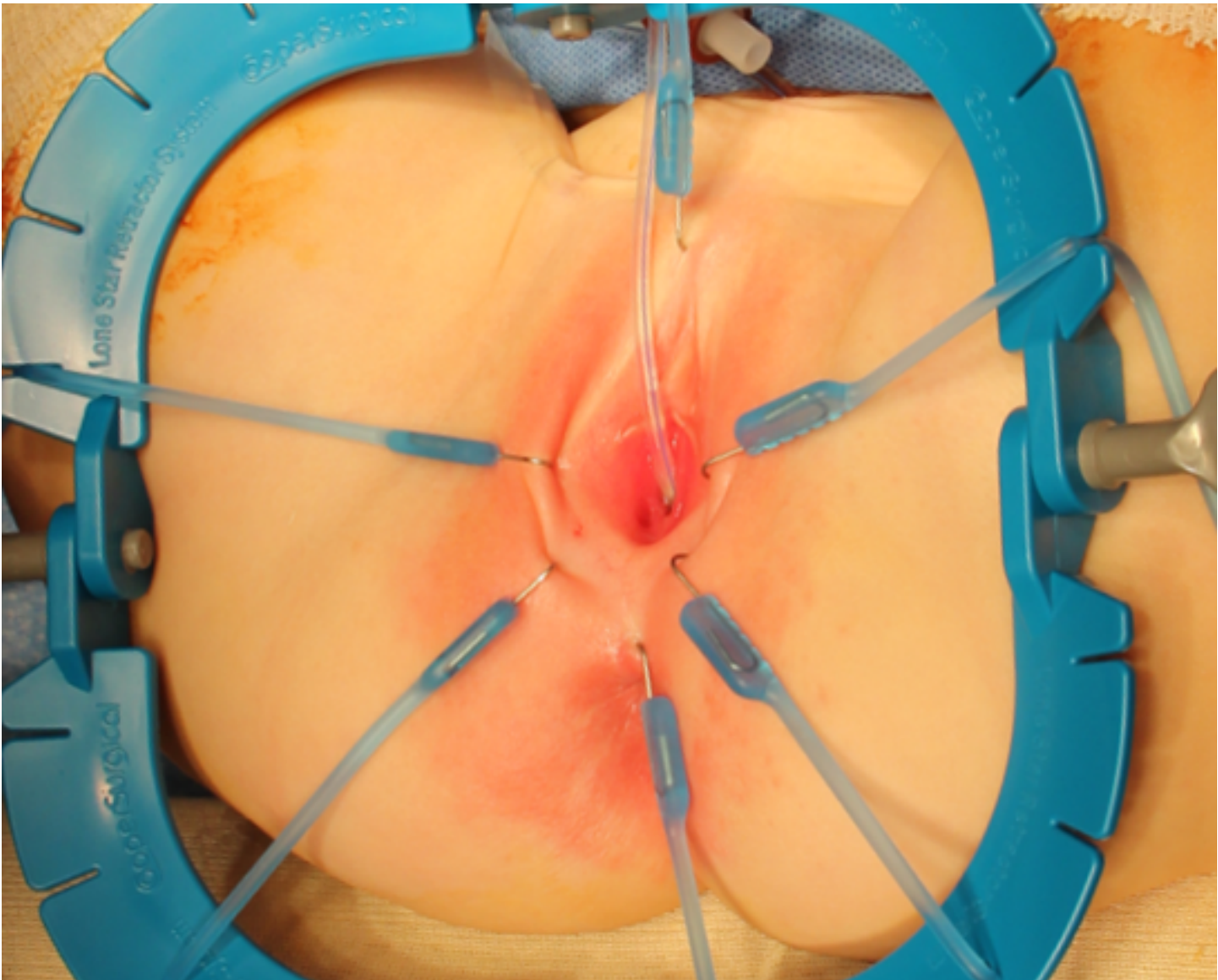


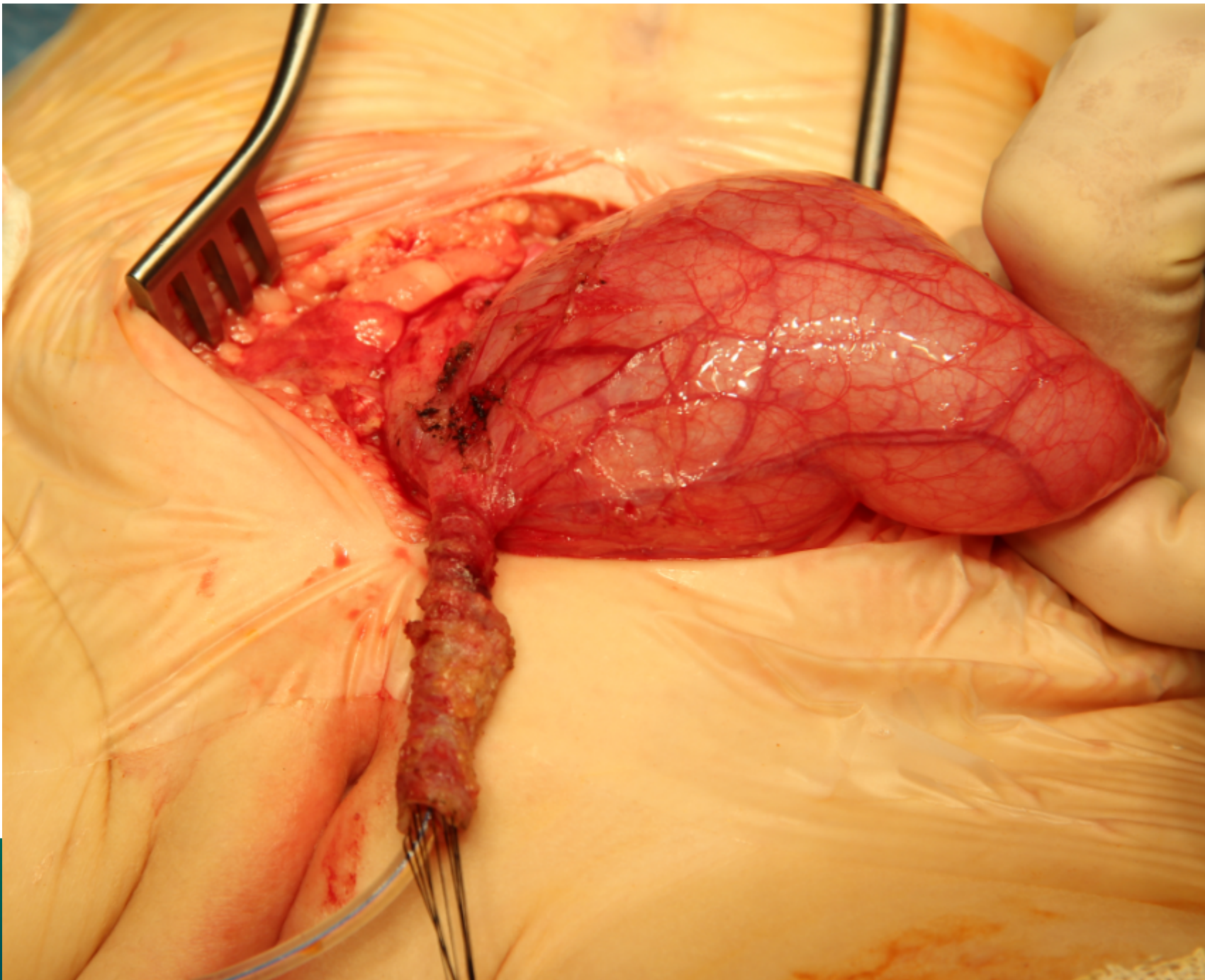
- At 6 months of age, open heart operation
- At 7 months of age, ultrasound guided, reinsertion of vaginal catheter
  - Catheter came out
- At 8 months of age, laparoscopic guided placement of catheter

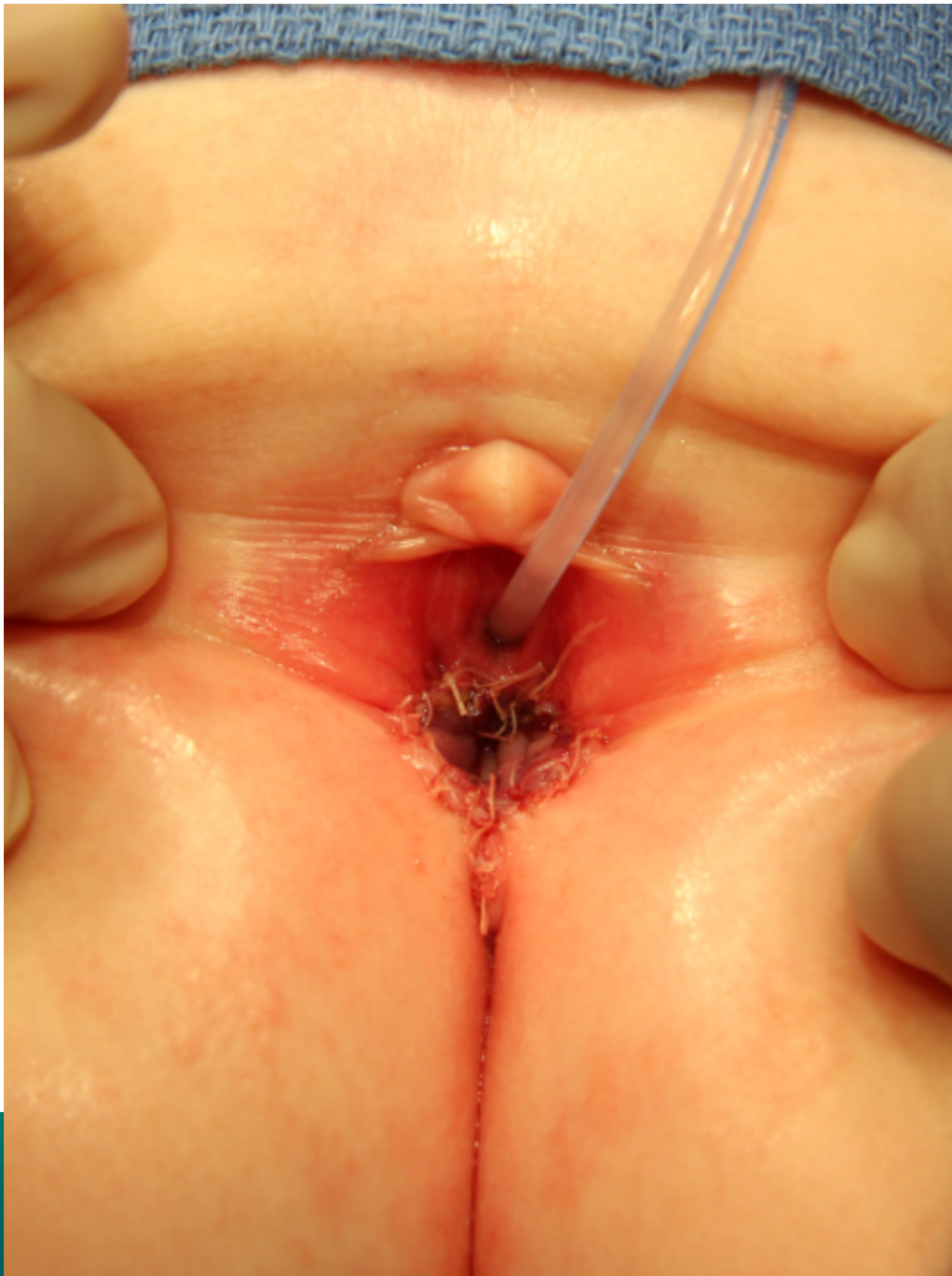




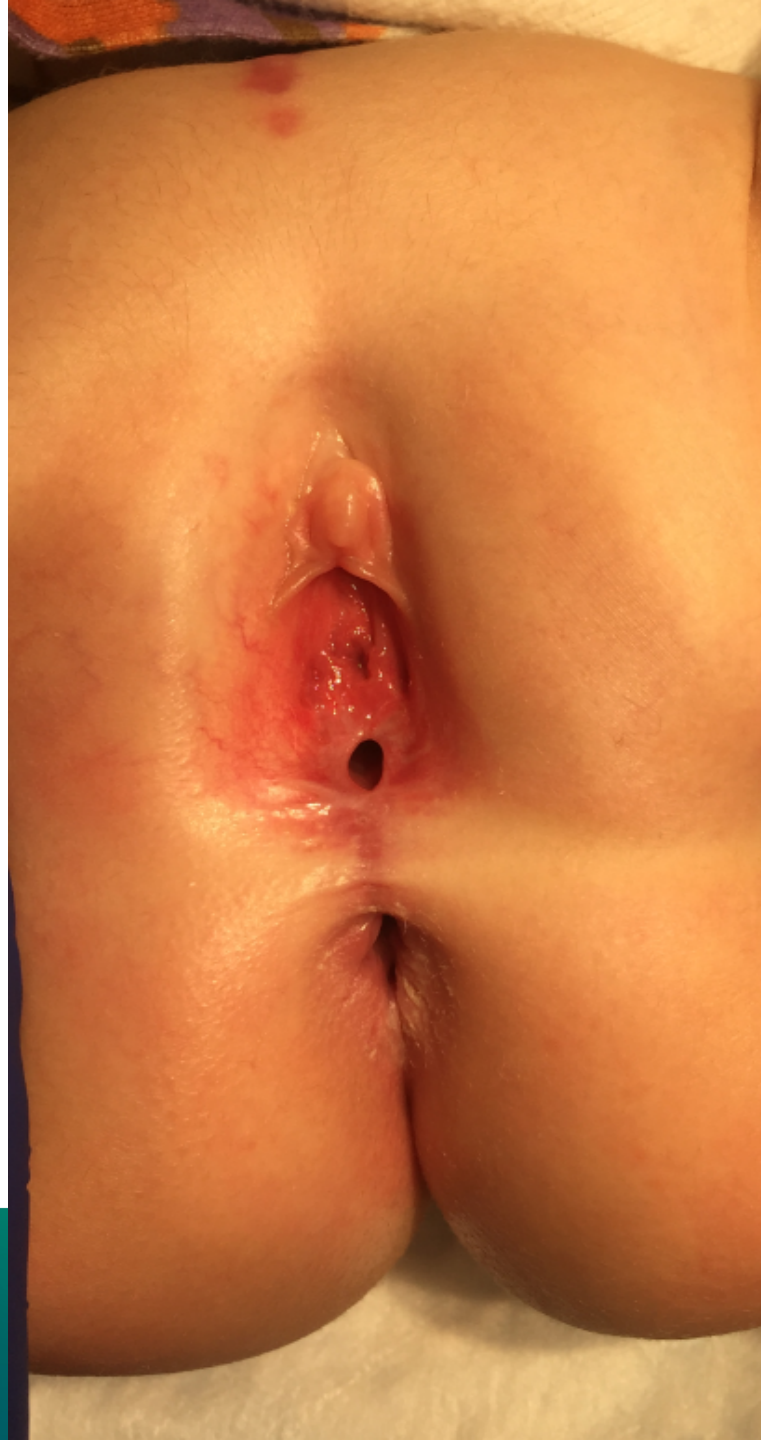INTERNATIONAL CENTER FOR  
**RECTAL AND  
GENITAL CARE**











INTERNATIONAL CENTER FOR  
**COLORECTAL AND  
UROGENITAL CARE**

# Our Next International Colorectal Web Meeting will be on July 13<sup>th</sup>, 2017



**Children's Hospital Colorado**  
International Center for  
Colorectal Care



Your Global Networked Community  
for Pediatric Surgery & Urology