

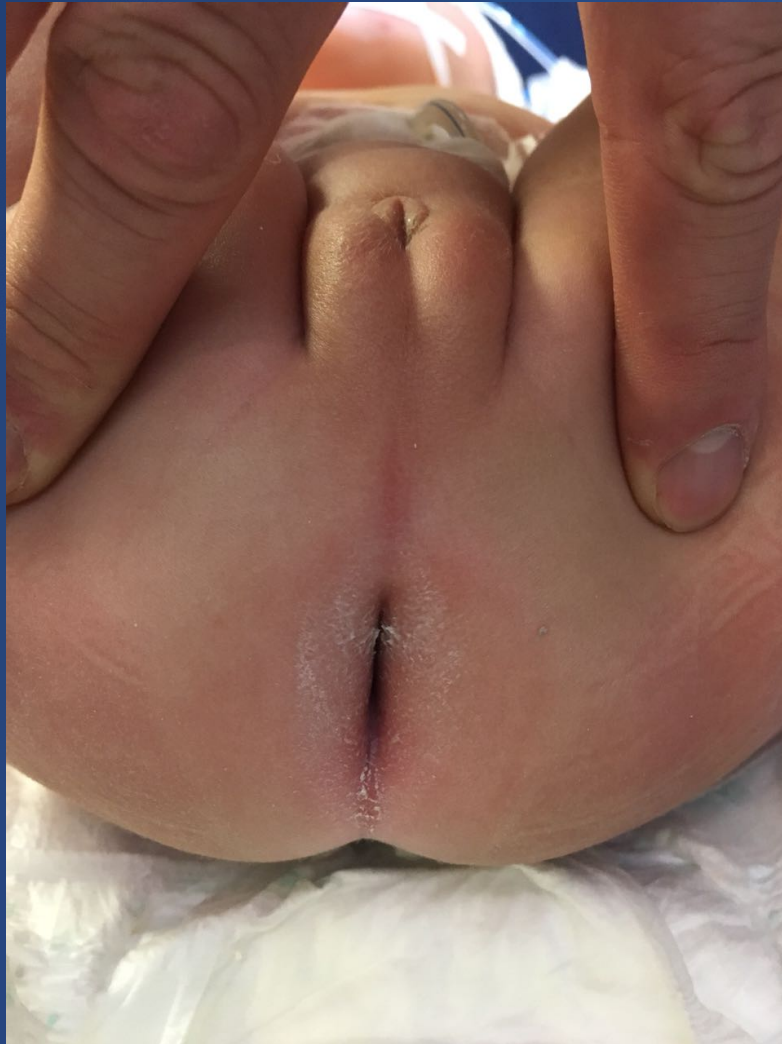

Colorectal Web Meeting

HOSPITAL INFANTIL DE MEXICO FEDERICO GOMEZ

- 6-month-old patient referred to our institution for “ambiguous genitalia”
- “Urethral agenesis”
- Laparotomy done when newborn where a suprapubic tube insertion and “salpingostomy” was done





No urethral or vaginal
orifice

Funnel looking anus

Hypertrophic pubic bone



What is your diagnosis?

1. Urethral and vaginal agenesis
2. Ambiguous genitalia
3. Posterior cloaca
4. I don't know



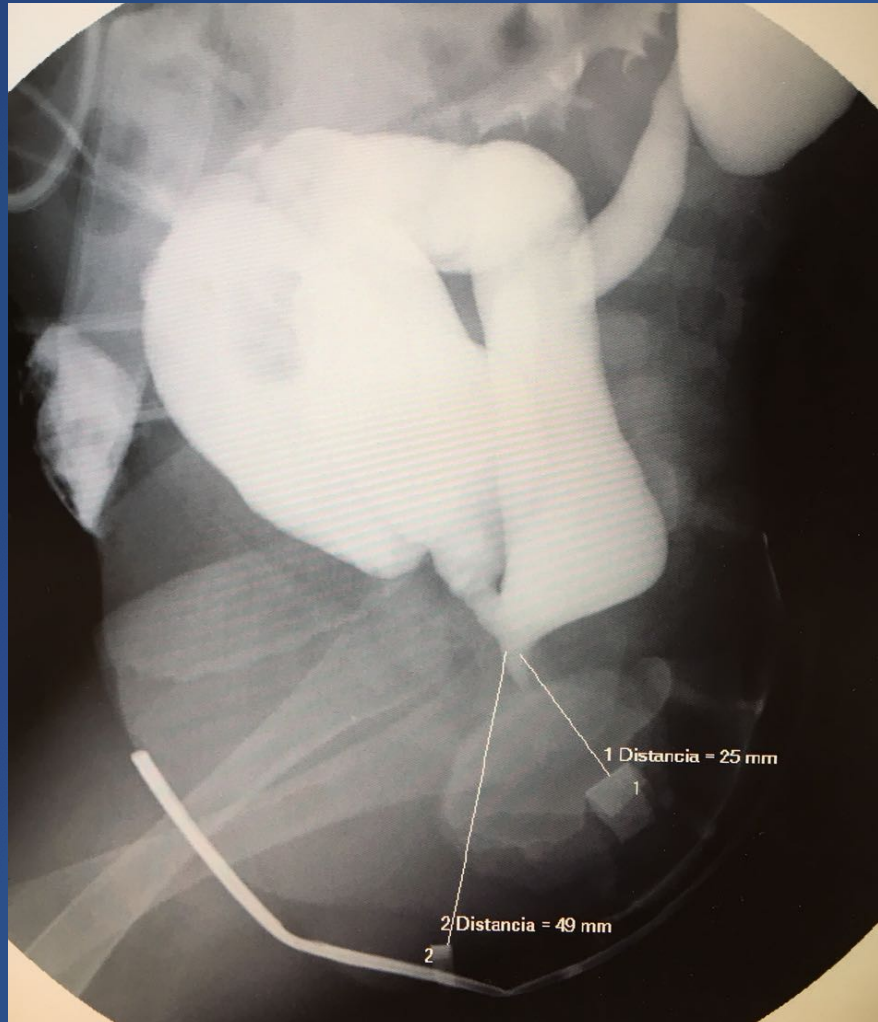
What would you do first?

1. Endocrine and genetic consultation
2. Diverting colostomy
3. Vesicostomy and vaginal replacement
4. I don't know



- Caryotype 46 XX
- Sacral ratio 0.56
- Diverted descending colostomy was made
- Distal colostogram, cystogram, and vaginostogram were performed

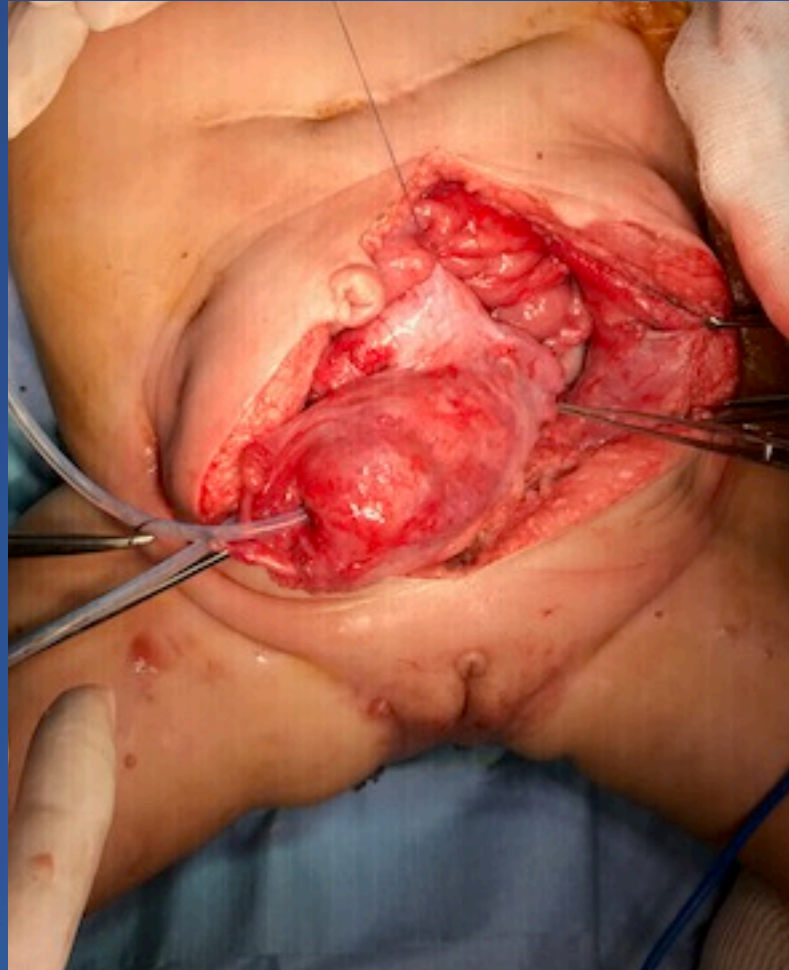
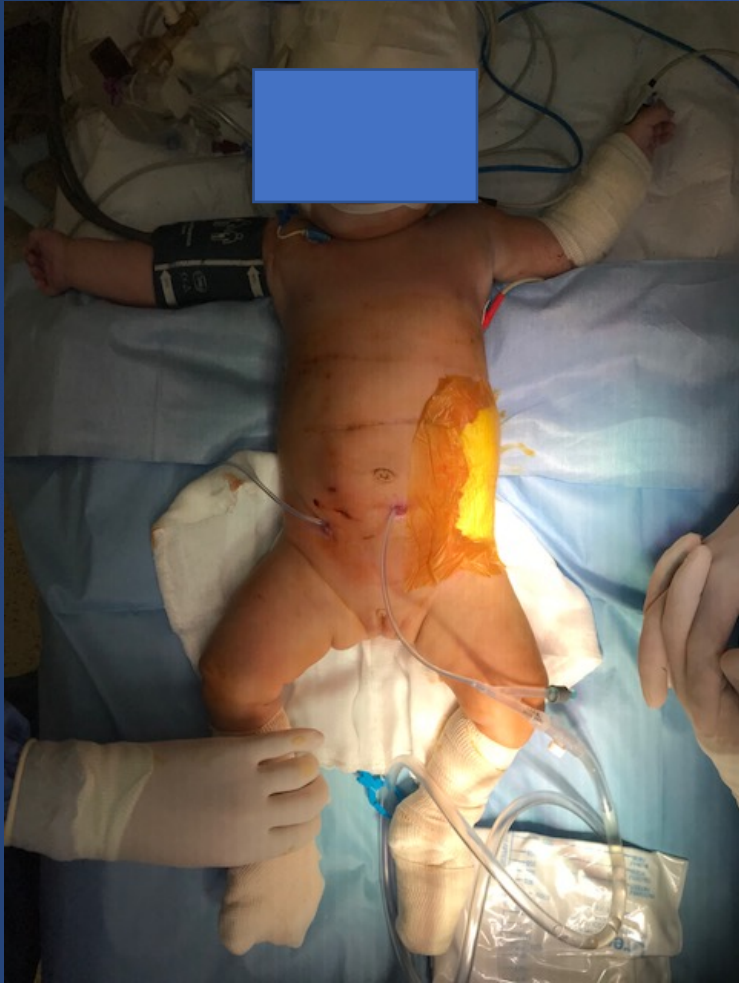
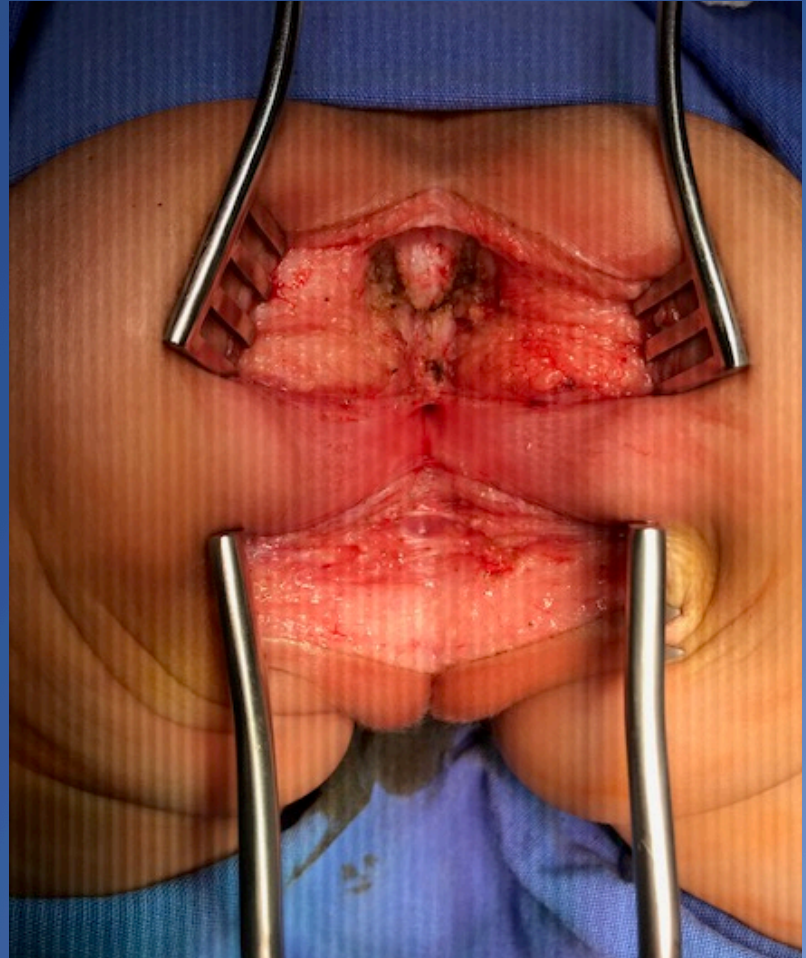


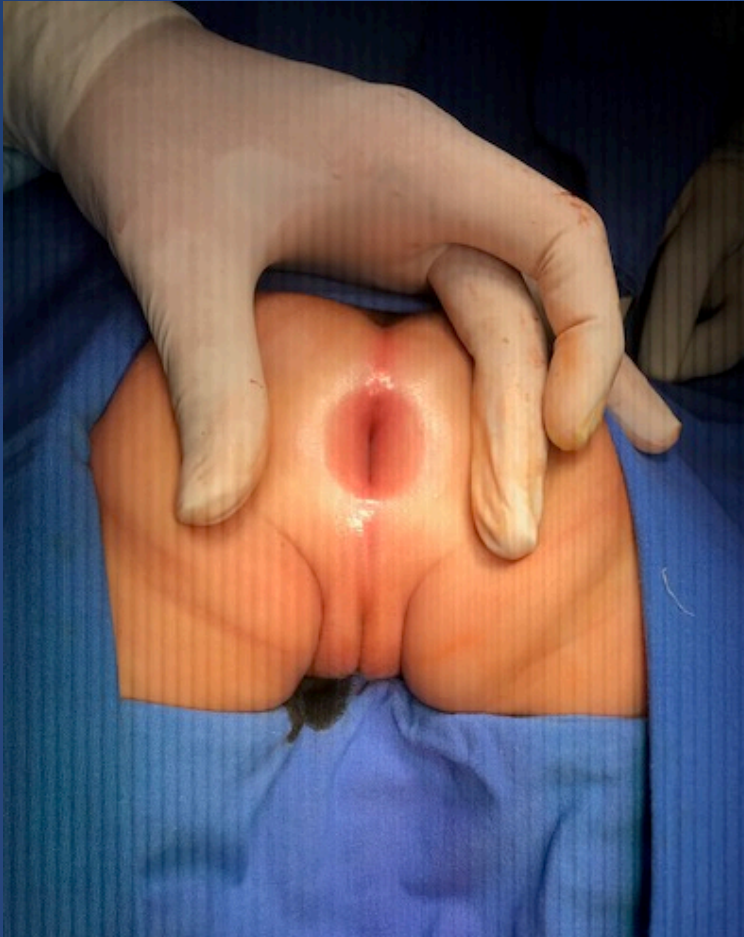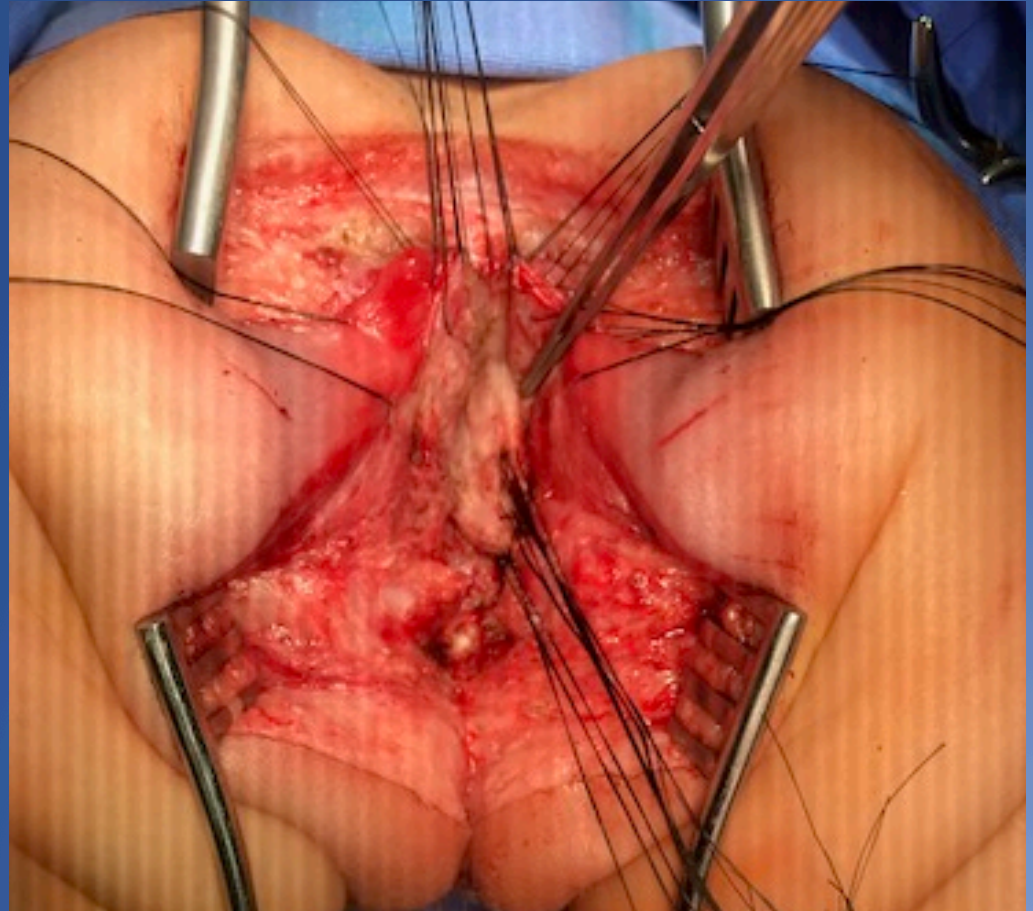
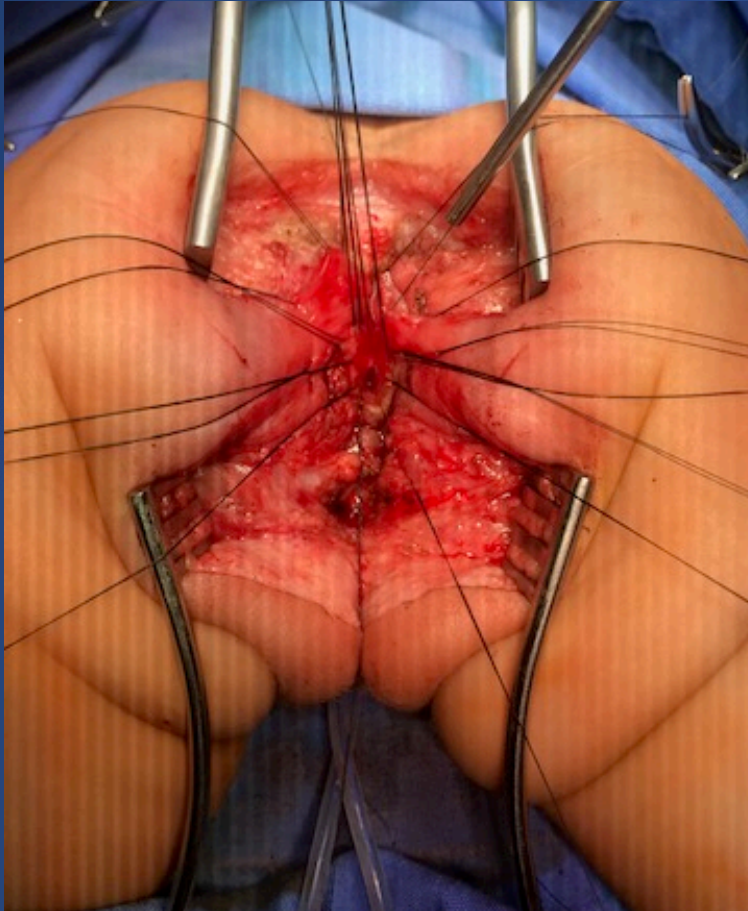What would be your surgical approach?

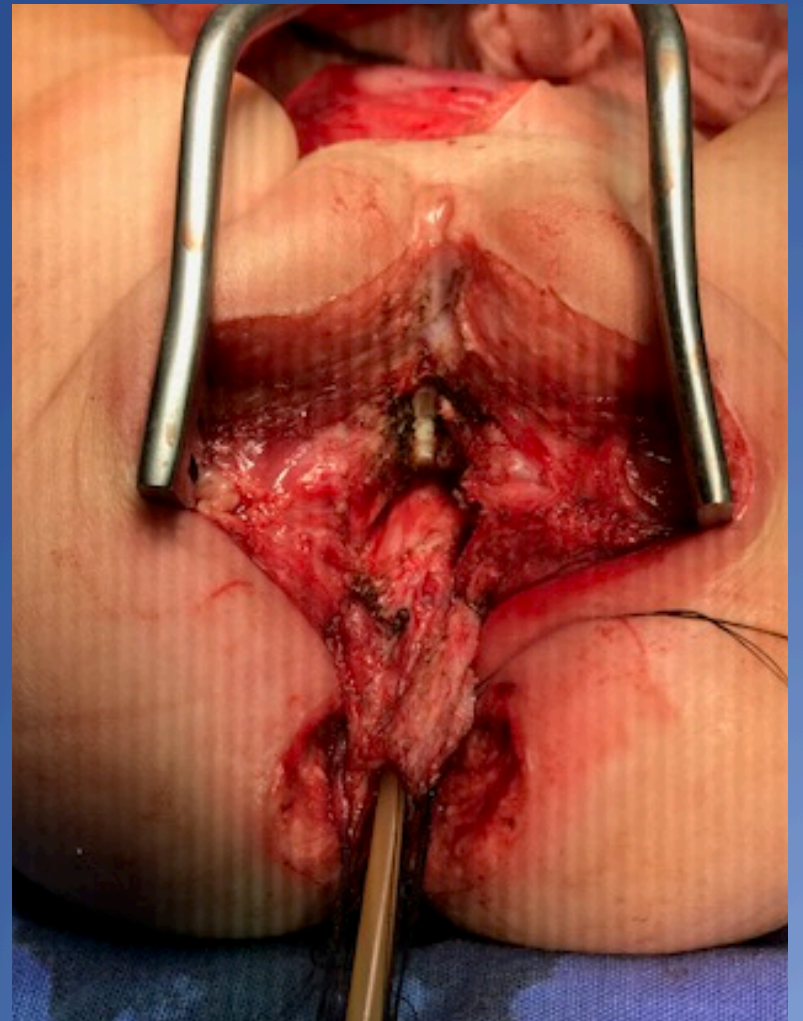
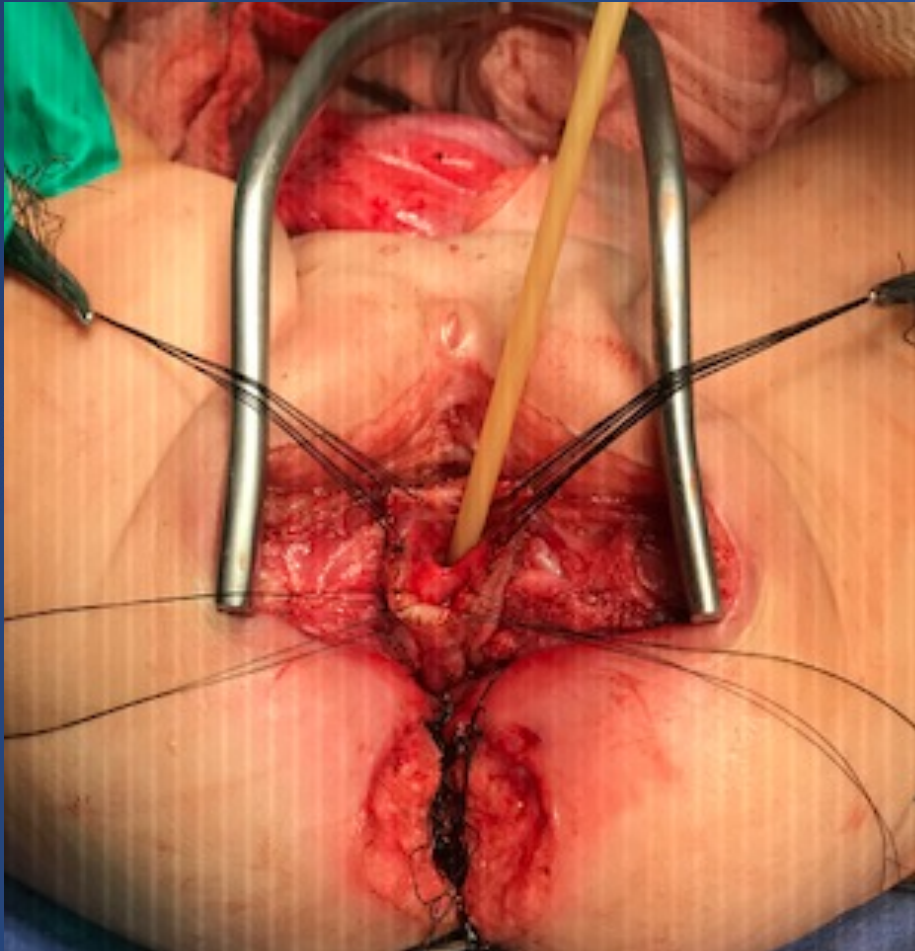
1. Laparotomy + posterior sagittal transanorectal approach + urogenital sinus mobilization
2. Posterior sagittal approach + rectal and urogenital sinus mobilization
3. Vaginal replacement + vesicostomy

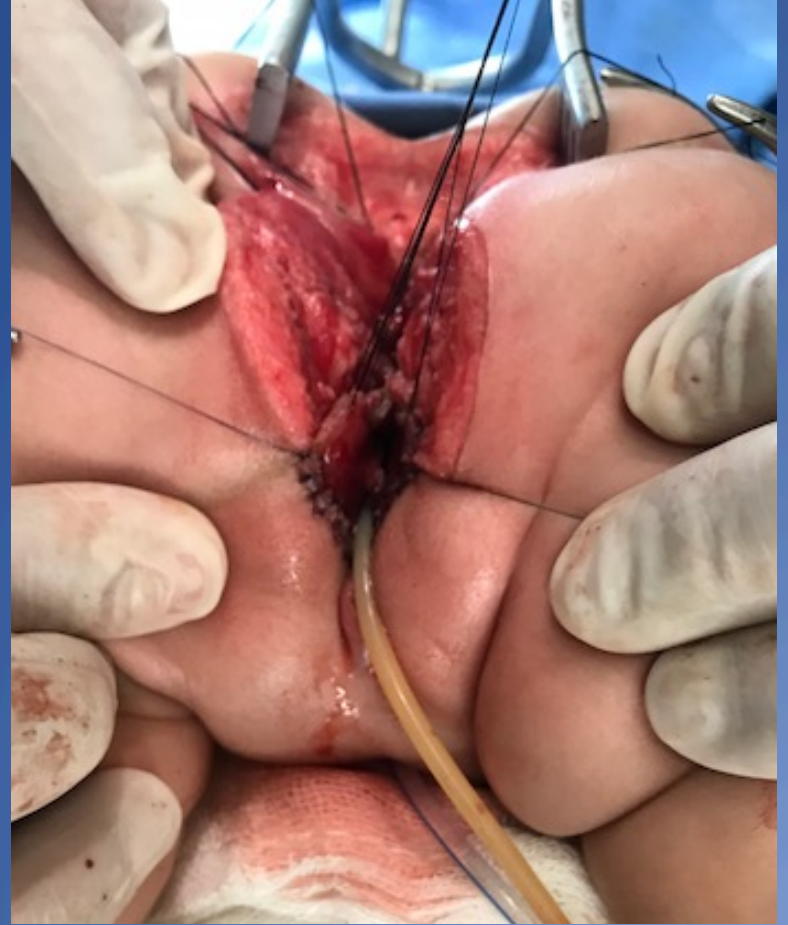
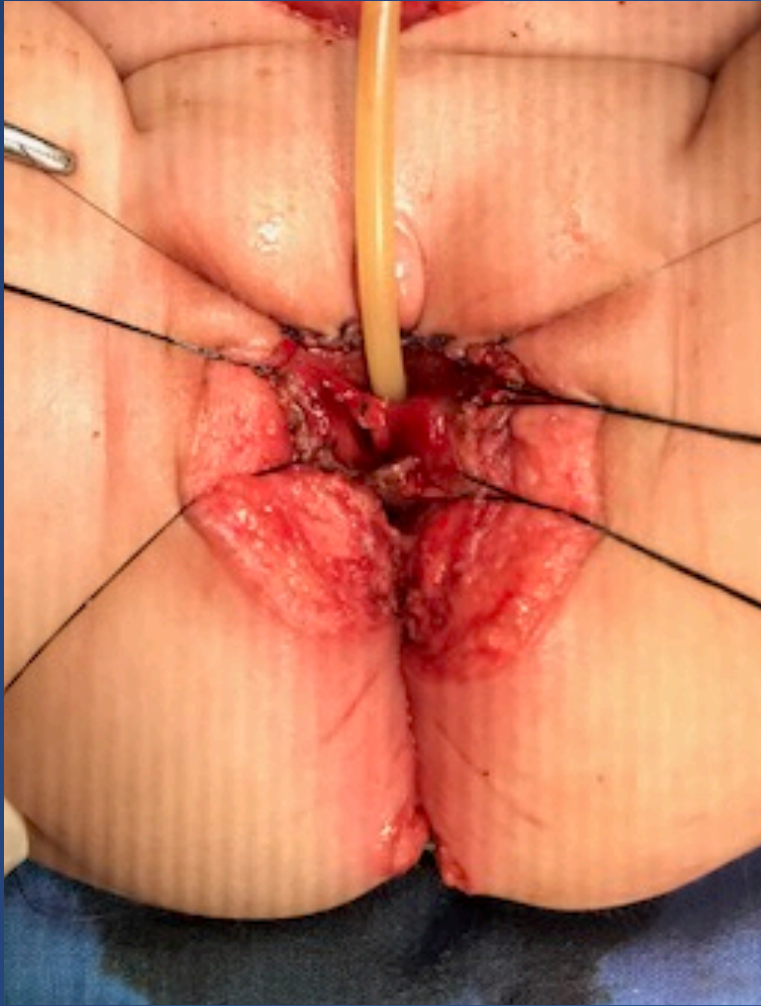


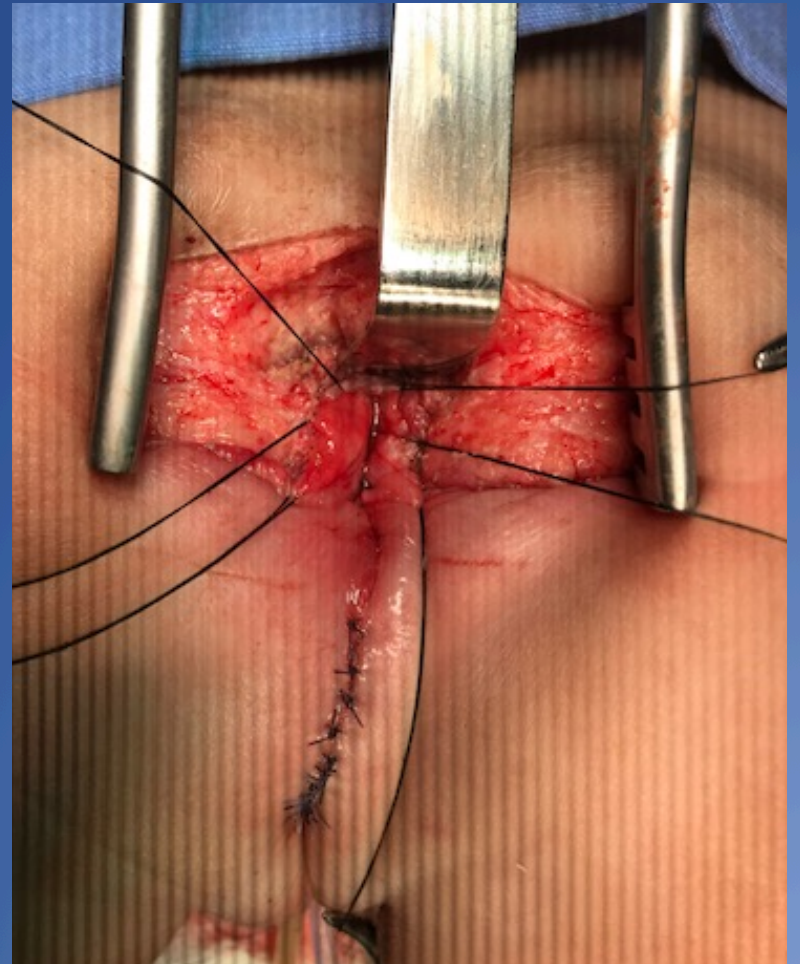
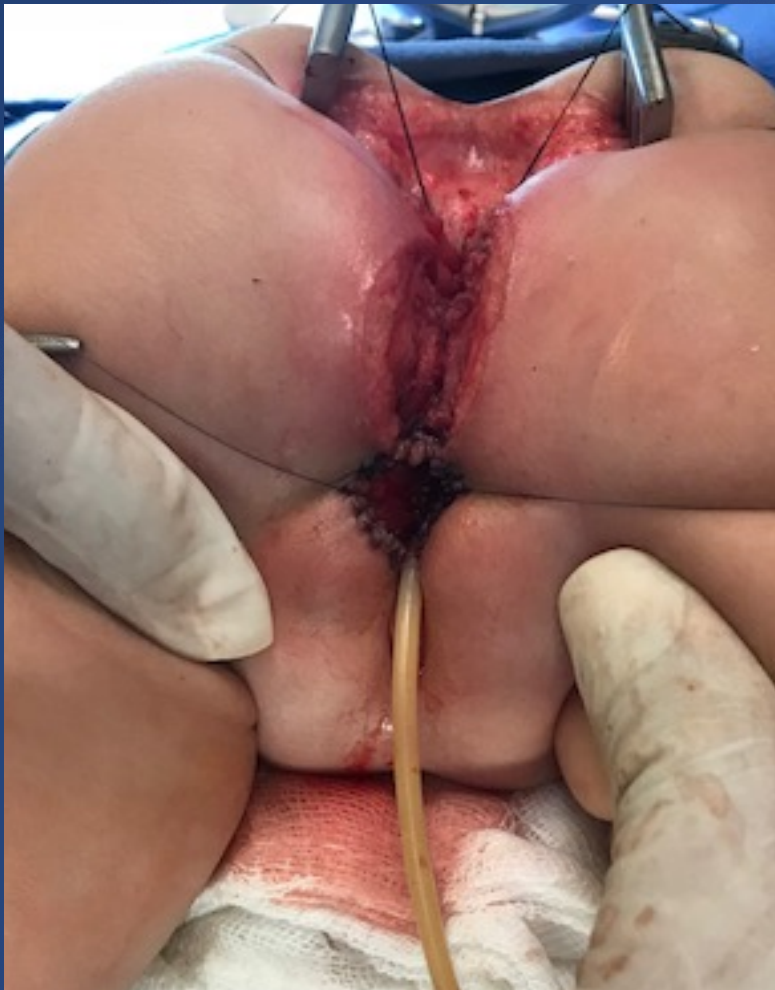











Comments

