



centro **COLORRECTAL** para **NIÑOS**  
**CCN México y Latinoamérica**

Dr. Alejandro Ruíz

Dra. María Zornoza

Dr. Porfirio Rivera

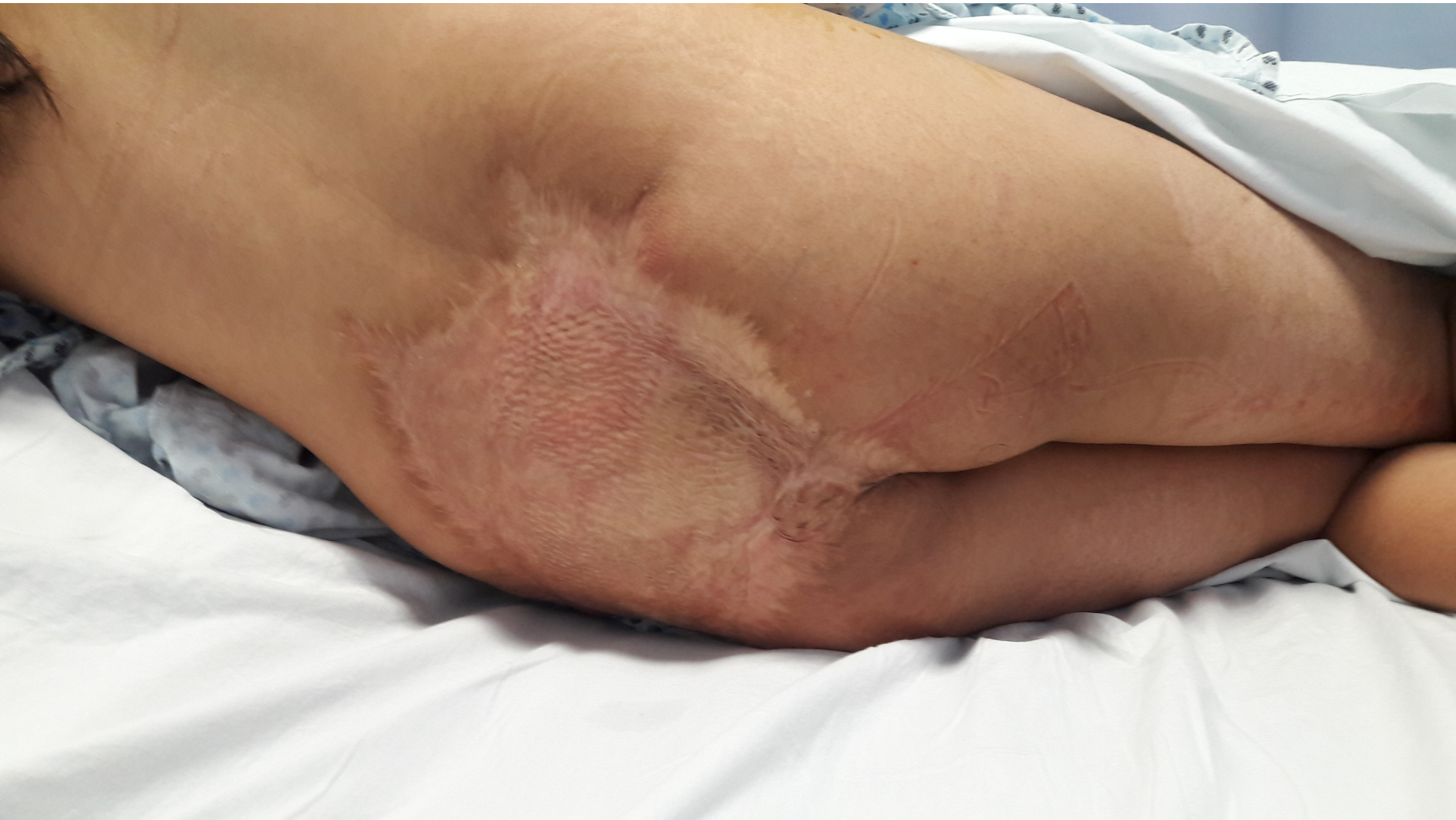

- Female, 18 years old
- DOB: 09.29.1998
  
- Perineal trauma (4 years old)
  - Colostomy
  - Severe pelvic soft tissues damage
  - Colostomy closure
  - Fecal soiling

# Physical examination



centro **COLORRECTAL** para **NIÑOS**











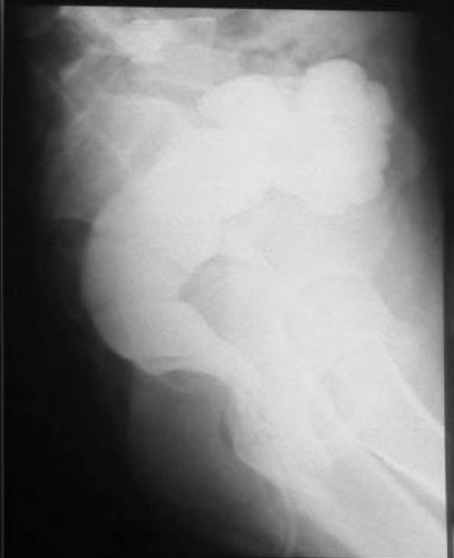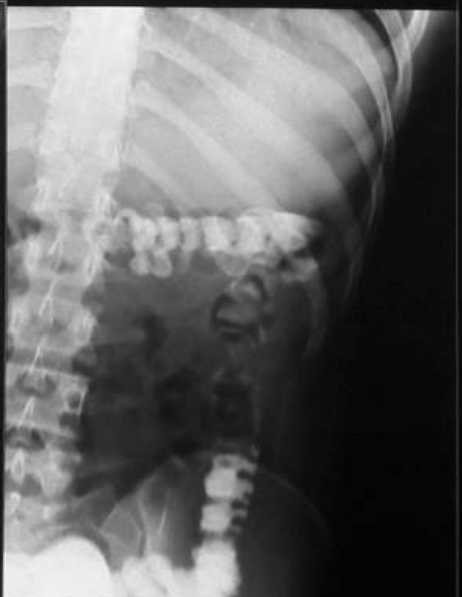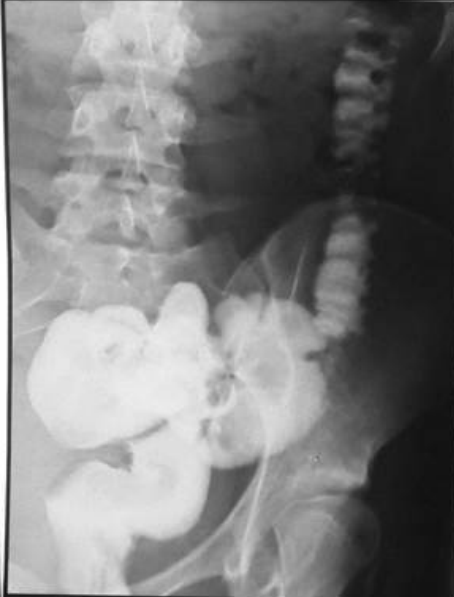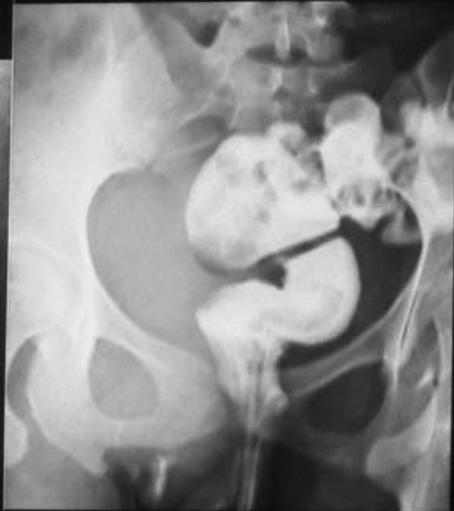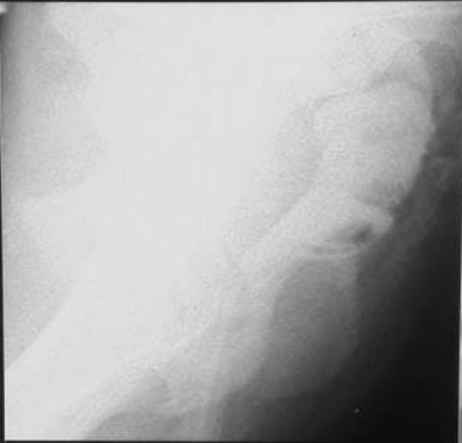
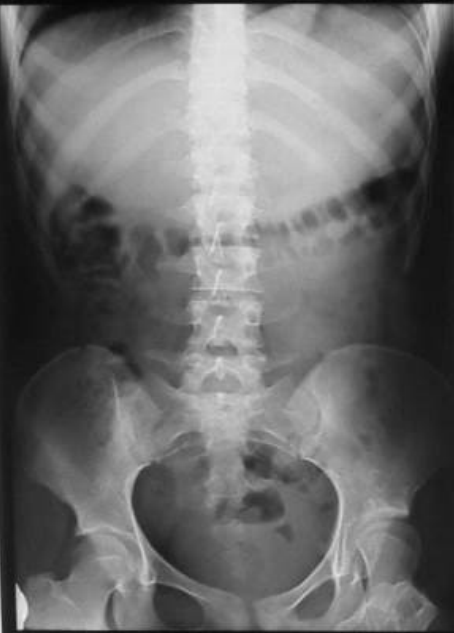# What is your diagnosis?

1. Normal
2. Pseudo-fecal incontinence
3. True fecal incontinence
4. Constipation

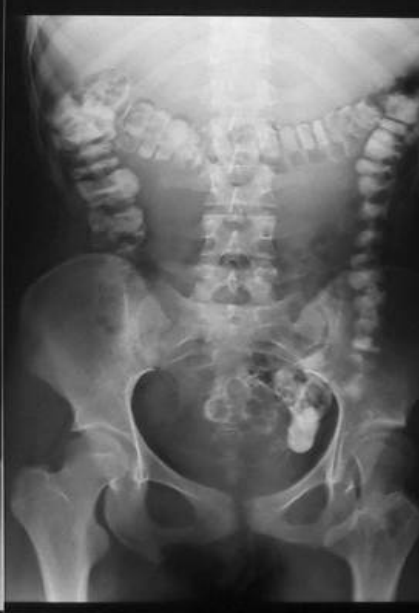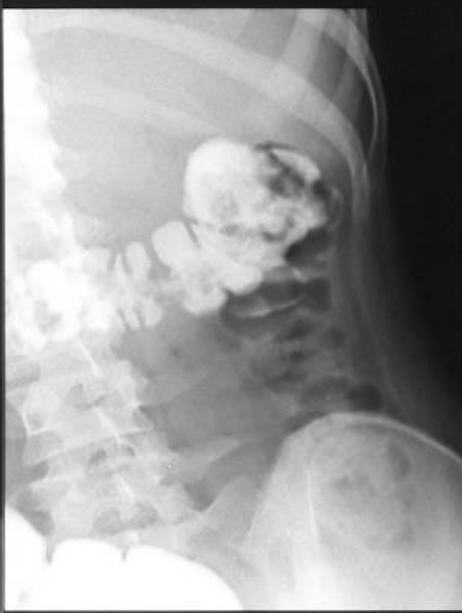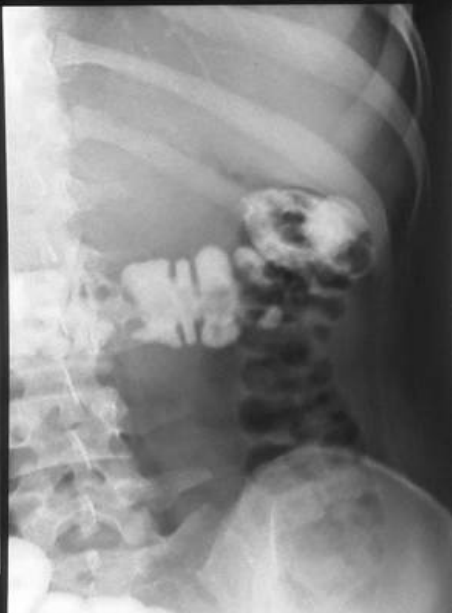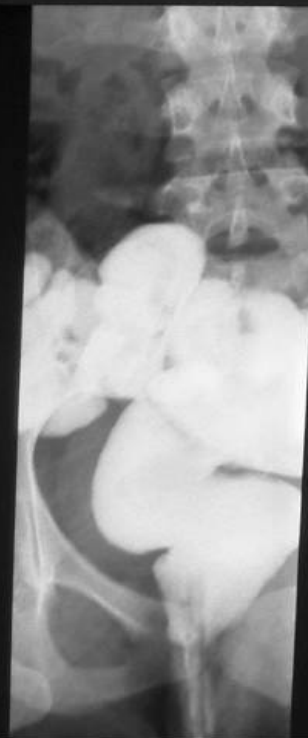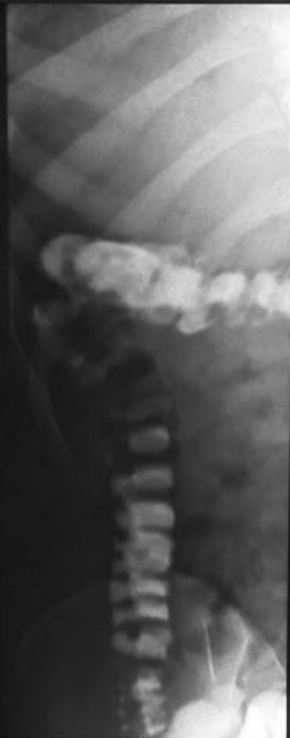


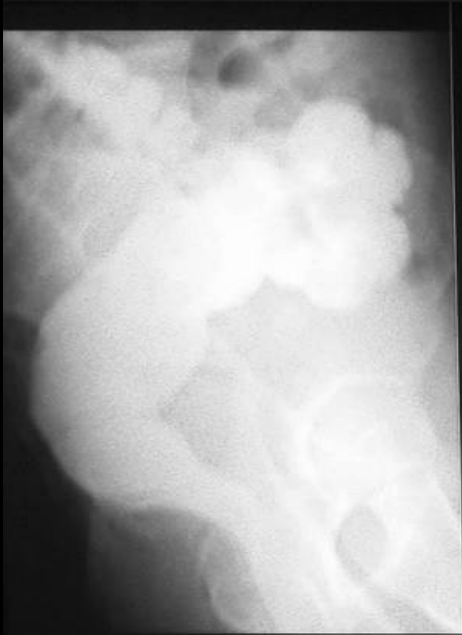# What studies would you order?

1. Colonoscopy
2. Sacral X-ray
3. Contrast enema
4. Manometry
5. Sacral X-ray + contrast enema









# What is your plan of treatment?

1. Colostomy
2. Ileostomy
3. Malone
4. Bowel management program

# Bowel management program



centro **COLORRECTAL** para NIÑOS

Enemas 300-30-20  
Loperamide 2-2-2mg

# Bowel management program



centro **COLORRECTAL** para **NIÑOS**

Successful for 4  
months



Contents lists available at [ScienceDirect](#)

## Journal of Pediatric Surgery

journal homepage: [www.elsevier.com/locate/jped surg](http://www.elsevier.com/locate/jped surg)



### Operative Techniques

## New surgical technique for creation of a continent appendicostomy: Invaginated appendicostomy

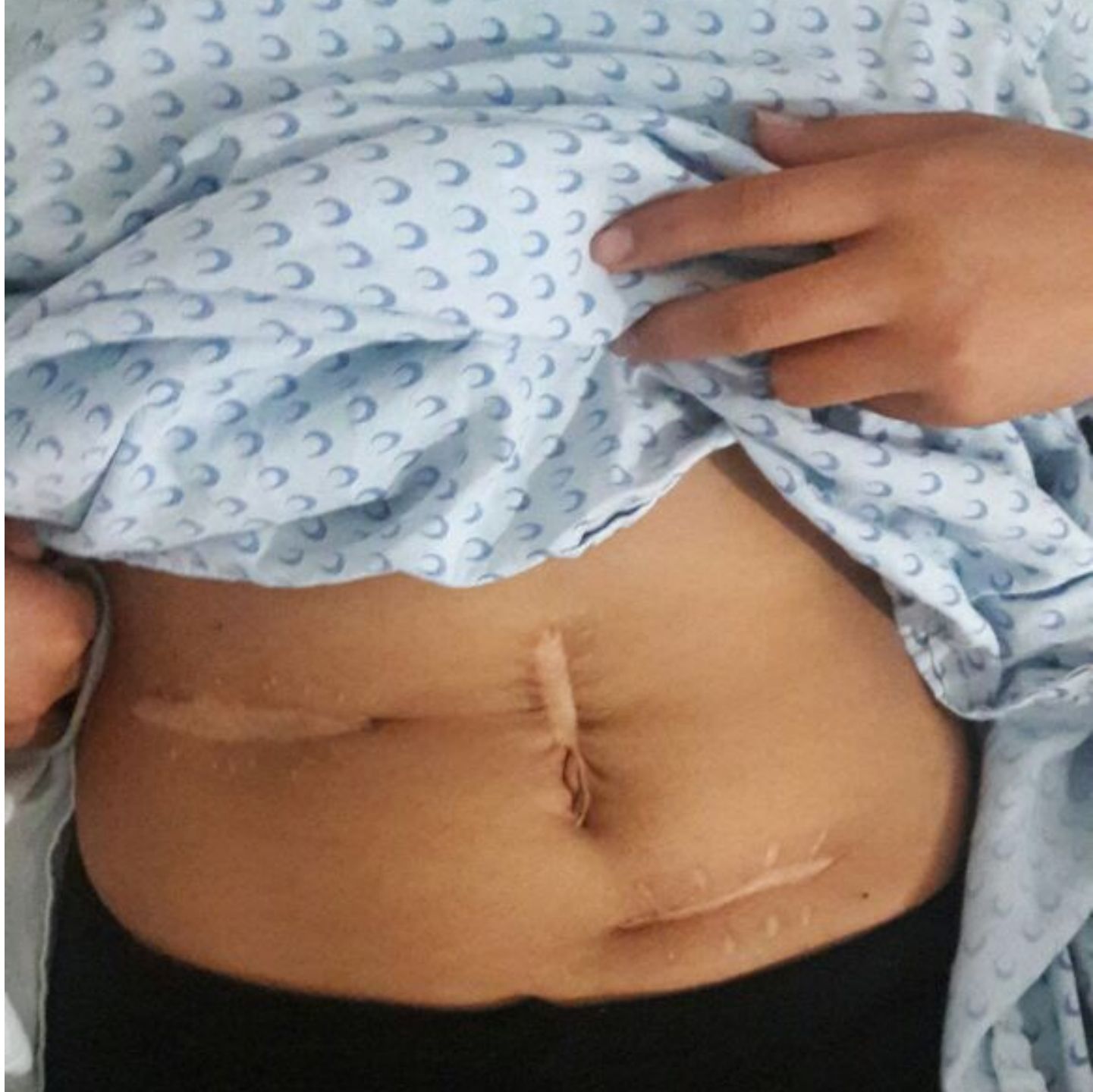Maria Zornoza <sup>a,\*</sup>, Alejandro Ruiz-Montañez <sup>a</sup>, Guillermo Victoria-Morales <sup>b</sup>, Luis De la Torre-Mondragón <sup>c</sup>

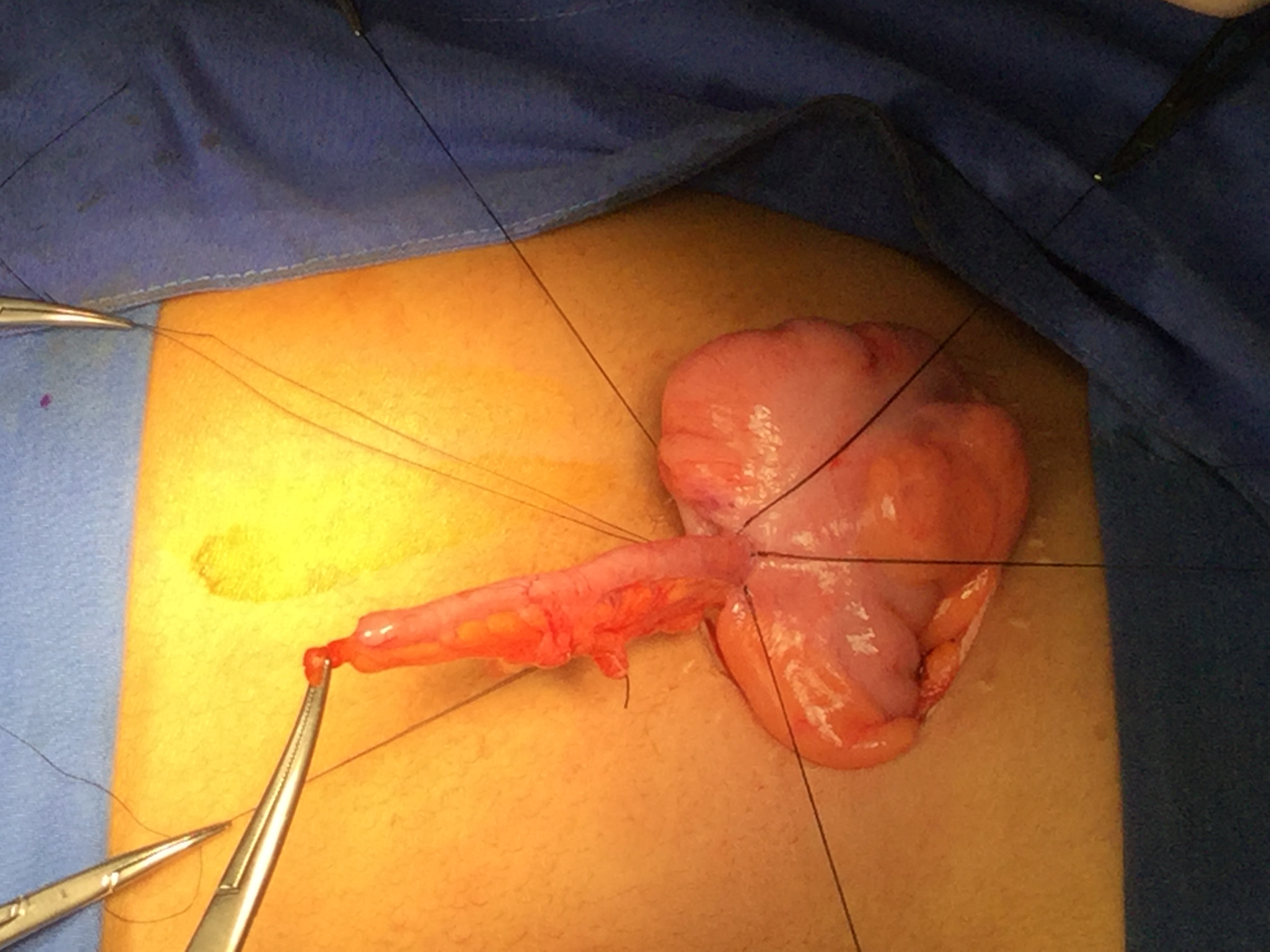
<sup>a</sup> Centro Colorrectal para Niños de México, Hospital Ángeles Puebla, Avenida Kepler 2143-530, Puebla, Mexico, 72190

<sup>b</sup> Hospital para el Niño Poblano, Boulevard del Niño Poblano 5307, Puebla, Mexico 72190

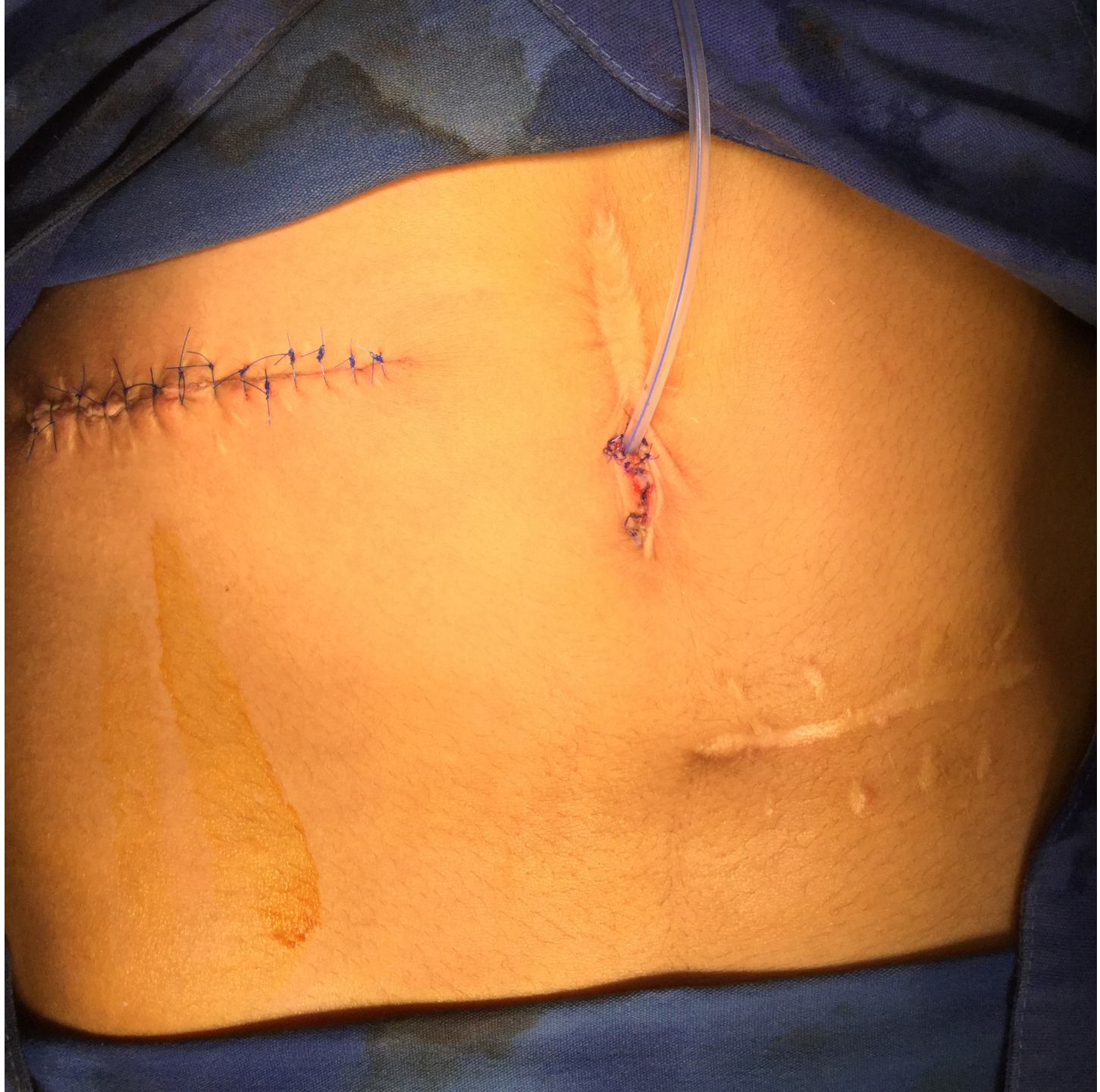<sup>c</sup> Colorectal Center for Children of Children's Hospital Pittsburgh of UPMC, Children's Hospital of Pittsburgh of UPMC, One Children's Hospital Drive 4401 Penn Avenue, Pittsburgh, PA 15224, USA













centro **COLORRECTAL** para **NIÑOS**

Thank you very much