

Case # 3

Andrea Bischoff, MD

05/17/2018

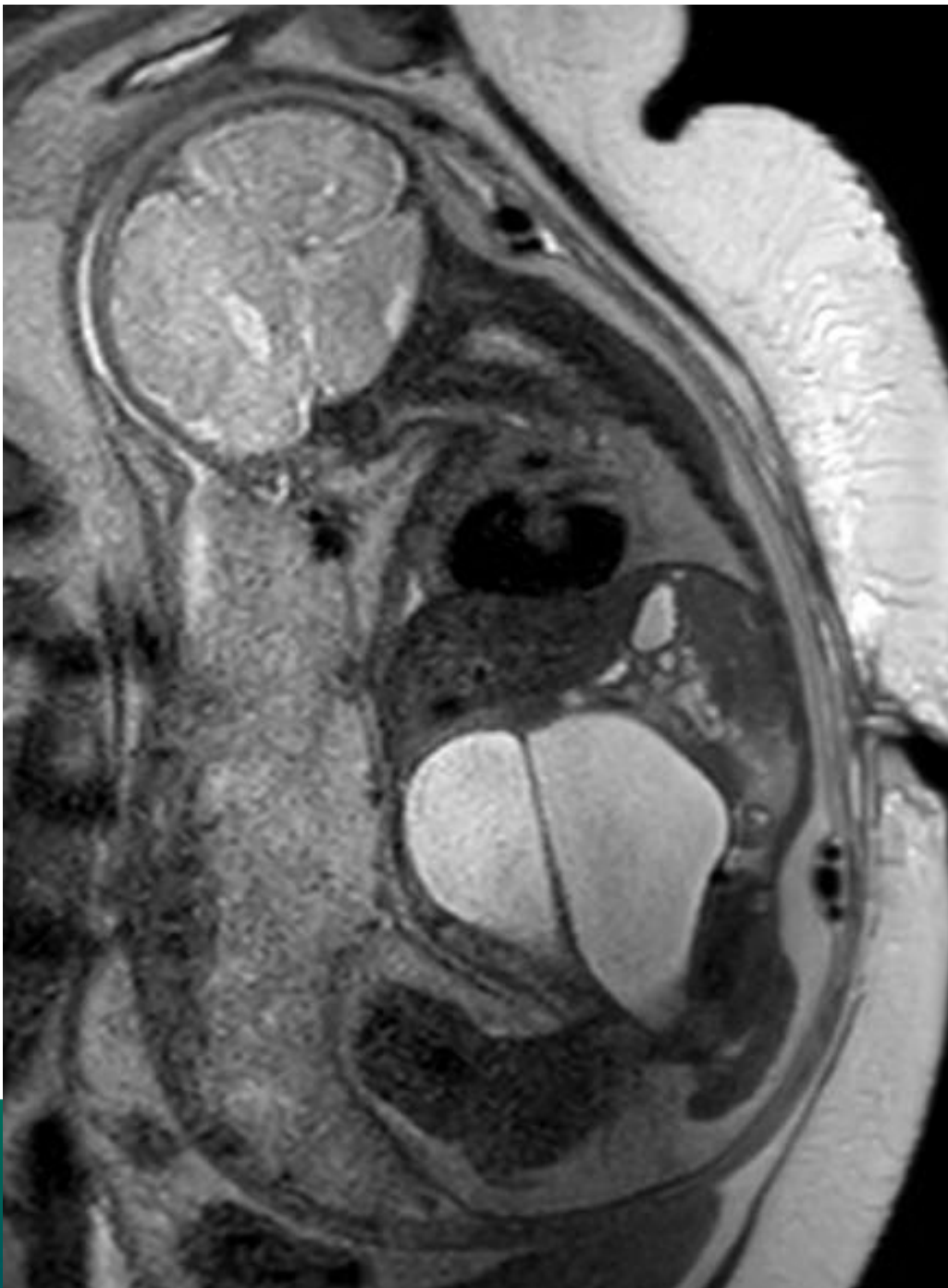


Children's Hospital Colorado

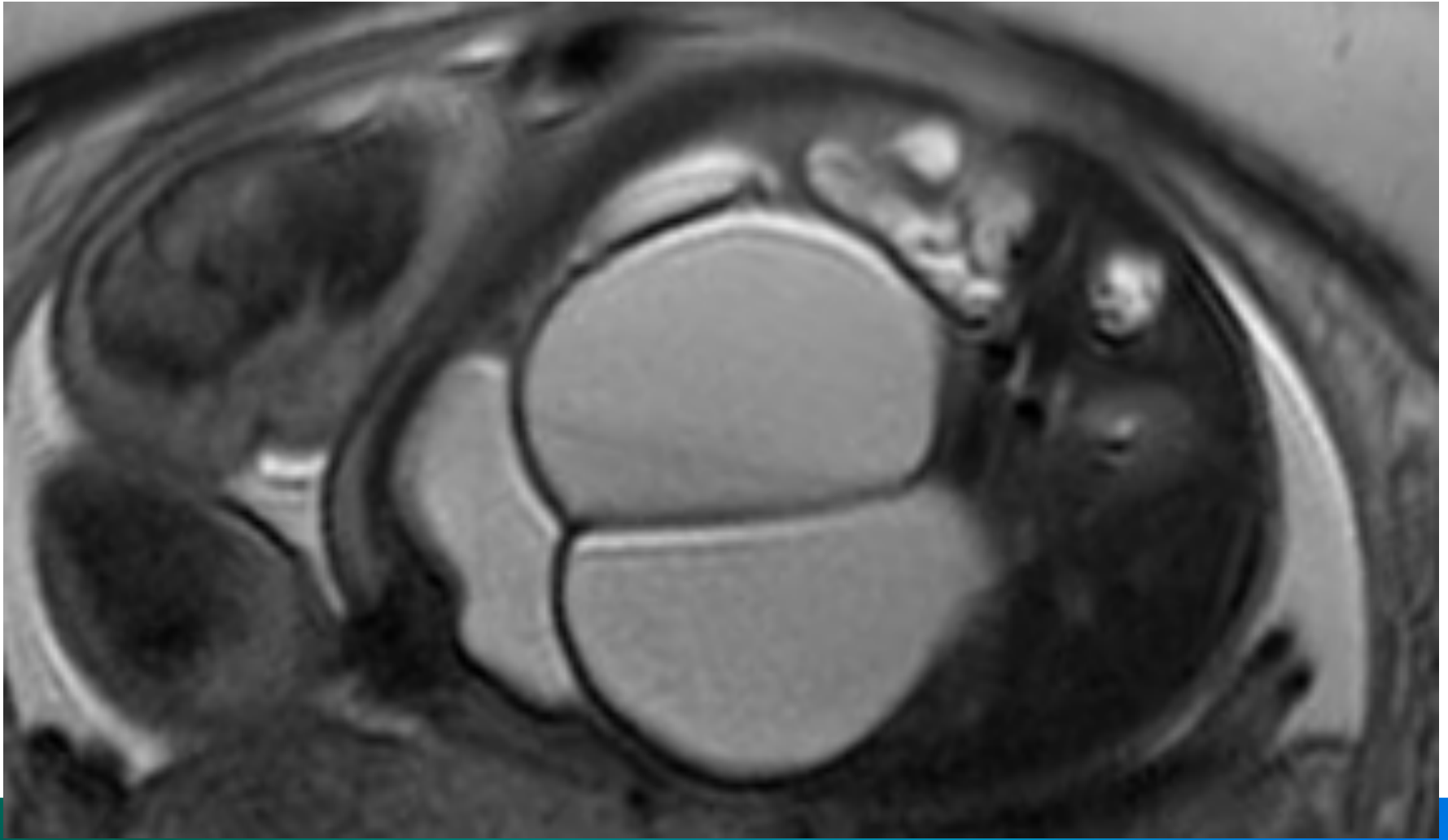
INTERNATIONAL CENTER FOR
**COLORECTAL AND
UROGENITAL CARE**



- Fetal consultation



INTERNATIONAL CENTER FOR
**COLORECTAL AND
UROGENITAL CARE**



INTERNATIONAL CENTER FOR
**COLORECTAL AND
UROGENITAL CARE**

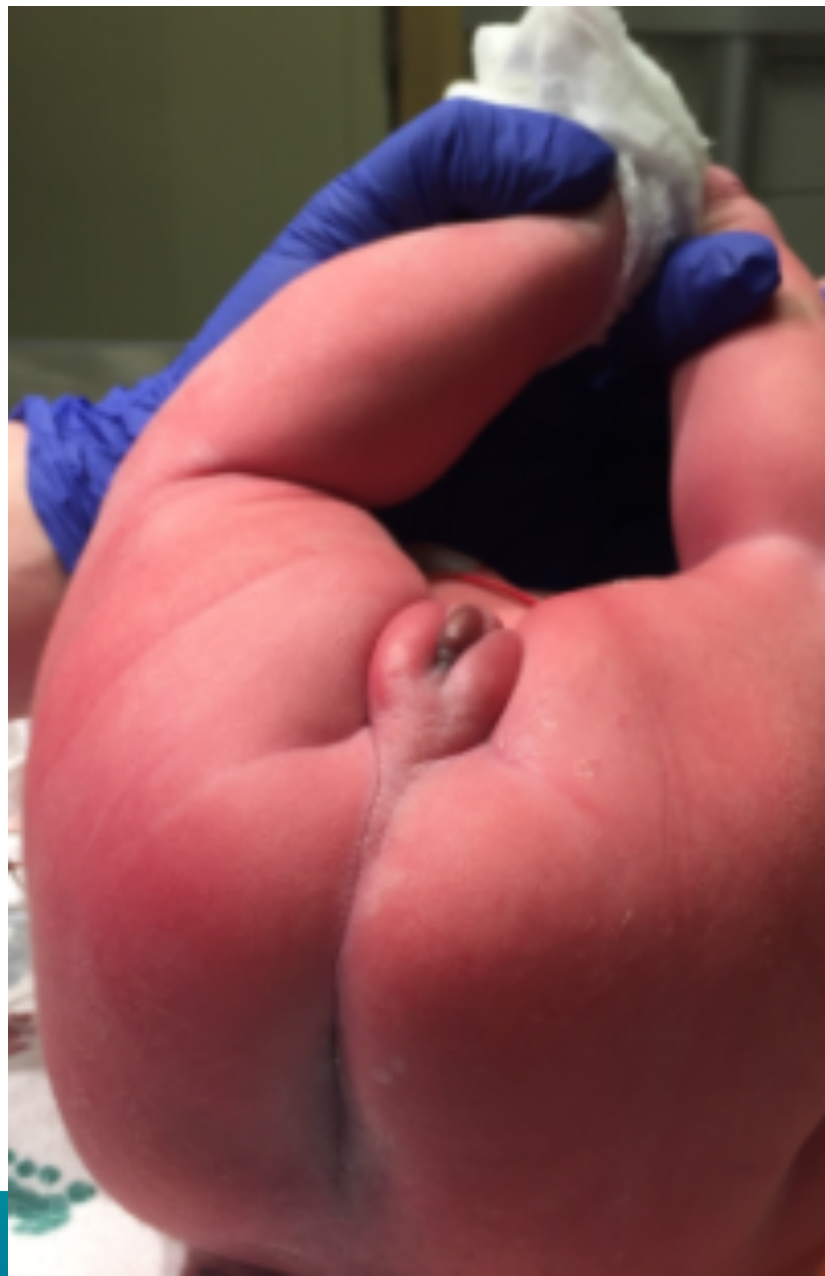
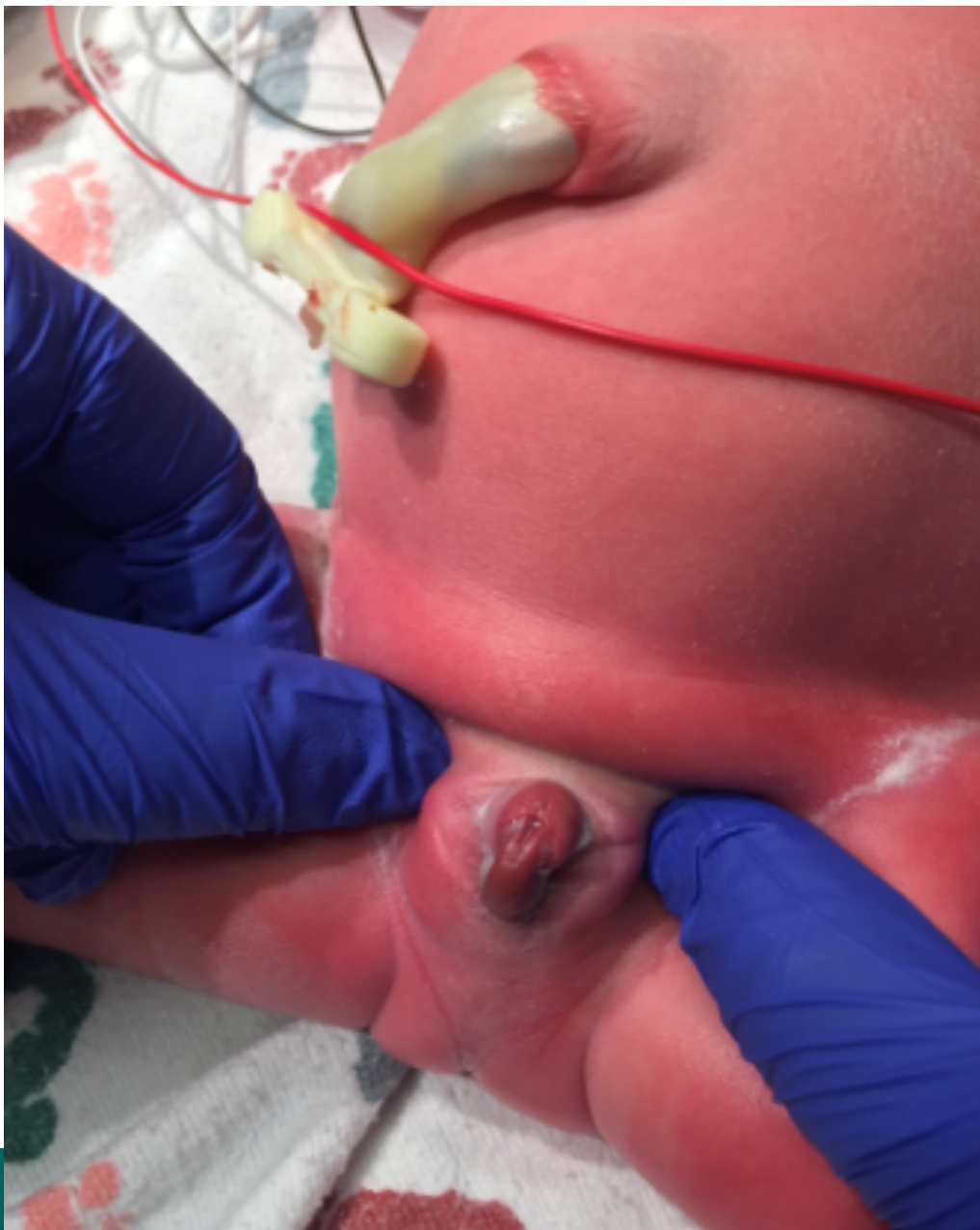
INTERNATIONAL CENTER FOR
**COLORECTAL AND
UROGENITAL CARE**

What is the diagnosis?



1. I need more information
2. Ovarian cyst
3. Bladder duplication
4. Urogenital sinus
5. Cloaca
6. I don't know




**COLORECTAL AND
UROGENITAL CARE**



Does this patient need karyotype due to ambiguous genitalia?

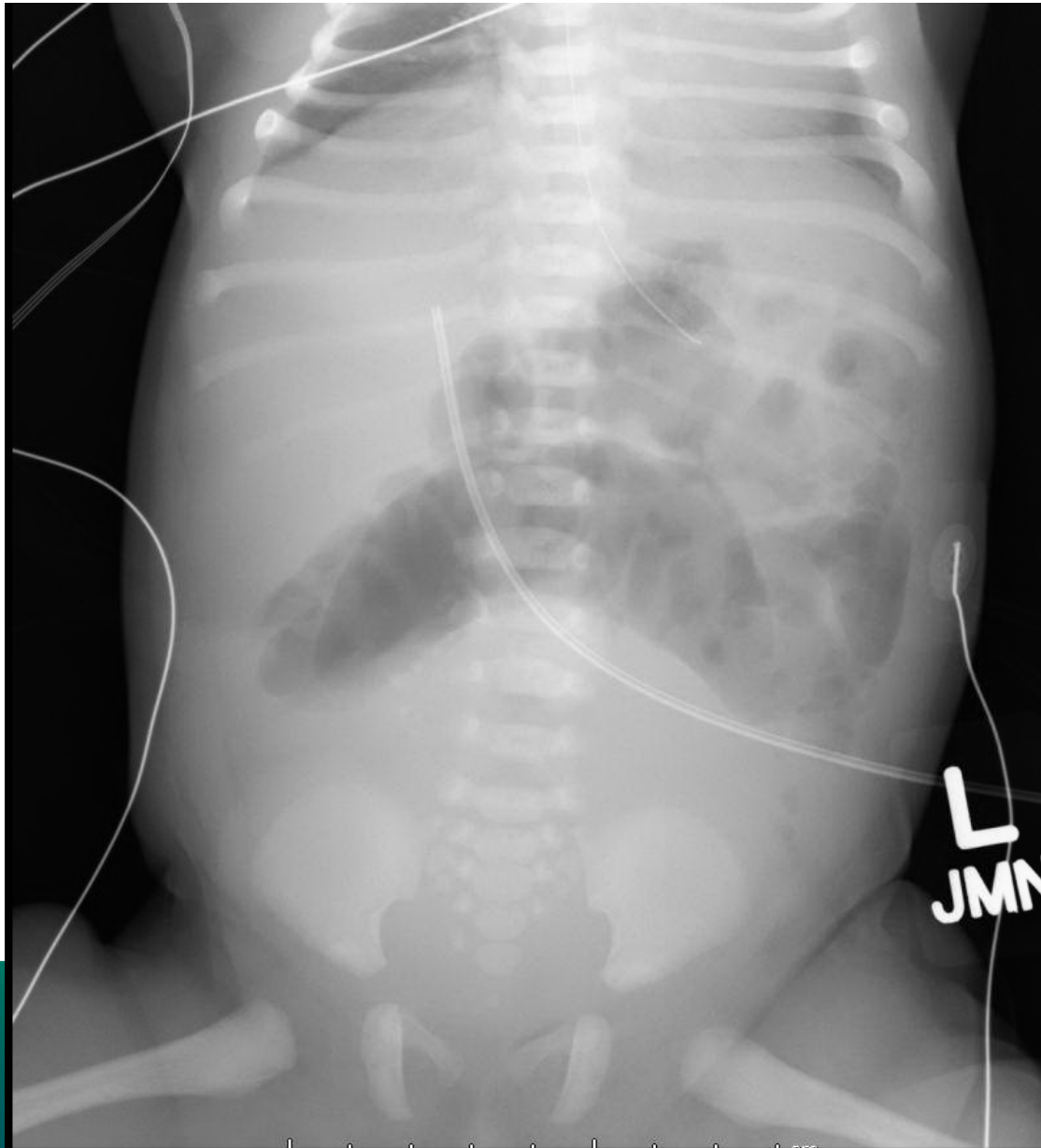
1. Yes
2. No
3. I don't know

Which studies would you order during the first 24 hours of life?



1. Sacral X-ray AP and lateral
2. Spinal ultrasound
3. Kidney and pelvic ultrasound
4. Echocardiogram
5. I don't know

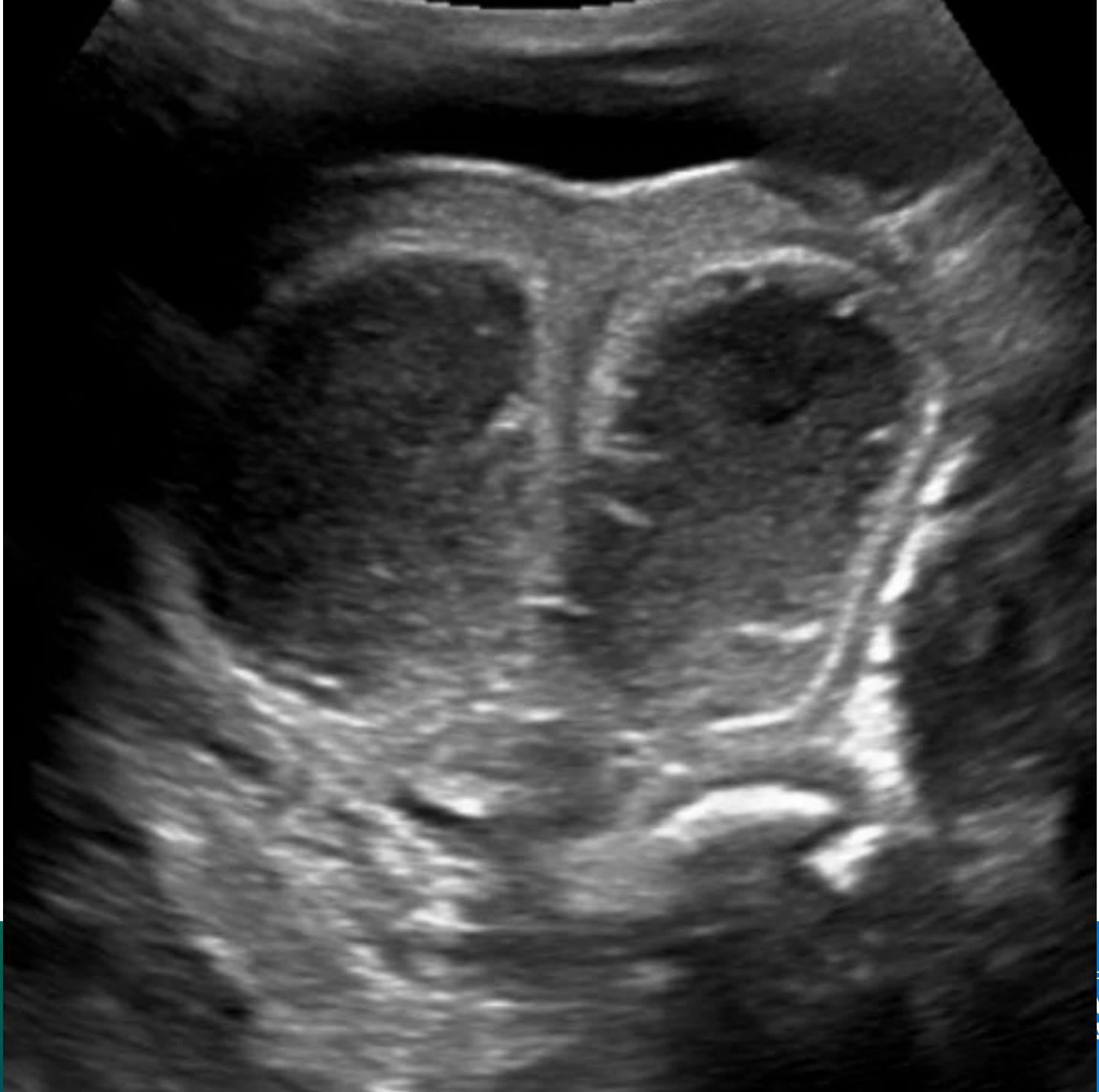What do you see in this image?



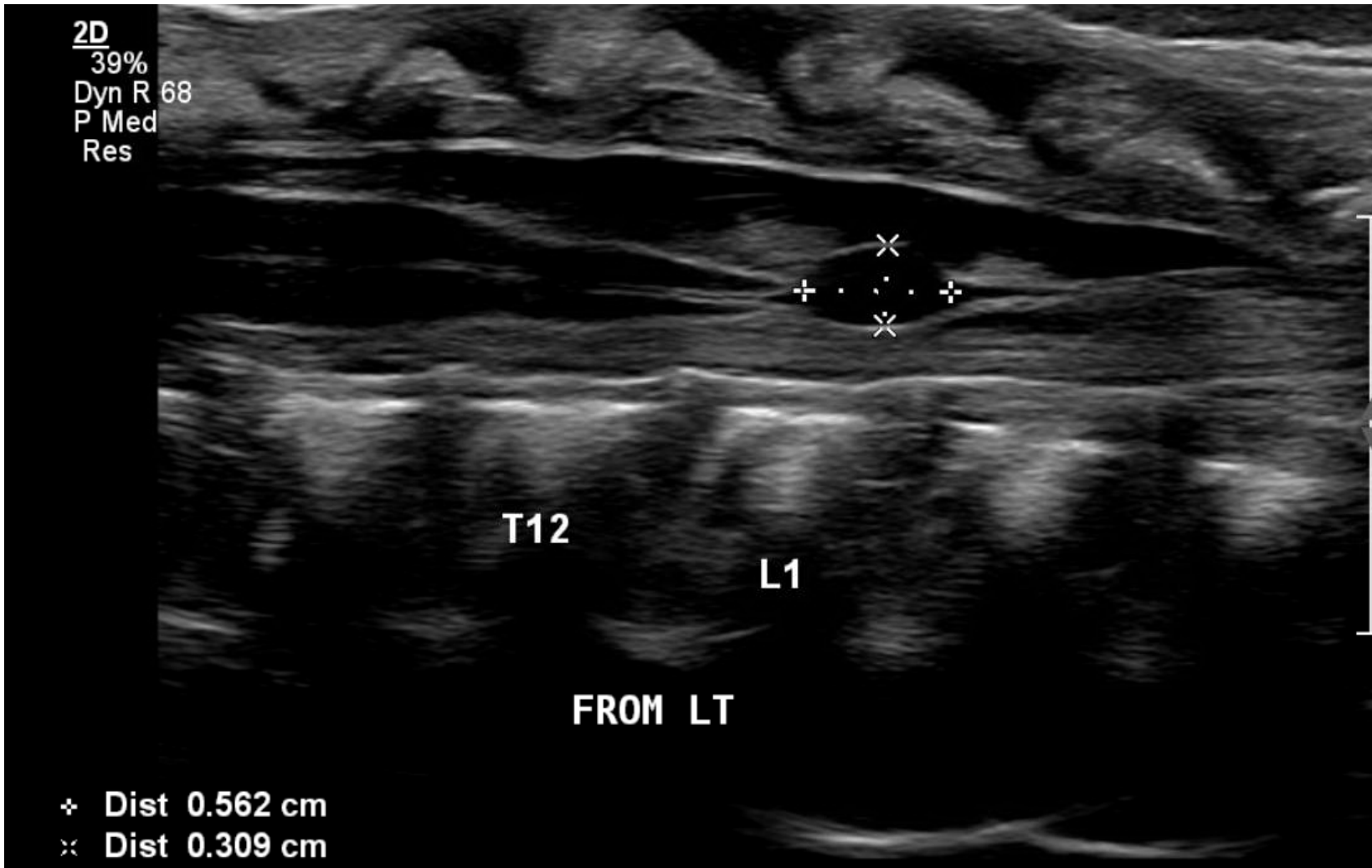


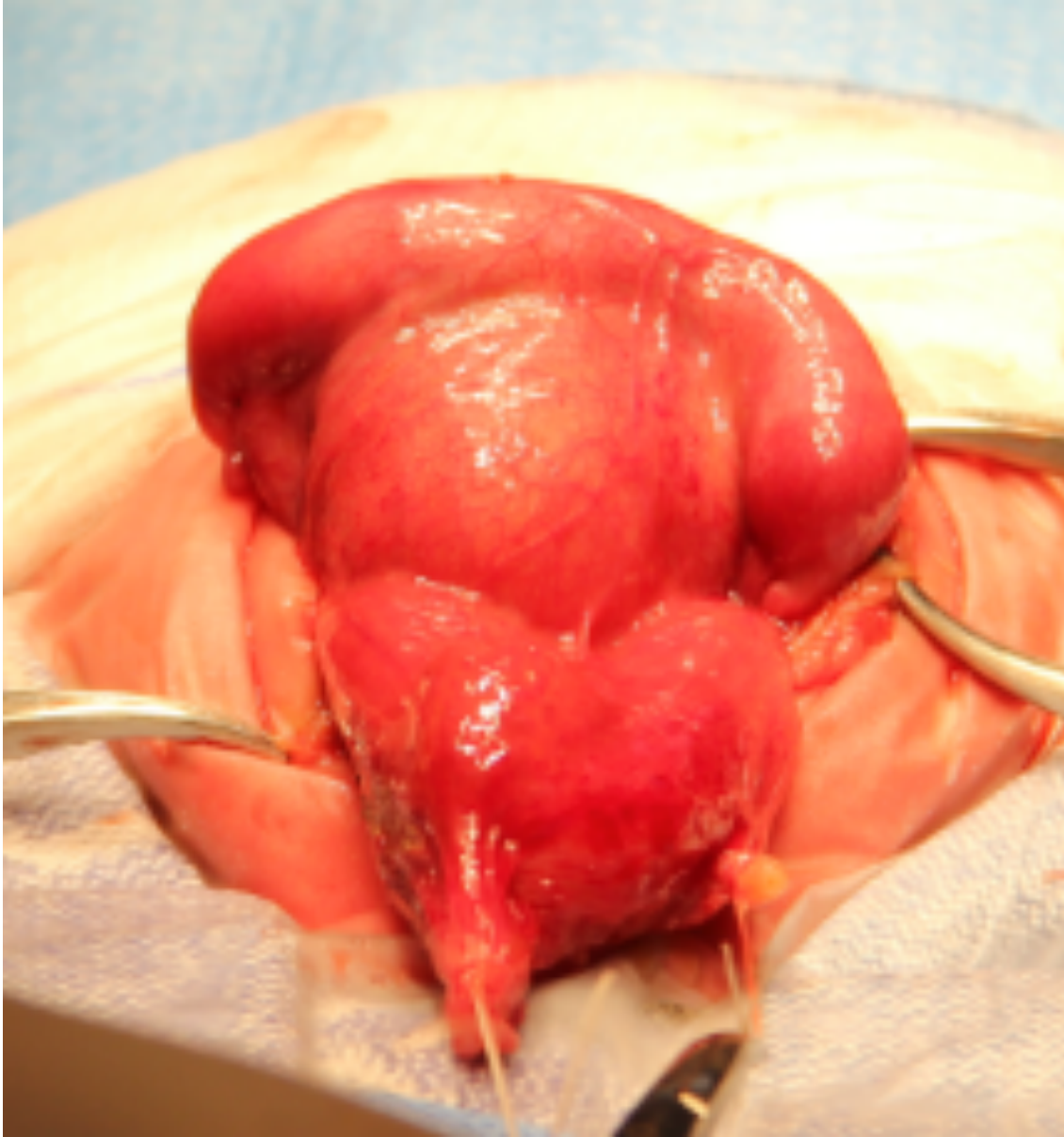
What do you see in this image?

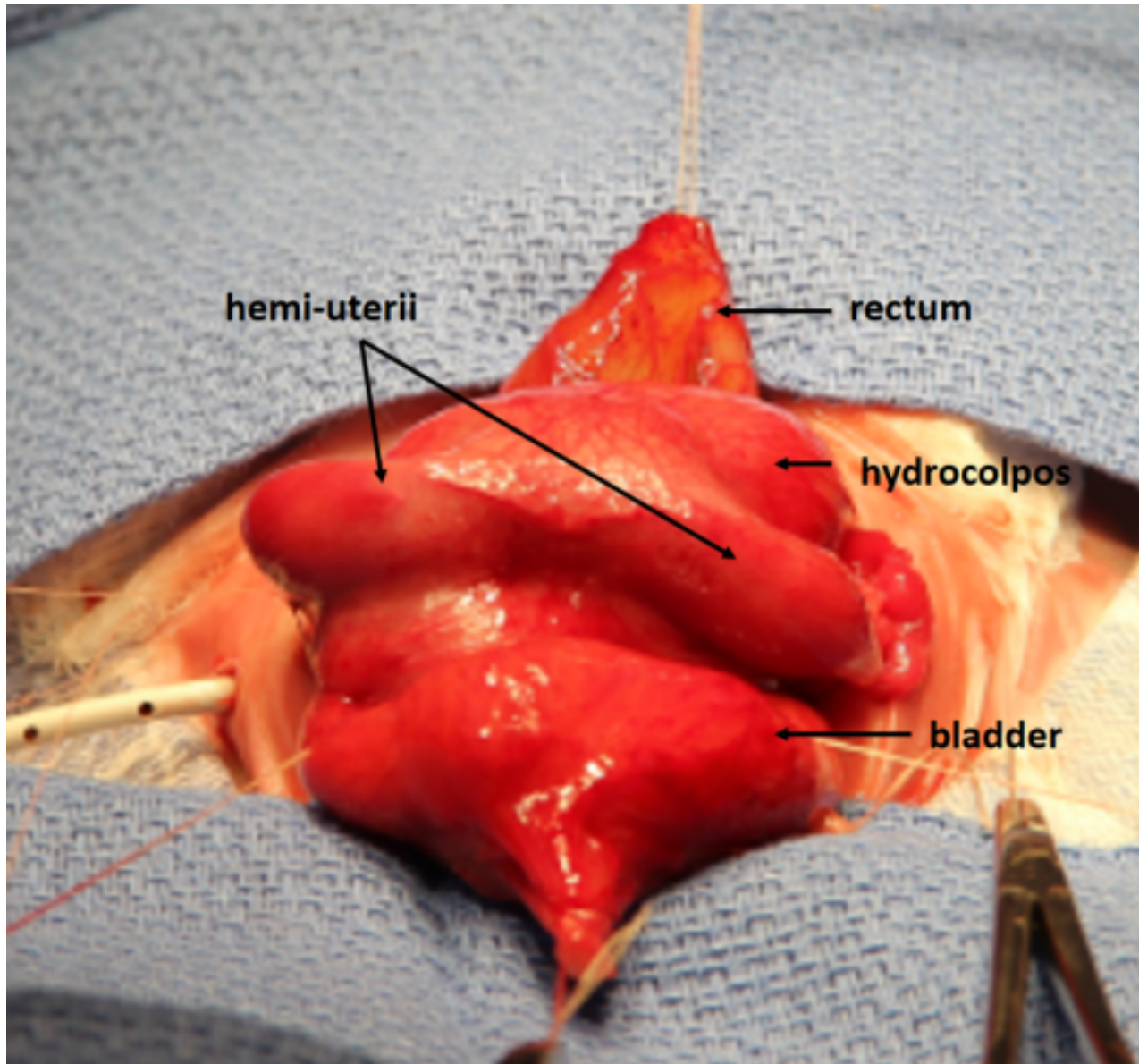
1. Distended bladder
2. Hydrocolpos, until proven otherwise
3. Malrotation
4. I don't know

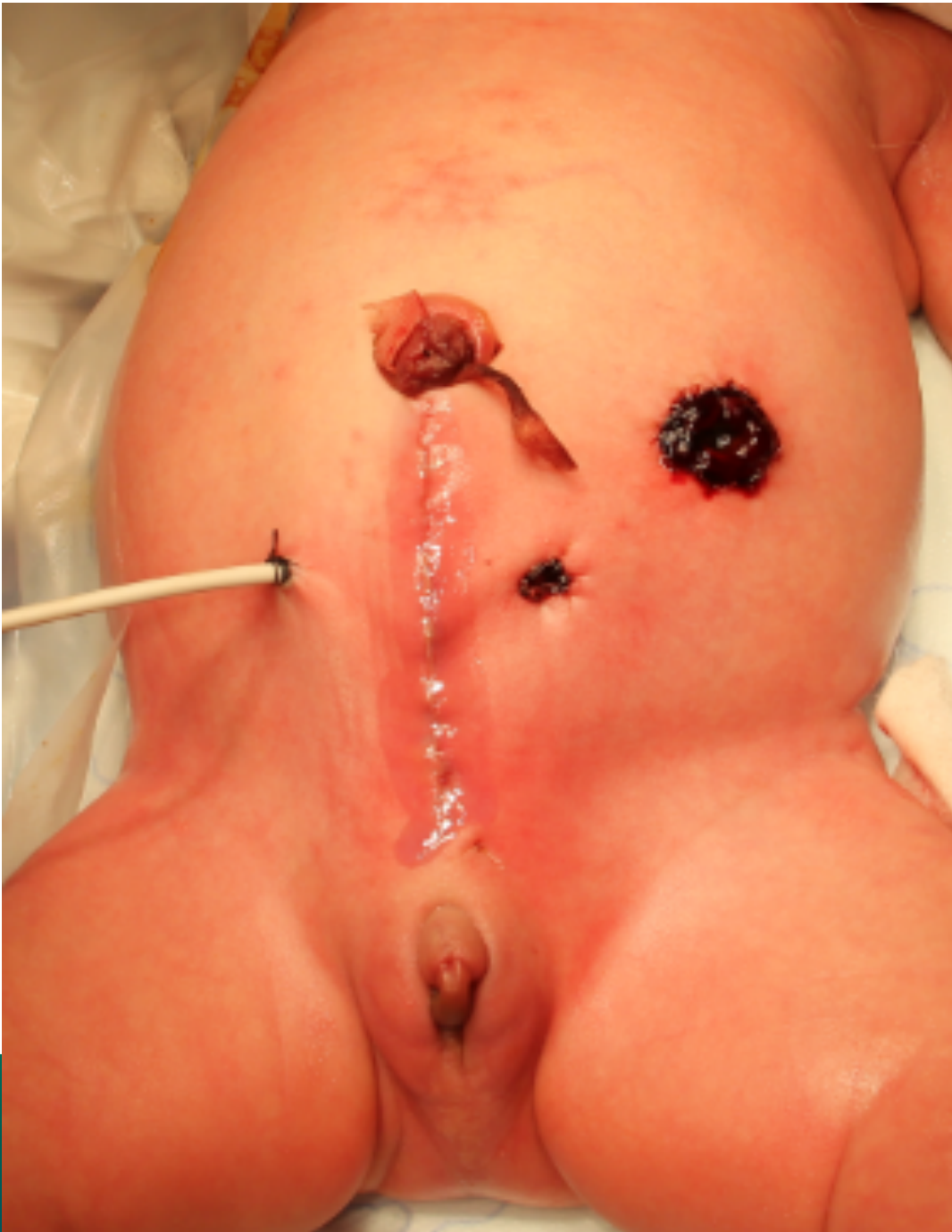

R FOR
AND
ARE









INTERNATIONAL CENTER FOR
**COLORECTAL AND
UROGENITAL CARE**