

# Discussion # 4

Alberto Peña, MD

---

05/17/2018



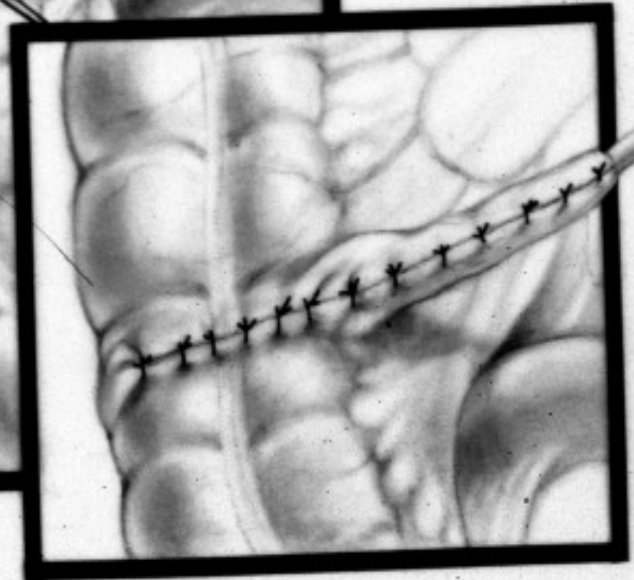
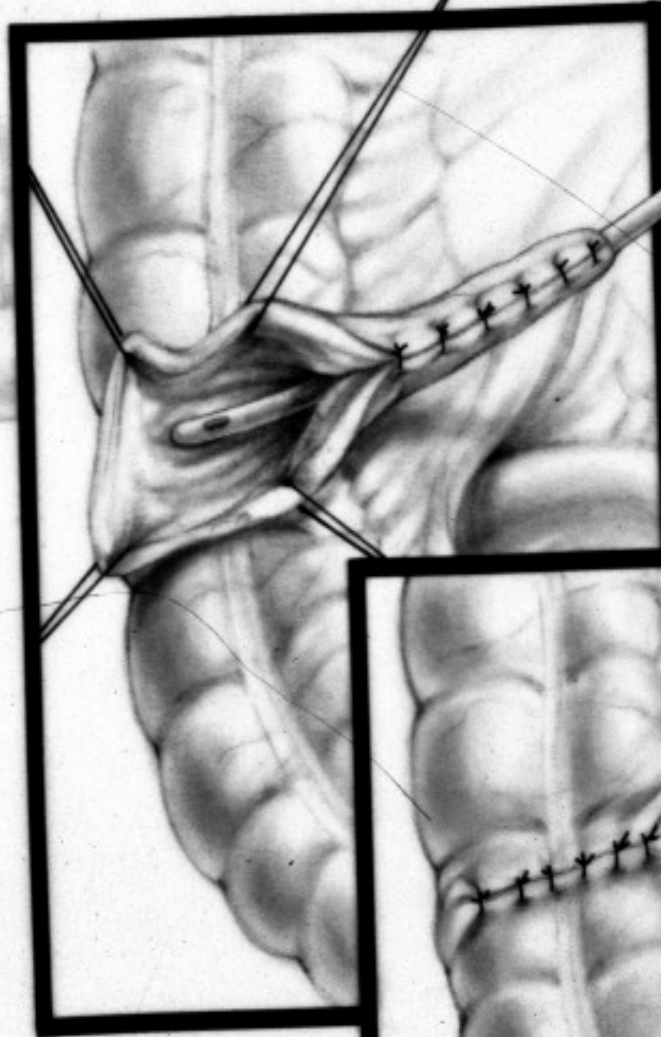
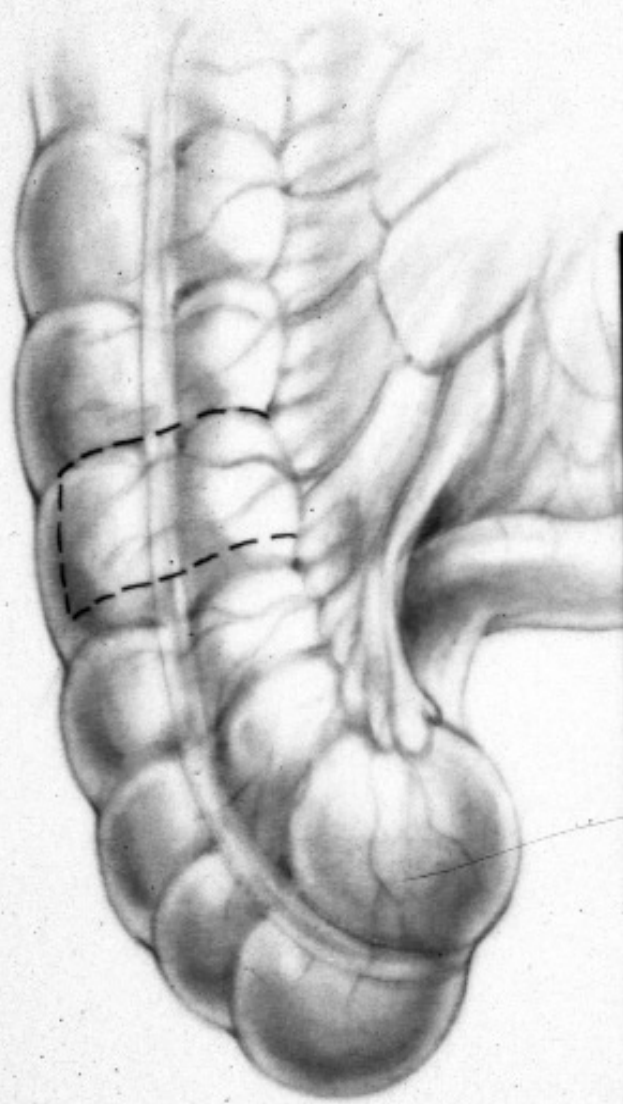
Children's Hospital Colorado

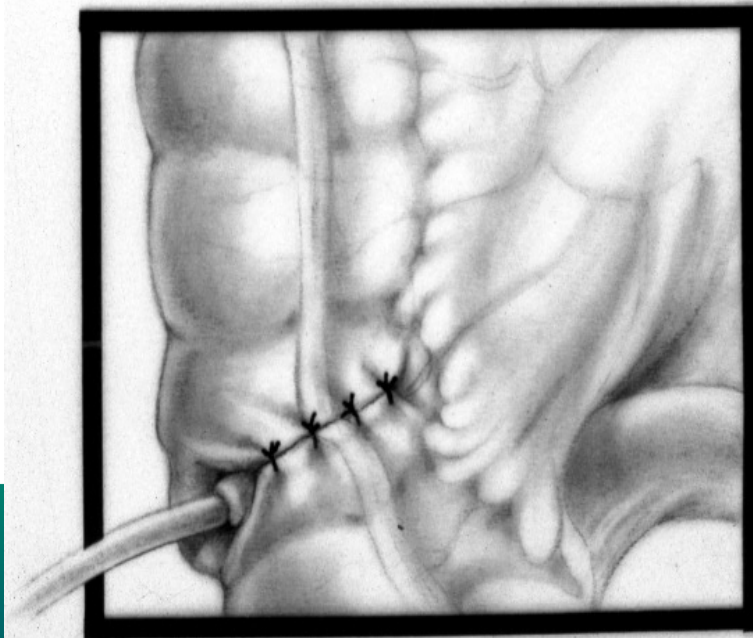
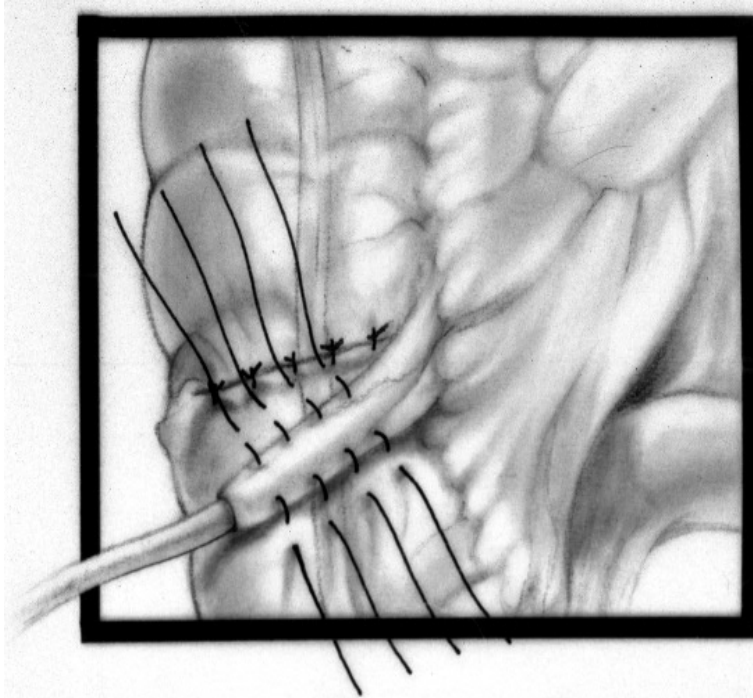
INTERNATIONAL CENTER FOR  
**COLORECTAL AND  
UROGENITAL CARE**

A patient is fecally incontinent, he is clean with rectal enemas, wants an antegrade enema procedure and the appendix has been already removed. What would you do?



1. Percutaneous cecostomy tube
2. Laparoscopically cecostomy tube
3. Neo-appendicostomy
4. Continue with rectal enemas
5. I don't know

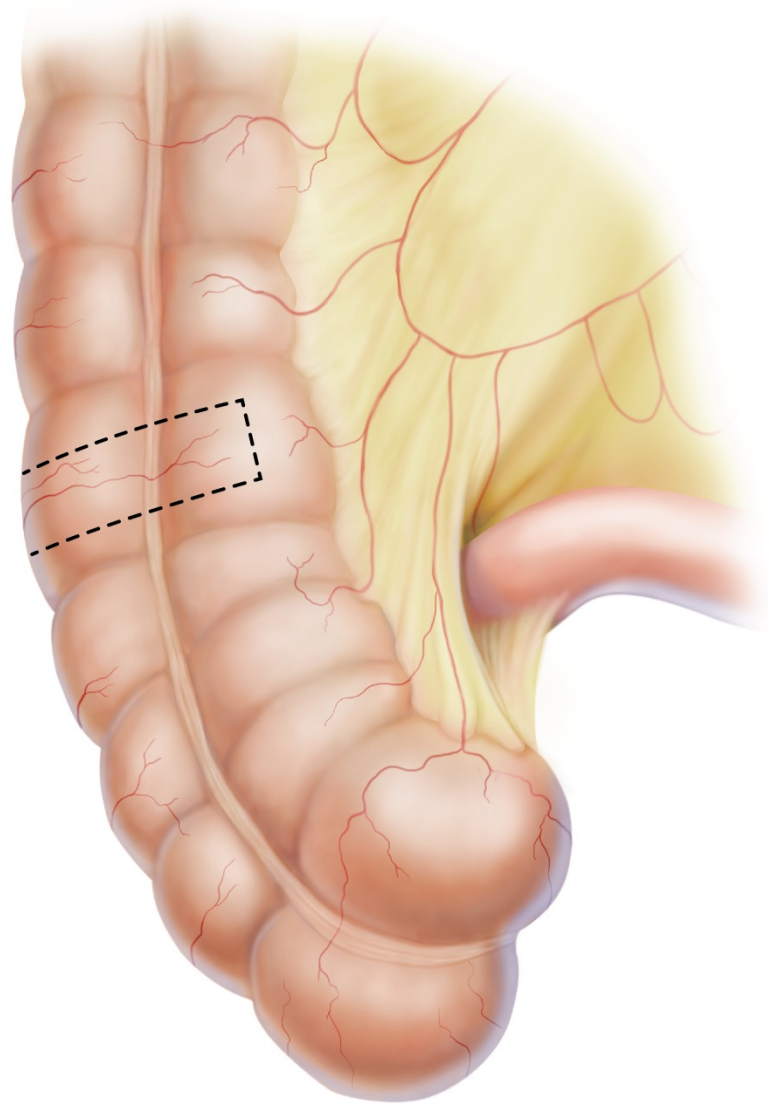




L. BARNES

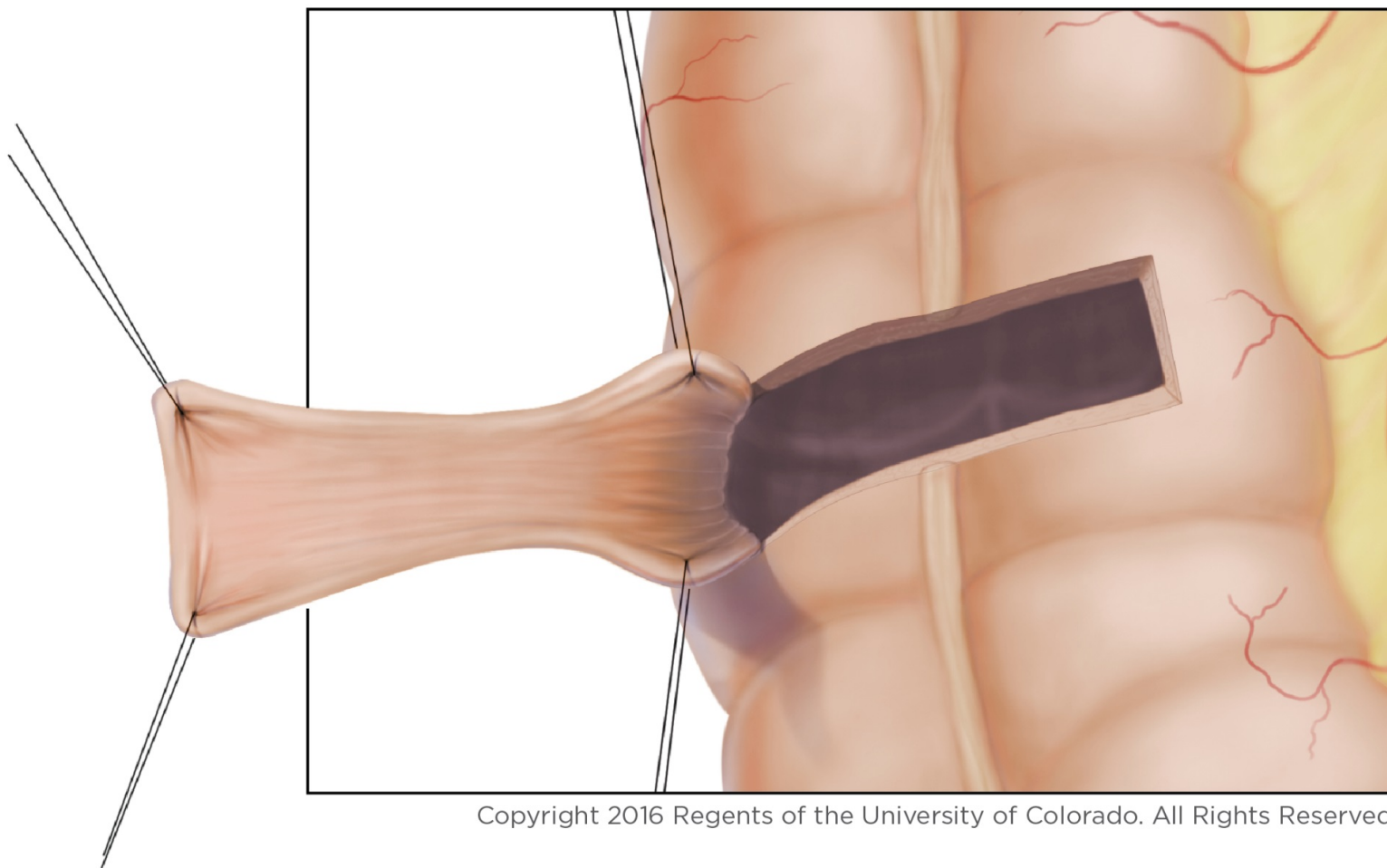
INTERNATIONAL CENTER FOR  
**COLORECTAL AND  
UROGENITAL CARE**



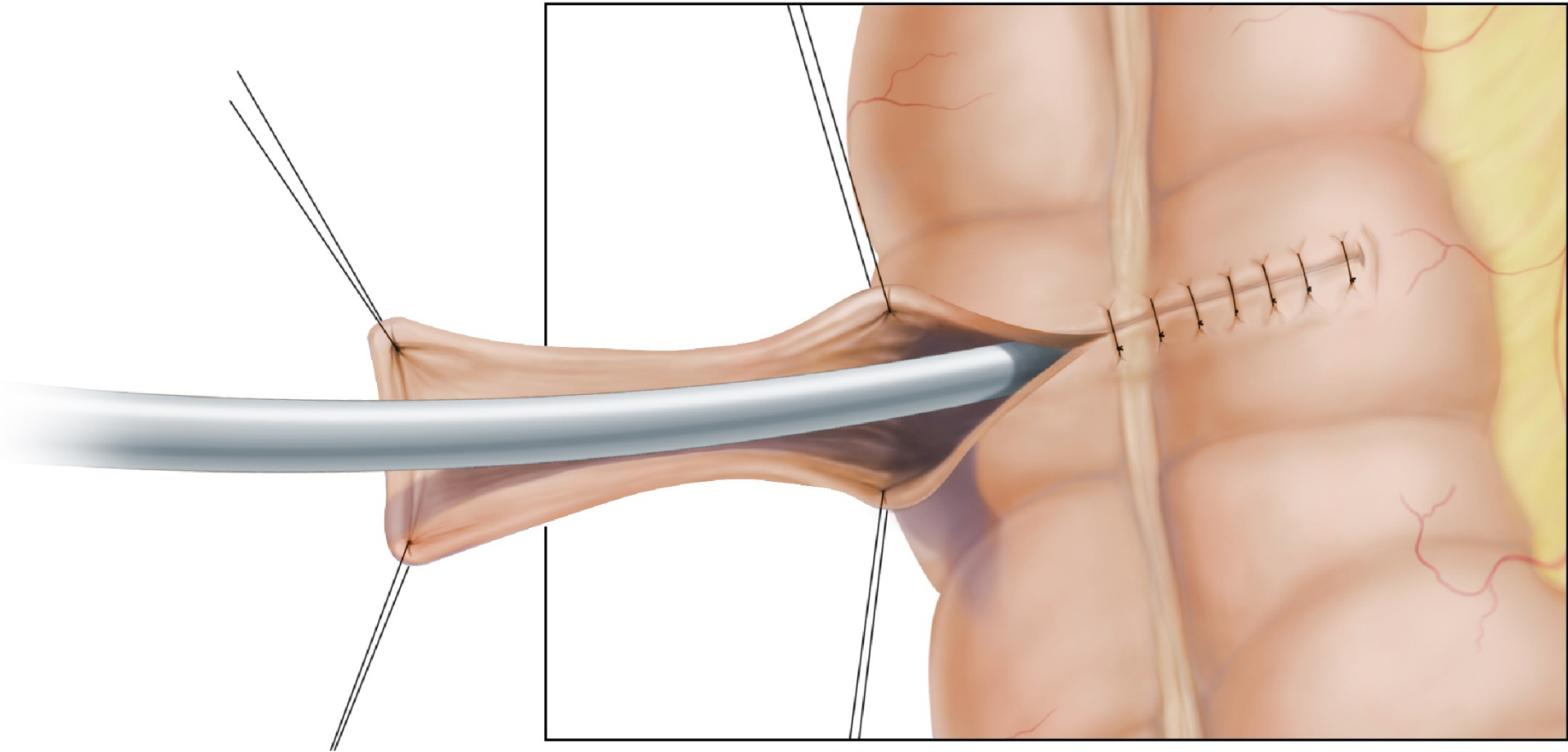


Copyright 2016 Regents of the University  
of Colorado. All Rights Reserved.

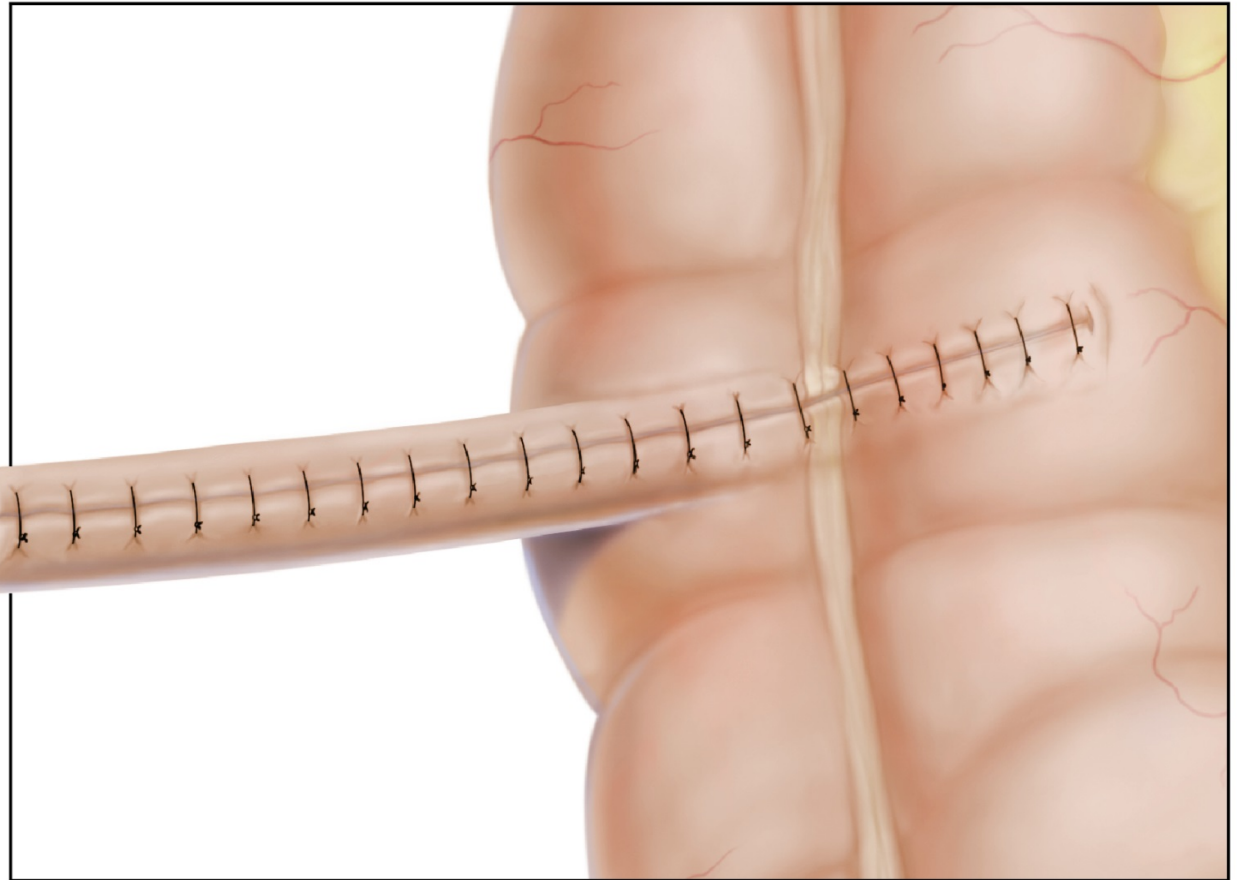
INTERNATIONAL CENTER FOR  
**COLORECTAL AND  
GENITAL CARE**



Copyright 2016 Regents of the University of Colorado. All Rights Reserved.

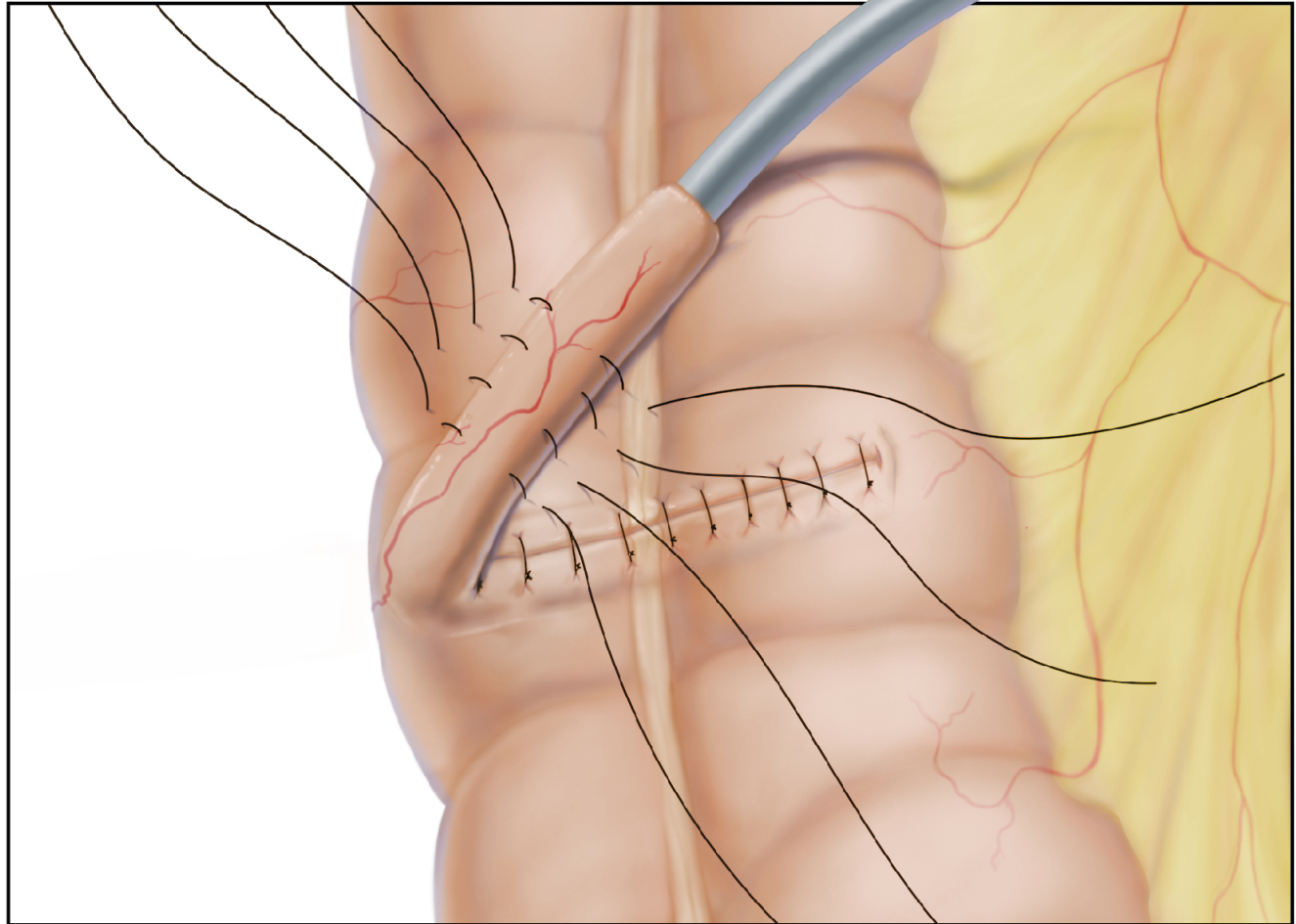


Copyright 2016 Regents of the University of Colorado. All Rights Reserved.



Copyright 2016 Regents of the University of Colorado. All Rights Reserved.





Copyright 2016 Regents of the University of Colorado. All Rights Reserved.

