

Case # 5

Alberto Peña

May 17, 2018.



Children's Hospital Colorado

INTERNATIONAL CENTER FOR
**COLORECTAL AND
UROGENITAL CARE**

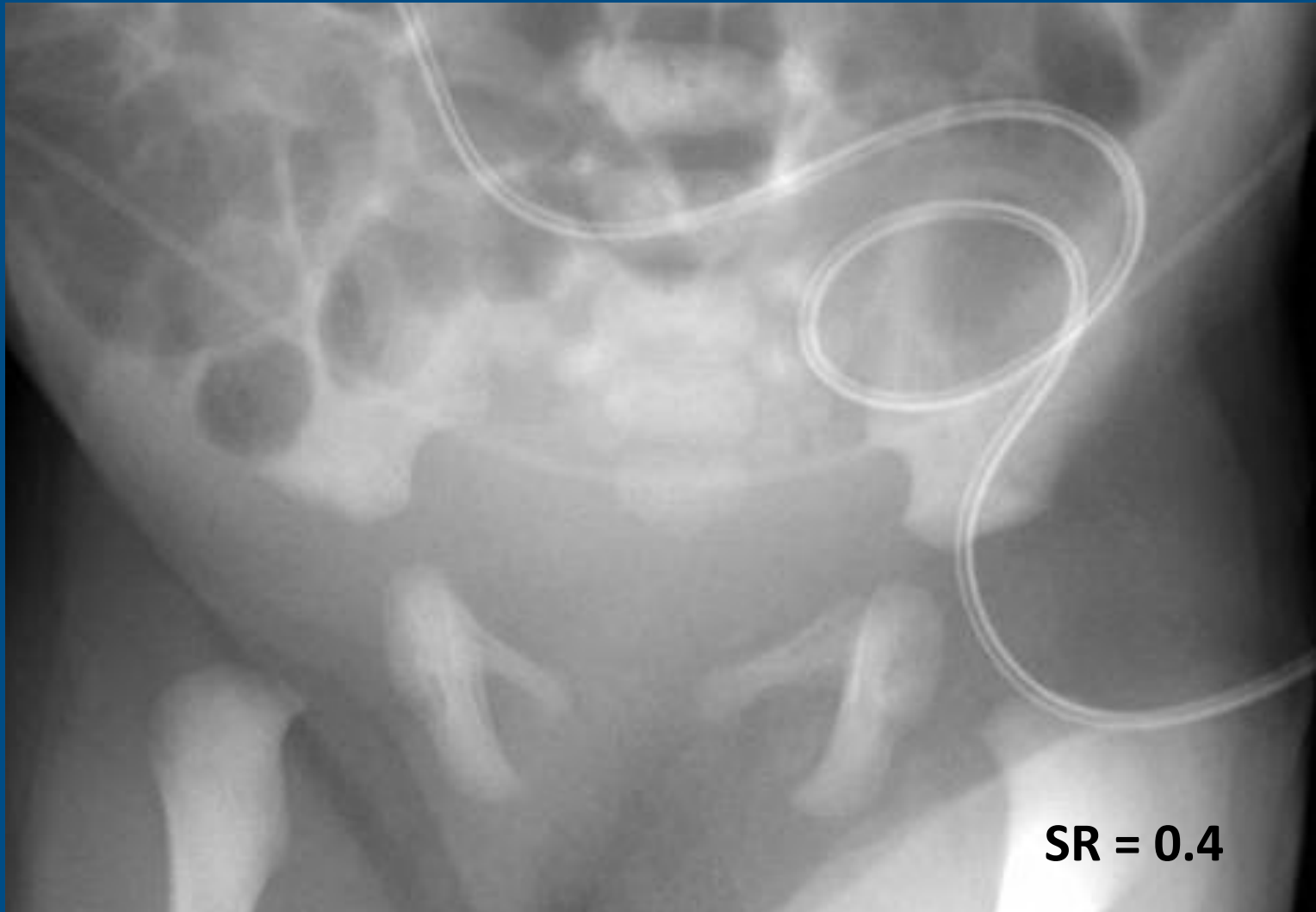


- Female patient born with a cloacal anomaly
- Divided colostomy at birth

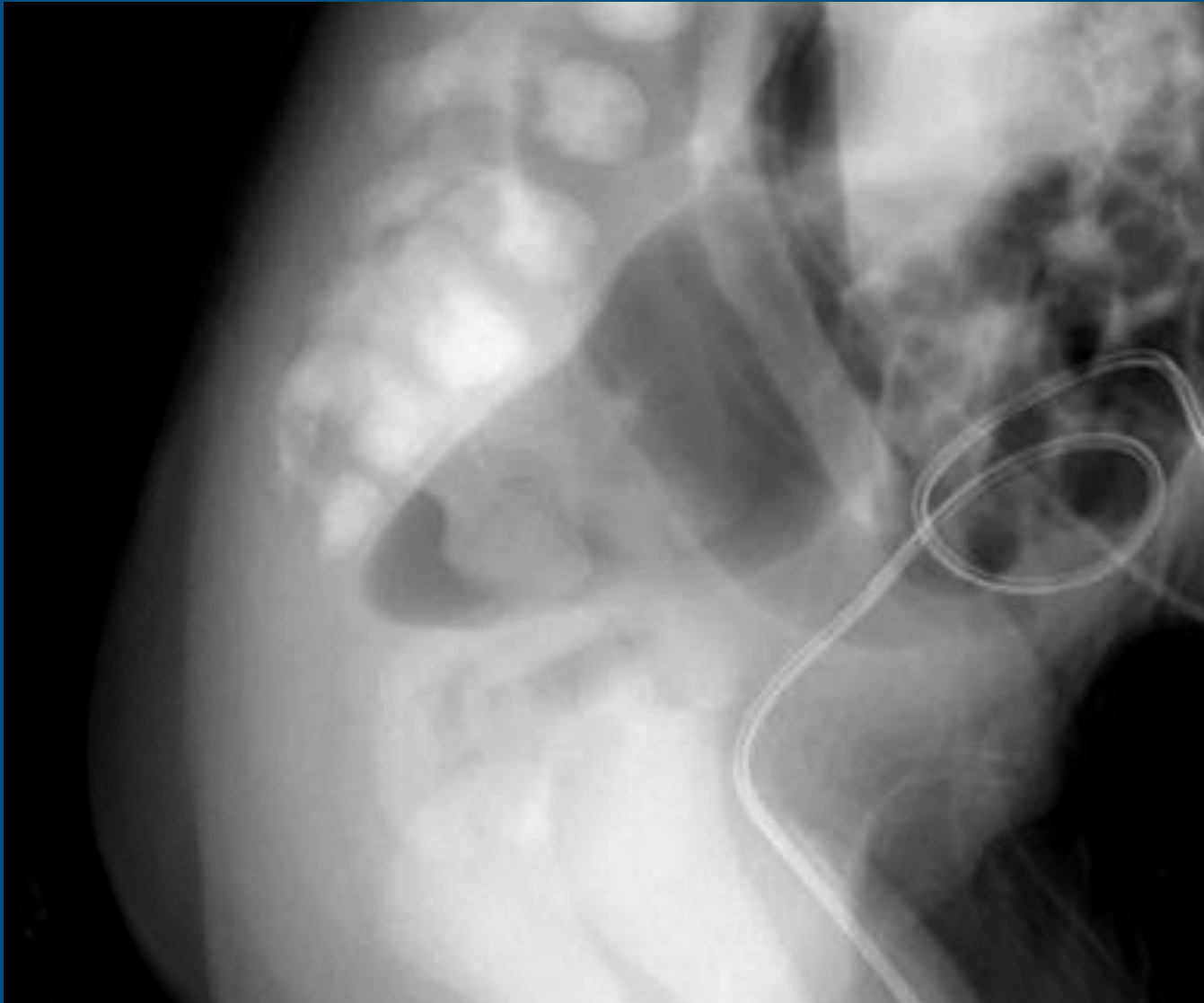What is the ideal age to repair a cloaca?



1. 3 months
2. 6 months
3. 12 months
4. 24 months
5. When after the colostomy it is demonstrated that the patient is growing well
6. It depends
7. I don't know

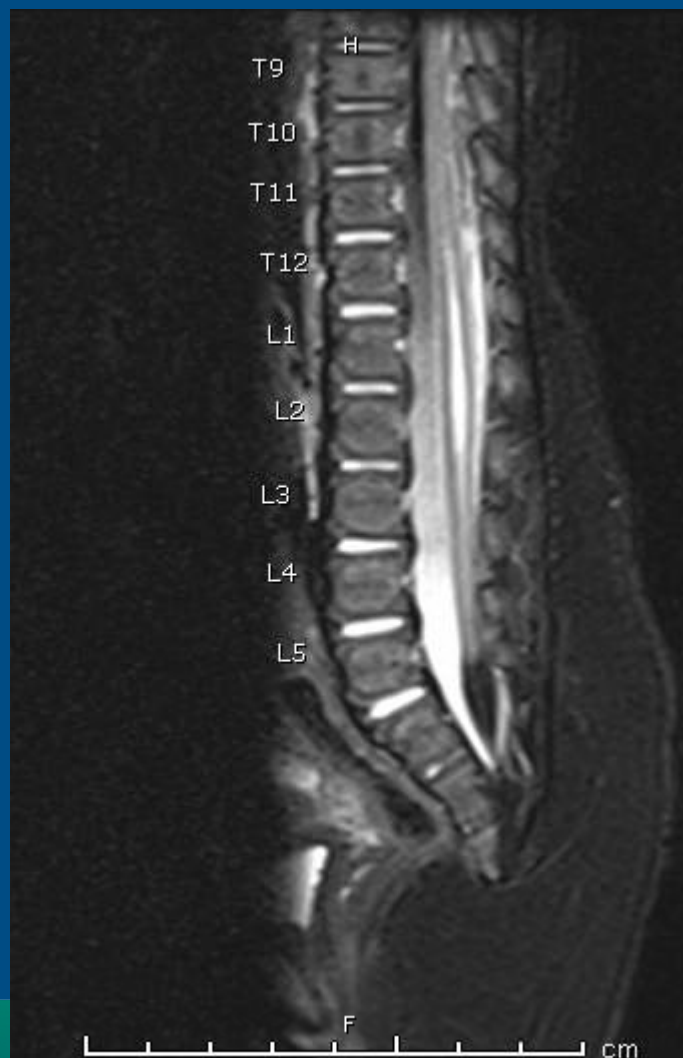


SR = 0.4



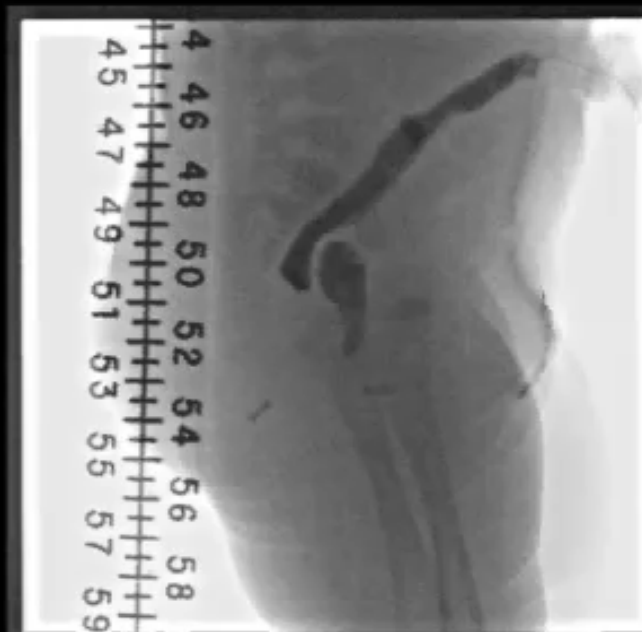INTERNATIONAL CENTER FOR
**COLORECTAL AND
UROGENITAL CARE**

Tethered Cord





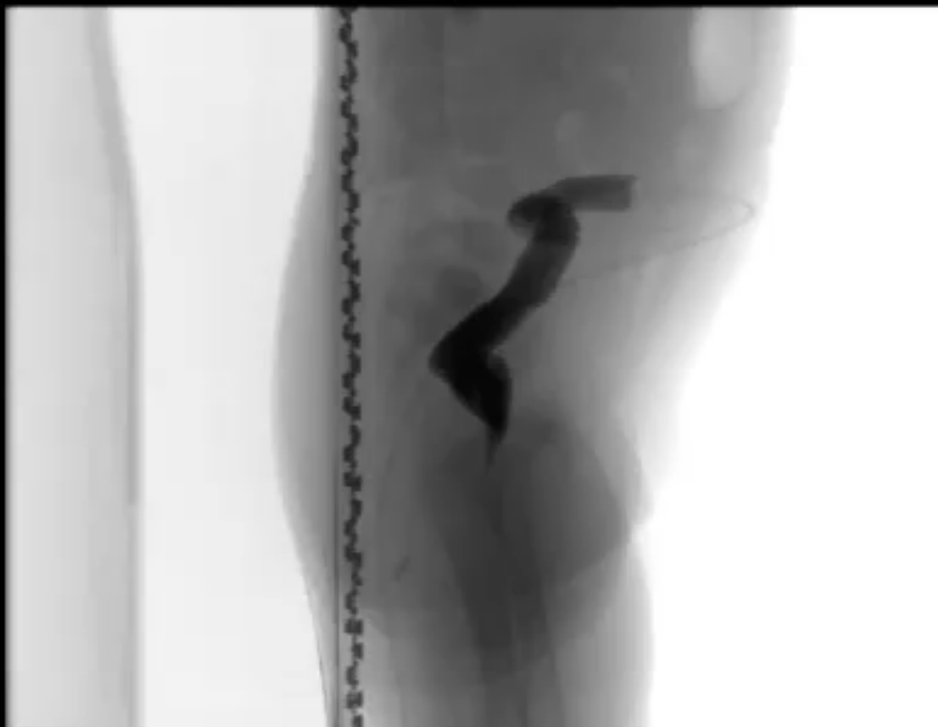- Renal US-mild left hydronephrosis
- Echocardiogram- small PDA



Page: 1 of 146



IM: 1



Page: 1 of 20

IM: 1

INTERNATIONAL CENTER FOR
**COLORECTAL AND
UROGENITAL CARE**



- 1.5 cm to the urethra
- 2.5 cm to the vaginas
- 3.5 cm to the rectum
- Separated the rectum from the vagina, Total Urogenital Mobilization. All structures reached but the rectum was dusky, laparotomy for further rectal mobilization.



Our Next International Colorectal Web Meeting will be on June 21st, 2018

