Why patients with Hirschsprung present colitis and how to prevent it

Luis De la Torre, M.D., FAAP, FAPSA
Pediatric Colorectal Surgeon

Colorectal and Hirschsprung Center

The Hendren Project

Hirschsprung

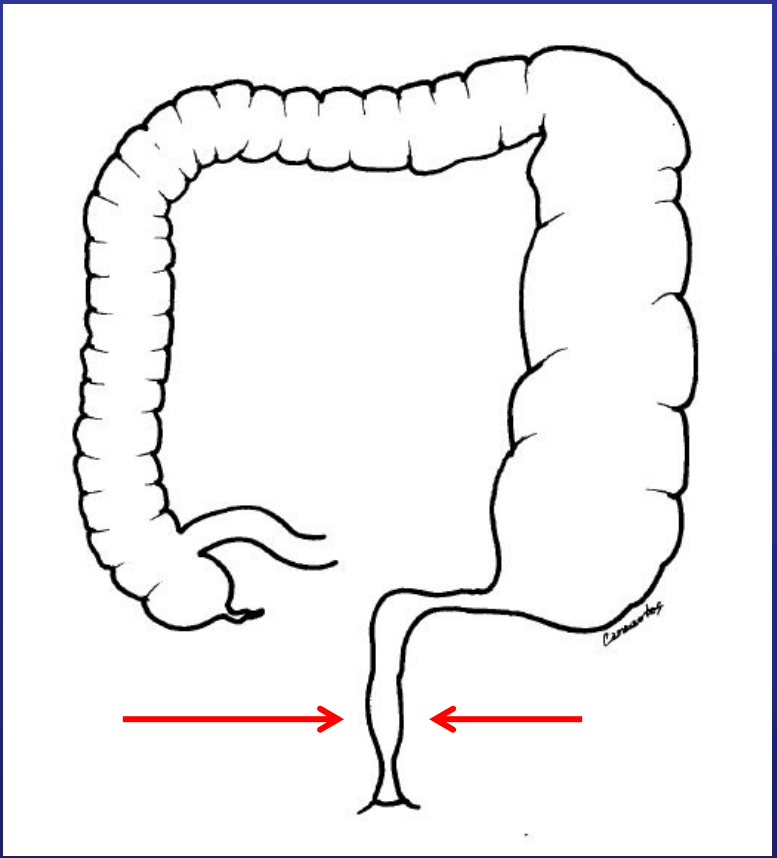

The Hendren Project

Congenital disease of the rectum and anal canal

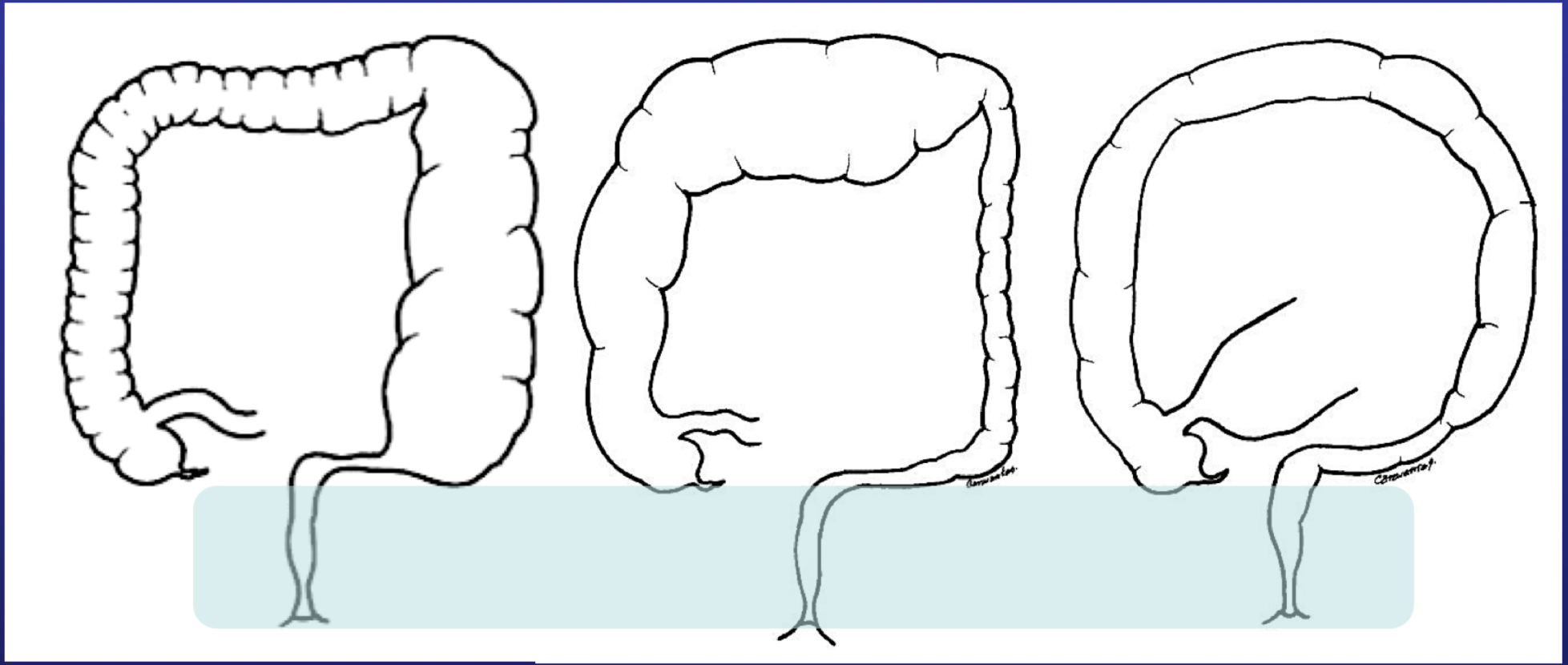

1. Resection of aganglionic segment
2. Pull-through of ganglionic segment
3. Anastomosis near to the Pectinate line

Colorectal and Hirschsprung Center

The Hendren Project

3 Objectives and challenges

1. Obtain normal colon
-Good irrigation
-Good pathology

2. Crossing "The Blind zone"
-Pass through the pelvis
-Do not damage pelvic structures

3. Good anastomosis
-Not too low
-Not too high
-Perform it properly

	Swenson	Duhamel	Soave
Primario o por etapas Laparotomía	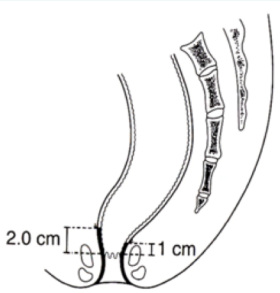 Orvar Swenson Chicago, USA 1948	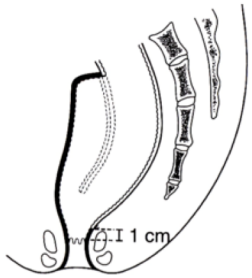 Bernard Duhamel Paris, Francia 1956	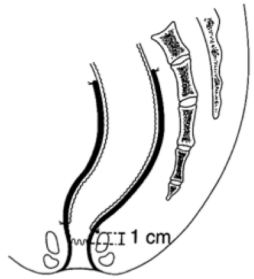 Franco Soave Génova, Italia 1960
Primario o por etapas Asistido por laparoscopia	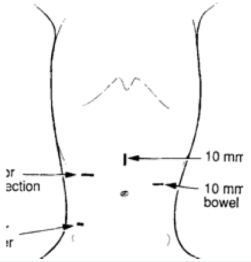 Raffensperger USA 1995	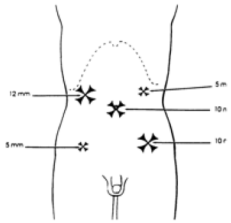  Thom Lobe USA 1994	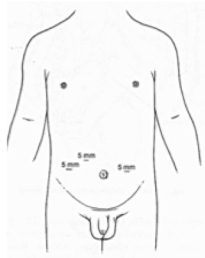 Keith Georgeson Alabama, USA 1995
Primario o por etapas Transanal	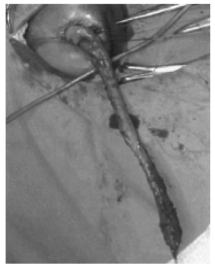 Martins Brazil 2003		 De la Torre y Ortega México 1996

Colorectal and Hirschsprung Center

The Hendren Project

Hirschsprung
Complications and outcome

Fecal incontinence

Residual aganglionosis
Transitional zone
Low coloanal anastomosis
Dehiscence
Atresia
Stenosis
Fistulae
Abscess
Rectal stenosis
Rectal atresia
Fistulas: cutaneous, urethral, vaginal
Injury to vagina, ureter, seminal vesicle
Megarectum after Duhamel

Constipation/obstruction
Hypoactive peristalsis

Colitis

Preventable

Partially Preventable

Not preventable

Colorectal and Hirschsprung Center

The Hendren Project

Colorectal and Hirschsprung Center

The Hendren Project

Obstruction?

Infection?

Inflamation?

Colitis?

NEC?

Enterocolitis?

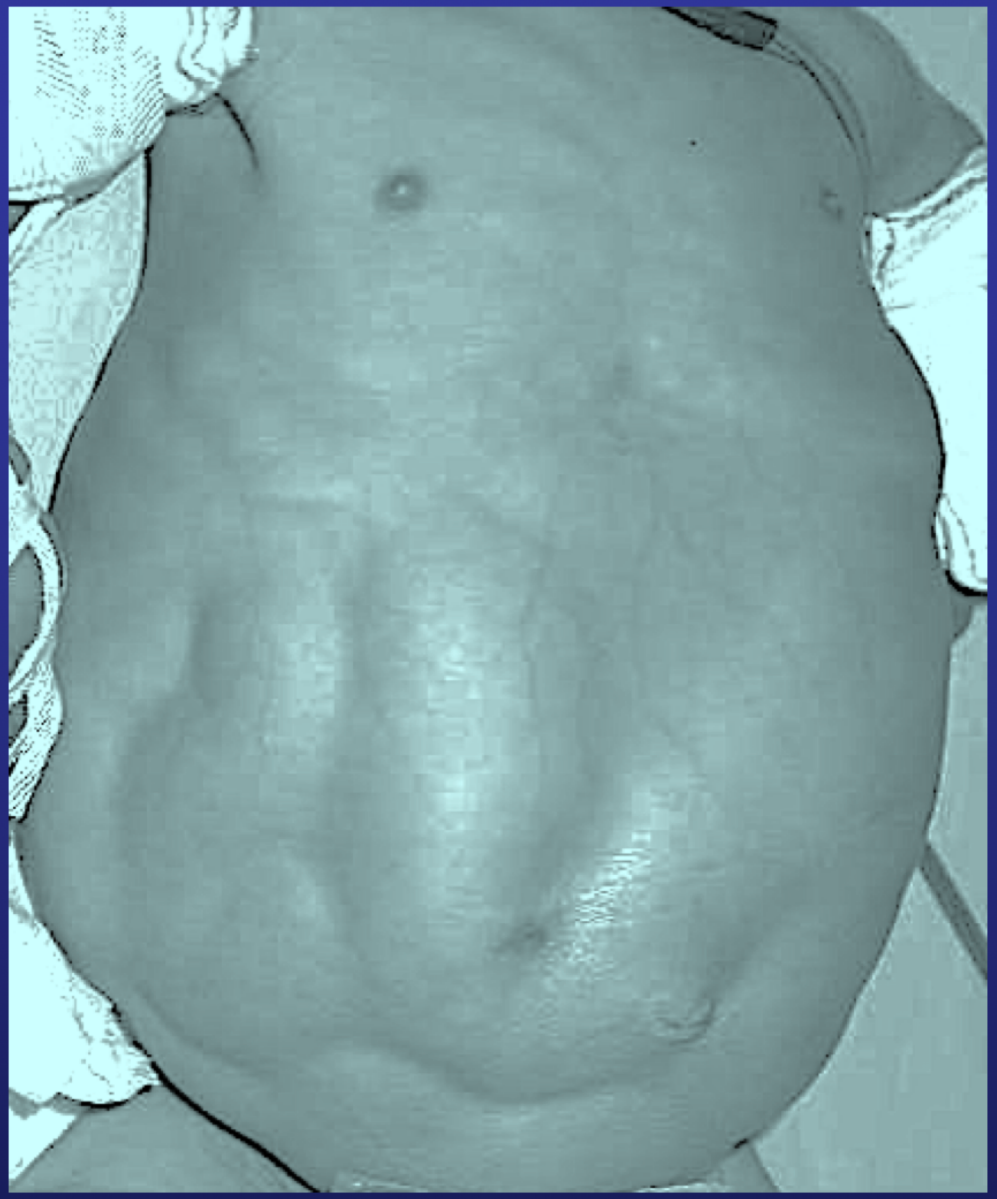

RT
JU
POST-EVAC
H: 0.40
F: 0.50
STE: 18

Video 1

Colorectal and Hirschsprung Center

The Hendren Project

Proliferative Obstructive **Colitis**

- Not able to pass stool
- Not able to move gas
- Abdominal distention
- Liquid stools
- Vomiting
- Irritable
- Fever
- “Intestinal infection.”

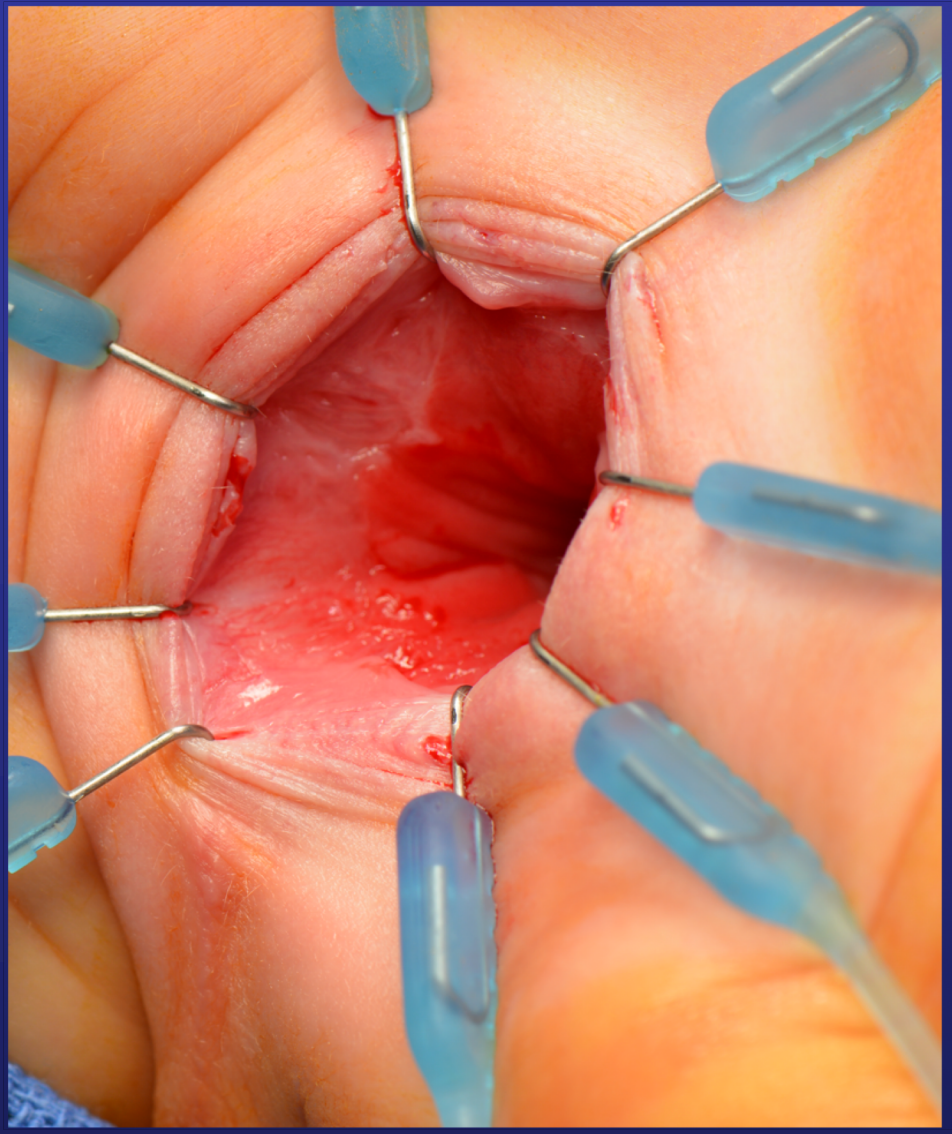

Examination under anesthesia

100% of anal canal normal

Rectal biopsy with ganglion cells

No stenosis

Video 2

Colorectal and Hirschsprung Center

The Hendren Project

What's going on?

Colorectal and Hirschsprung Center

The Hendren Project

There is no perfect surgical technique

“Obstructive Proliferative Colitis”

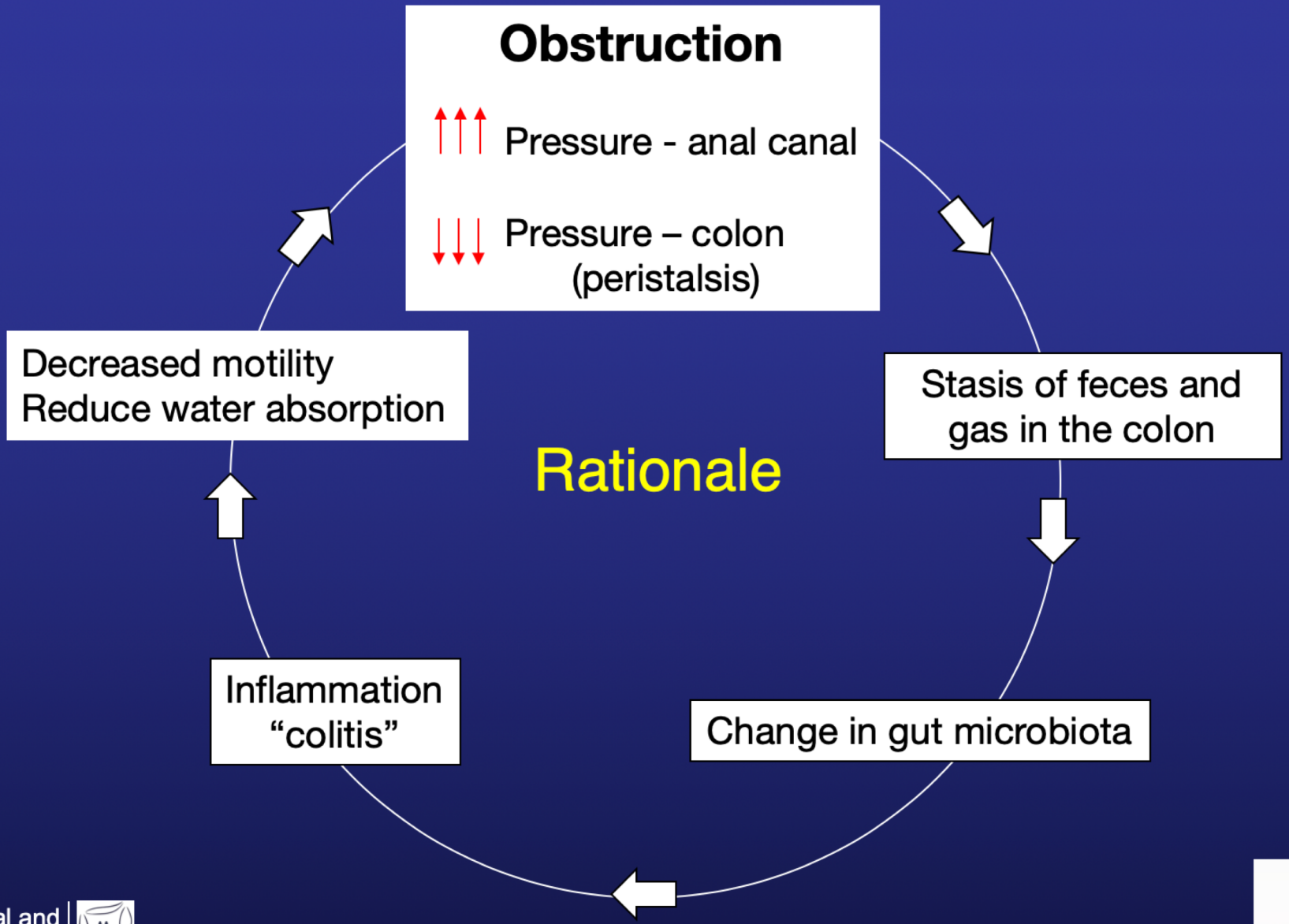

Colorectal and Hirschsprung Center

The Hendren Project

“Obstructive Proliferative Colitis”

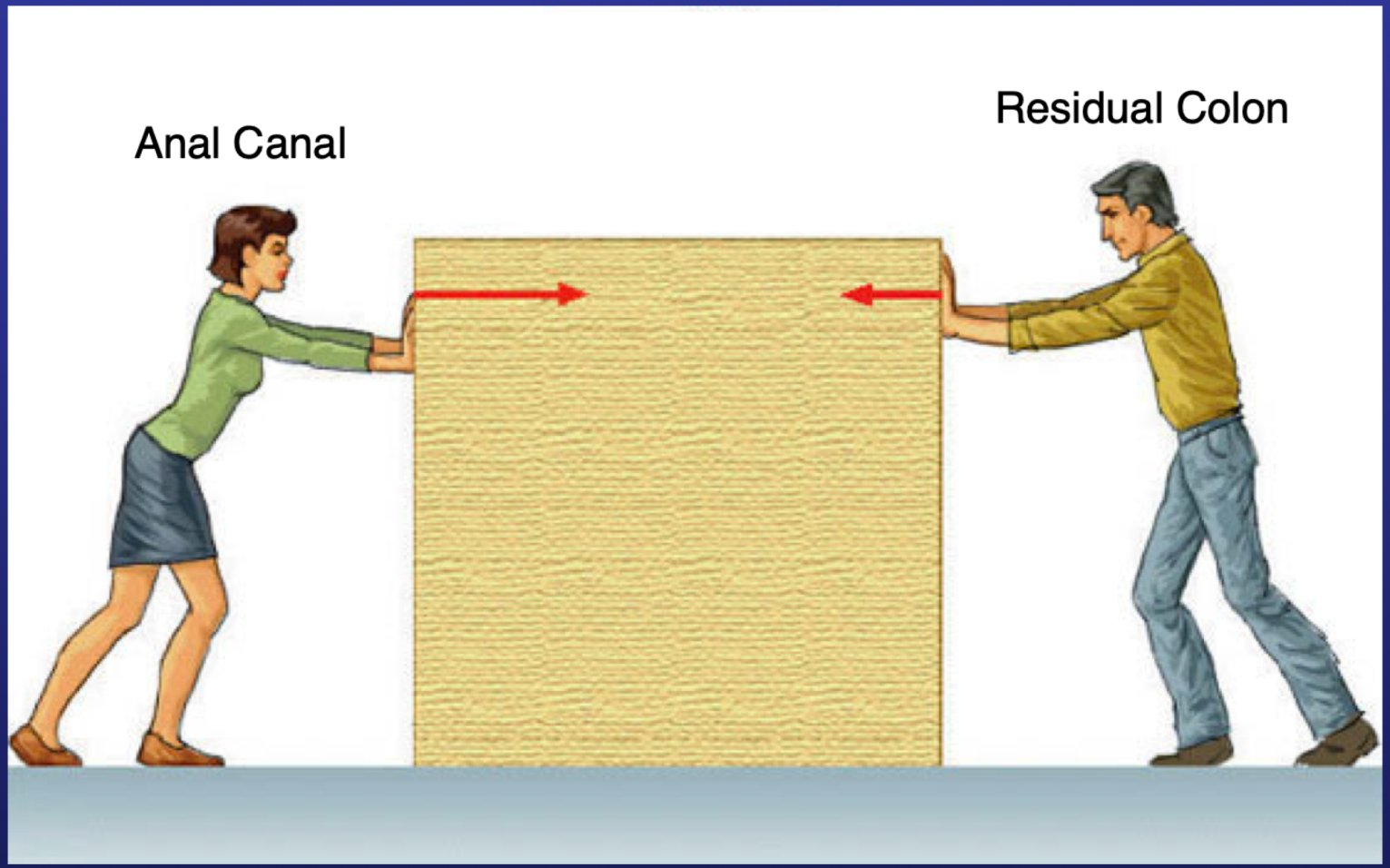

Colorectal and Hirschsprung Center

The Hendren Project

Anatomy Anal Canal

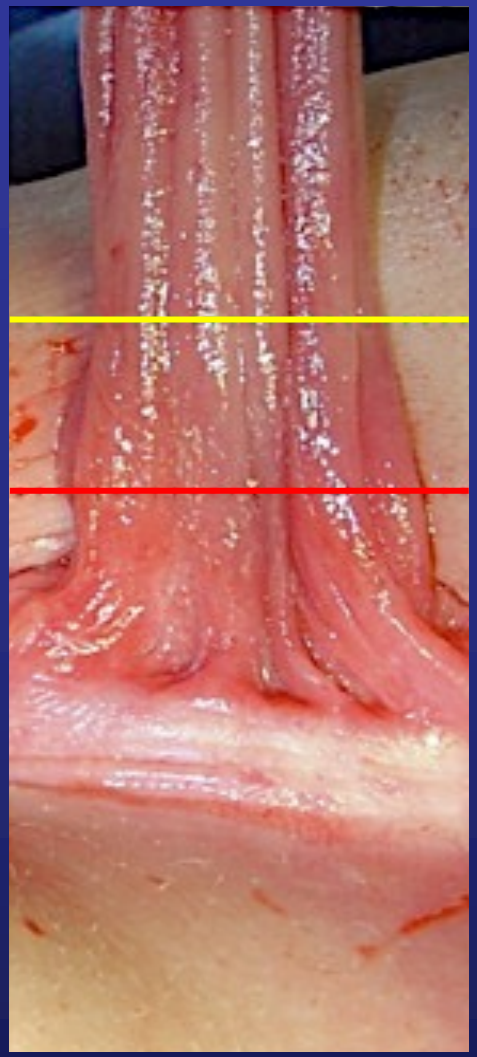

Rectum

Anal Canal

Pectinate Line

Anoderm
squamous epithelium

Skin
keratinized squamous epithelium

Colorectal and Hirschsprung Center

The Hendren Project

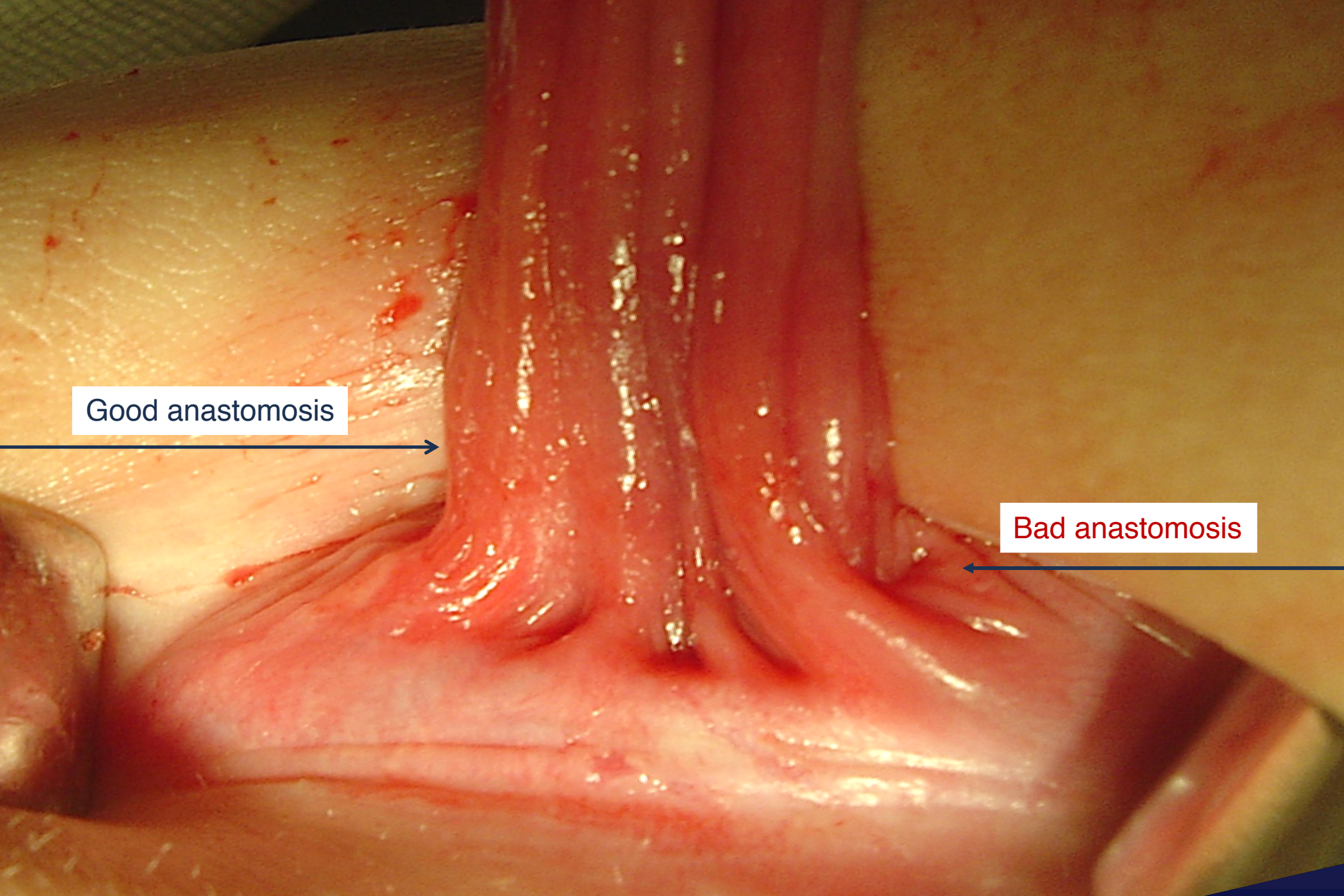
Good anastomosis
Bad anastomosis

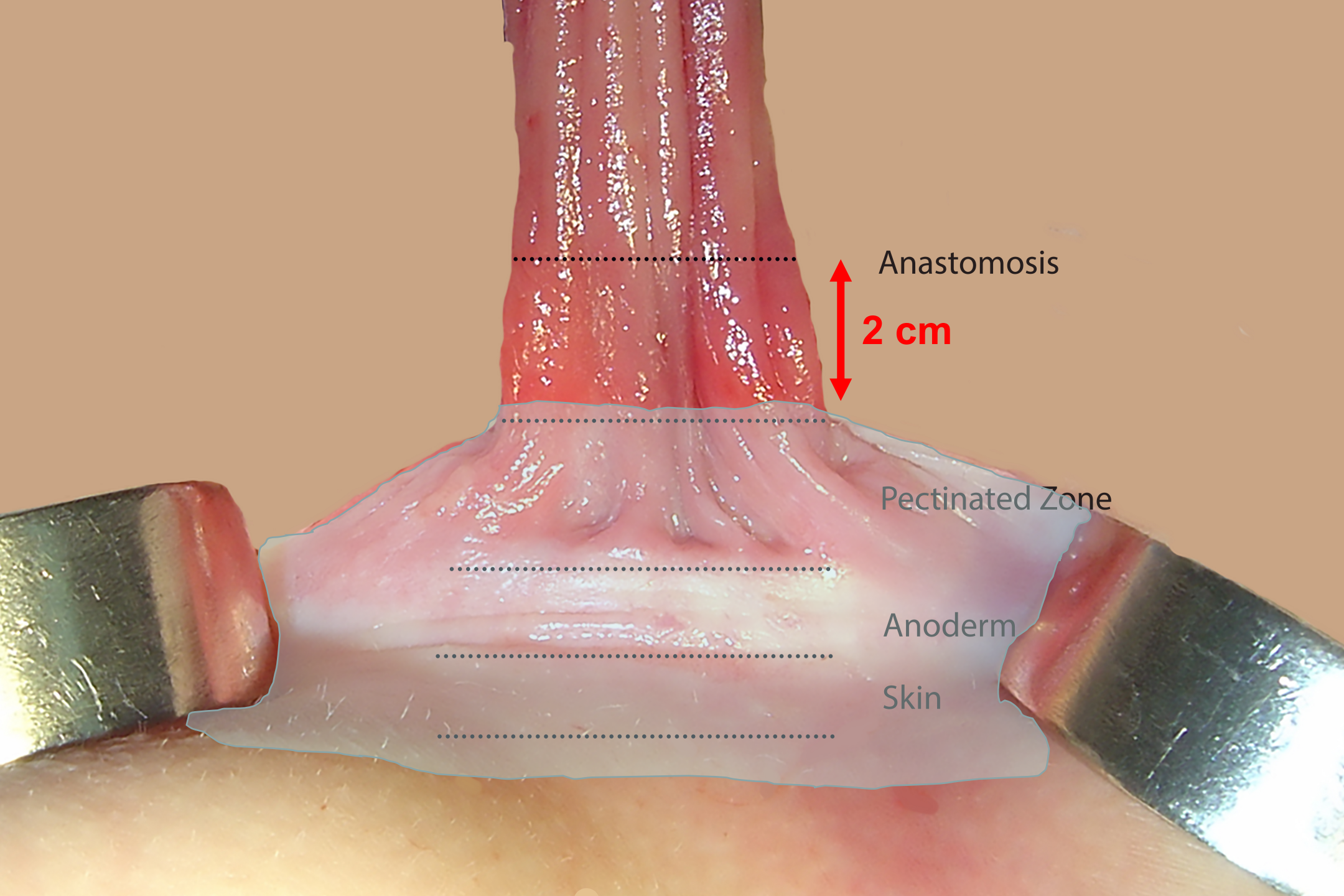
Anastomosis
2 cm
Pectinated Zone
Anoderm
Skin

Pathogenesis

Abnormal development of ENS

Intestinal barrier dysfunction

- -Lumen
- -Mucus Coating
- -Epithelial barrier
- -*Lamina propria*

Glia enteric Cells

Abnormal innate immune response

- -Ig A decreased

Abnormal Microbiota

- -Clostridium difficile
- -Rotavirus
- -*E. coli*
- -Cryptosporidium

Genetic abnormalities

- -Gen ITGB2 (CD18)

Miller, KA. The pathogenesis of Hirschsprung's disease-associated enterocolitis. Sem Ped Surg 2012 21(4):319-27.

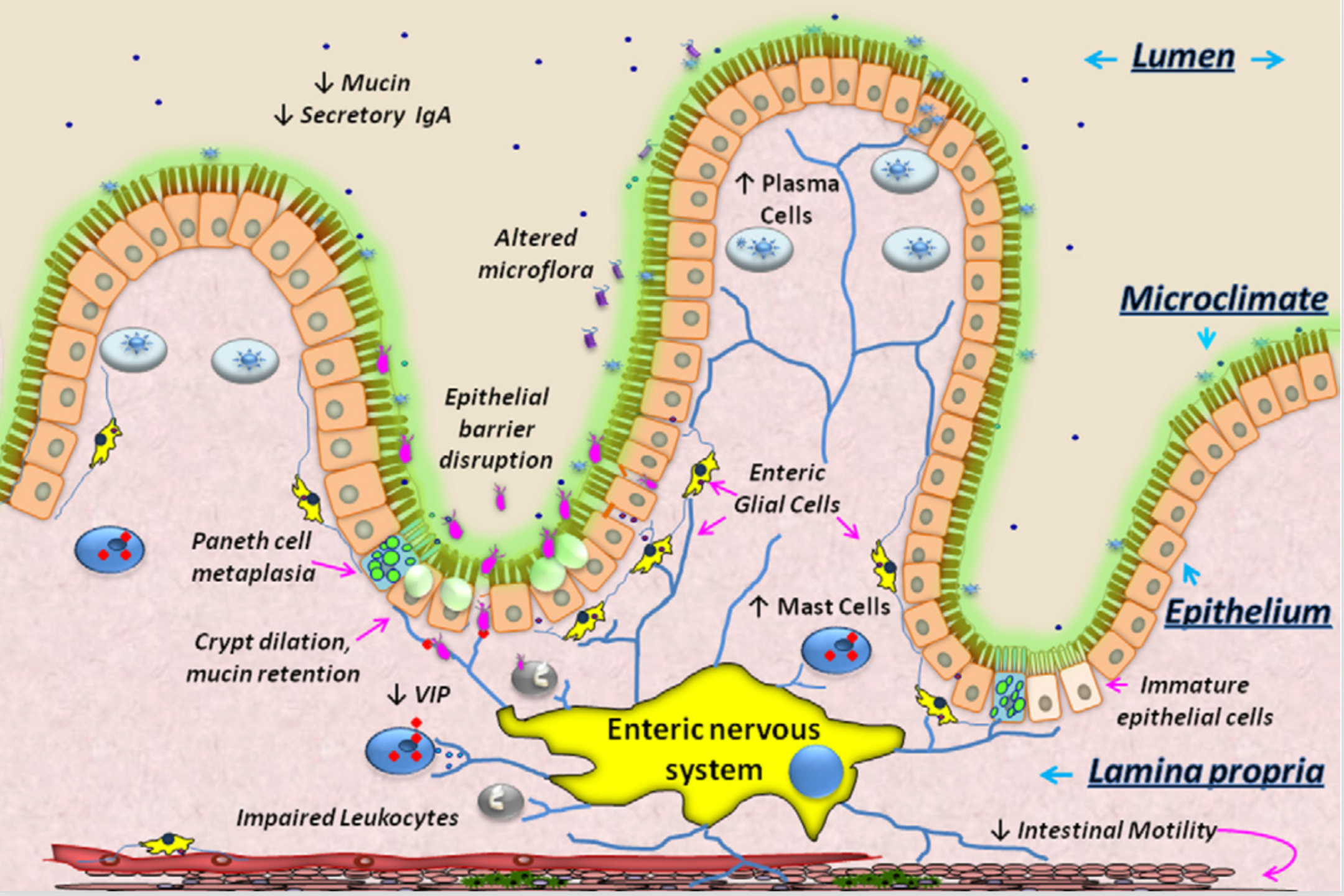
↓ Mucin
↓ Secretory IgA
Lumen
↑ Plasma Cells
Altered microflora
Microclimate
Epithelial barrier disruption
Enteric Glial Cells
Paneth cell metaplasia
↑ Mast Cells
Epithelium
Crypt dilation, mucin retention
↓ VIP
Immature epithelial cells
Enteric nervous system
Lamina propria
Impaired Leukocytes
↓ Intestinal Motility

Enterocolitis

Enterocolitis

Colitis

Colorectal and Hirschsprung Center

The Hendren Project

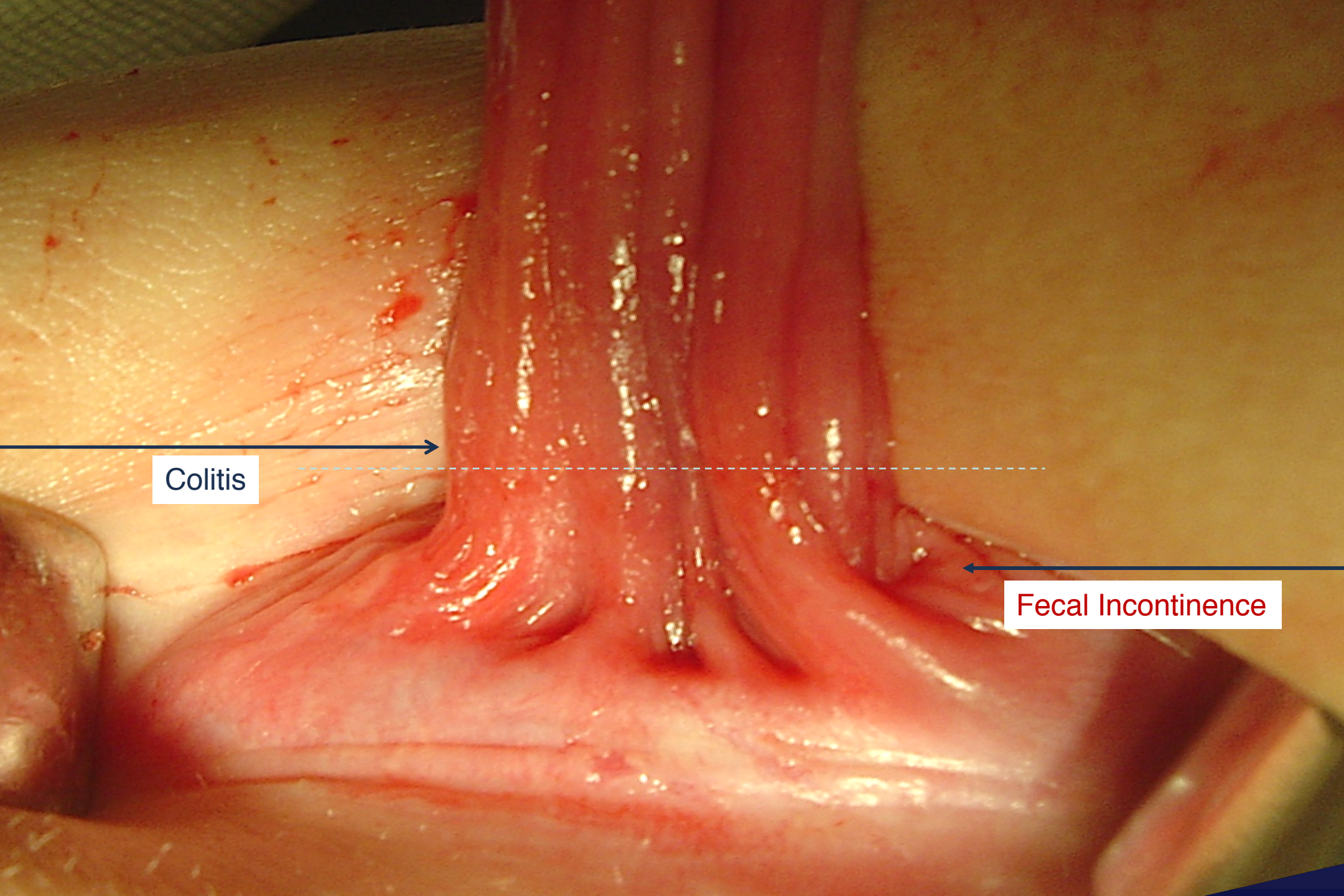
Colitis
Fecal Incontinence

Risk Factors

The Hendren Project



Colorectal and Hirschsprung Center

The Hendren Project

Do you want a primary pull-through?



Colorectal and Hirschsprung Center

The Hendren Project

Hirschsprung - 7 years

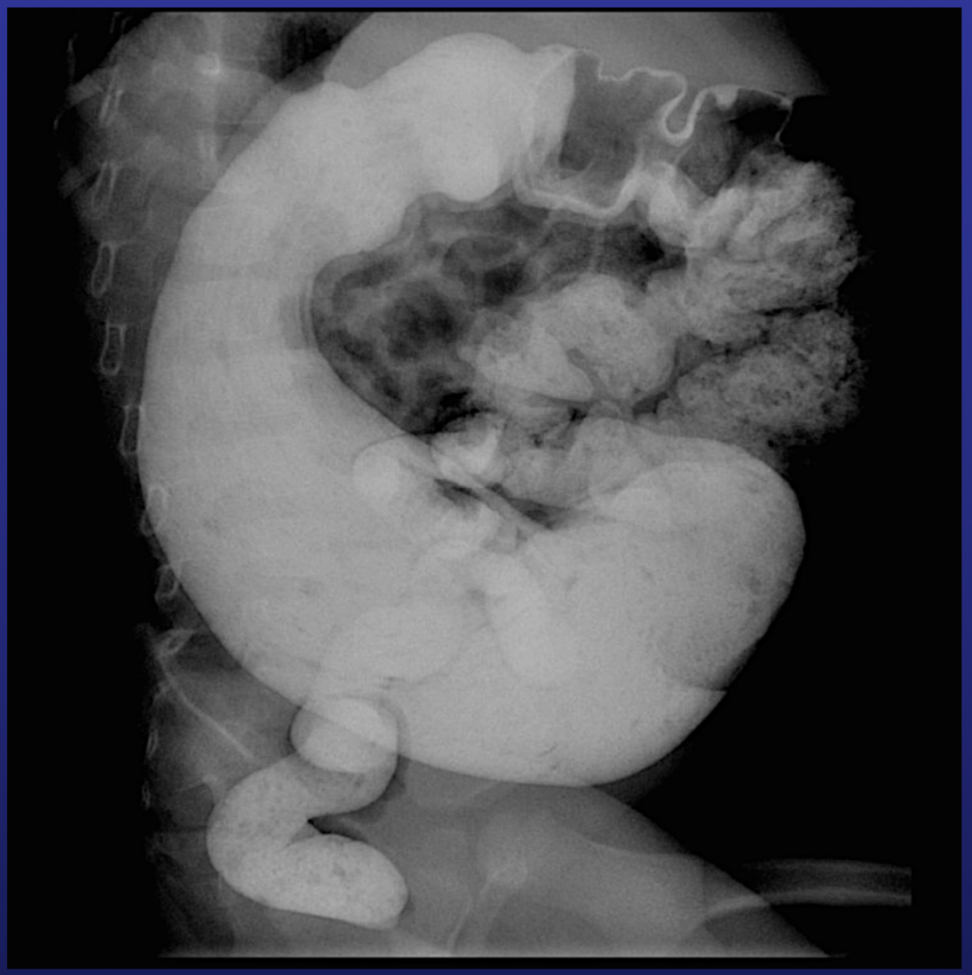

Colorectal and Hirschsprung Center

The Hendren Project

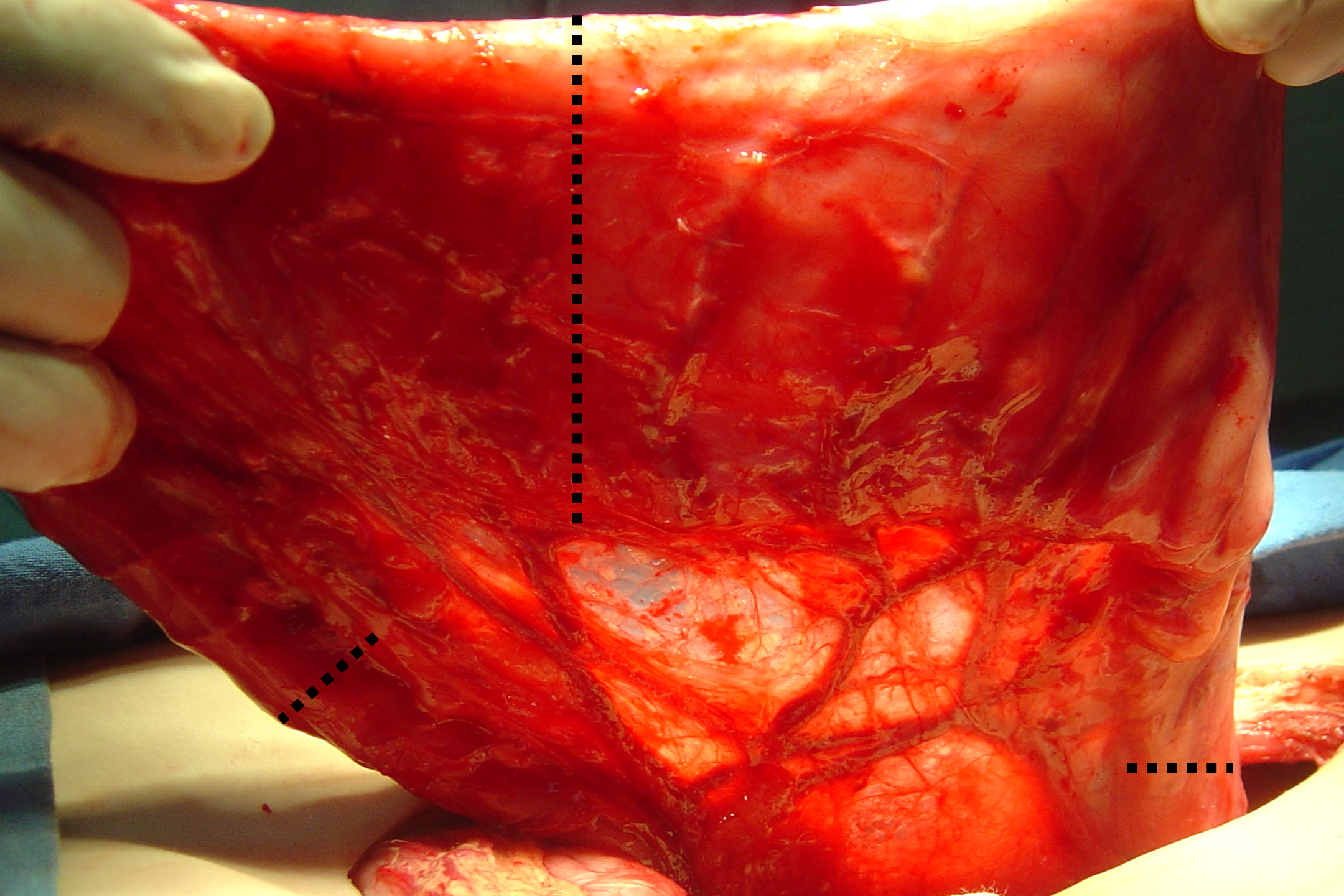

The motility (peristalsis) of the chronic dilated colon could be as ineffective as the aganglionic colon.

Immediate treatment

The Hendren Project

It's NOT an urgent situation!

Colorectal and Hirschsprung Center

The Hendren Project

Irrigations

Unexpected Death From Enterocolitis After Surgery for Hirschsprung's Disease

Terri L. Marty, MD*; Michael E. Matlak, MD*‡; Margo Hendrickson, MD§; Richard E. Black, MD*‡; and Dale G. Johnson, MD*‡

ABSTRACT. Unanticipated death from enterocolitis occurred in five children 3 weeks to 20 months after uncomplicated reconstruction for Hirschsprung's disease. In each case the presenting symptoms of enterocolitis were mild and were misinterpreted by examining physicians. Within 2 to 12 days of onset of symptoms, unexpected death occurred. Although fatal enterocolitis is a well-known complication of Hirschsprung's disease, emphasis is usually placed on preoperative enterocolitis. Fatal postoperative enterocolitis is not a new entity associated with Hirschsprung's disease, but physician awareness of this possibility is obviously deficient. We strongly recommend extensive parent education and better postoperative communication between the surgeon and the referring physician. *Pediatrics* 1995;96:118–121; *Hirschsprung's disease, enterocolitis, unexpected death.*

TABLE 2. Characteristics Surrounding Death

Case	Age at Death (mo)	Duration of Acute Illness Before Death (d)	Interval From Surgery Until Death (d)
1	8	5	19
2	30	2	20 months
3	8	3	26
4	6	12	34
5	11	4	23

4 Duhamel
1 Soave

Gastroenteritis

“Instruct the parents how to make irrigation, before the pull-through.”

Thank you and have happy colon!

Questions, claims or comments?



Colorectal and Hirschsprung Center

The Hendren Project