

# Idiopathic Constipation VS Hirschsprung

---



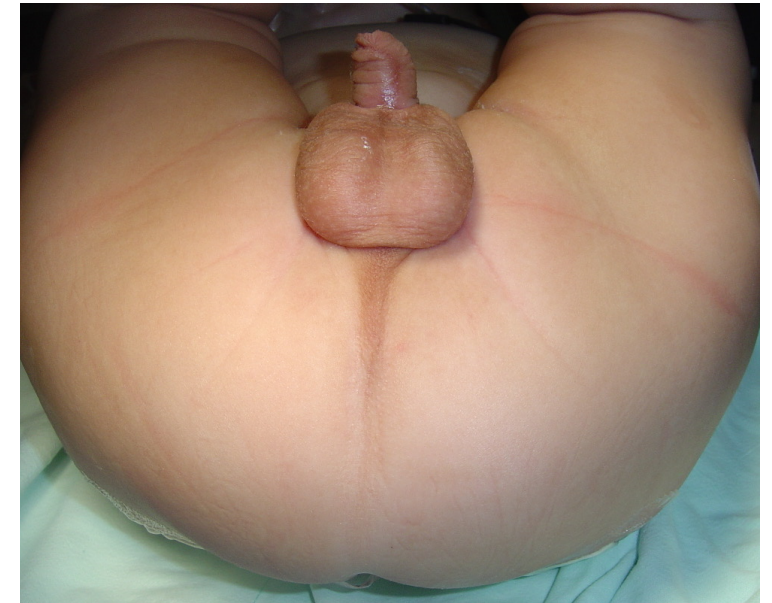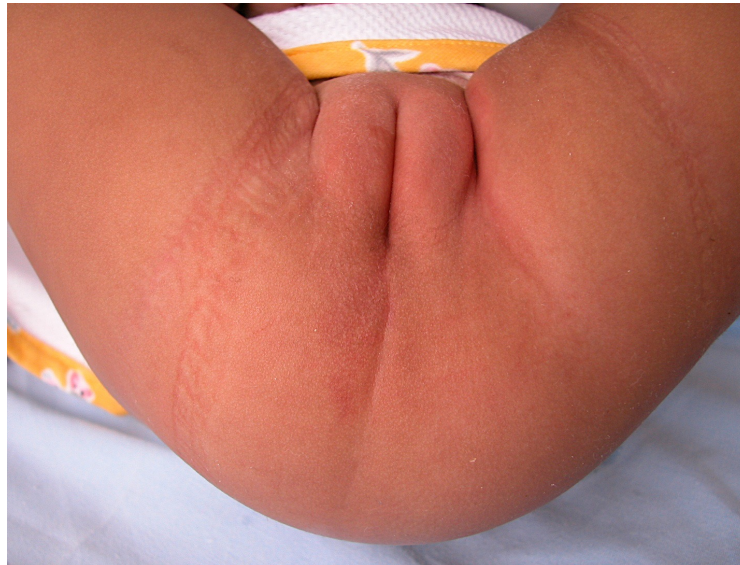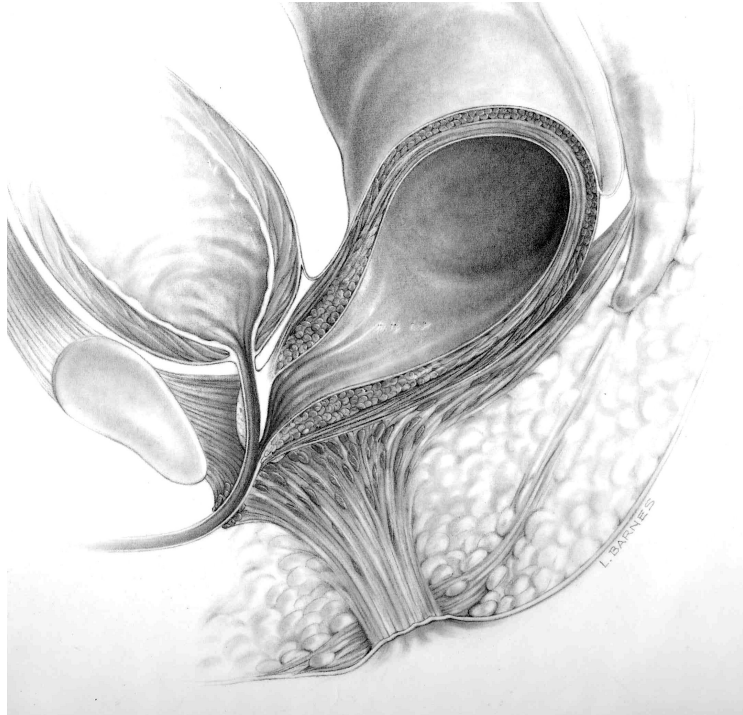
Children's Hospital Colorado

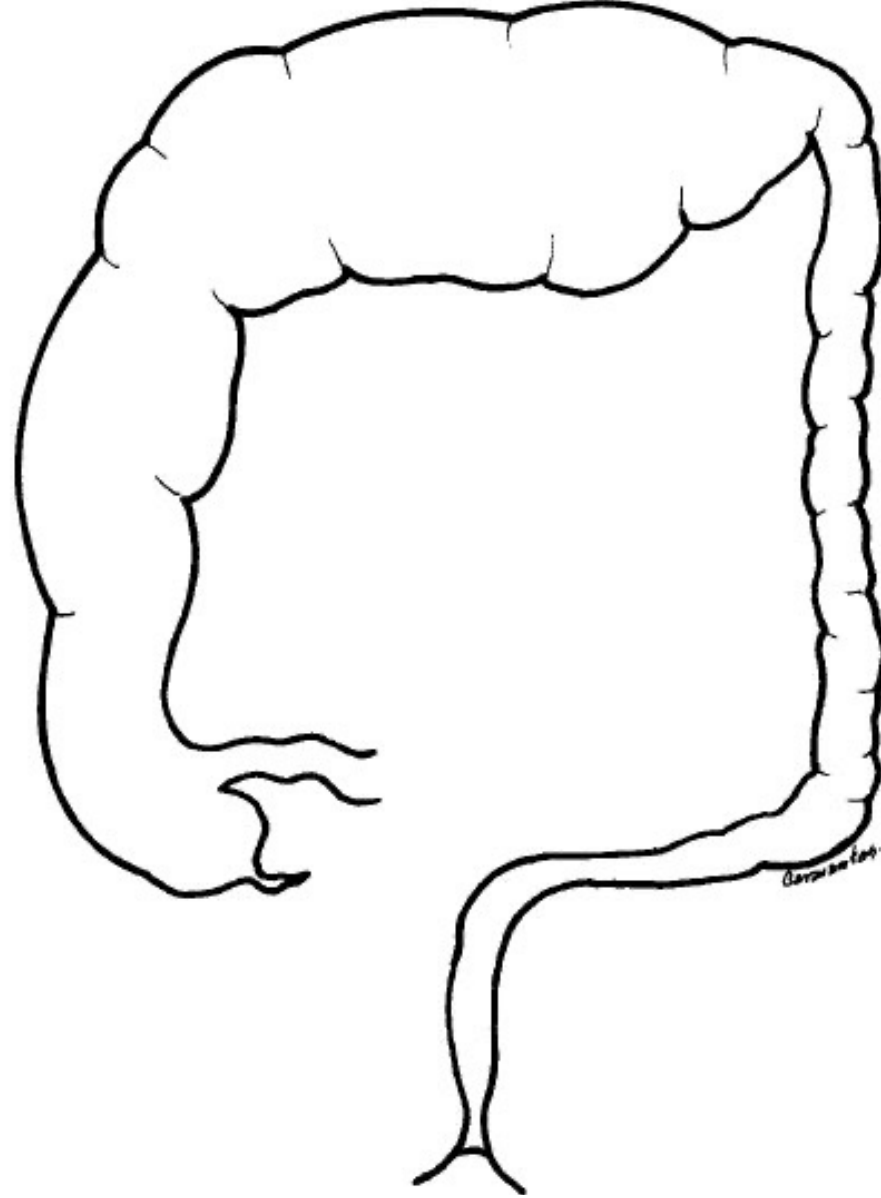
INTERNATIONAL CENTER FOR  
**COLORECTAL AND  
UROGENITAL CARE**

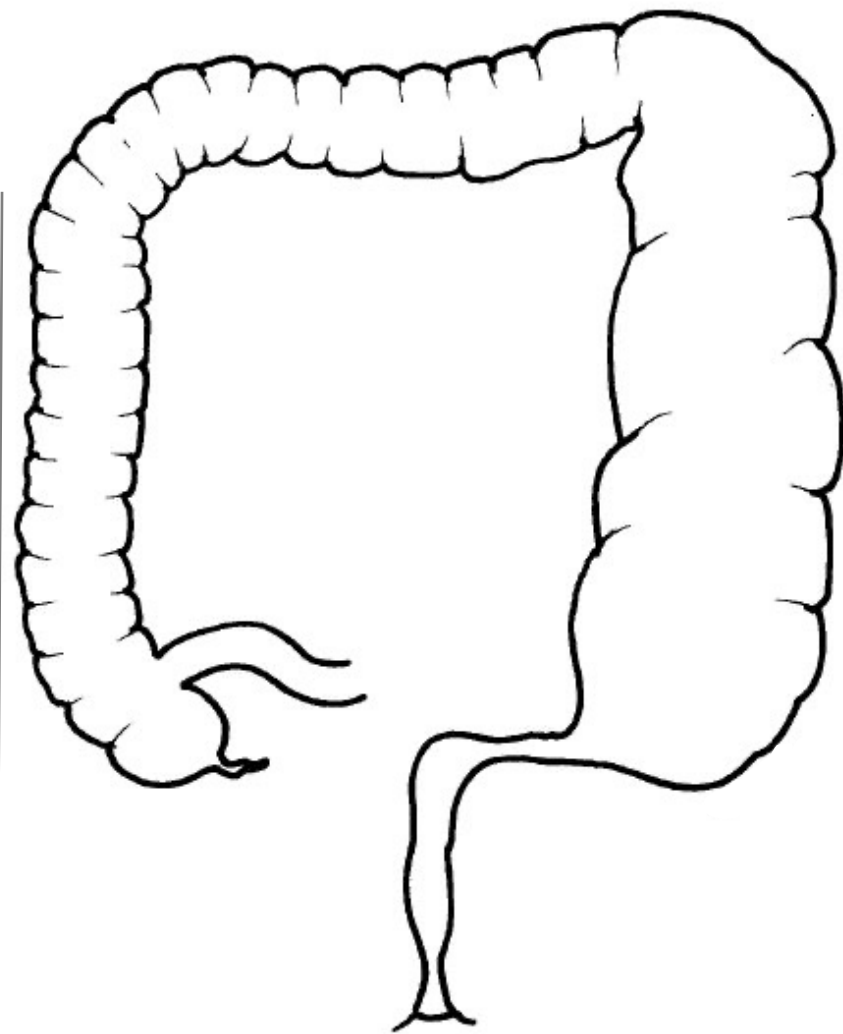
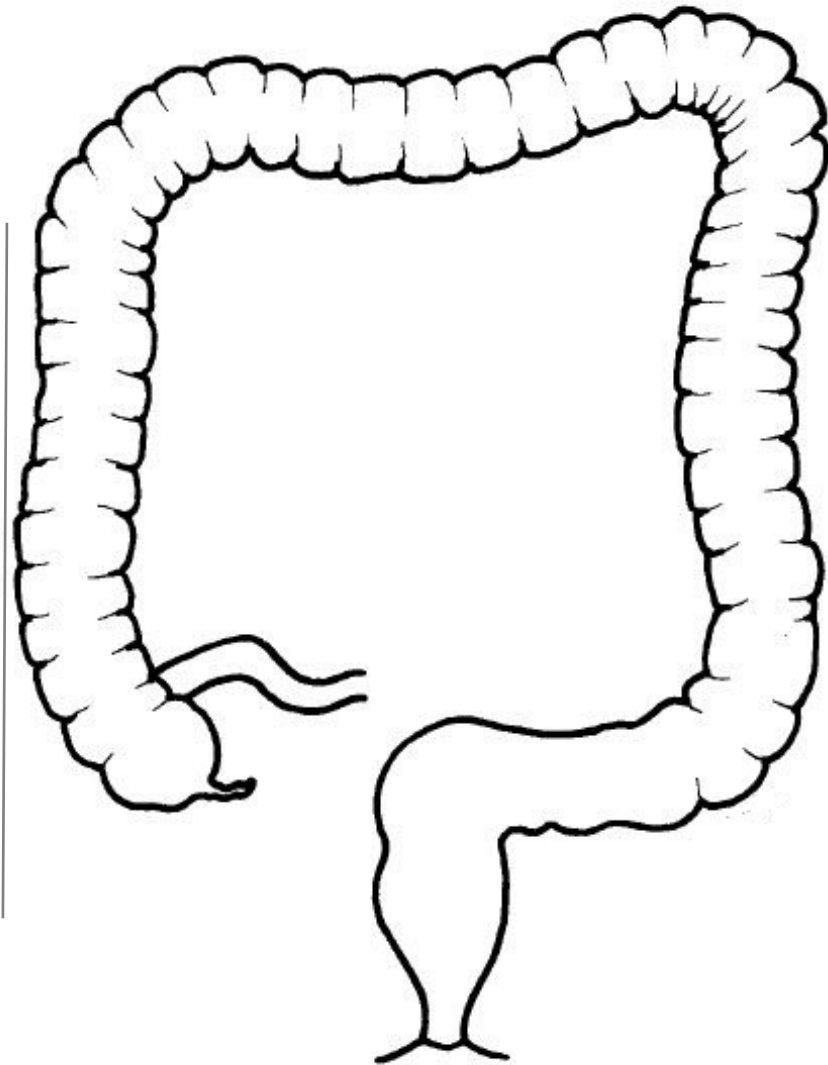
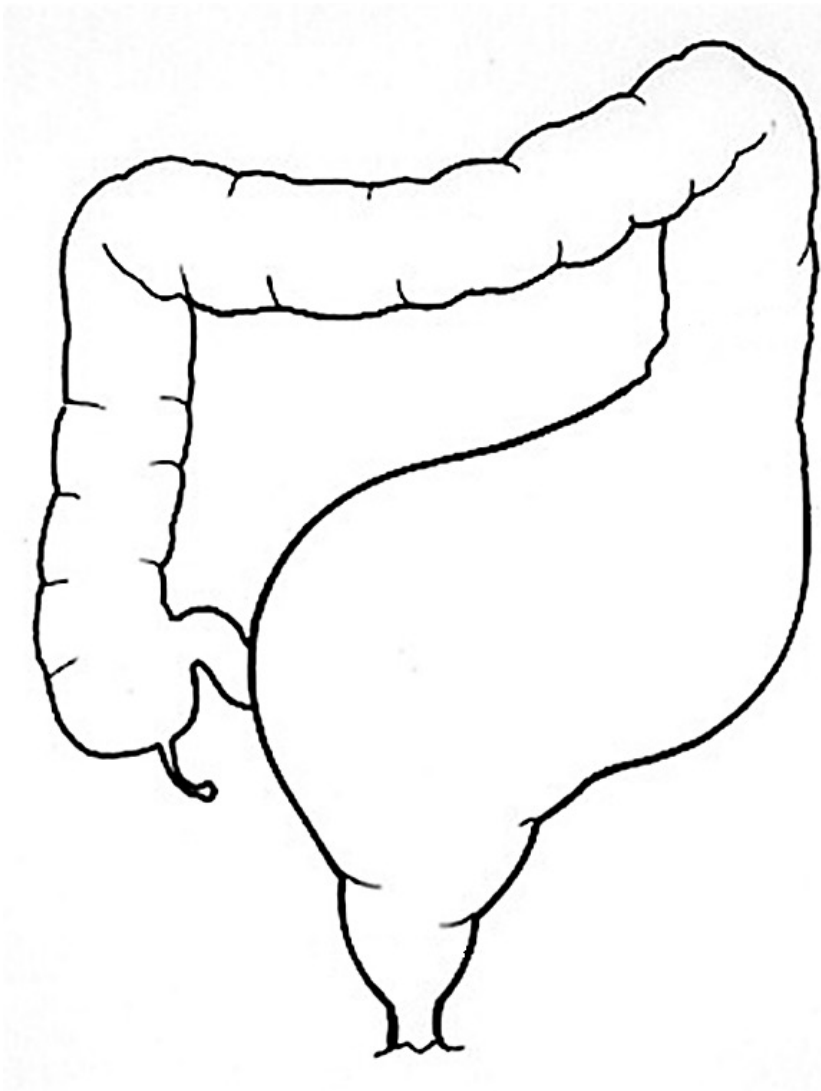


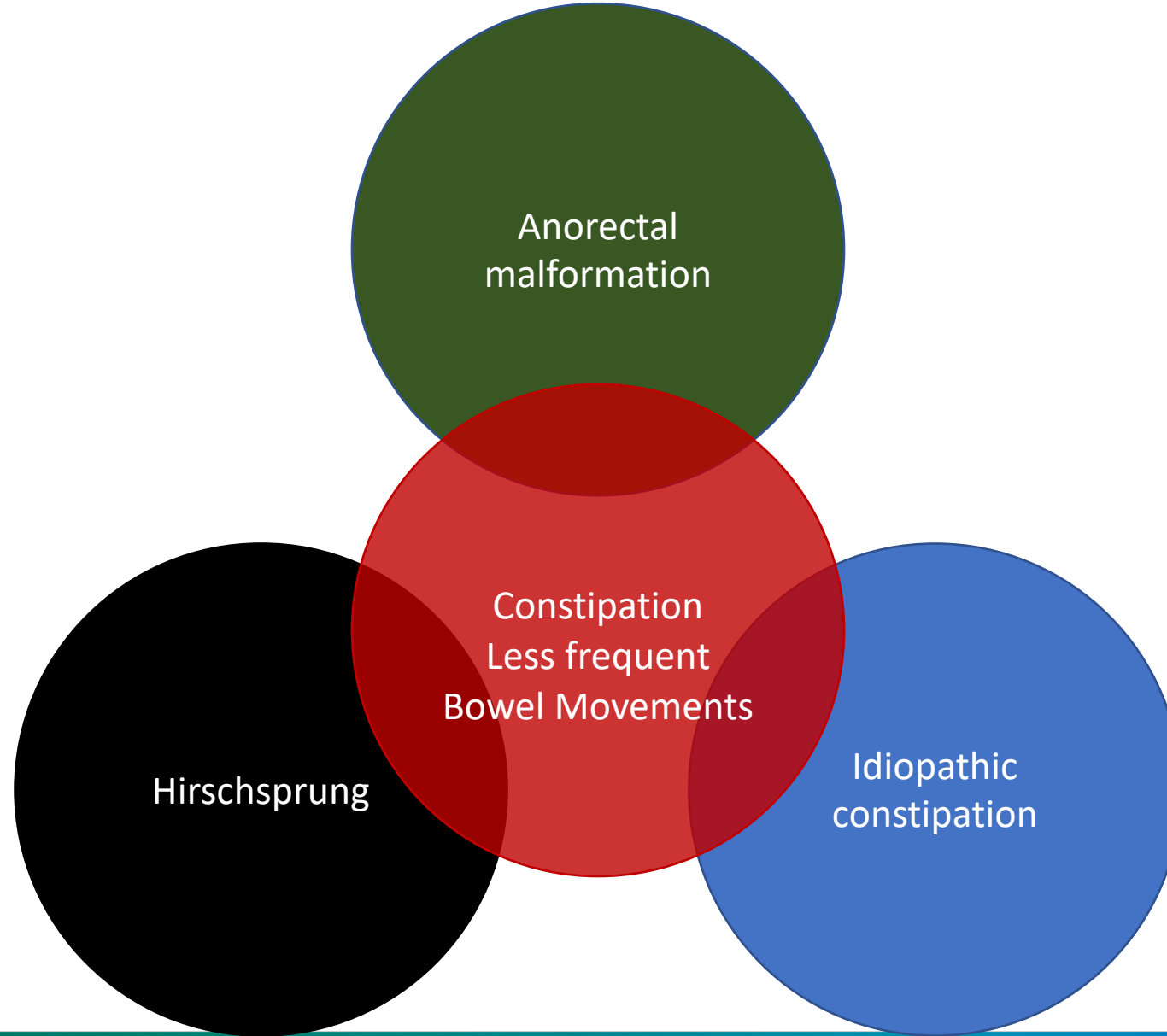
Constipation occurs when bowel movements become less frequent, and stools become difficult to pass.

Hirschsprung disease is a **birth defect** in which nerve cells are missing at the end of a child's bowel, and it does not work well **producing a blockage** in the bowel.











Colitis (enterocolitis)

No bowel movements or explosive with stimulation

No fecal incontinence

No pseudo-fecal incontinence

No encopresis

Do not produce hard, dry, big feces

Enemas make worst the clinical obstruction

Starts at birth

Abdominal x-ray shows significant dilated intestines

The rectum is NOT dilated in the contrast enema

When to think about the Hirschsprung possibility



No colitis (enterocolitis)

Involuntary bowel movements

fecal incontinence

pseudo-fecal incontinence

encopresis

Hard, dry, big feces

Painful bowel movements

Respond to enemas

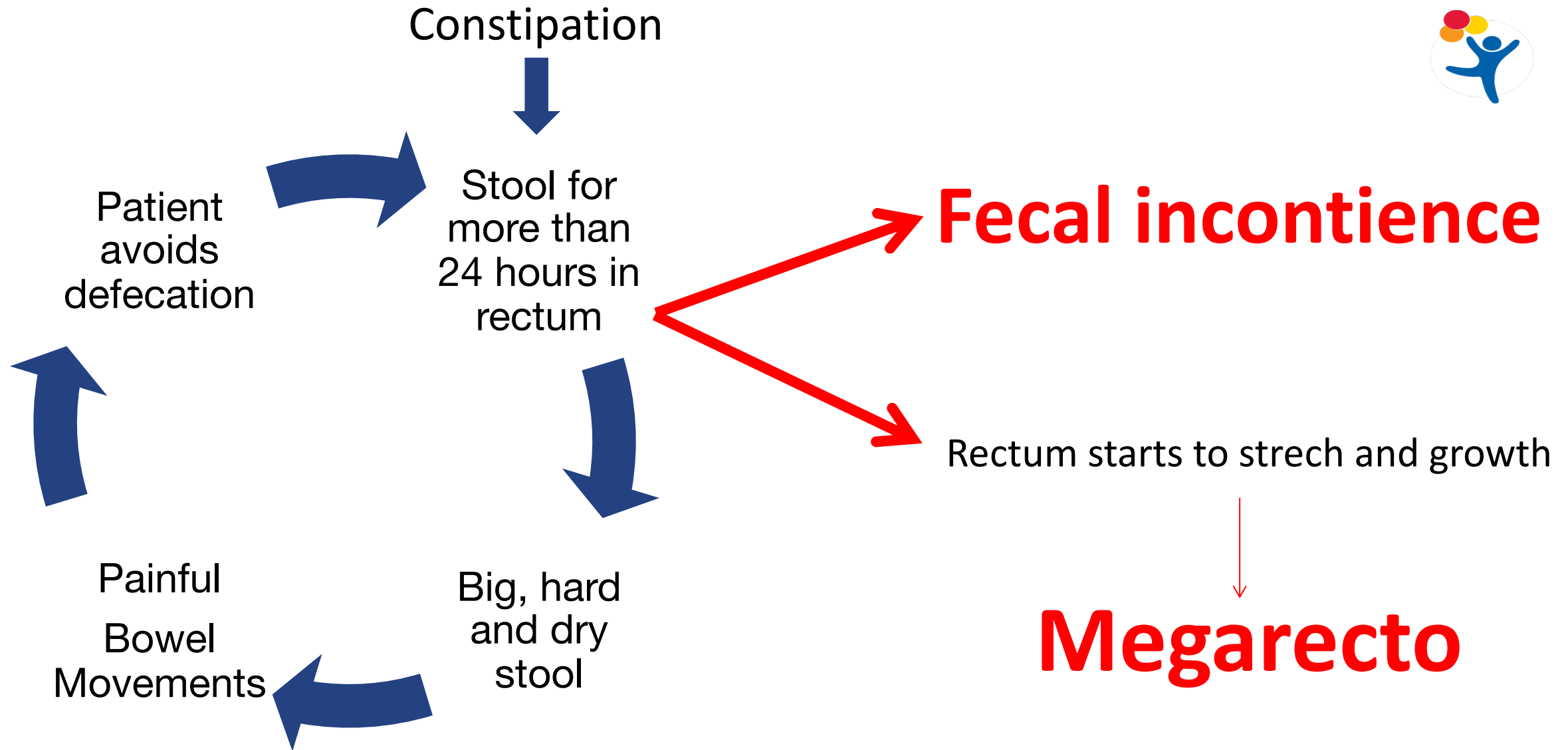
Start at any age, usually after 3-6 months of age

Abdominal x-ray shows significant fecal load

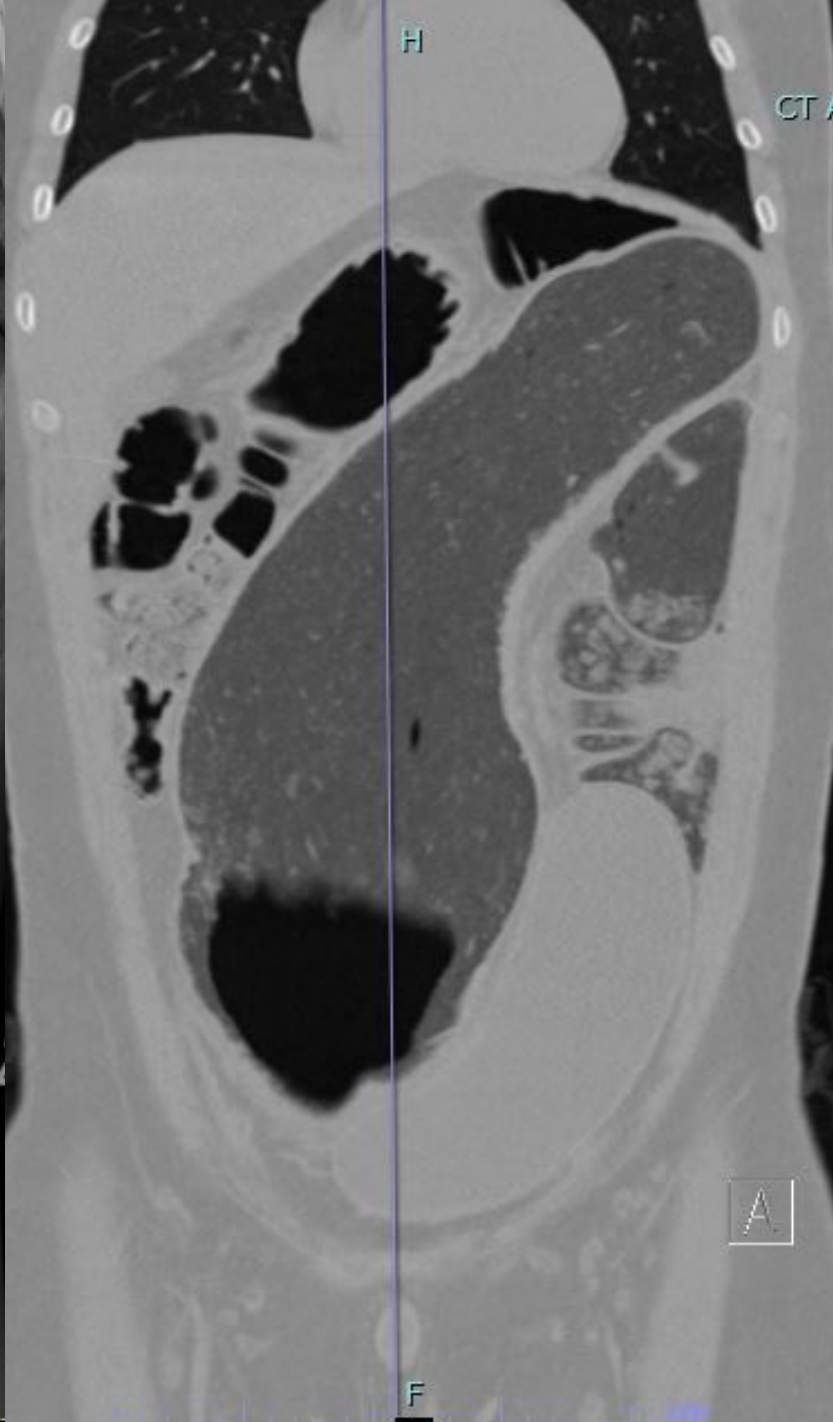
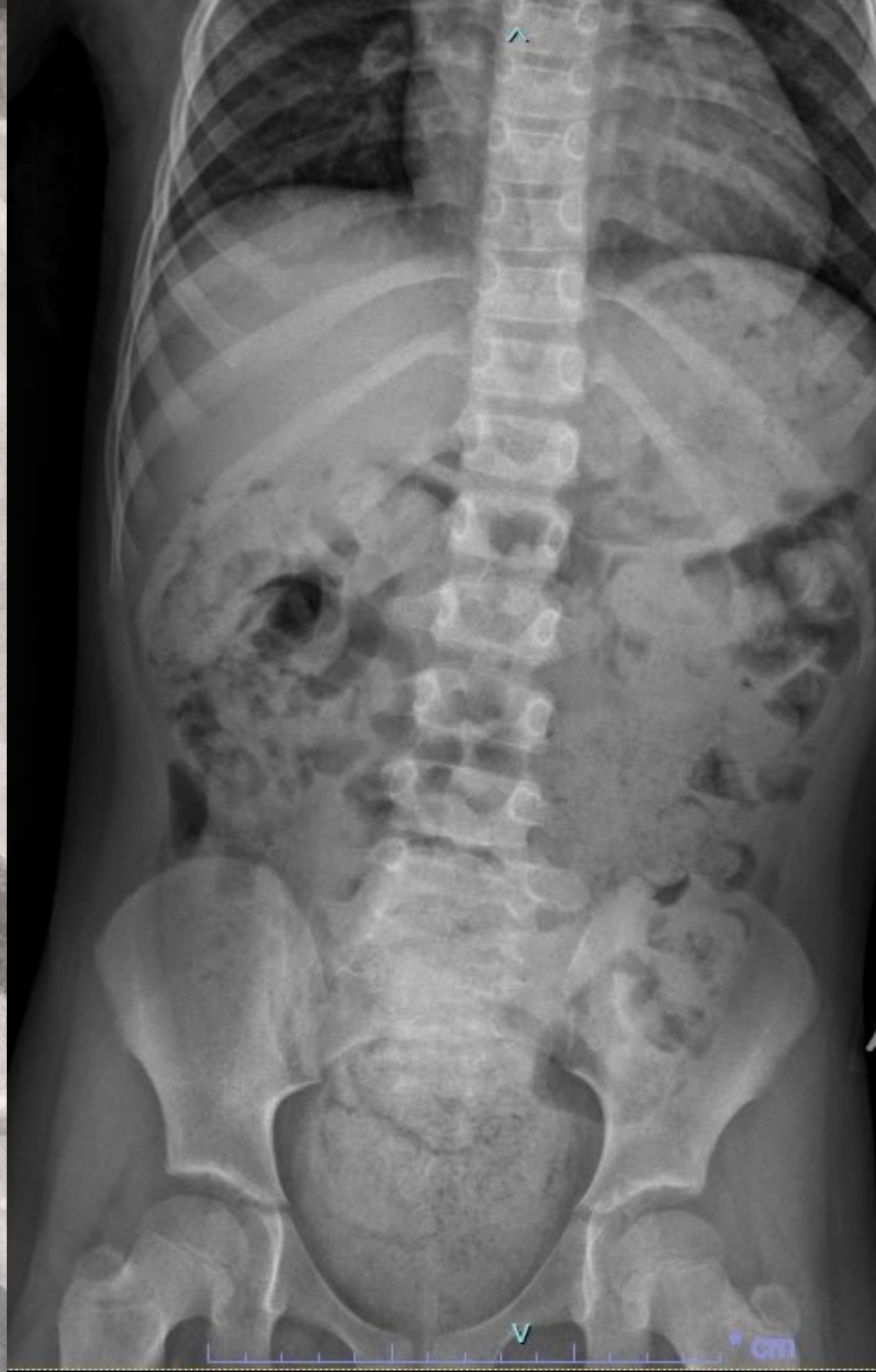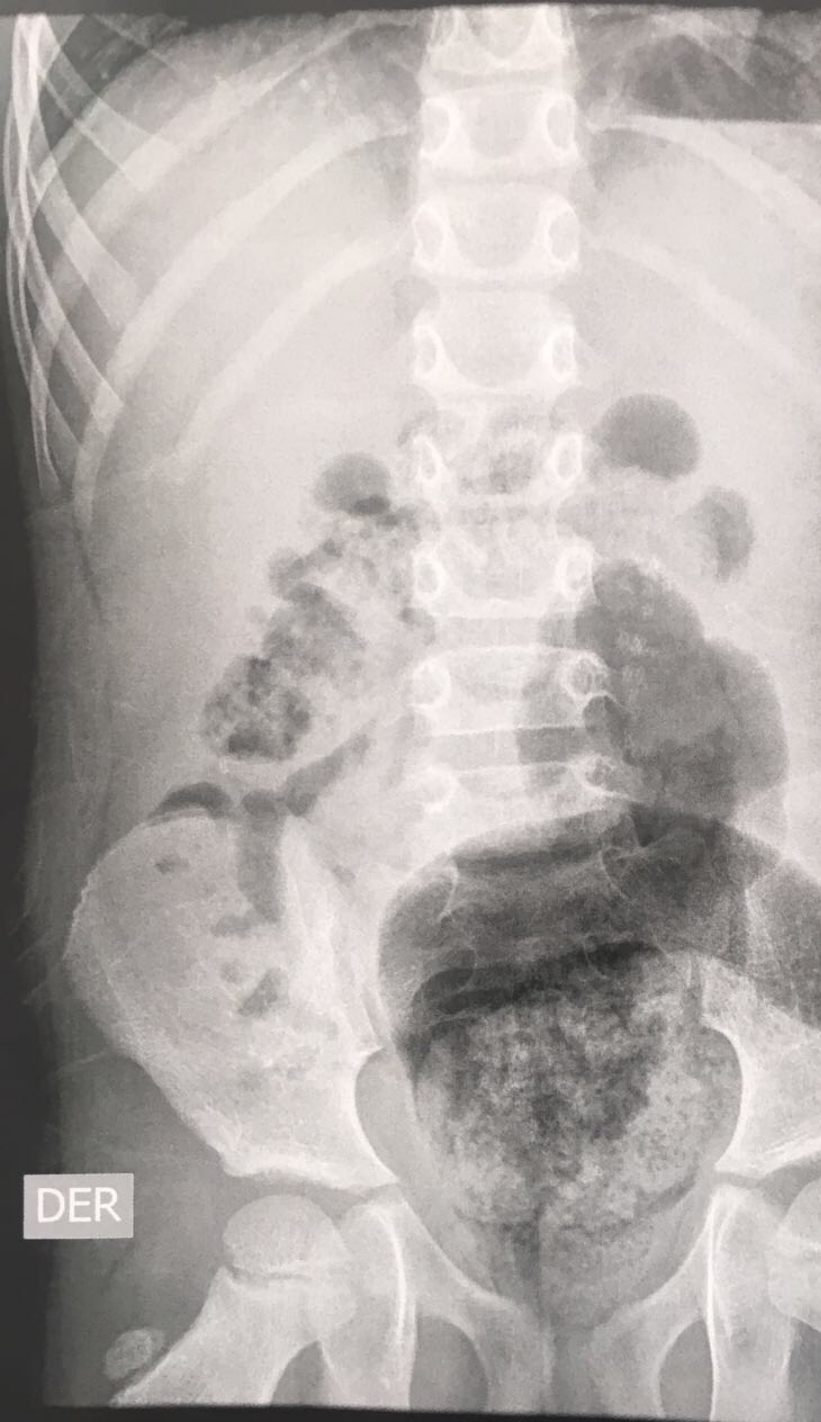The rectum is dilated/enlarged in the contrast enema

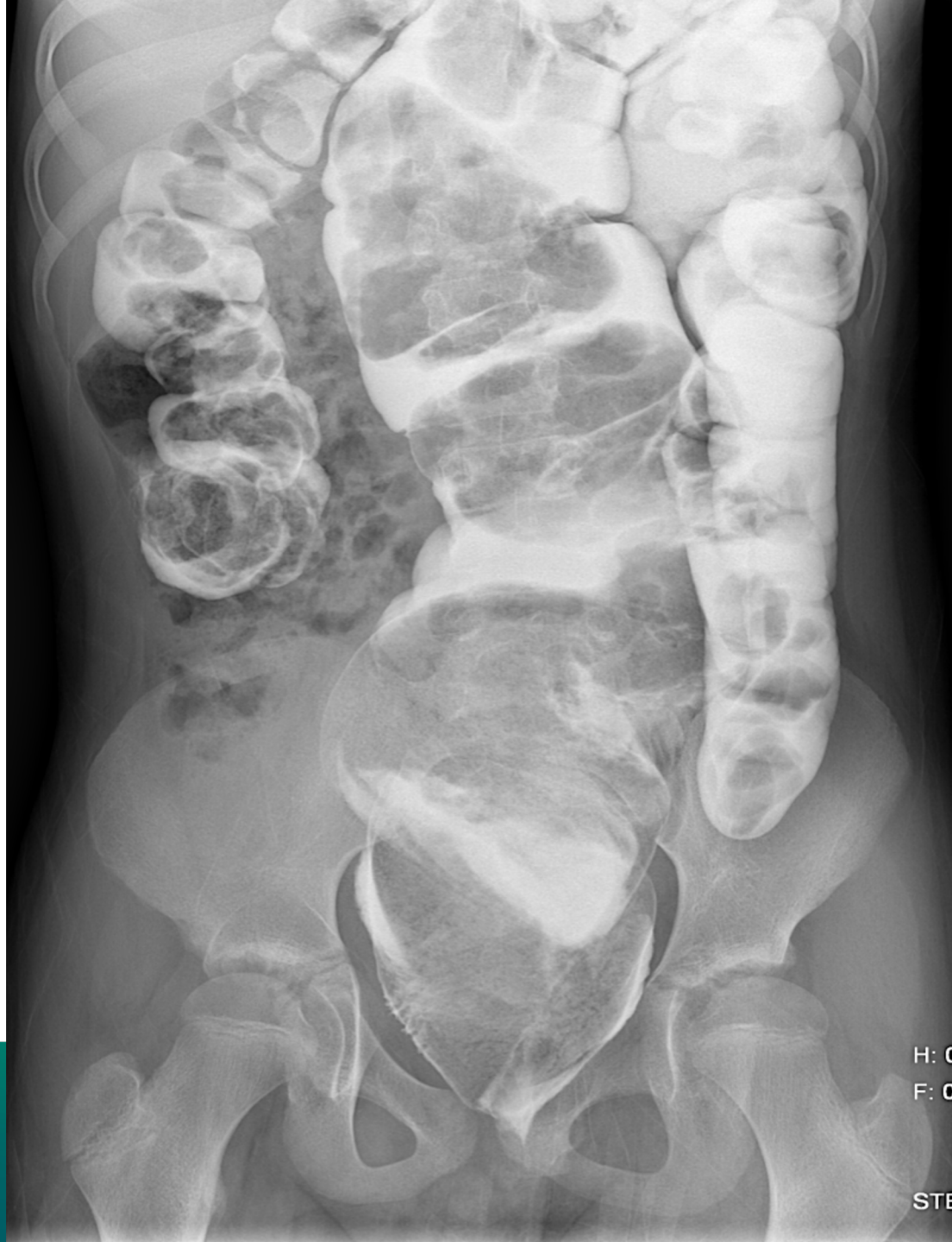When to think about the idiopathic constipation possibility





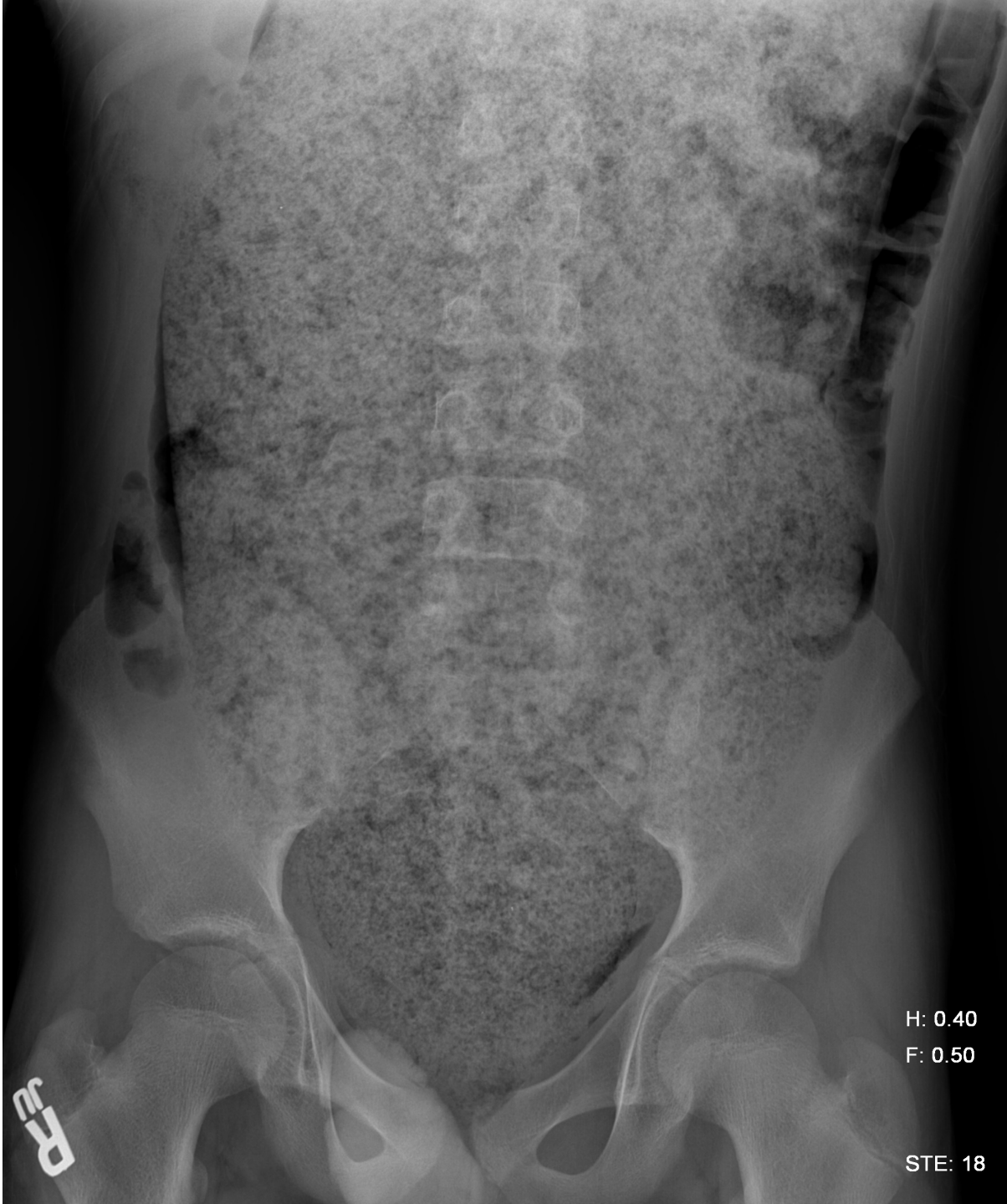





H: 0  
F: 0  
STE

INTERNATIONAL CENTER FOR  
**COLORECTAL AND  
UROGENITAL CARE**

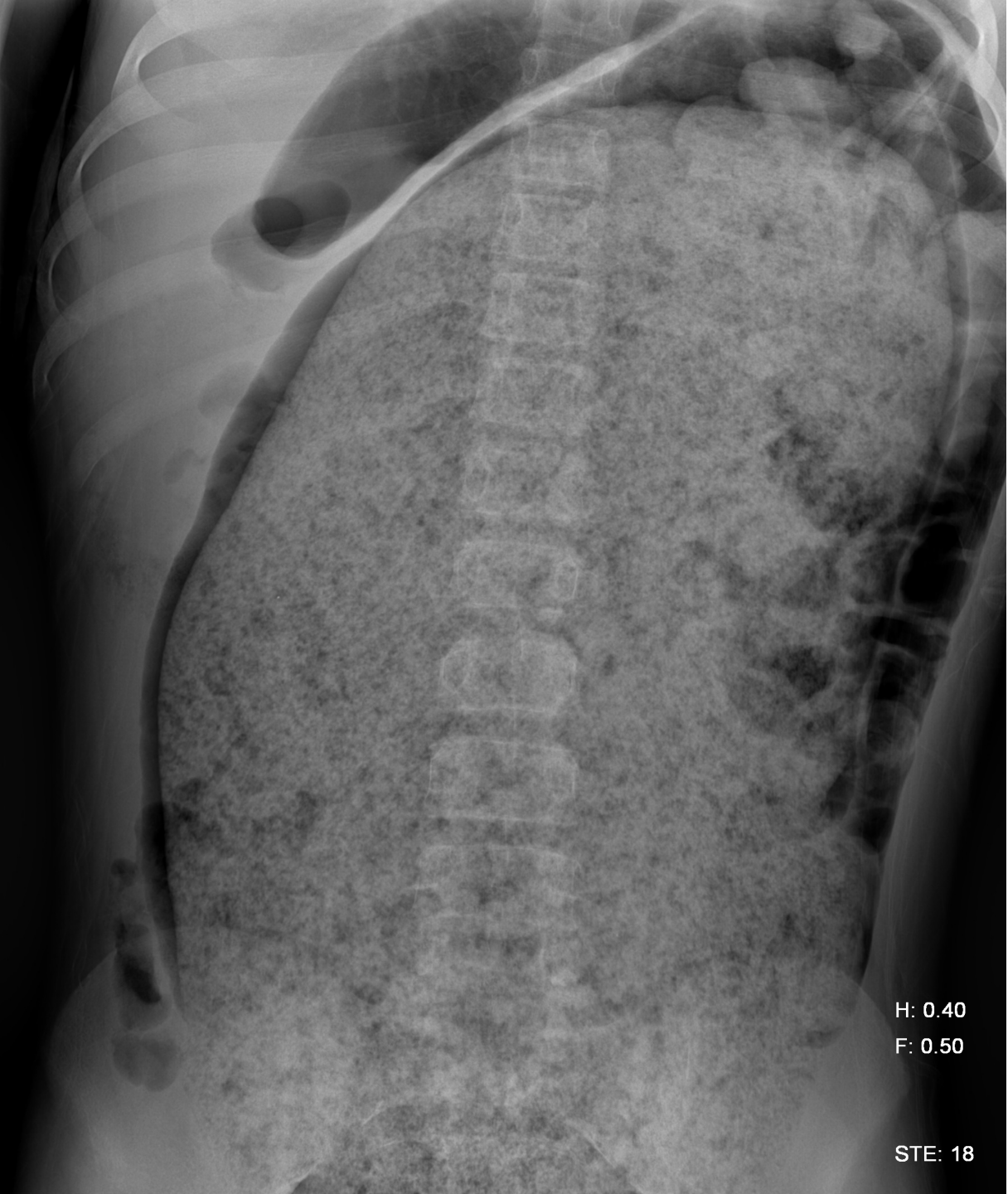

H: 0.40

F: 0.50

STE: 18

MP



H: 0.40

F: 0.50

STE: 18



# Idiopathic constipation

## Acute

Mild

No fecal impaction

Food helps

Osmotic laxatives help

No soiling

No social problem

## Chronic

Fecal impaction (frequent/chronic)

Food does not help

Needs stimulant laxative for many years

Fecal soiling

Important social problem

**Megarectosigmoid**



# What is Pseudo Hirschsprung?

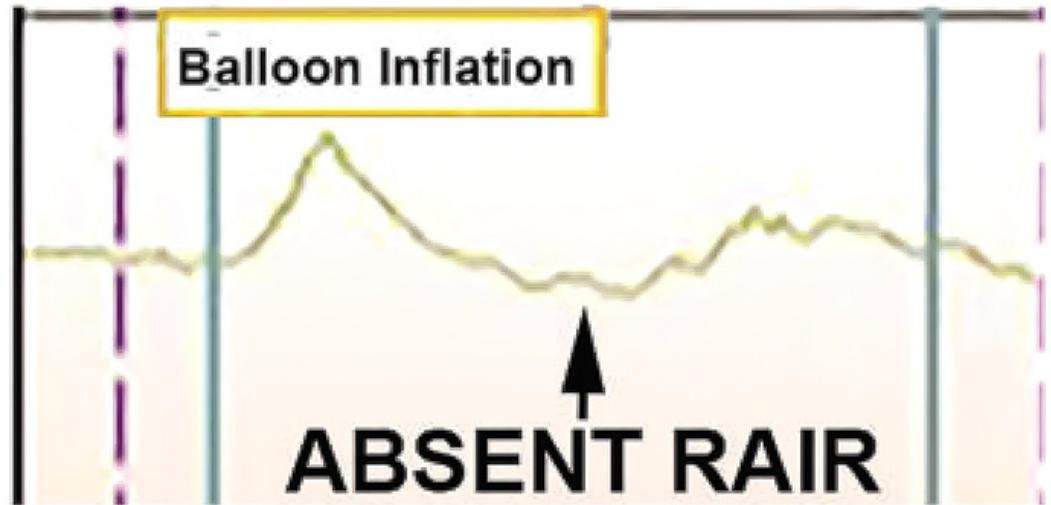

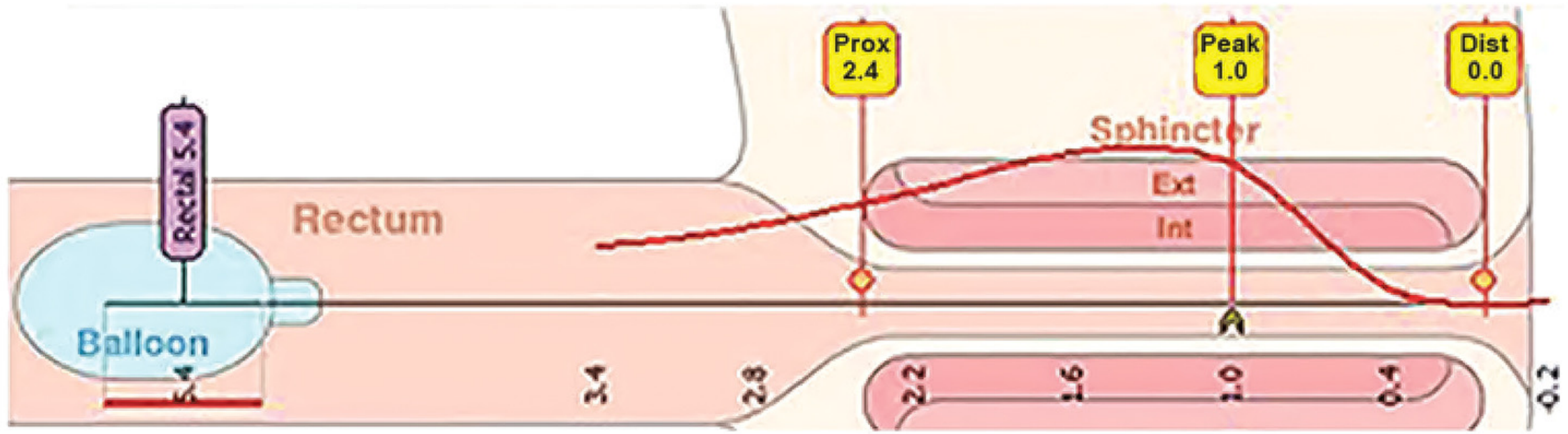
A constipated patient with ganglion cells in the rectum and submitted to a surgical procedure for Hirschsprung.



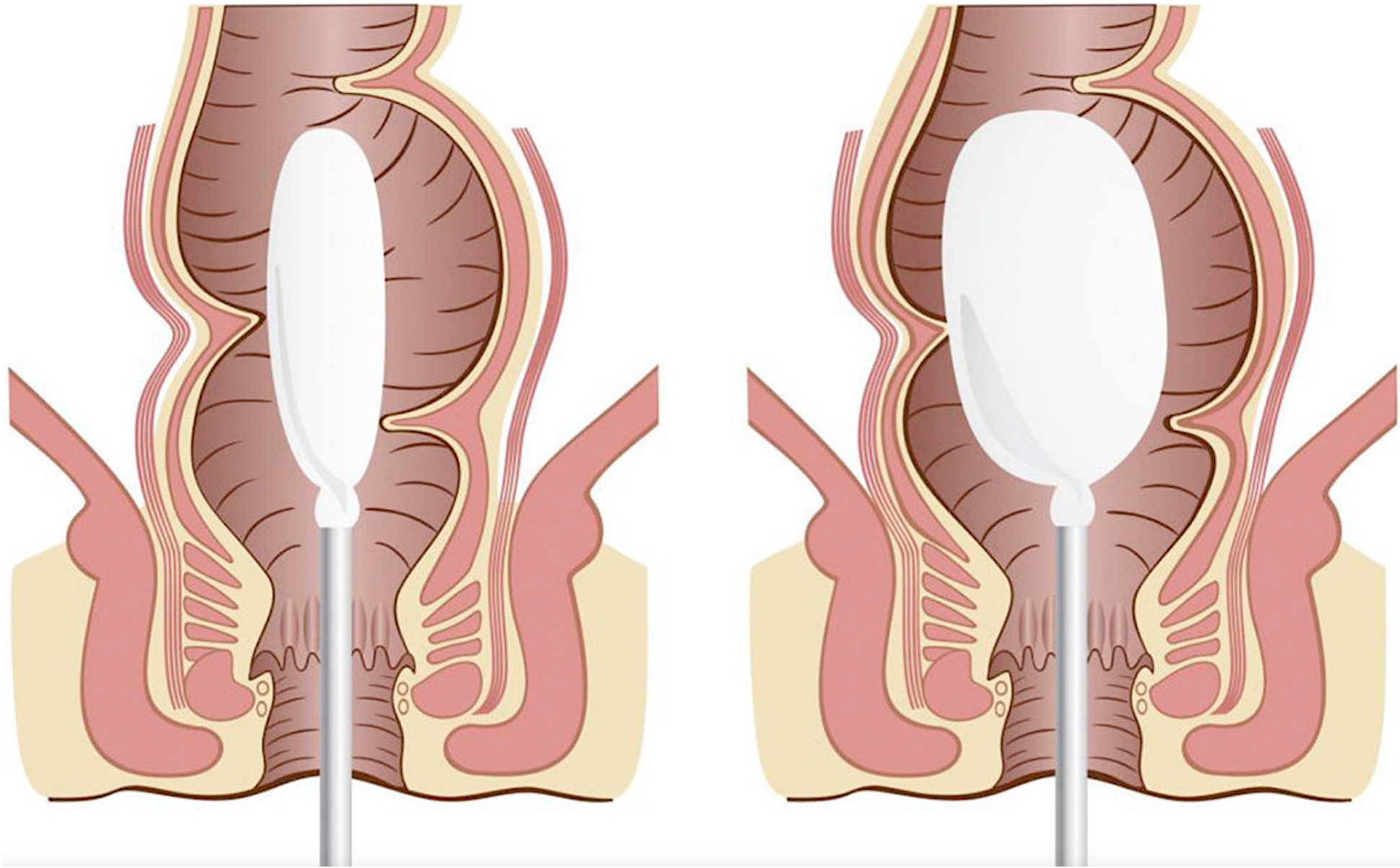
- (1) Patients with idiopathic constipation that are not responding to “the regular” treatment”.
- (2) Out of desperation to find the cause of constipation.
- (3) Due to an error in the performance or interpretation of diagnostic procedures

Why are there cases of pseudo-Hirschsprung?





Recto-anal inhibitory reflex

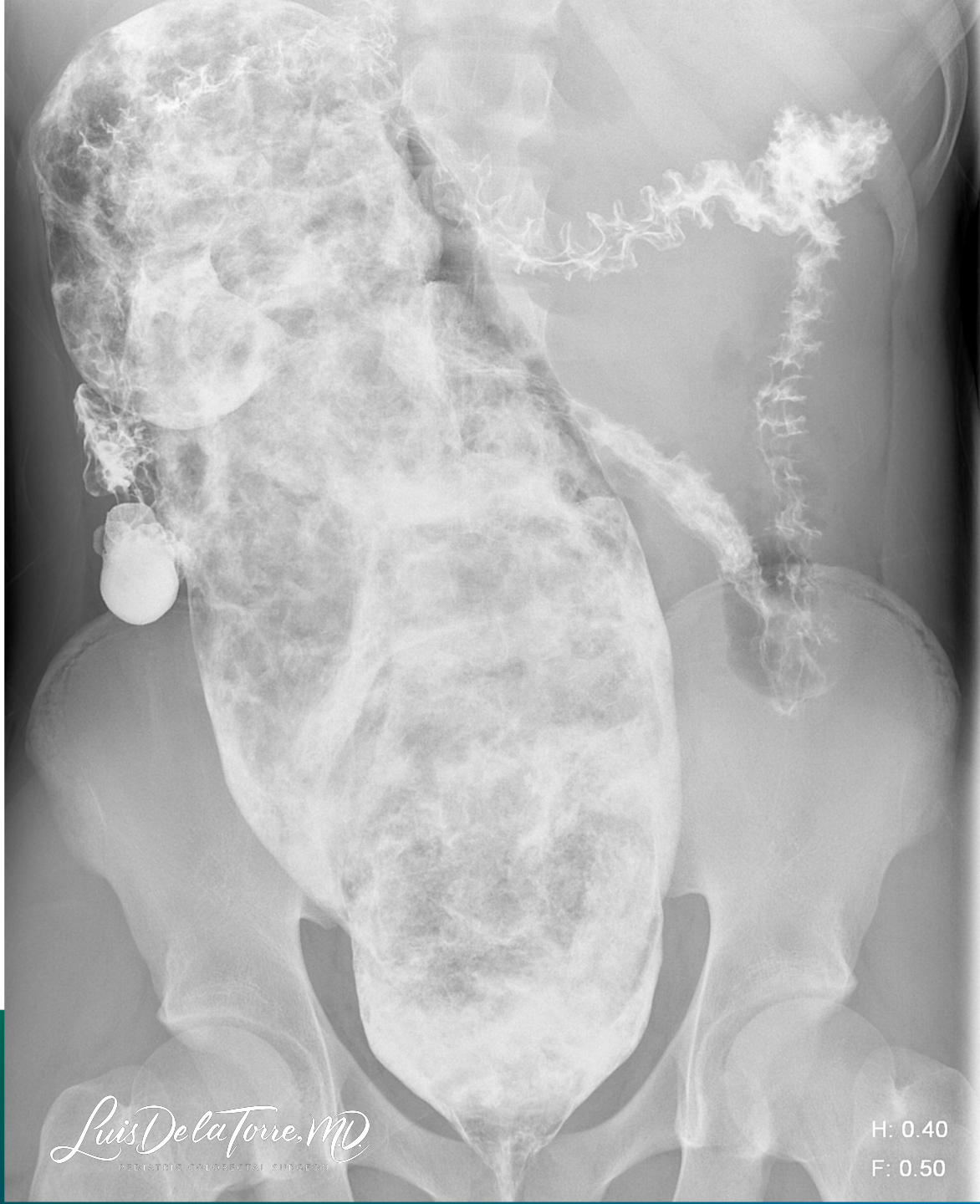

Trap and error



## Trap and error

Radiological diagnosis of  
Ultrashort or short  
Hirschsprung

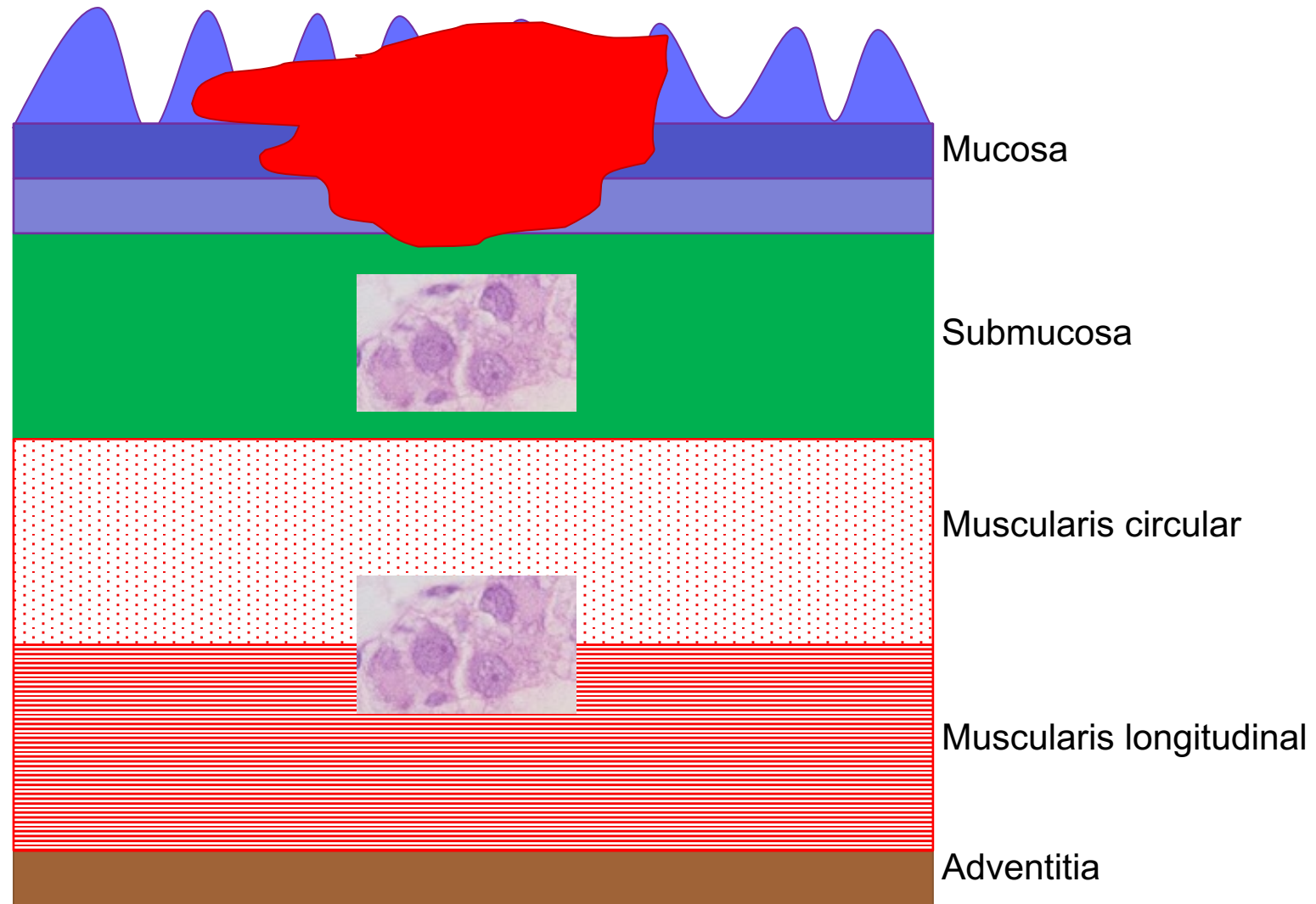


*Luis De la Torre, MD*  
PEDIATRIC COLORECTAL SURGERY

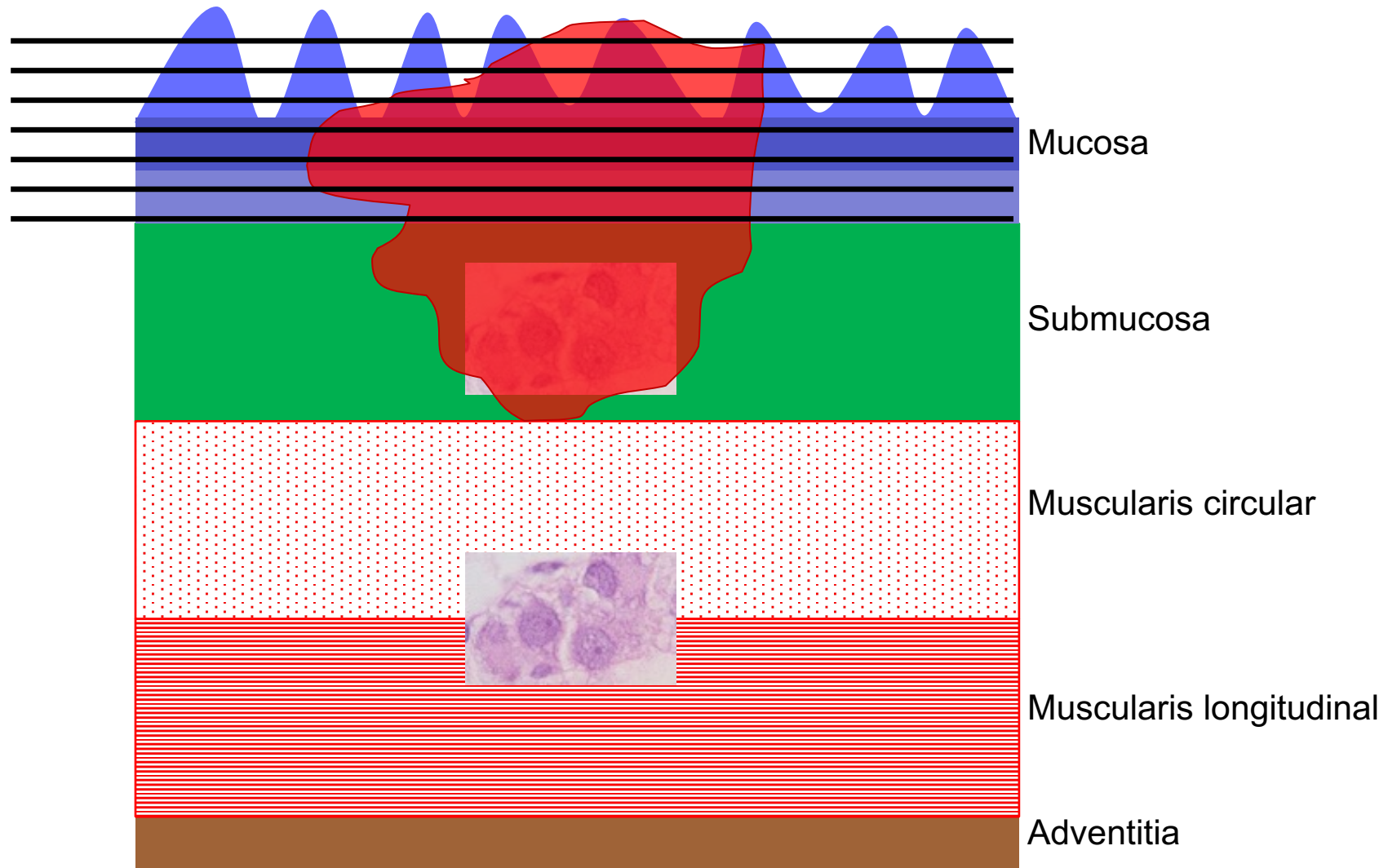
H: 0.40

F: 0.50

INTERNATIONAL CENTER FOR  
**COLORECTAL AND  
UROGENITAL CARE**

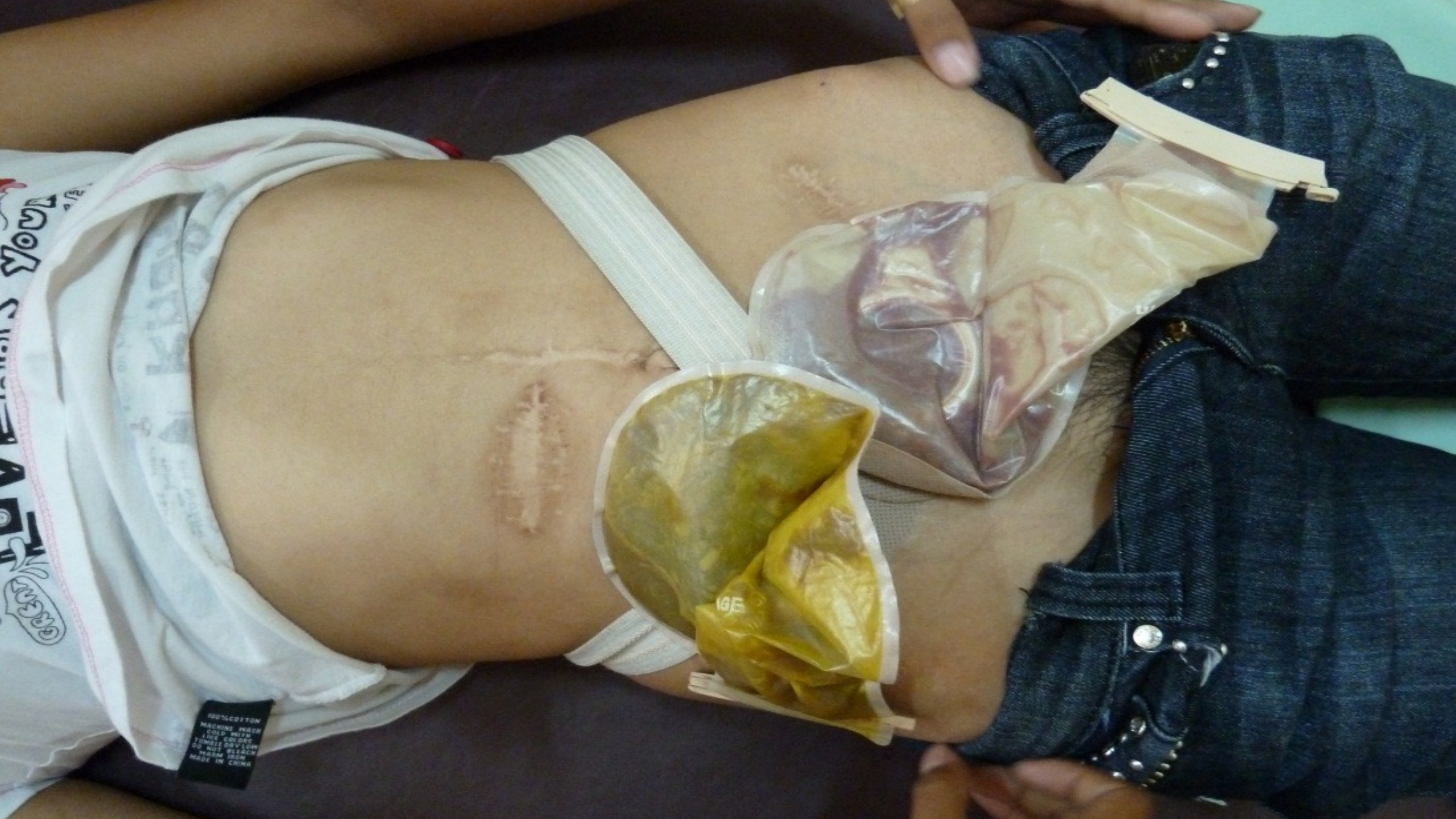

**Error trap** “superficial biopsy”



**Error trap** “few histological sections”

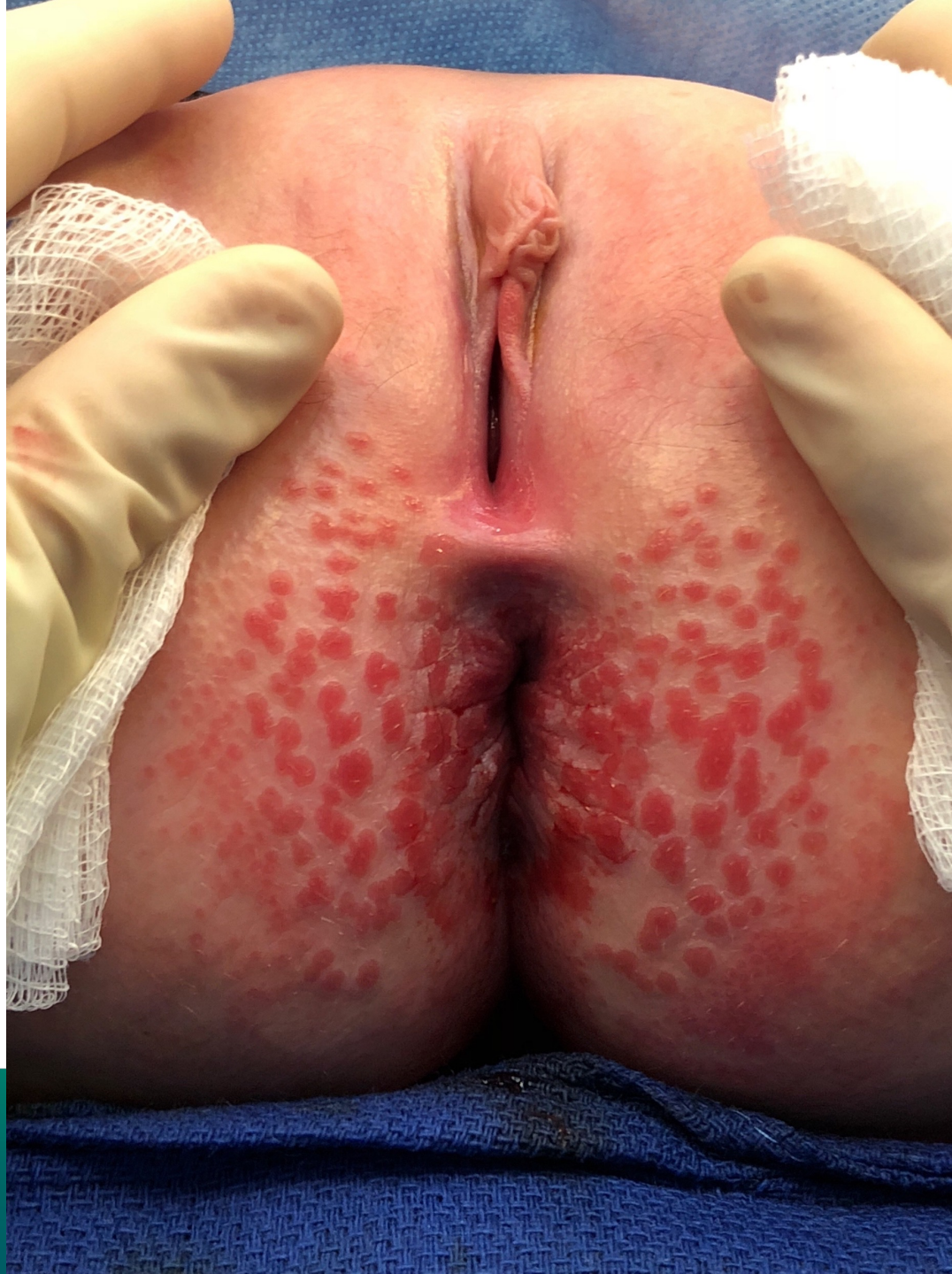INTERNATIONAL CENTER FOR  
**COLORECTAL AND  
UROGENITAL CARE**



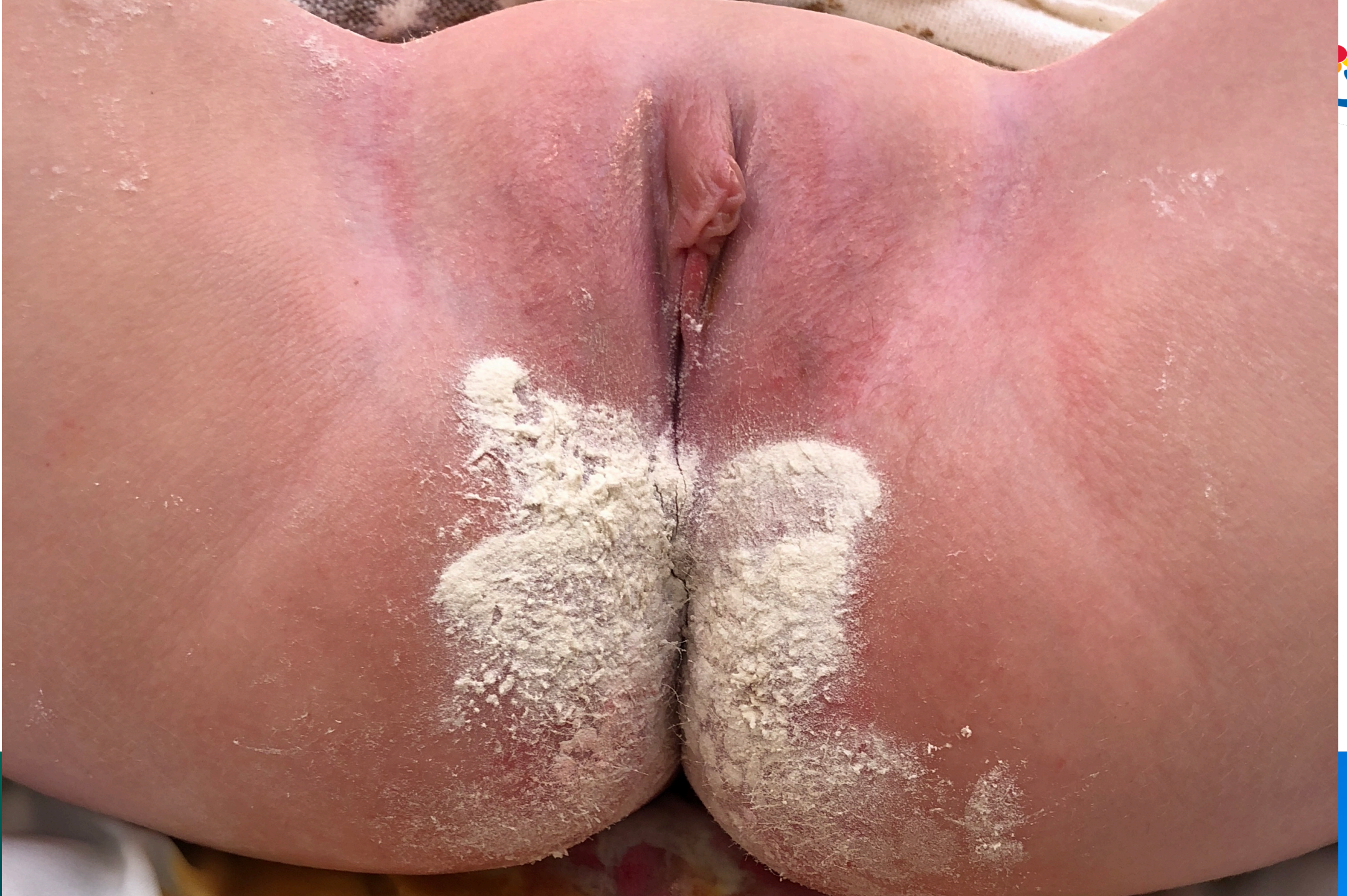LOVE YOURSELF

100% COTTON  
MACHINE WASH  
COLD WATER  
DO NOT BLEACH  
MADE IN CHINA

16E

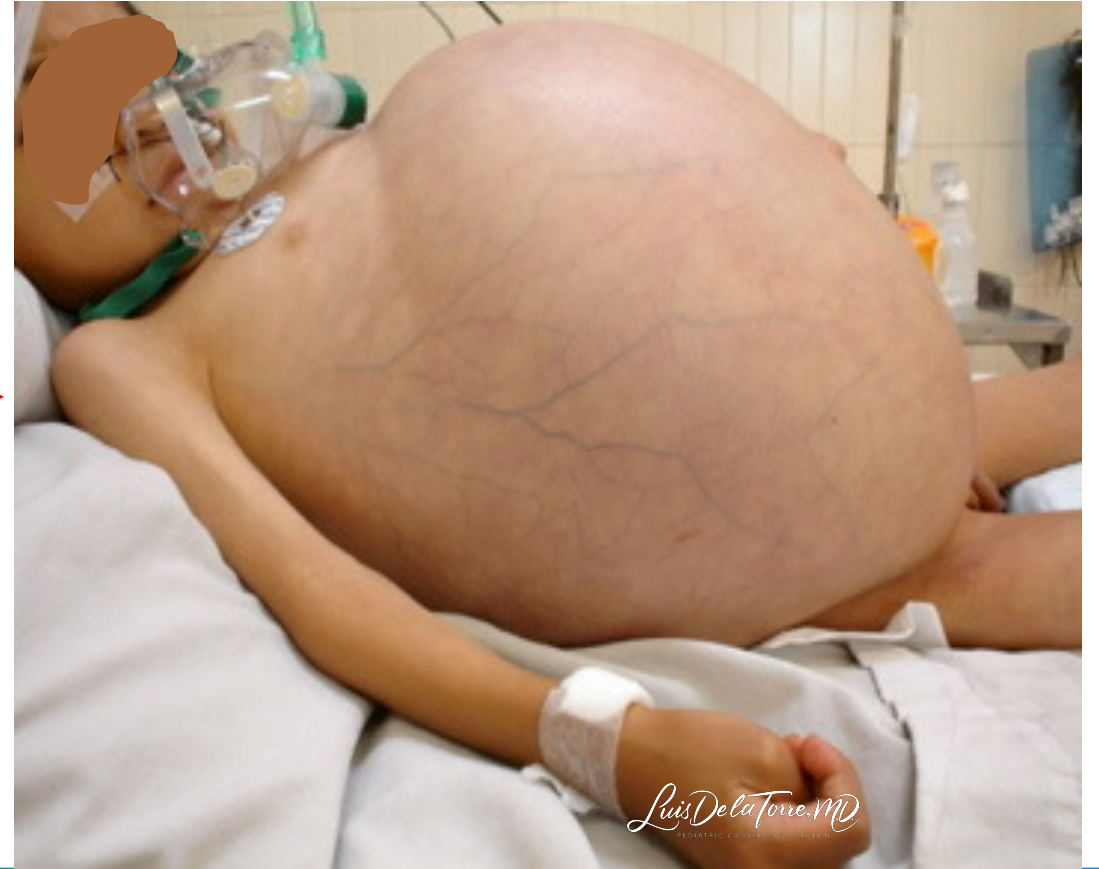

INTERNATIONAL CENTER FOR  
**COLORECTAL AND  
UROGENITAL CARE**





# Idiopathic constipation





INTERNATIONAL CENTER FOR  
**COLORECTAL AND  
UROGENITAL CARE**

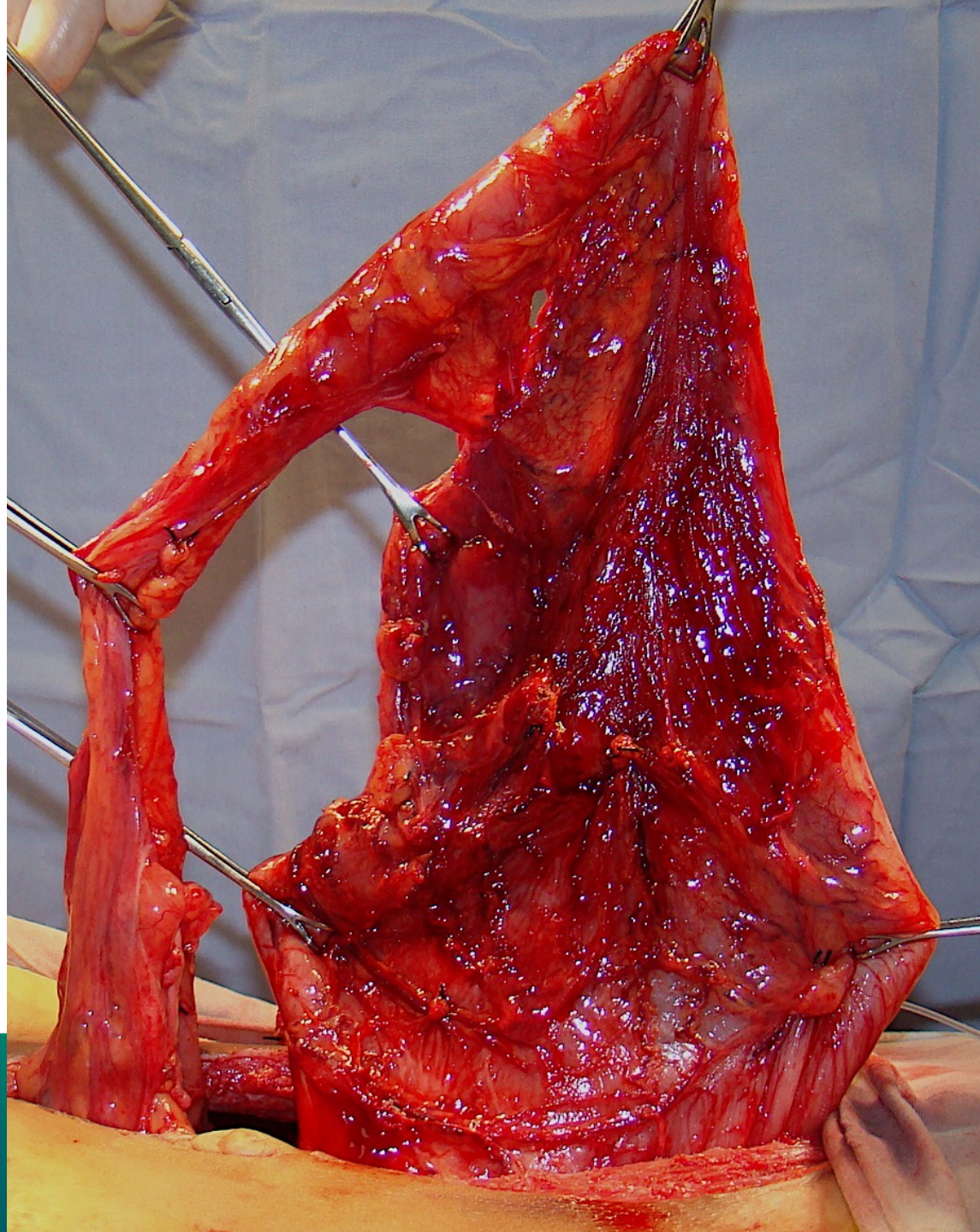
Thank you,  
[luis.delatorre@childrenscolorado.org](mailto:luis.delatorre@childrenscolorado.org)

---

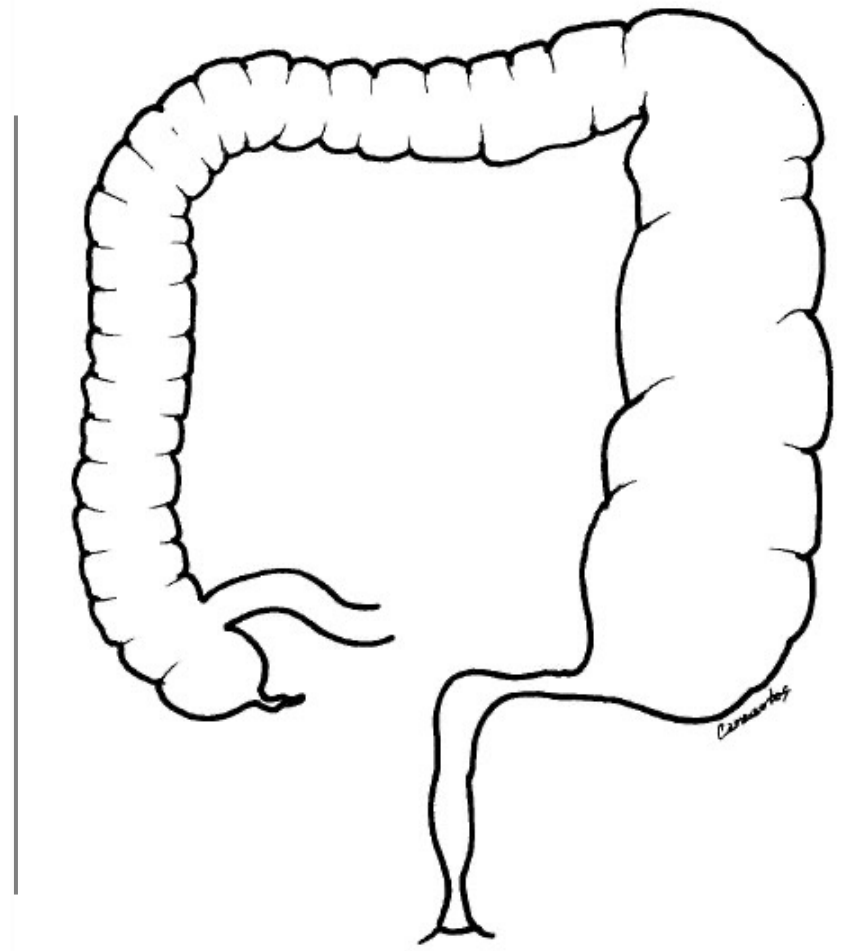
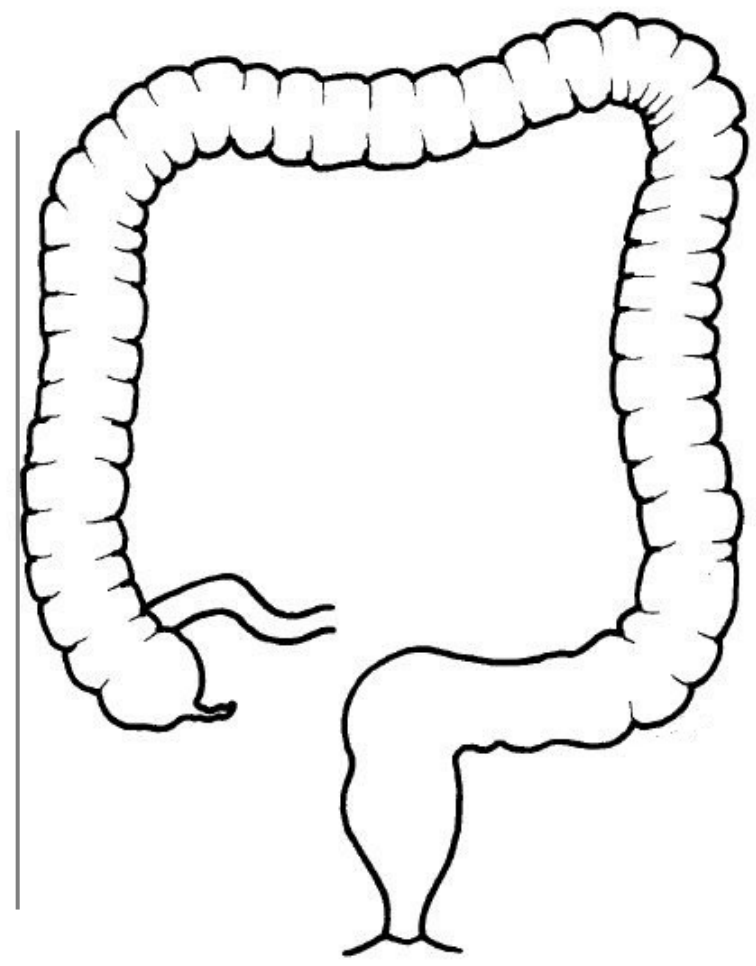
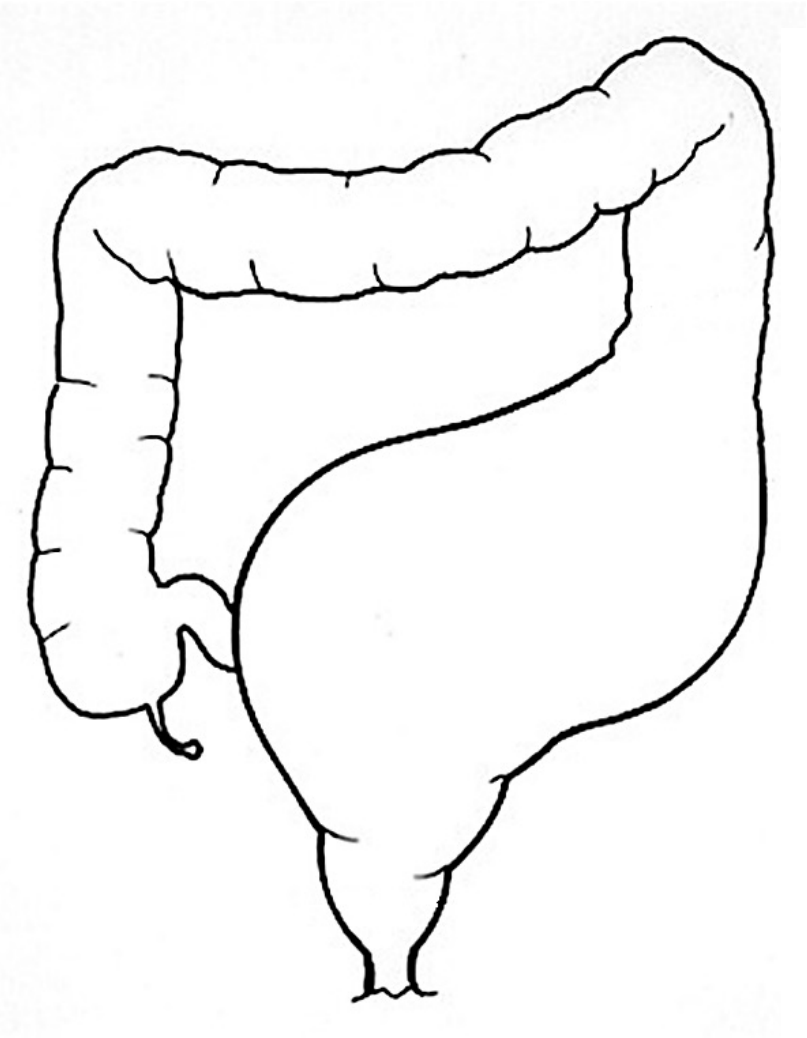


Children's Hospital Colorado

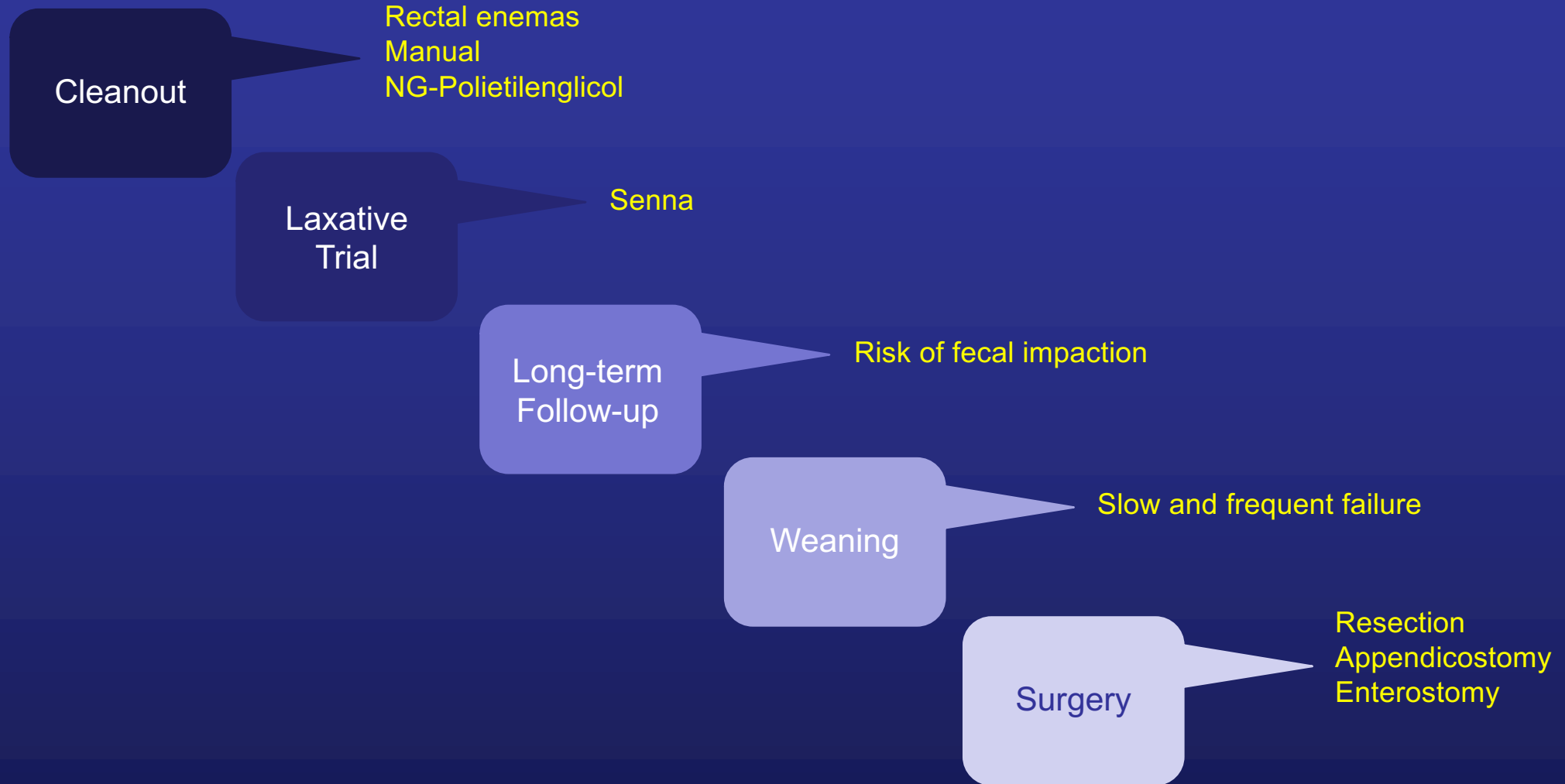
INTERNATIONAL CENTER FOR  
**COLORECTAL AND  
UROGENITAL CARE**




INTERNATIONAL CENTER FOR  
**COLORECTAL AND  
GYNECOLOGICAL CARE**



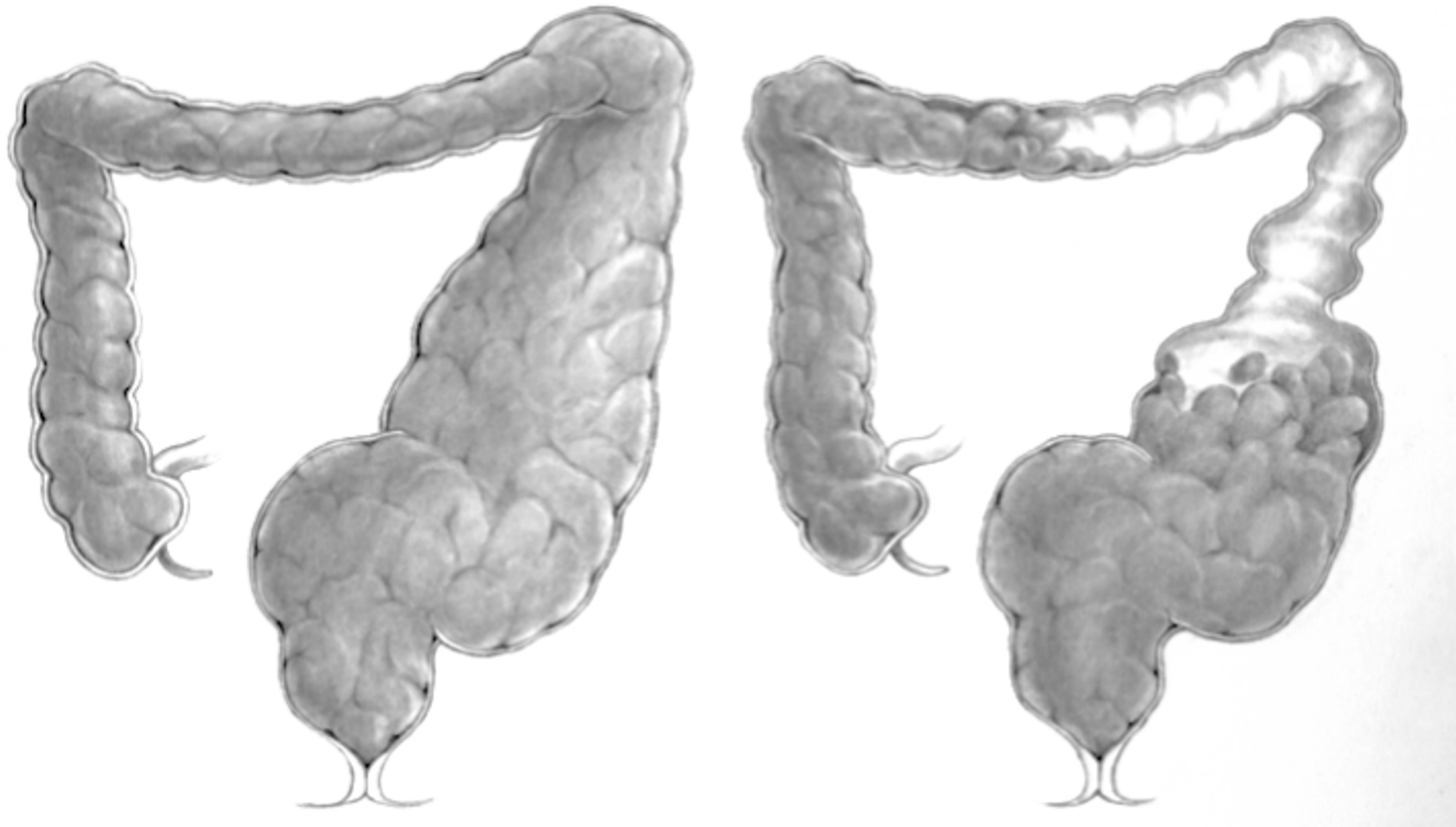
# Guidelines Treatment Complicated Idiopathic Constipation



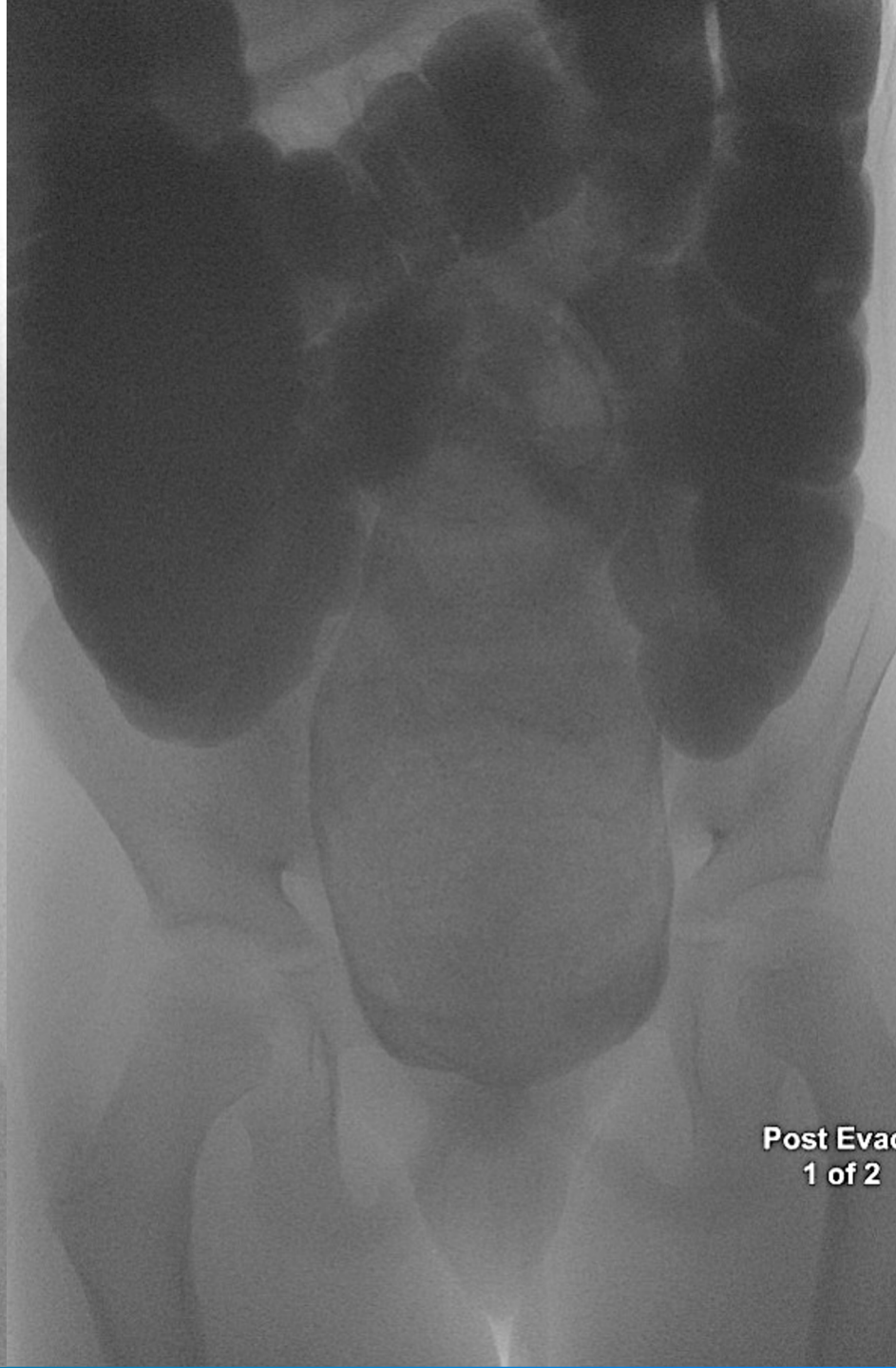
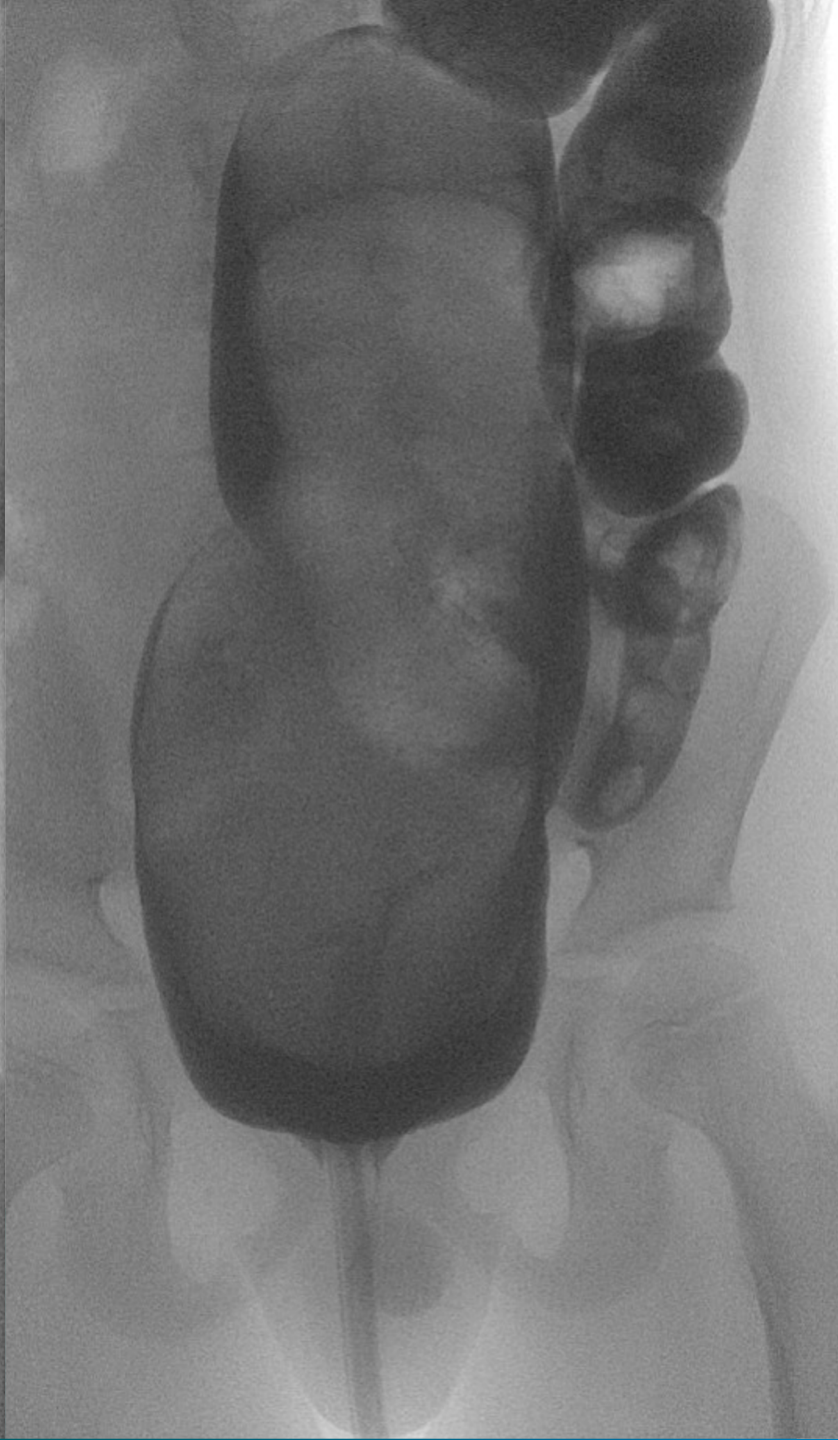
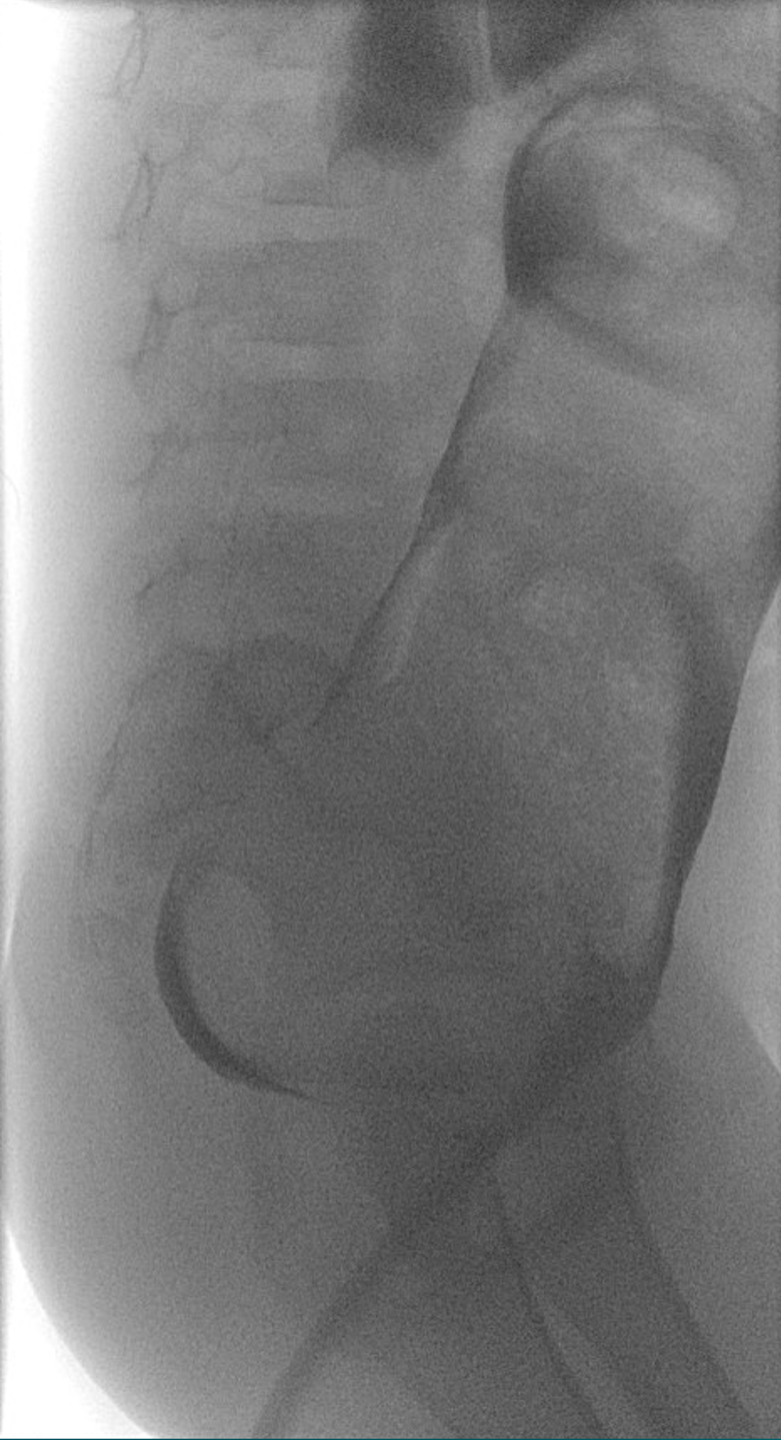Kwanyama mother giving enema to her baby boy.

INTERNATIONAL CENTER FOR  
**COLORECTAL AND  
UROGENITAL CARE**





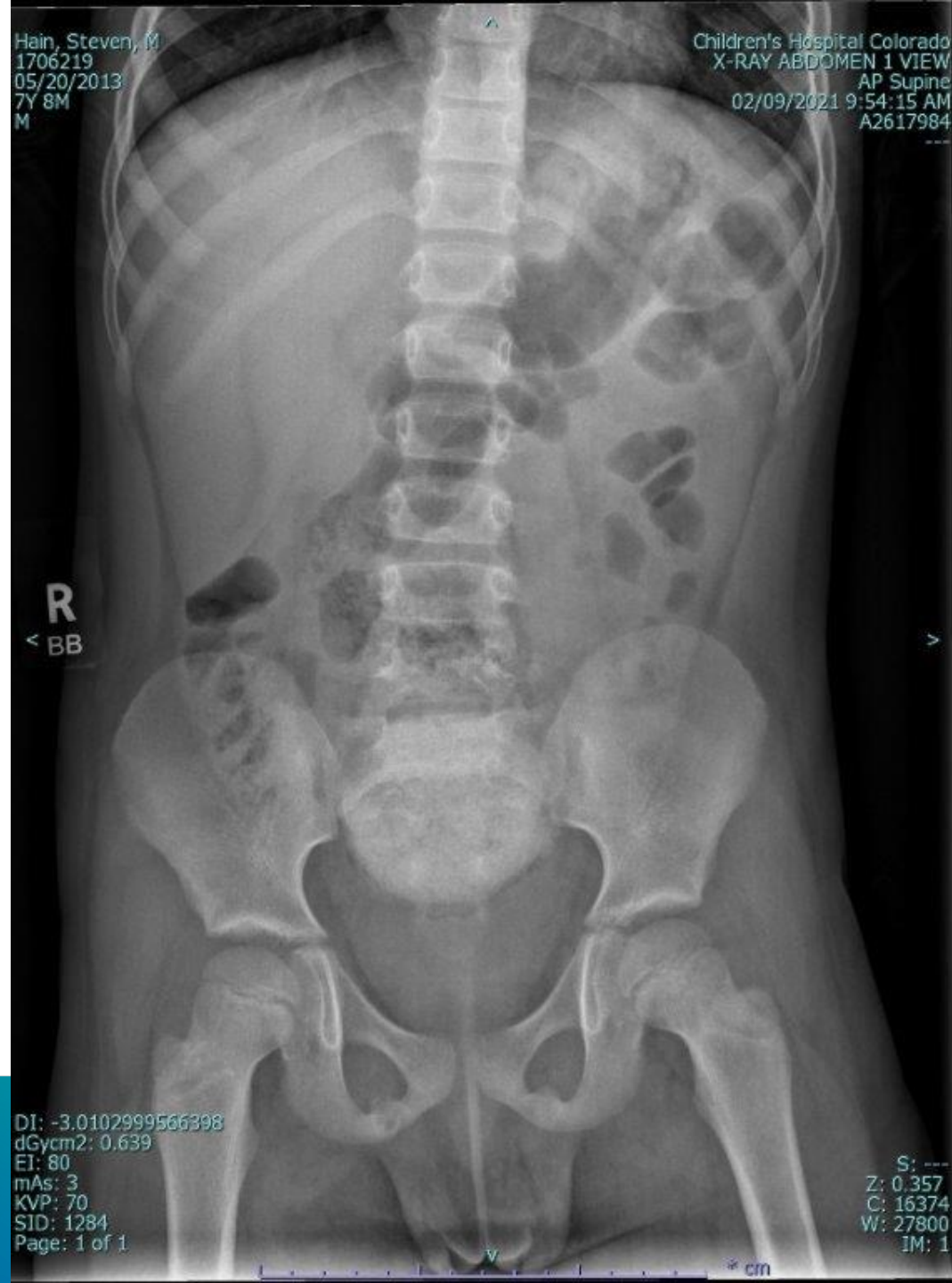
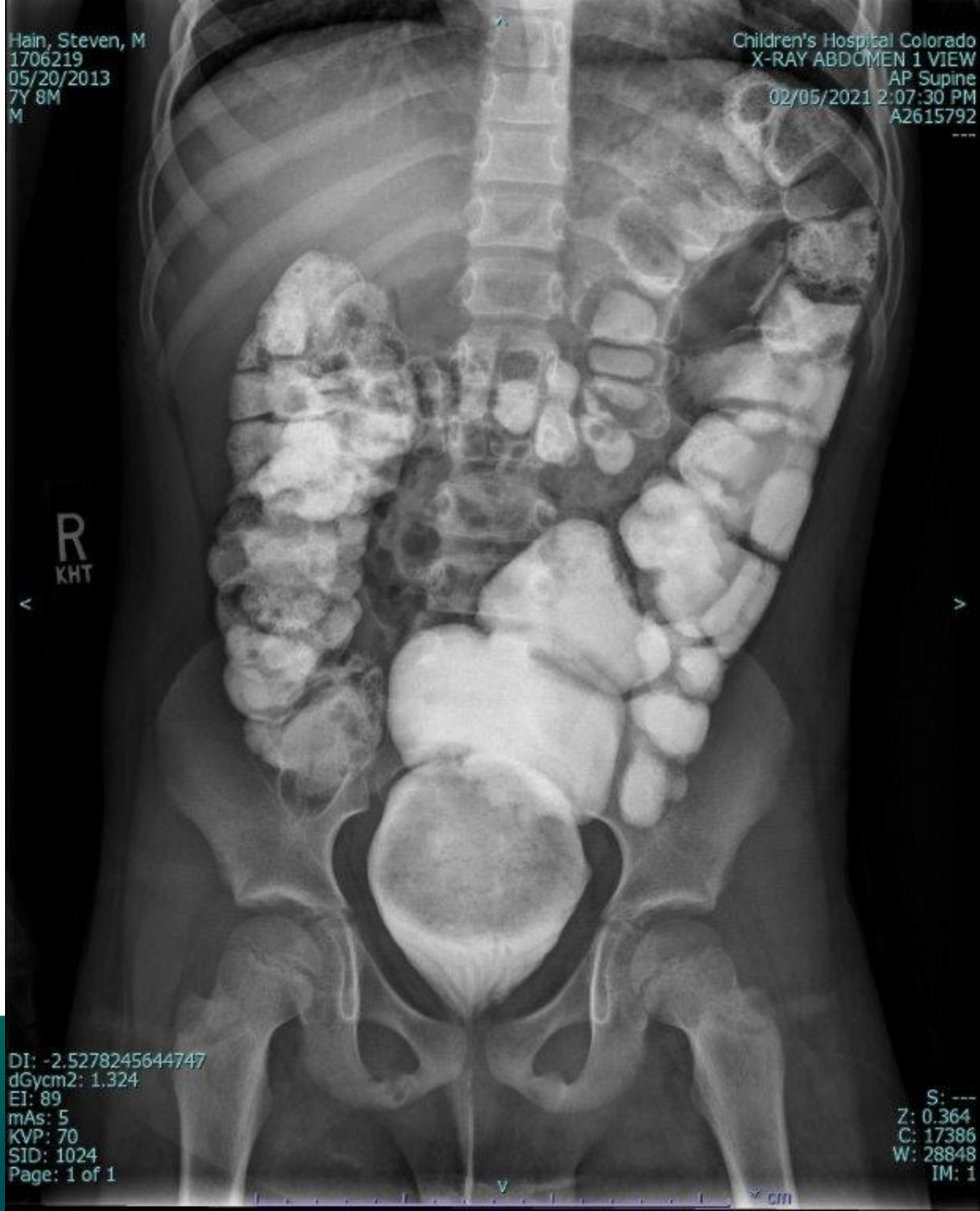
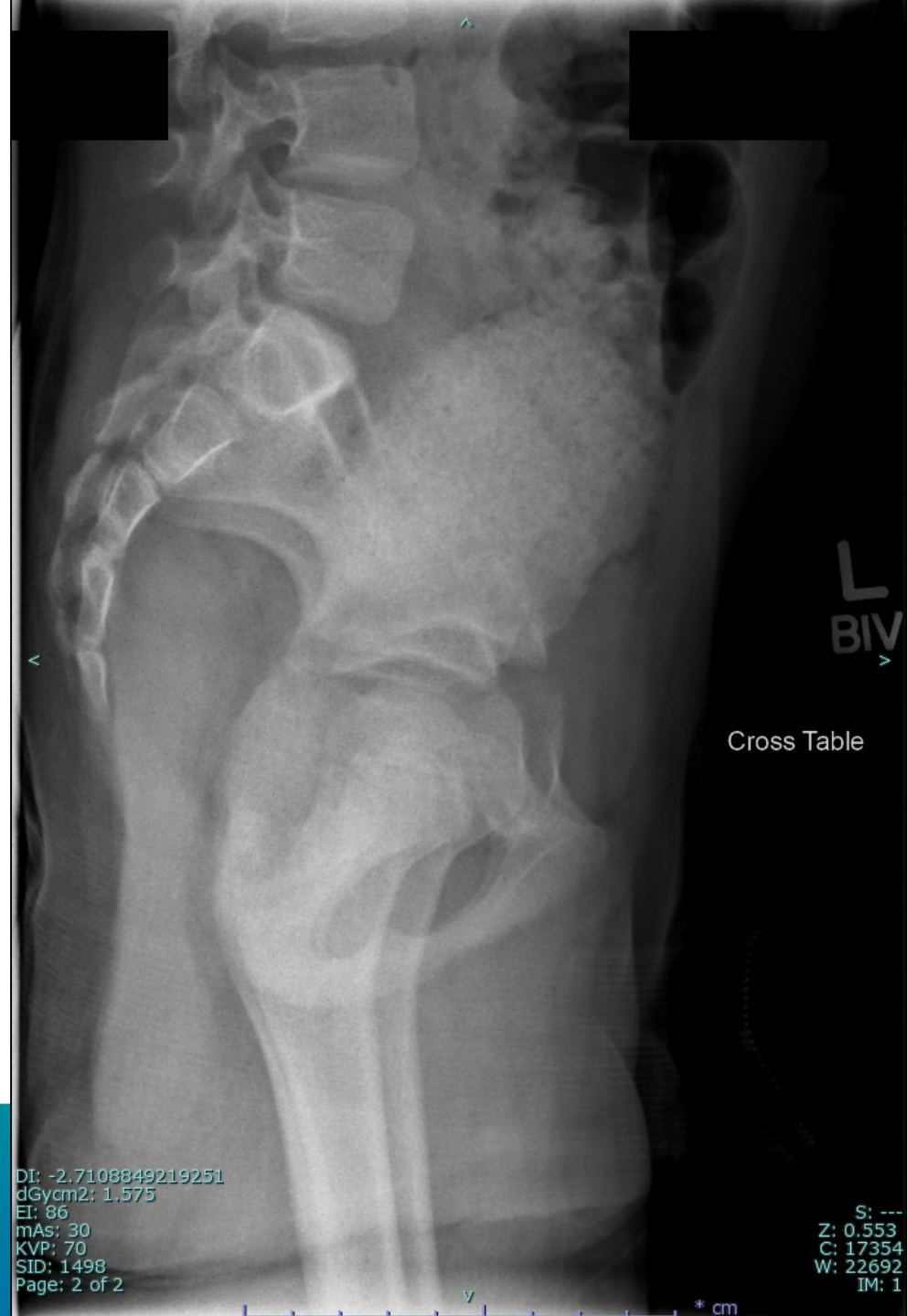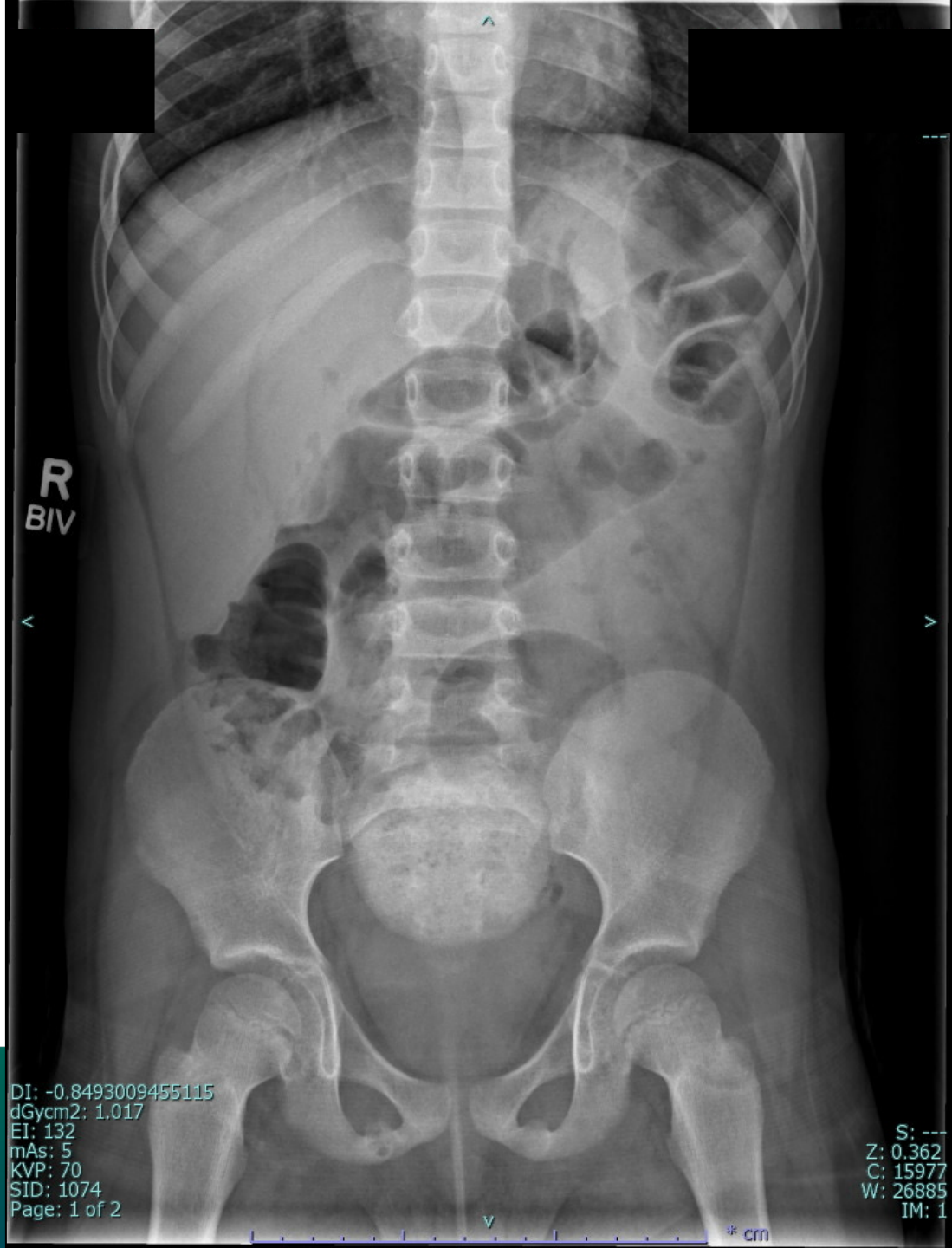Hain, Steven, M  
1706219  
05/20/2013  
7Y 8M  
M

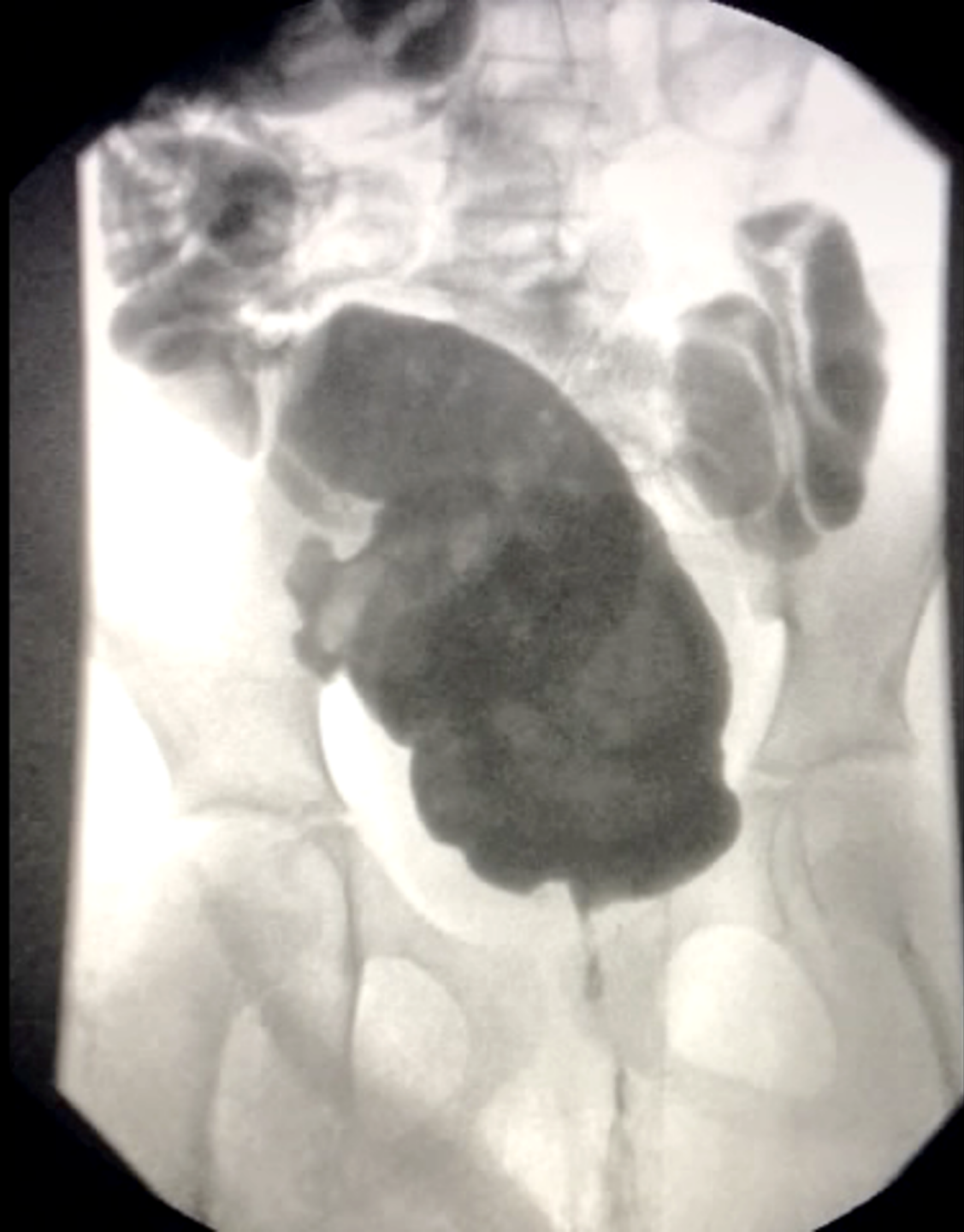Children's Hospital Colorado  
X-RAY ABDOMEN 1 VIEW  
AP Supine  
02/05/2021 2:07:30 PM  
A2615792  
---

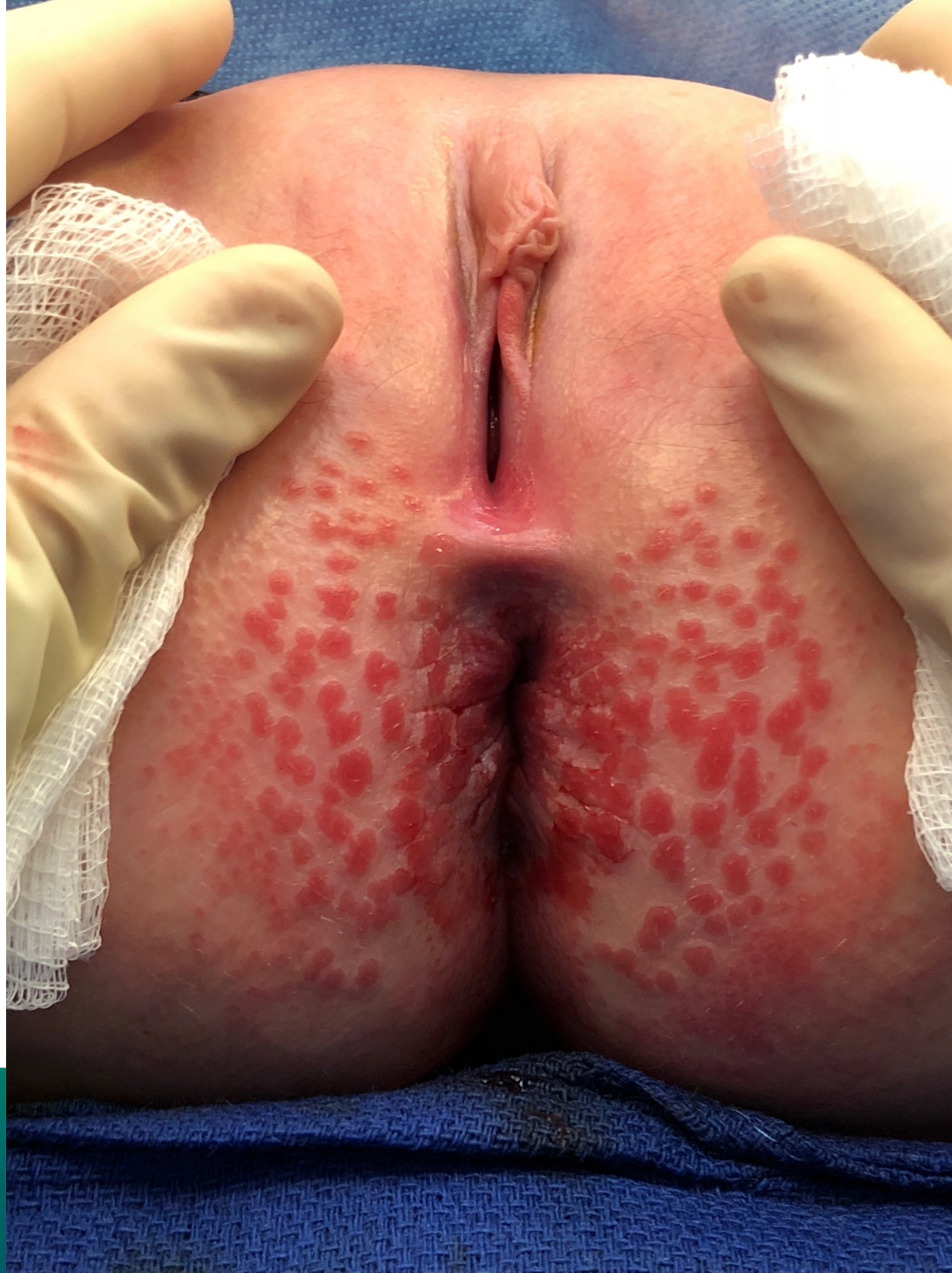Hain, Steven, M  
1706219  
05/20/2013  
7Y 8M  
M

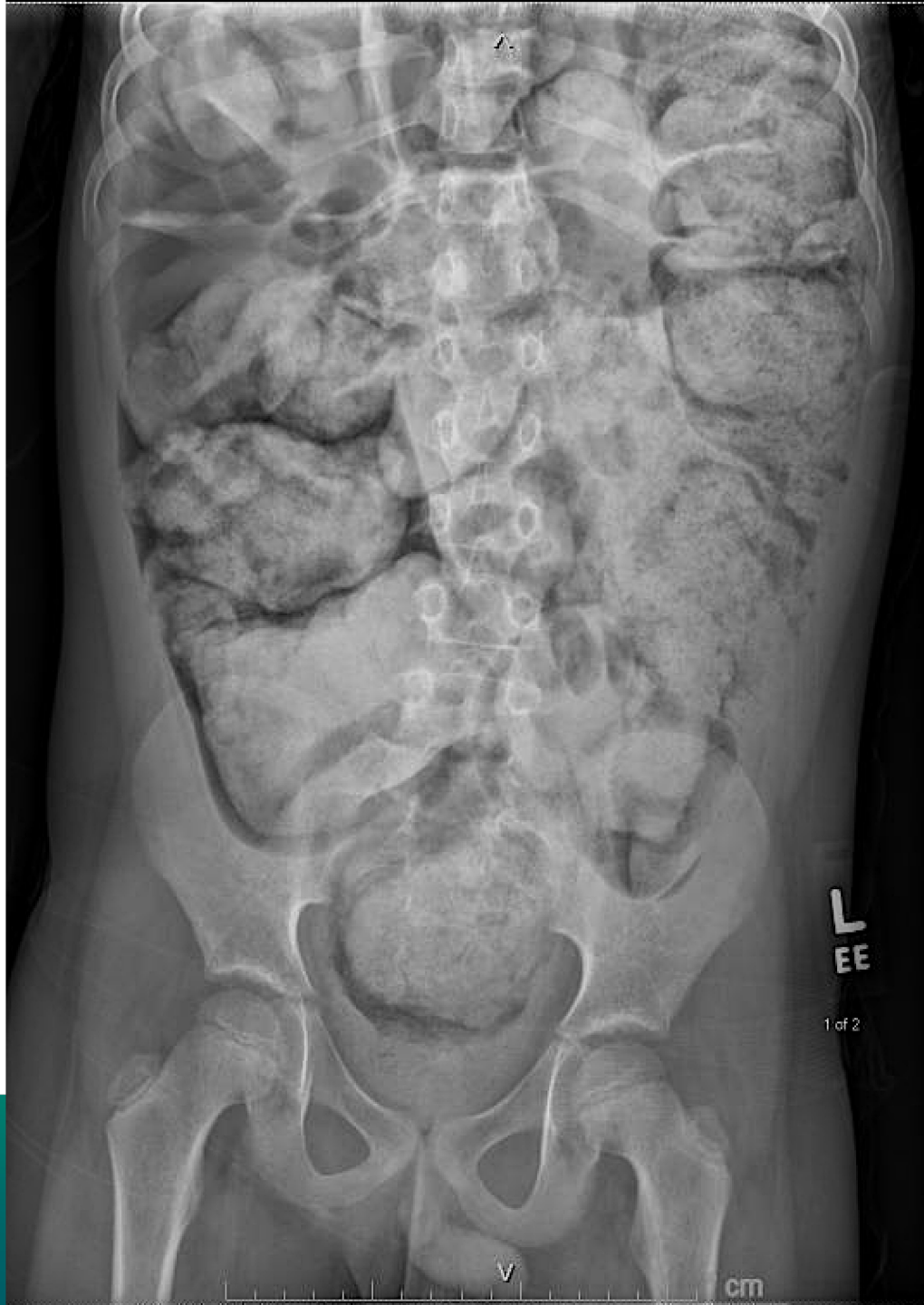Children's Hospital Colorado  
X-RAY ABDOMEN 1 VIEW  
AP Supine  
02/09/2021 9:54:15 AM  
A2617984  
---











INTERNATIONAL CENTER FOR  
**COLORECTAL AND  
UROGENITAL CARE**