



# Unusual case of cloacal malformation

Mansur Nasirov, MD  
National Children's Medical Center  
Tashkent/Uzbekistan

# Brief history

- 3 mo baby girl
- Single orifice (small)
- Double barrel colostomy

**Increasing head circumference on admission – Hydrocephalus**

# PMH

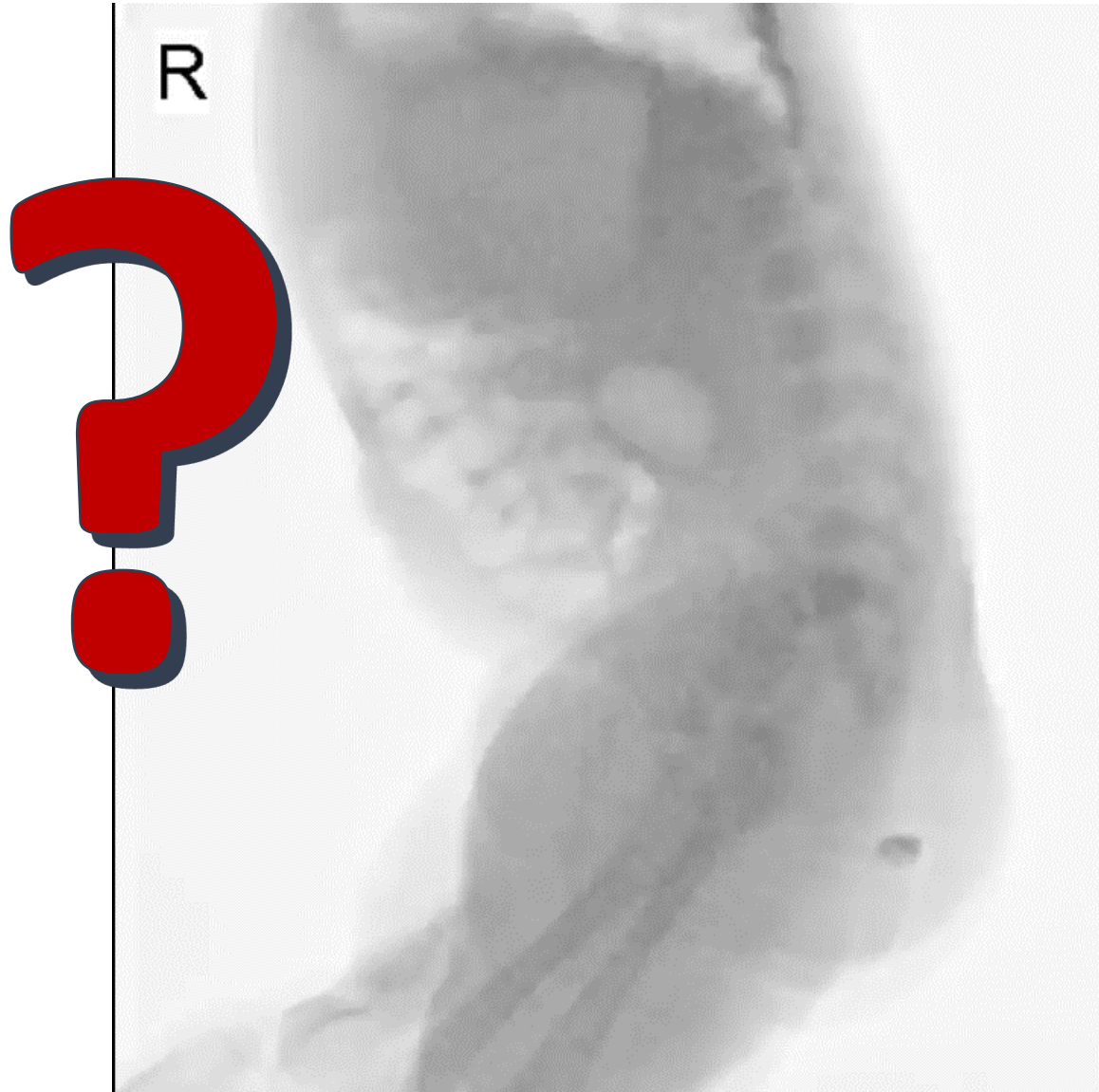
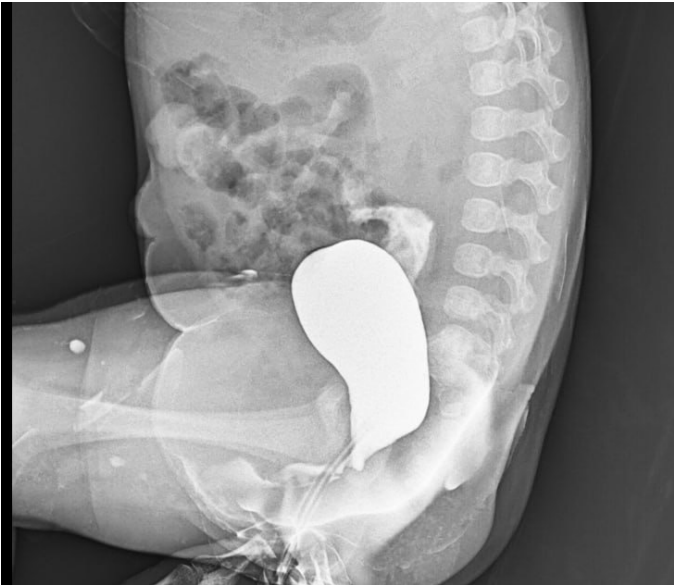- Was born with VACTERL

Thoracotomy. TEF repair (day 2)

Day 7 lap-assisted colostomy

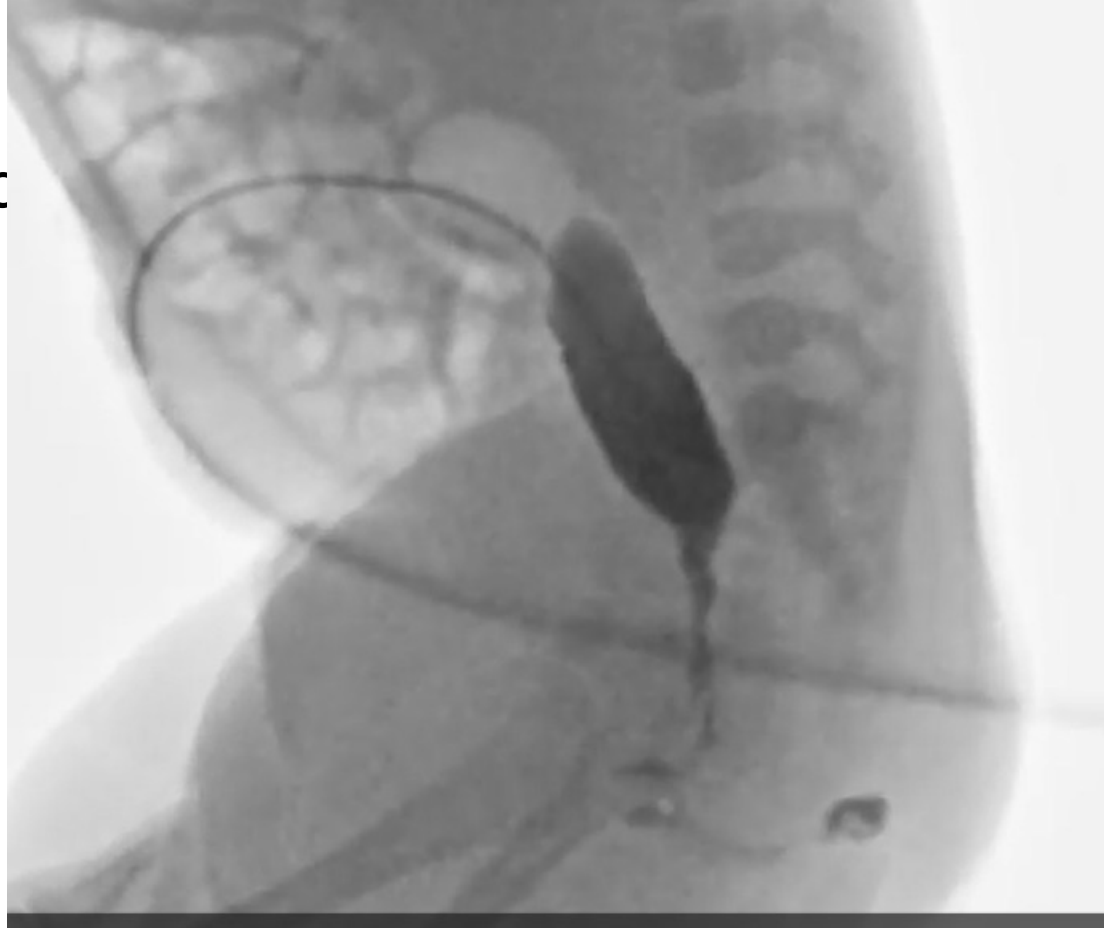# Workup

- Routine labs – NAD
- Distal colostogram



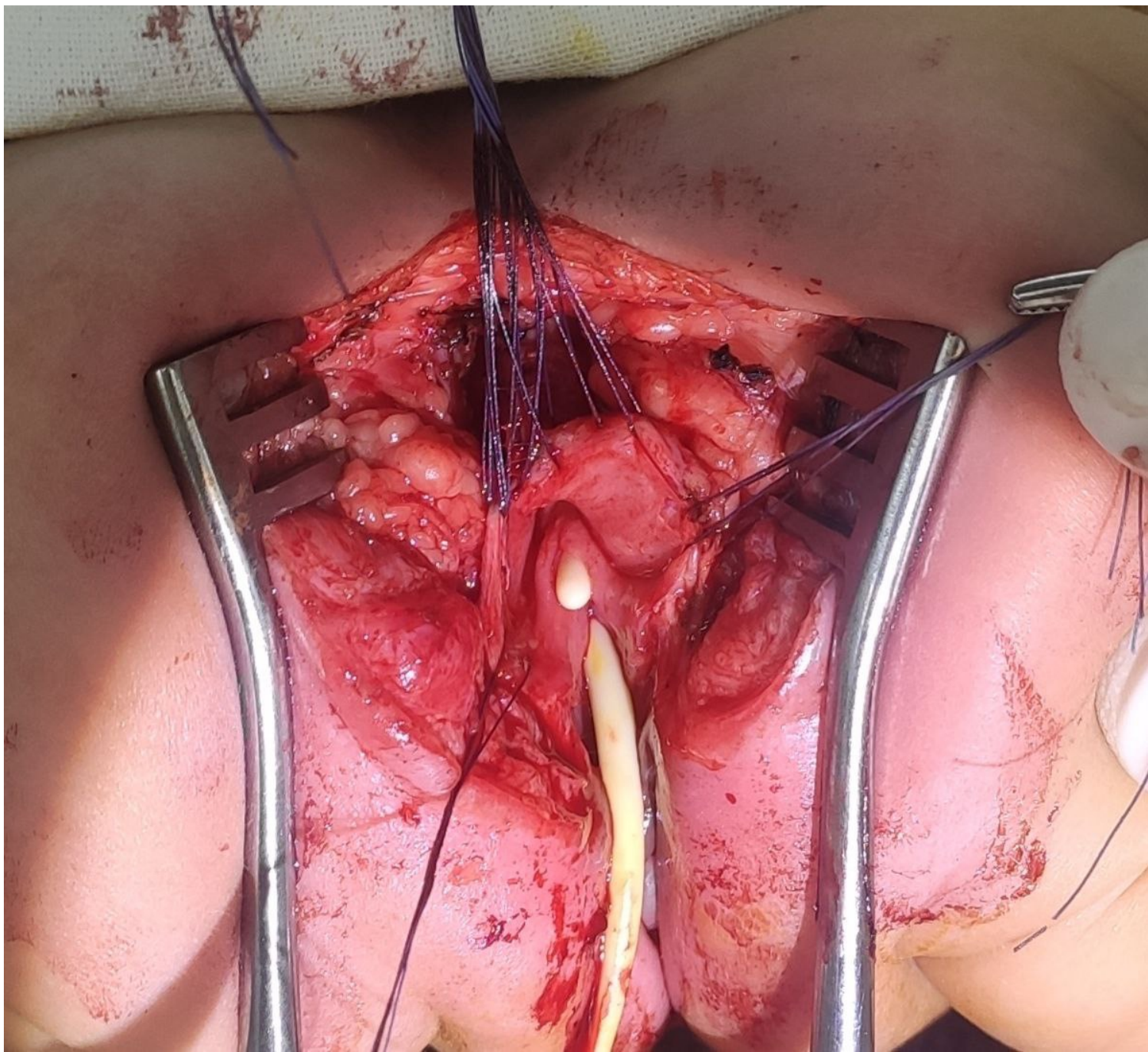
Dx?

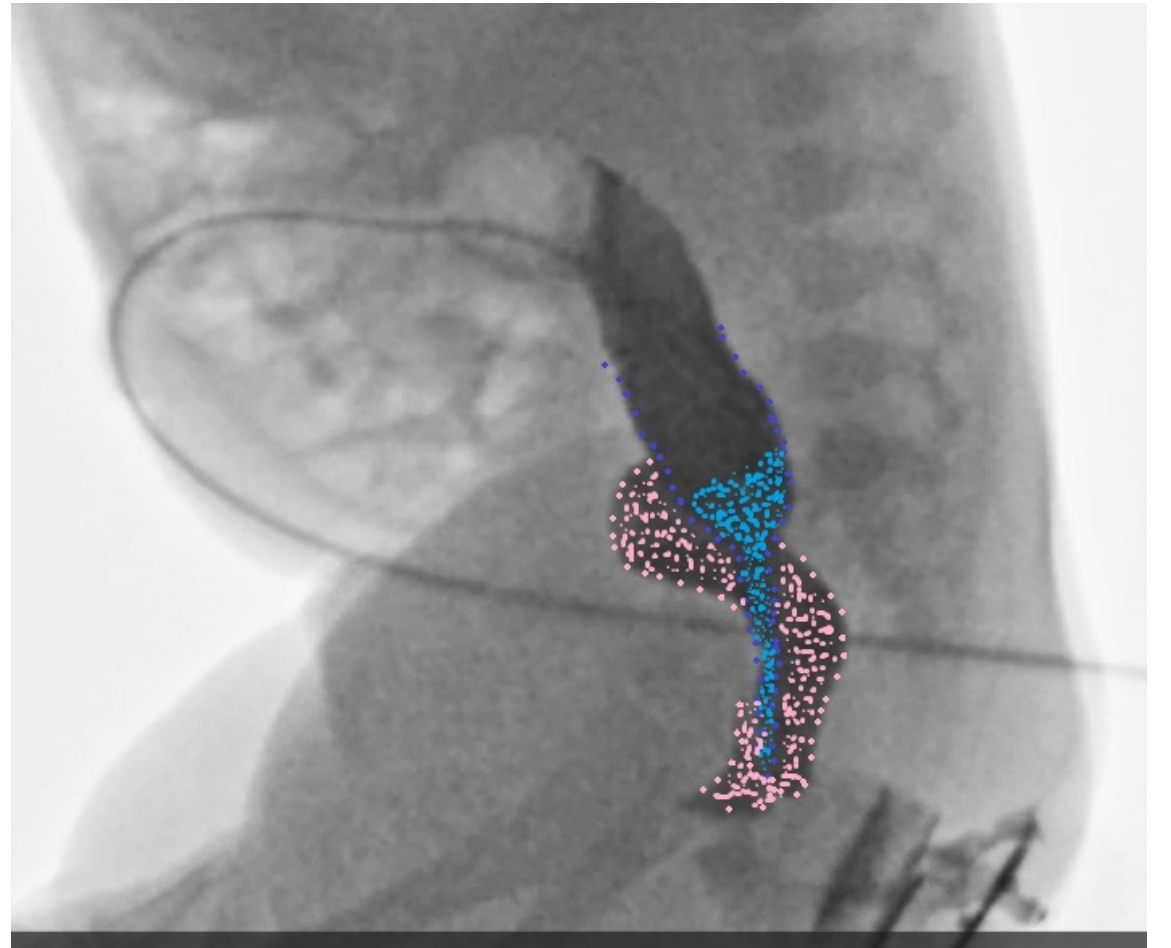
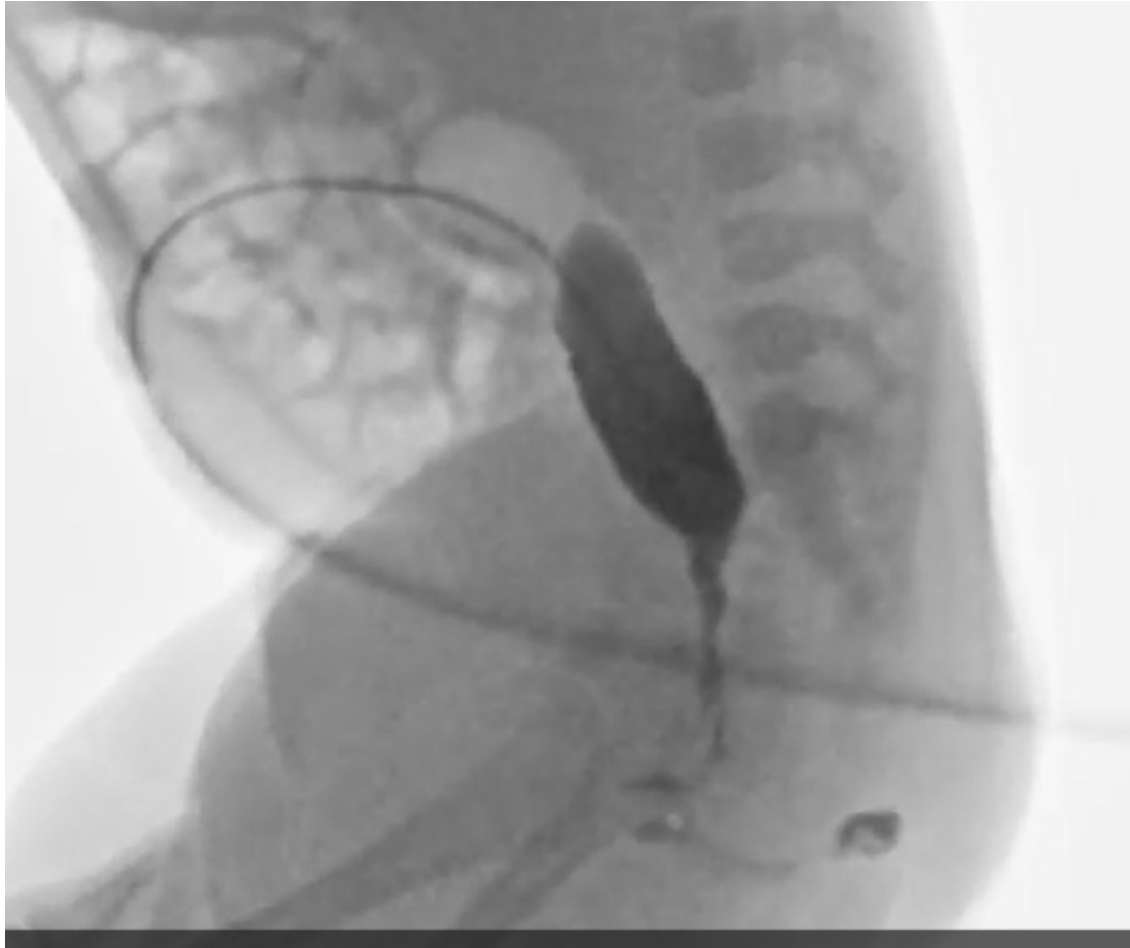- Short channel c



# Procedure

- Cystoscopy – couldn't find vagina
- Prone position with **full body prep** with Foley introduced to distal rectum



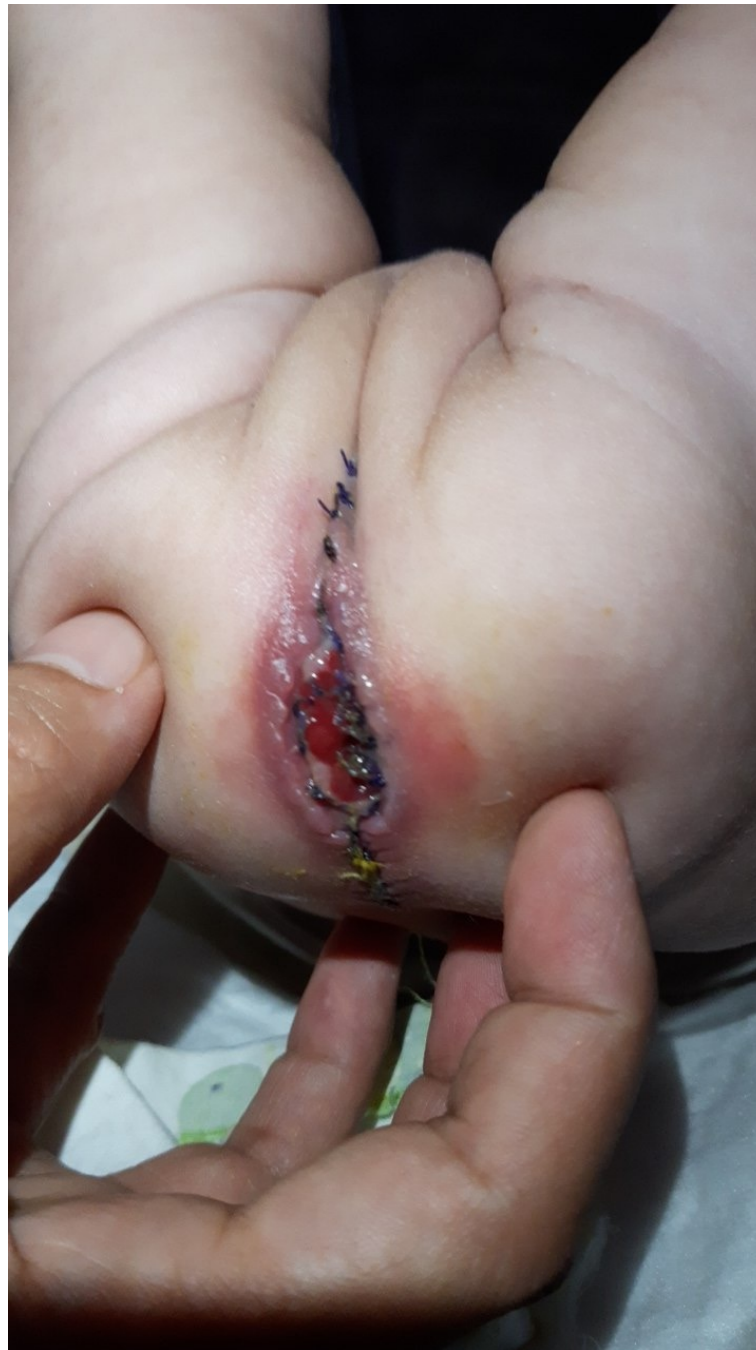



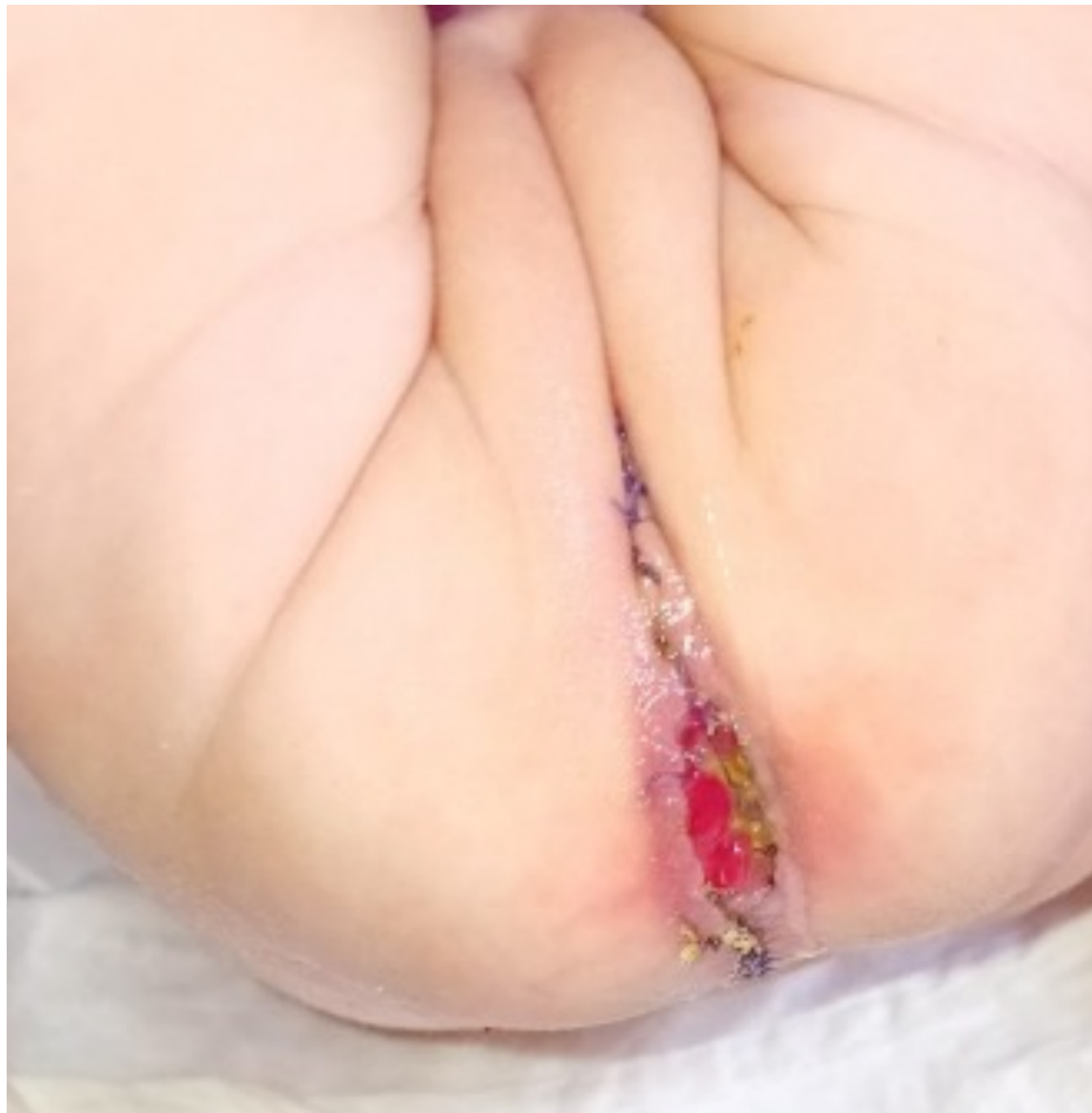# Procedure

- Colostomy takedown (full bowel prep been done)
- Distal rectum mobilization
- PT of anastomosed rectum
- PN for 10 days

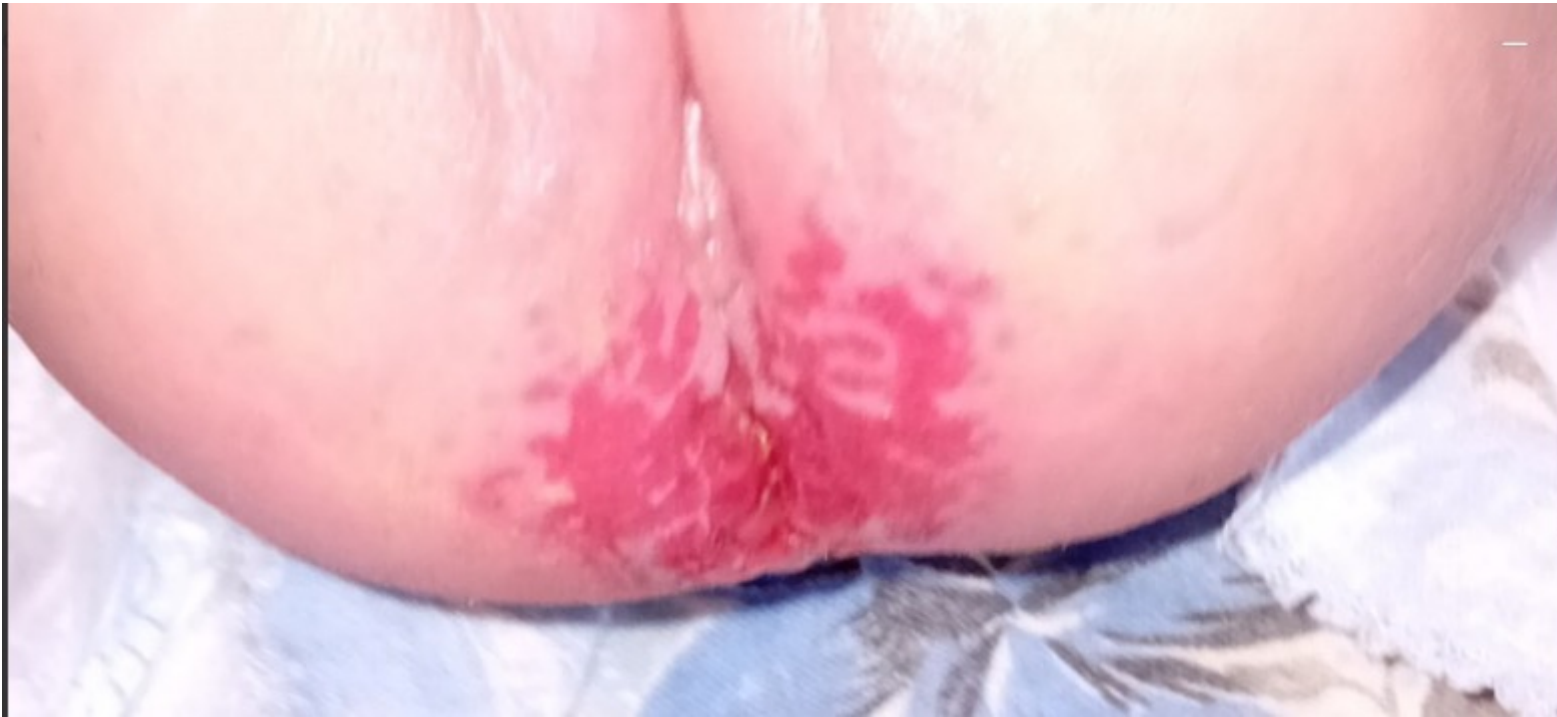Post op day 7



Post op day 10

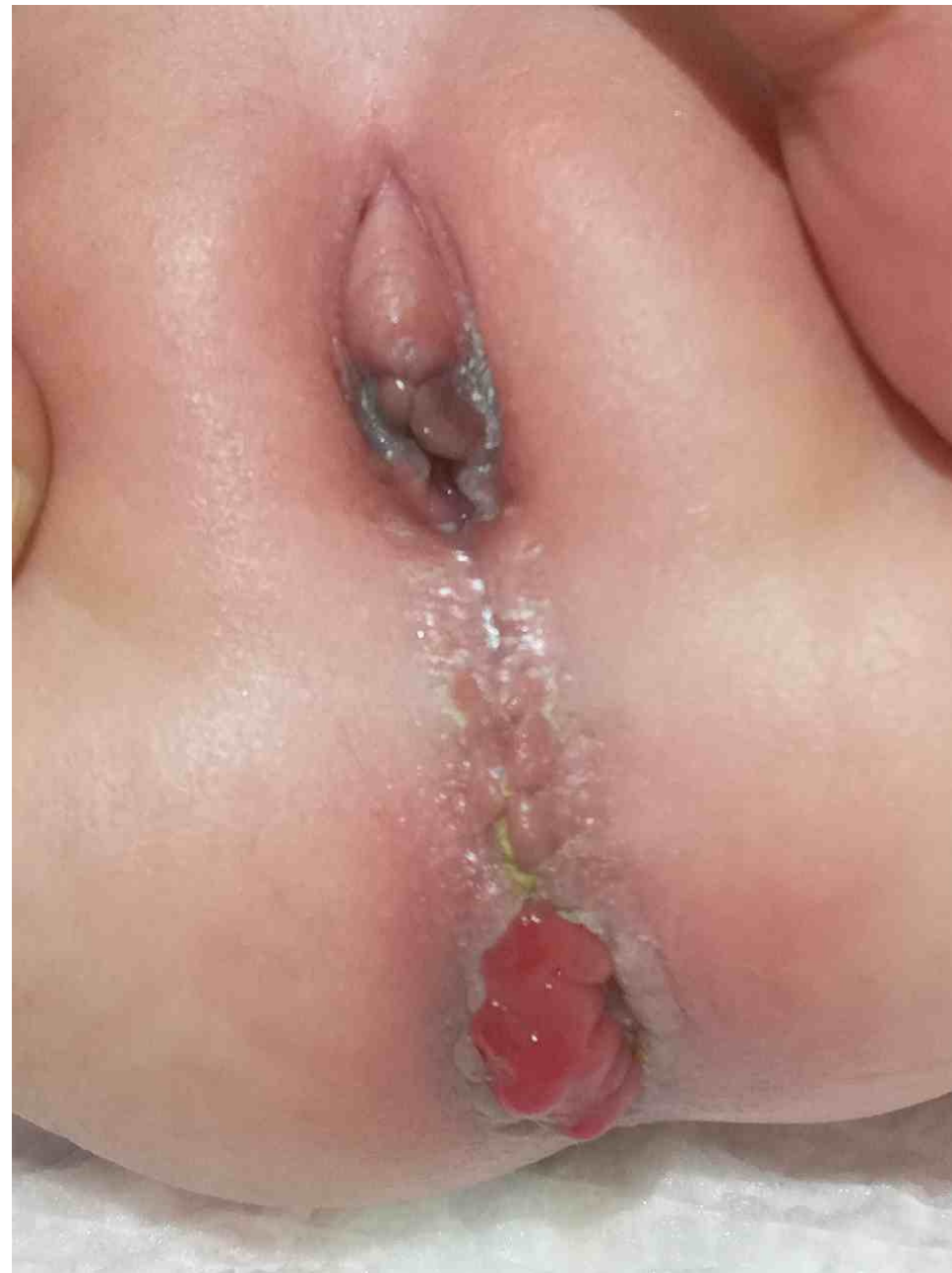

1 months follow up



# 2 months follow up

- VP shunt
- Normal growing



**Thank you for attention!**