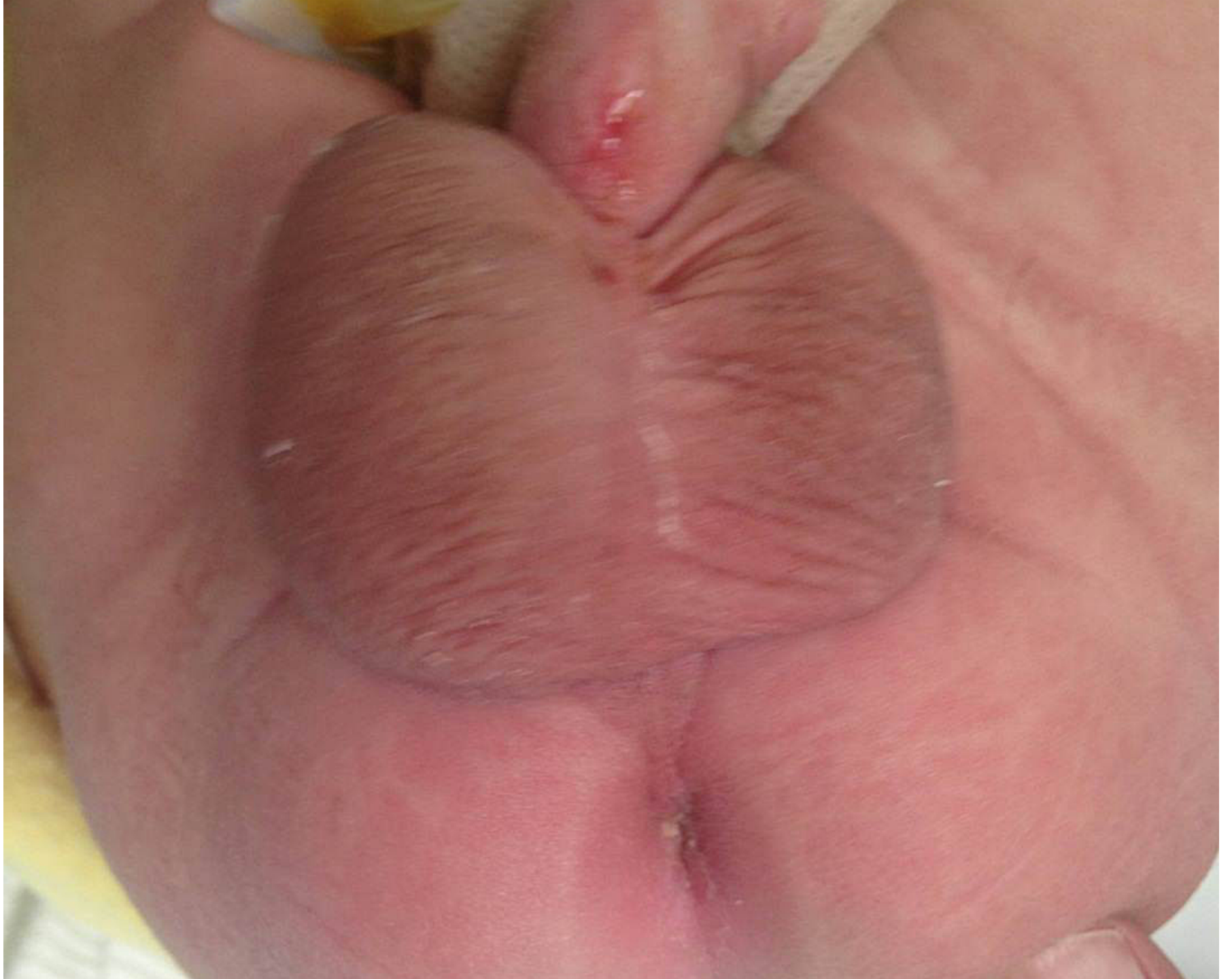



centro **COLORRECTAL** para **NIÑOS**

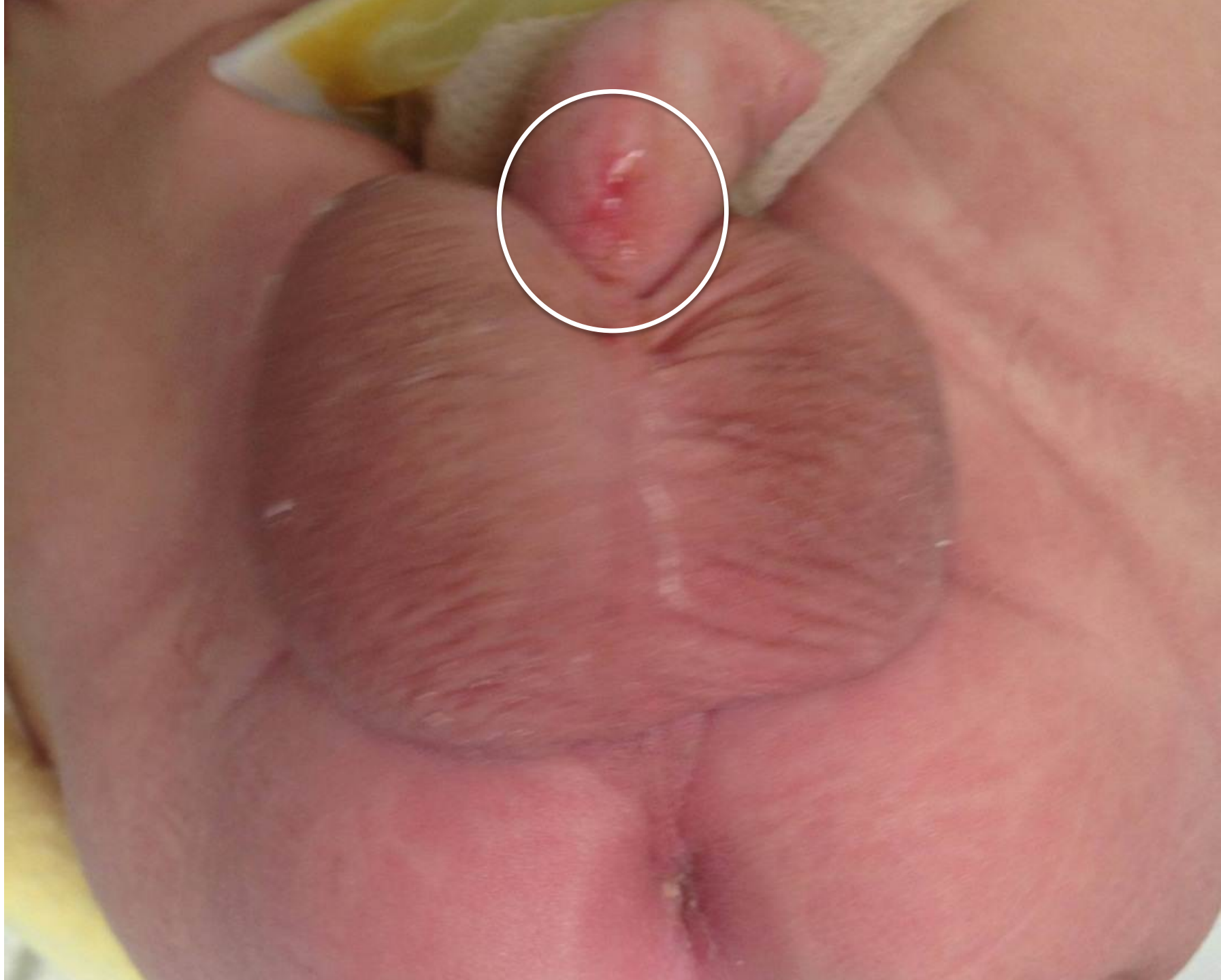
Dra. María Zornoza
Dr. Alejandro Ruíz

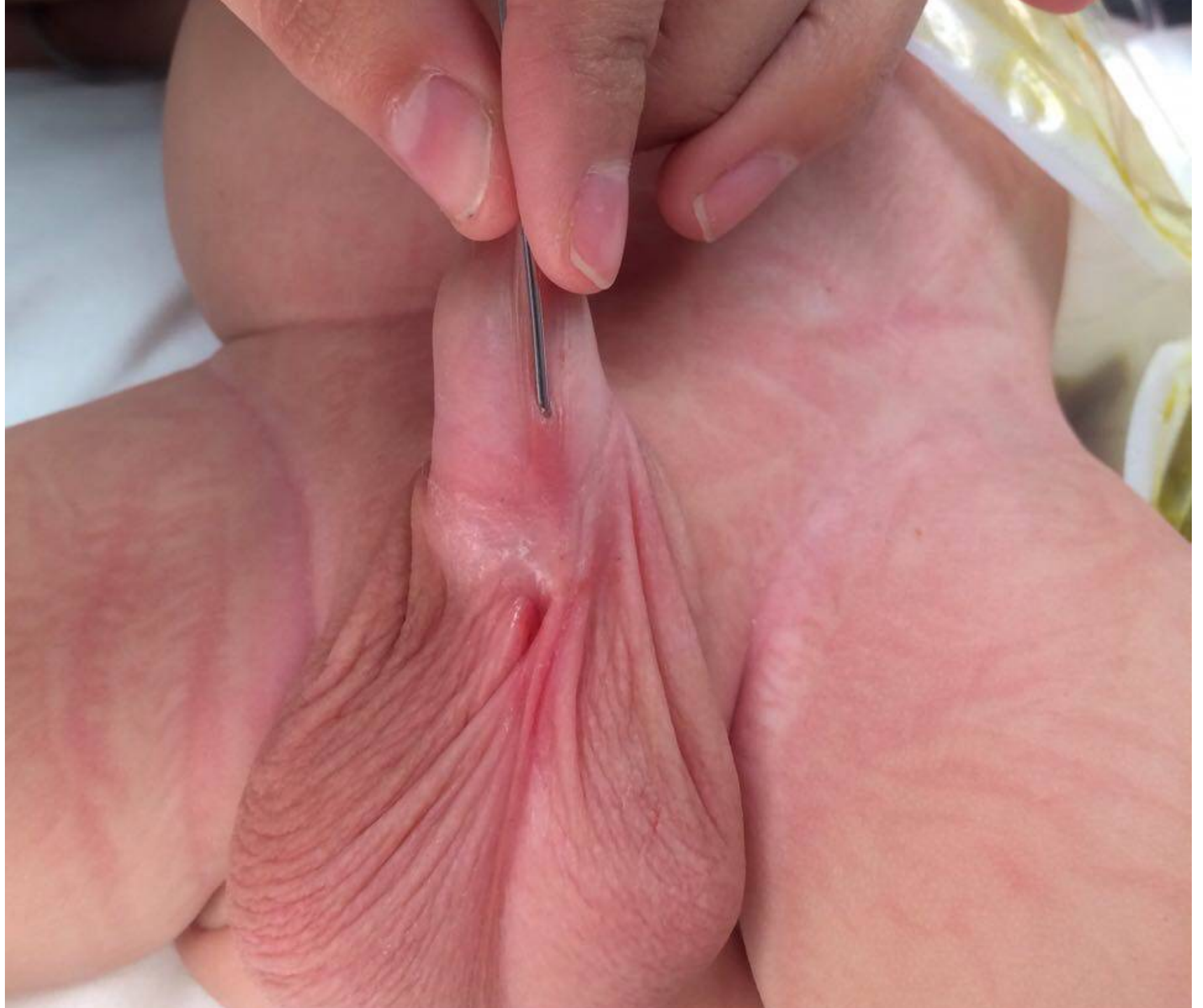- 3 months old, male.
- Referred to the colorectal center due to an anorectal malformation without fistula.
- Colostomy at 24 hours of life.



What malformation is this?

1. ARM without fistula
2. ARM with recto-perineal fistula
3. ARM with recto-urethral fistula
4. I don't know



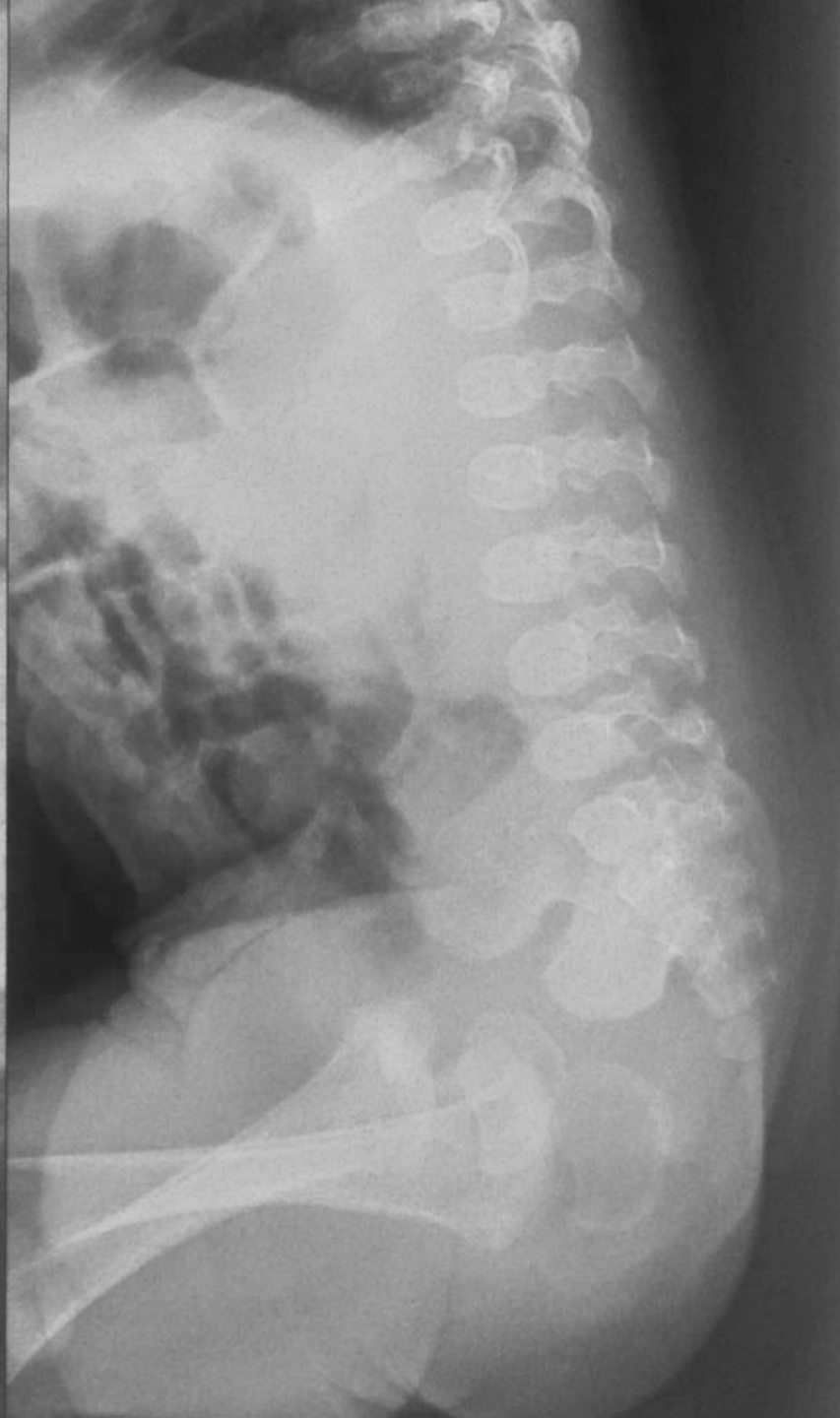
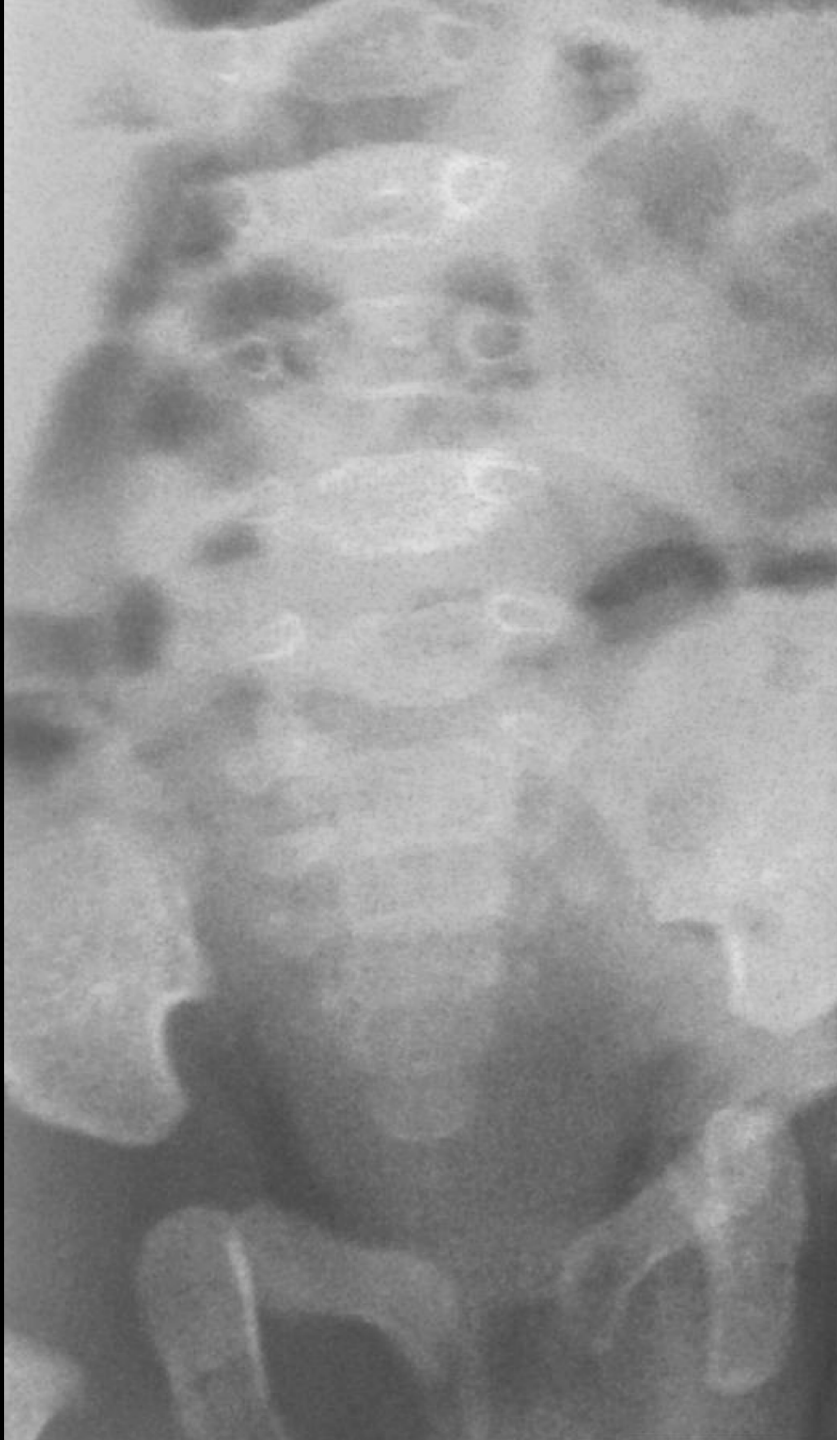
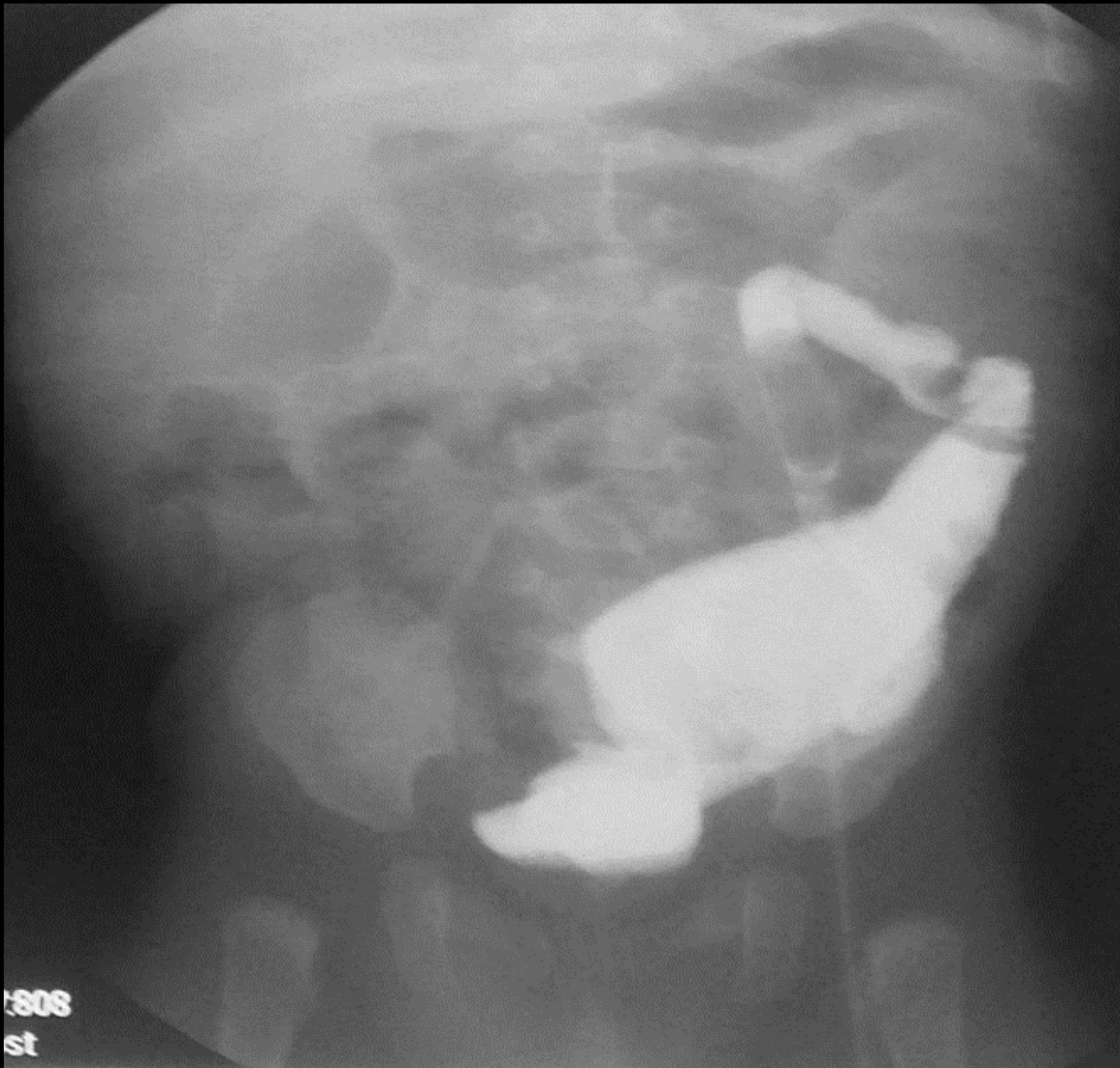What studies would you order?

1. Renal US
2. Echocardiogram
3. Spinal US
4. Sacral X-ray
5. Distal Colostogram
6. All of the Above

Work-up

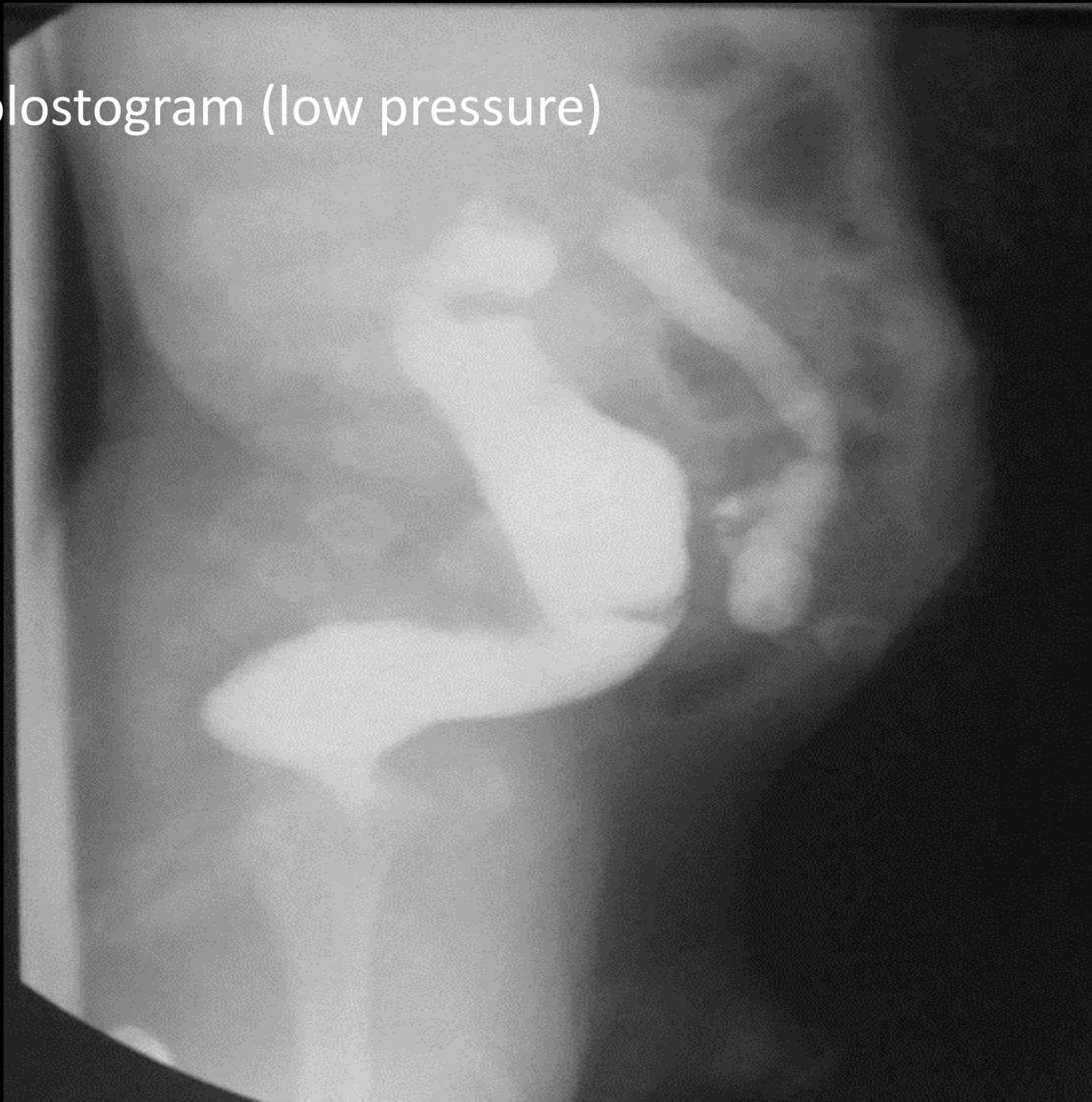1. Renal US: normal.
2. Echocardiogram: normal.
3. Spinal US: normal.
4. Sacral X-ray: SR AP: 0.66 Lat: 0.71
5. Distal Colostogram done at 4 m.o.



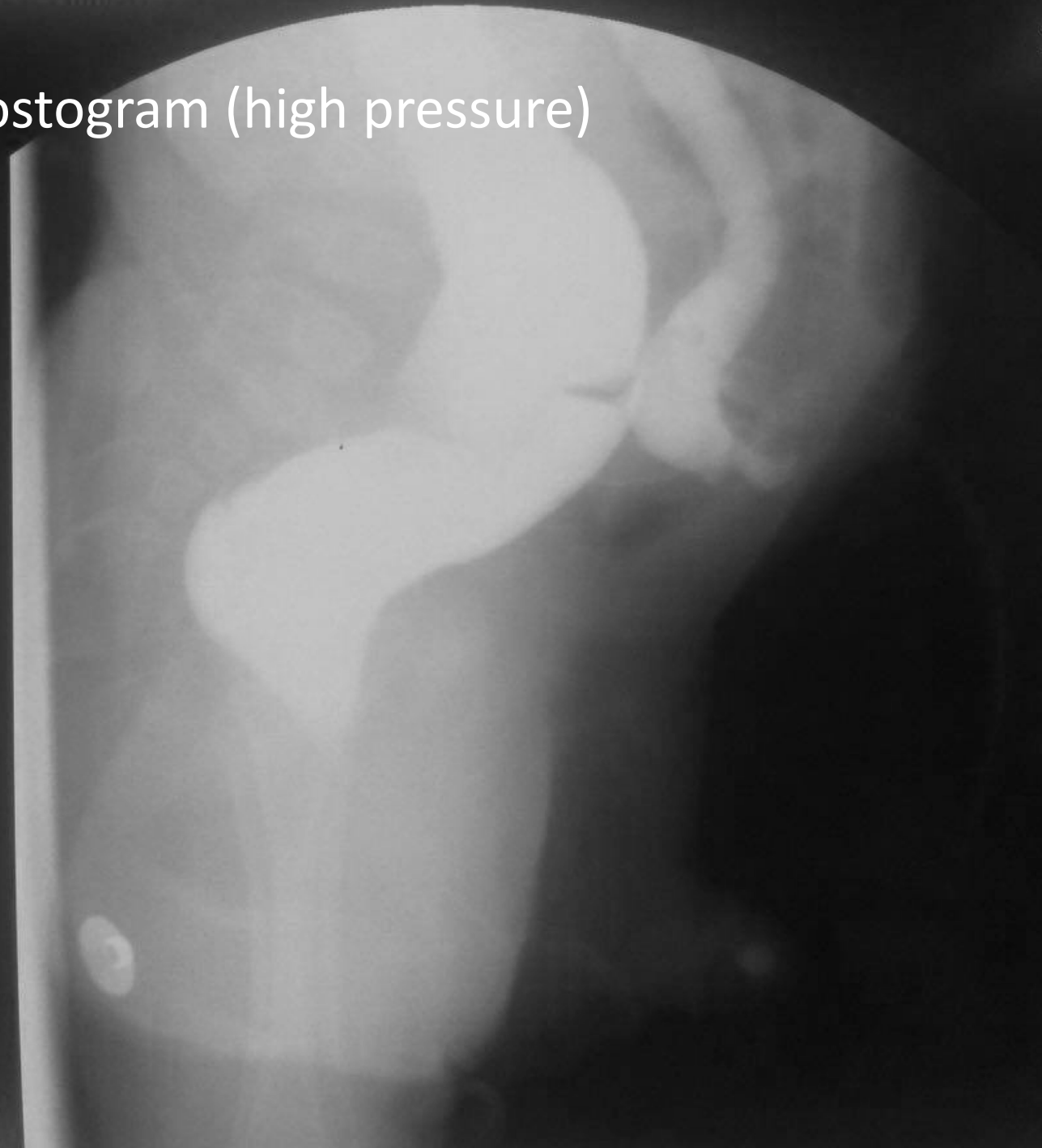

1808
st

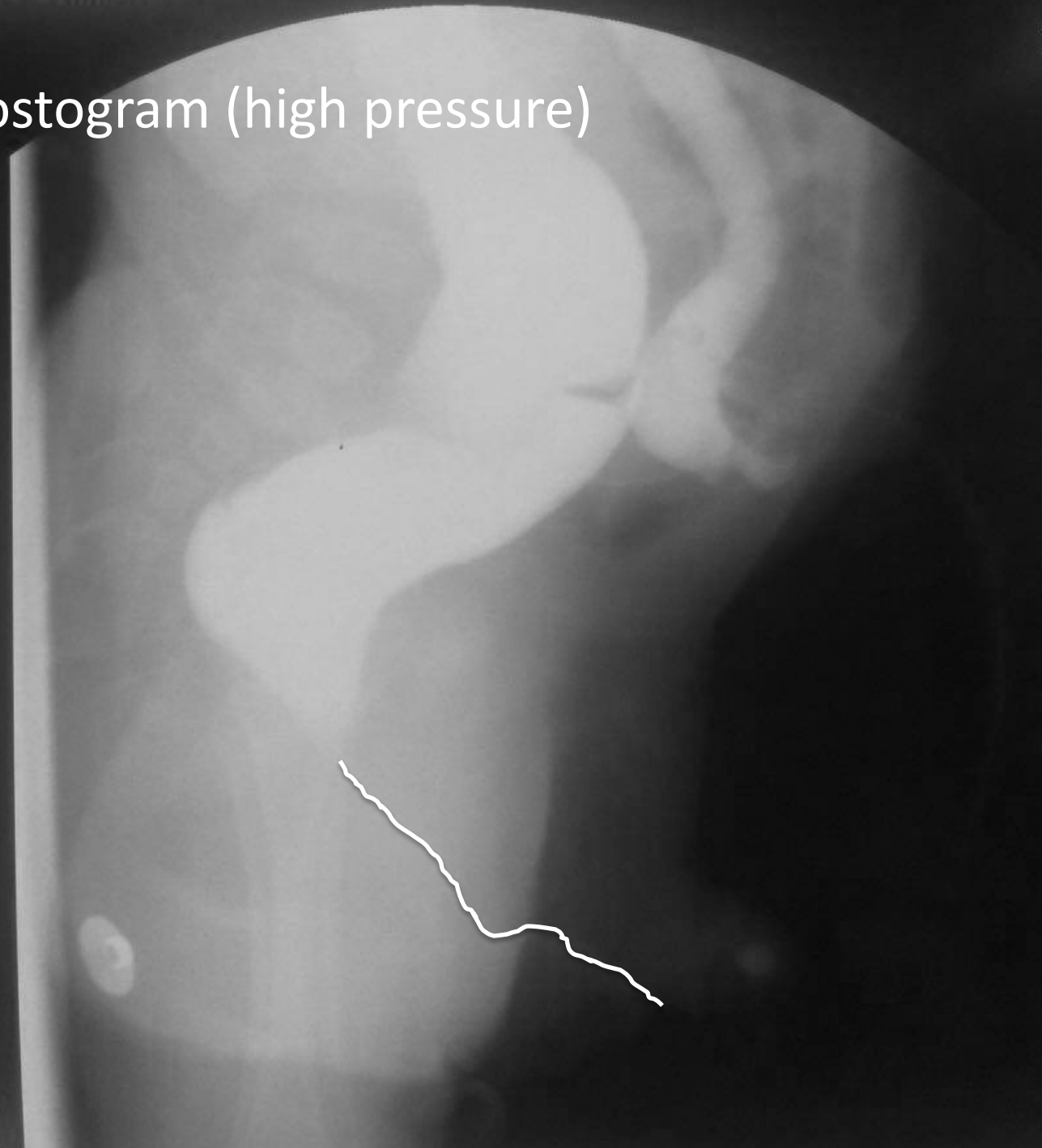
Colostogram (low pressure)

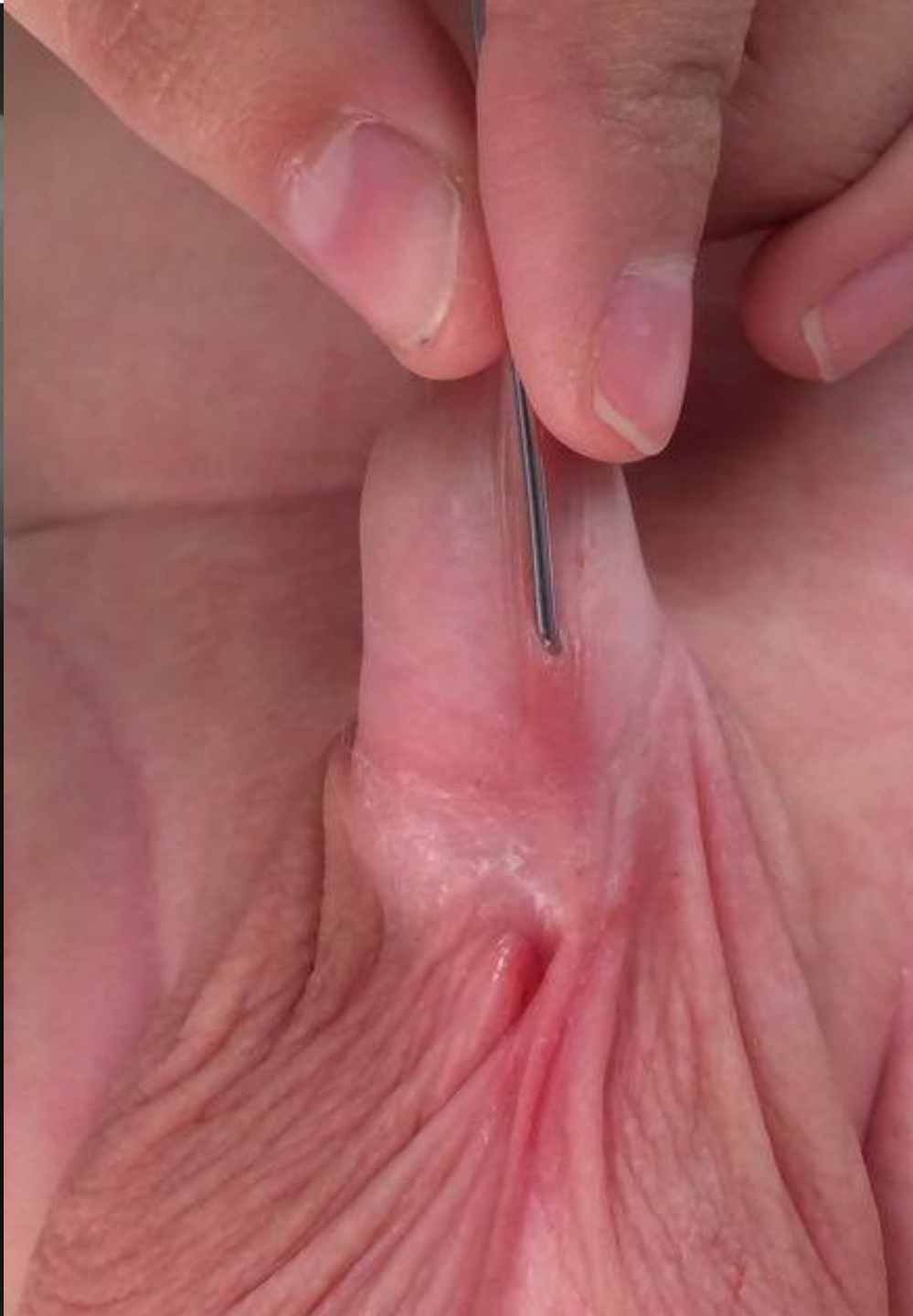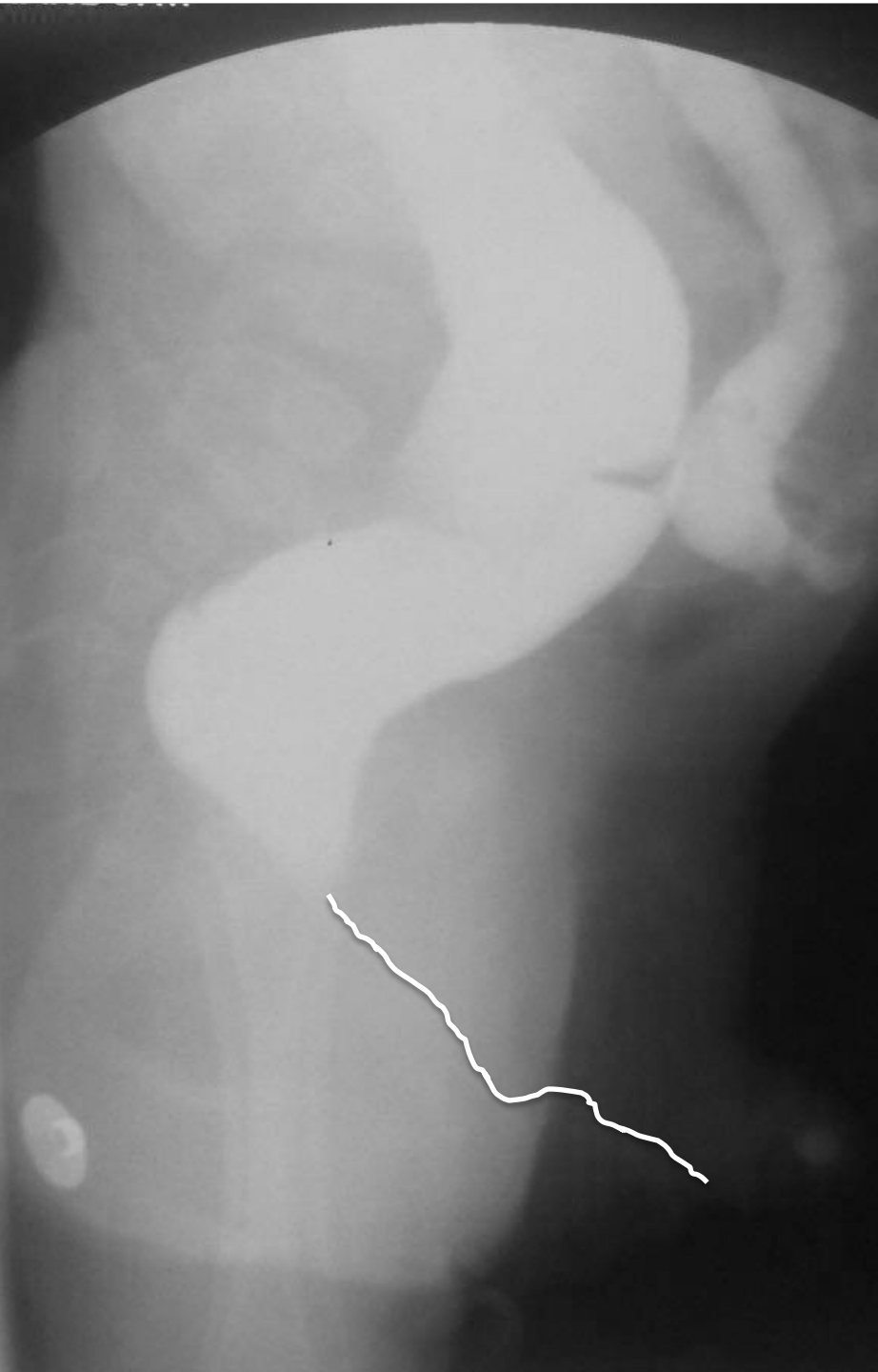


Colostogram (high pressure)



Colostogram (high pressure)



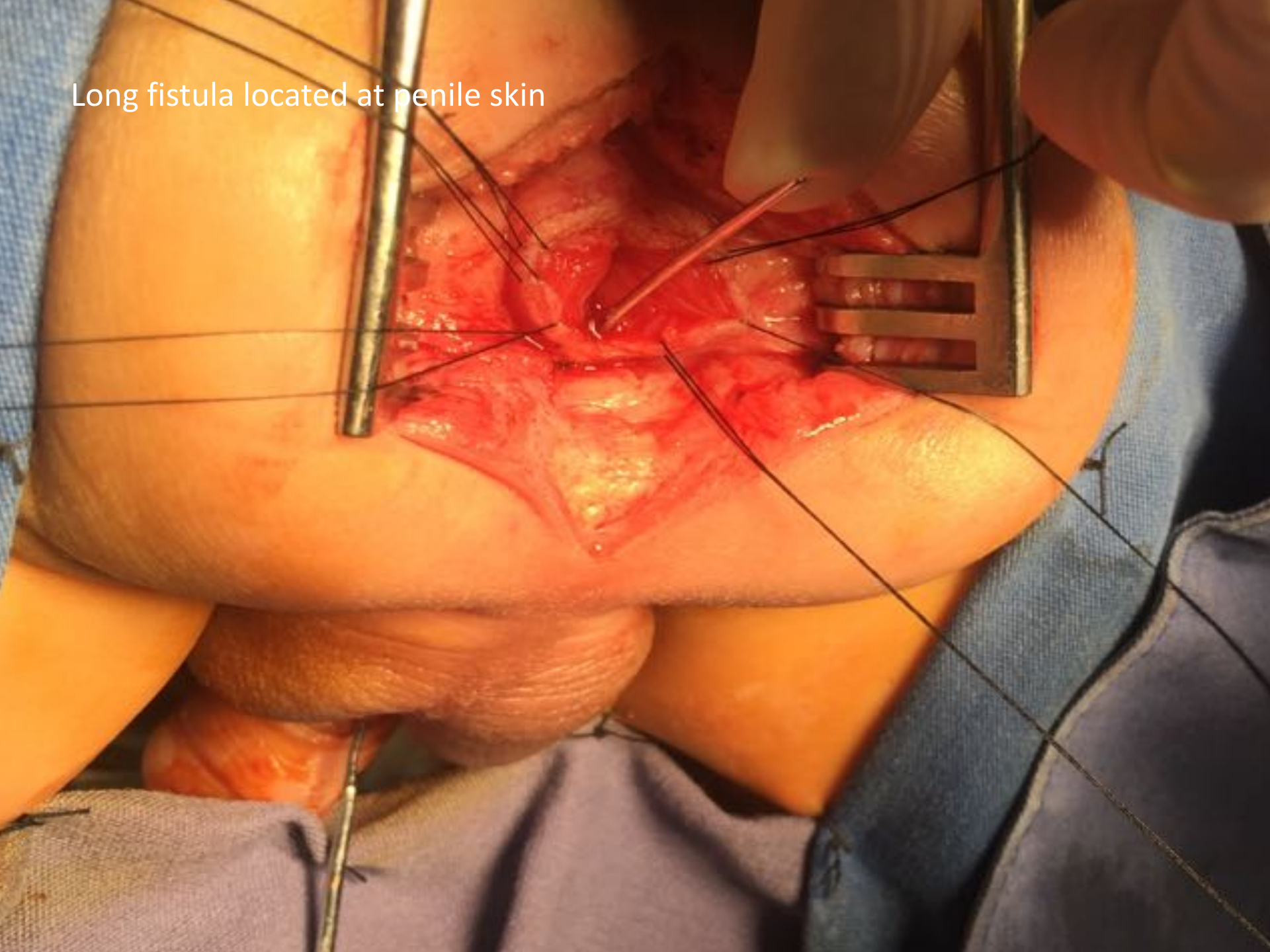


What malformation is this?

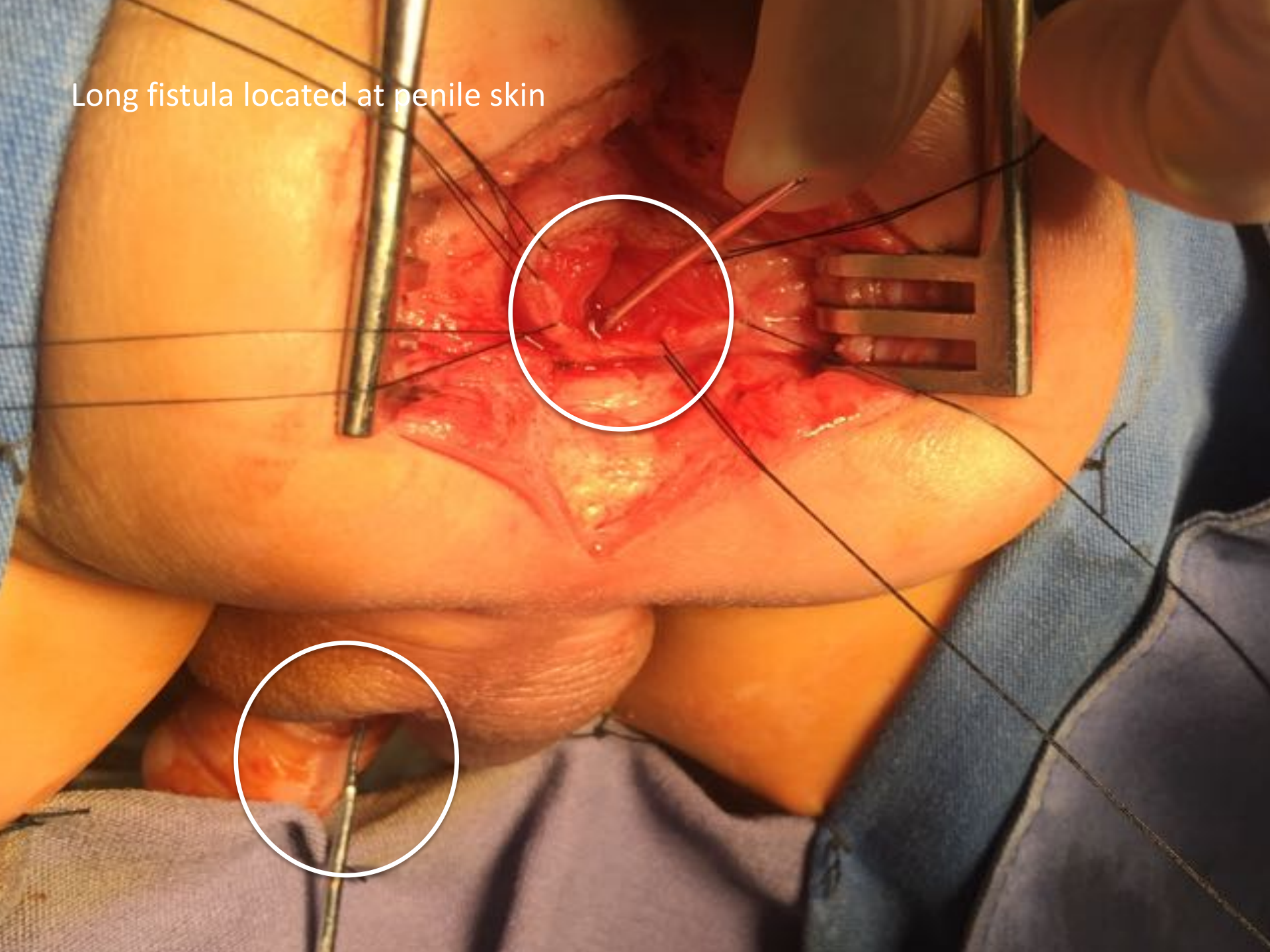
1. ARM with recto-perineal fistula.
2. ARM with recto-urethral fistula.
3. ARM with fistula to penile skin.
4. ARM with a variant of recto perineal fistula.



Long fistula located at penile skin



Long fistula located at penile skin

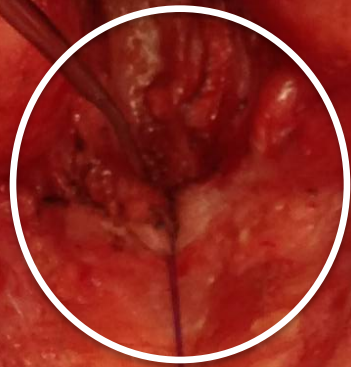

A surgical photograph showing a penile fistula repair. The penile skin is incised, and the underlying bulbospongiosus muscle is exposed. A long, narrow fistula tract is visible, extending from the skin surface down towards the bulbospongiosus muscle. A blue suture thread is being used to close the fistula tract. Two metal retractors are used to hold the incision open. The surrounding tissue is pinkish-red, and the overall scene is brightly lit.

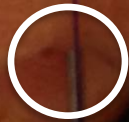Long fistula located at penile skin

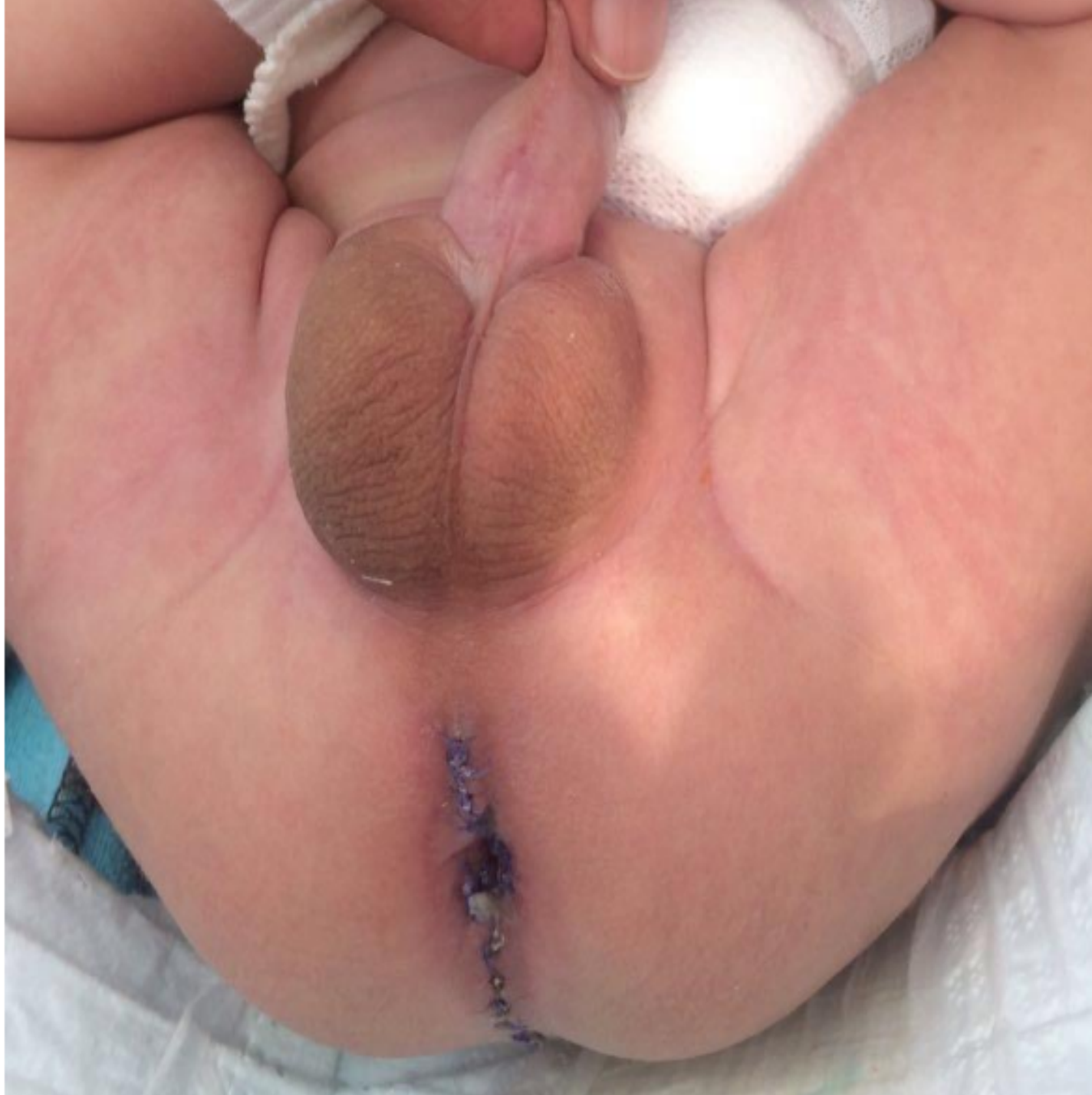We repaired it as a recto-bulbar-fistula

Long fistula located at penile skin

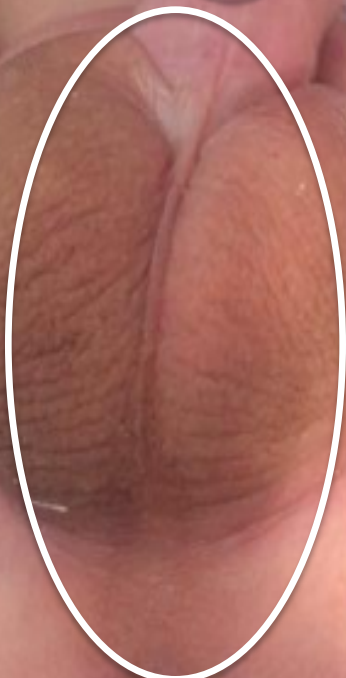
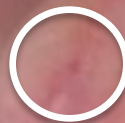
We repaired it as a recto-bulbar-fistula

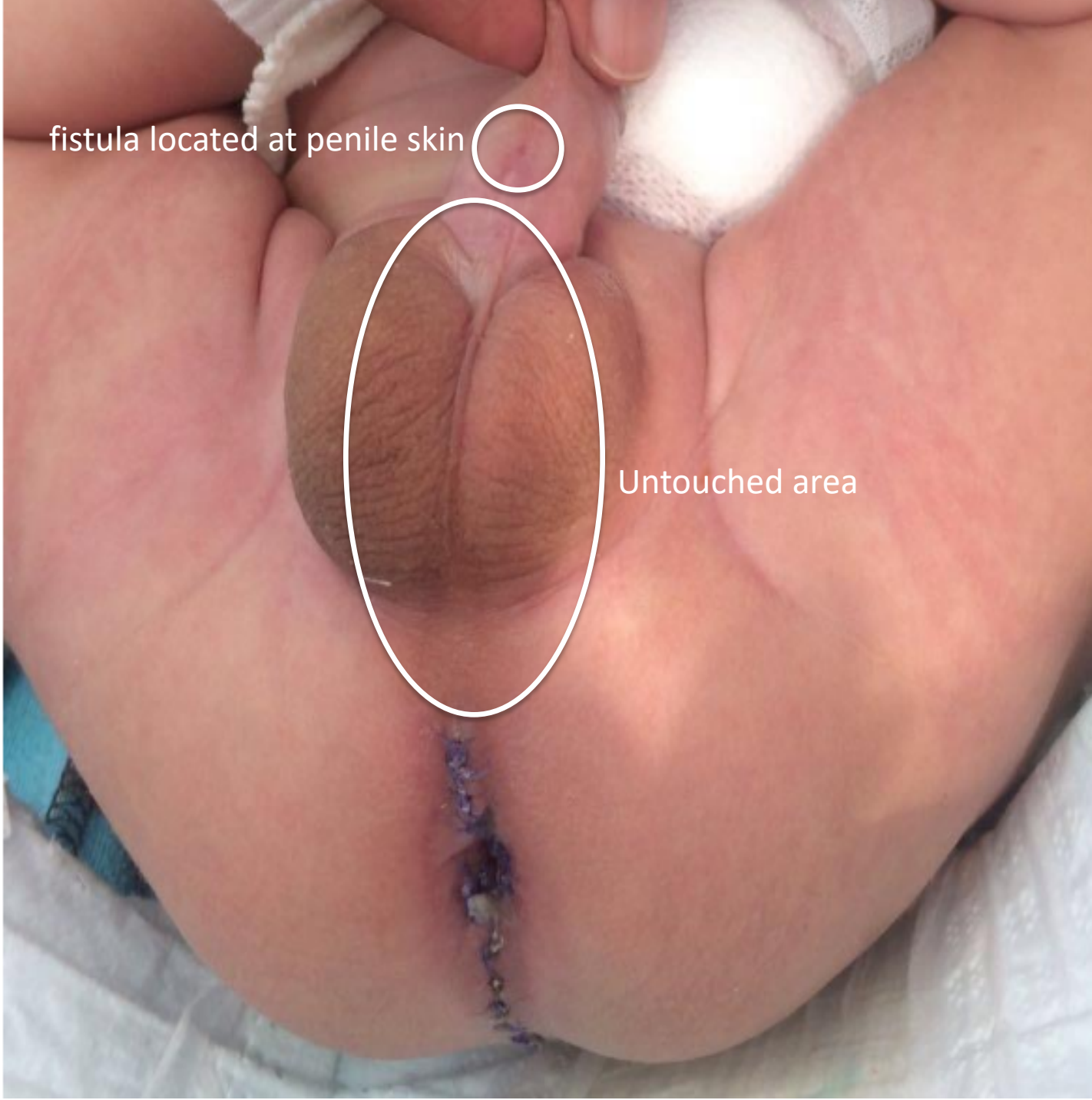


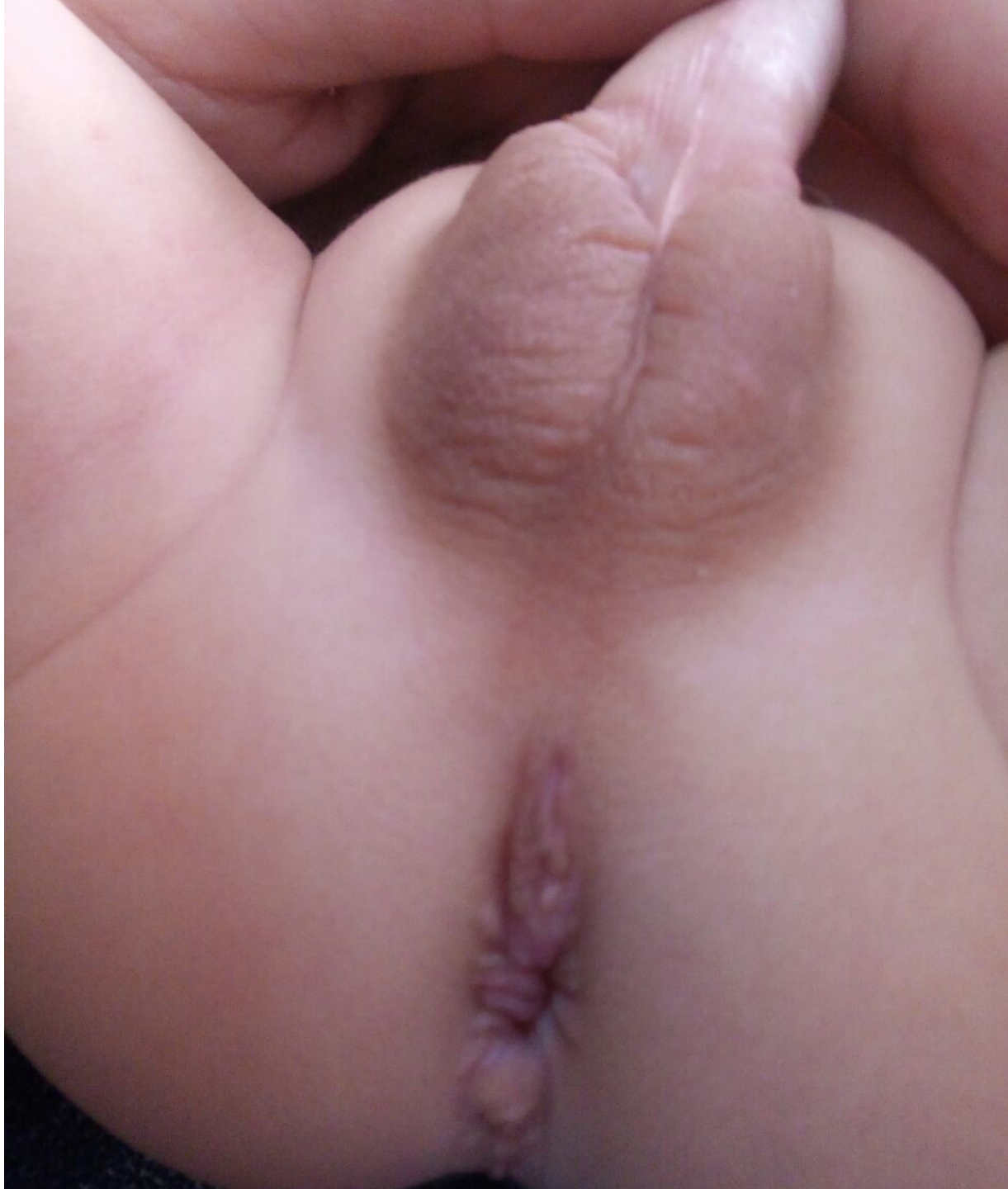
fistula located at penile skin

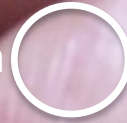

Untouched area

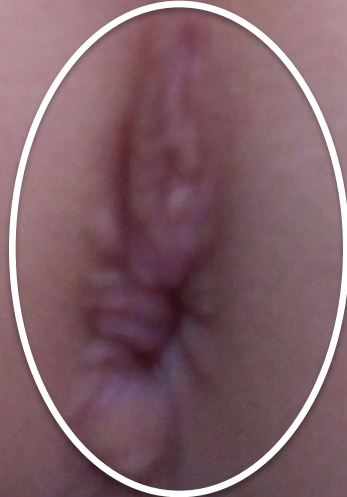



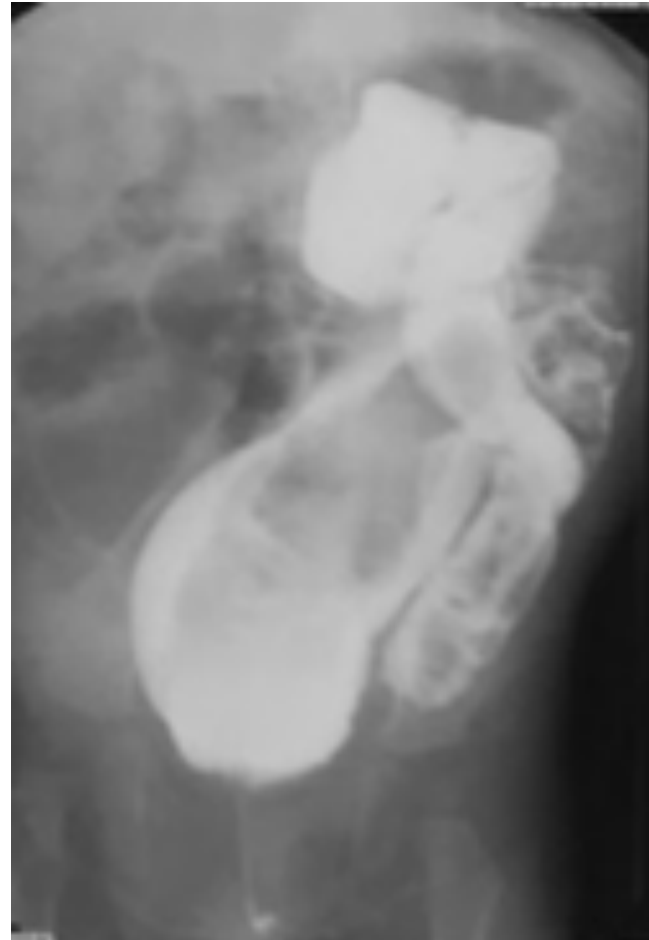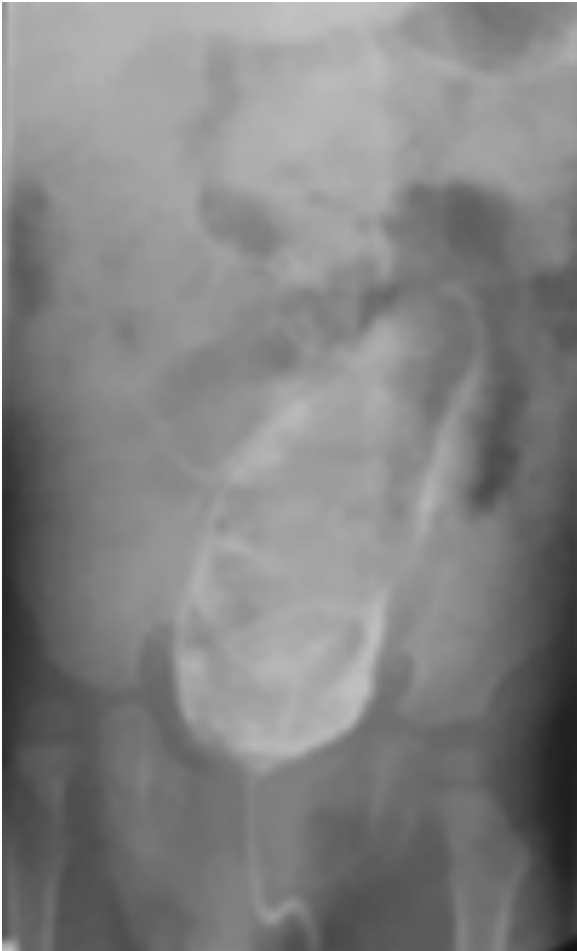Obliterated fistula



Anoplasty with queloid scar



He had a functional result with severe constipation and megarectum (patient is still less than 3 years of age) and is currently being managed with enemas.





centro **COLORRECTAL** para **NIÑOS**

THANK YOU