



KARLA SANTOS-JASSO M.D, MSc.
NATIONAL INSTITUTE OF PEDIATRICS
MEXICO CITY, MEXICO
February 2019

Past Medical History

13-Year-Old Girl

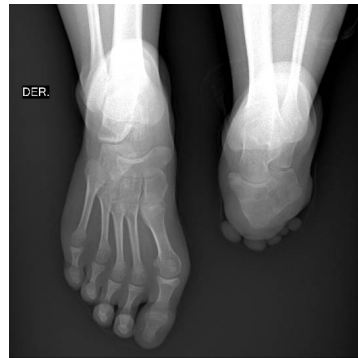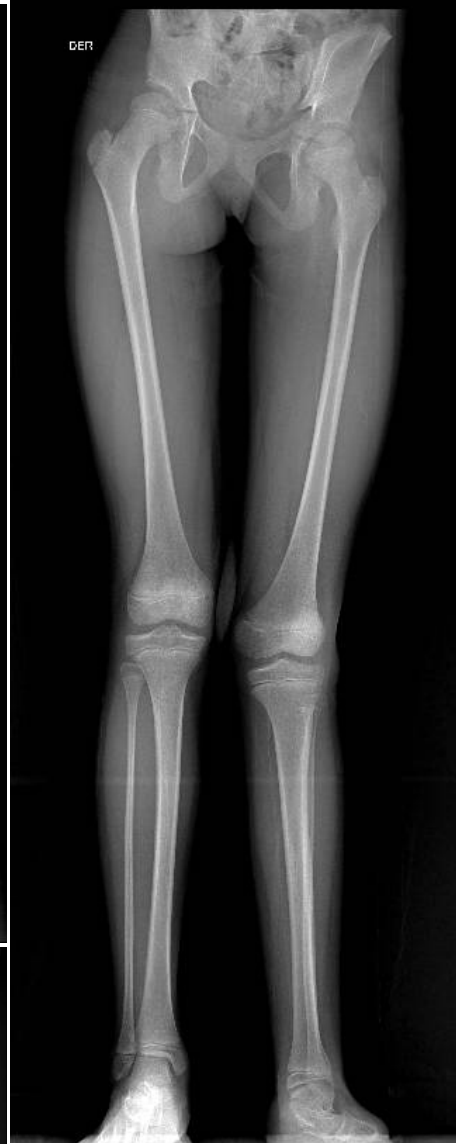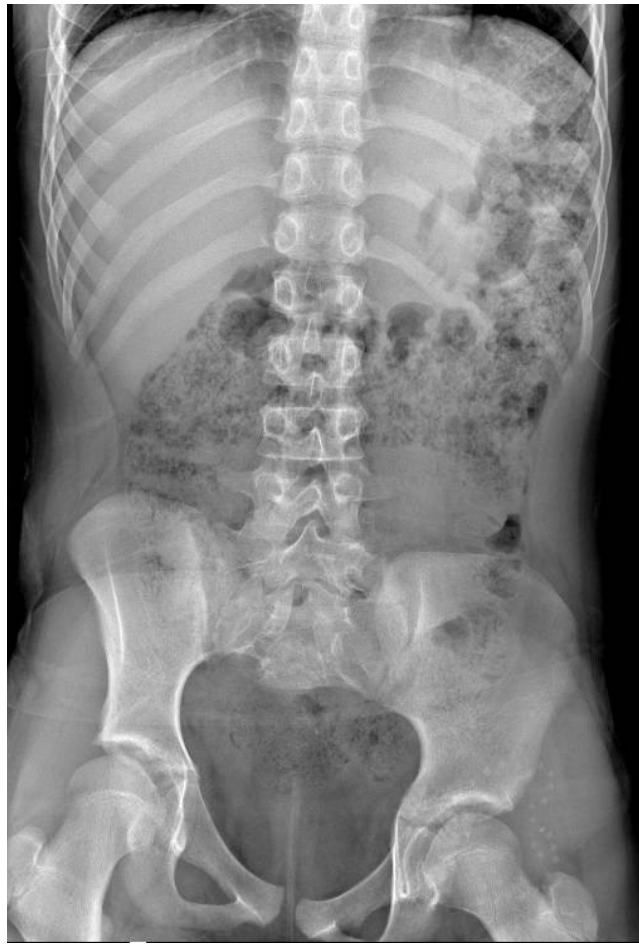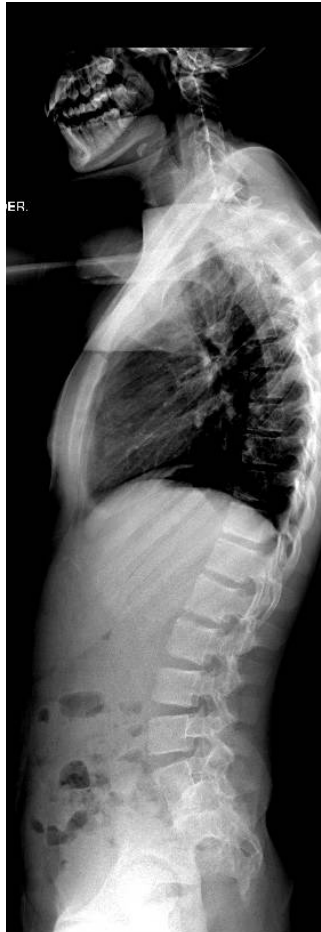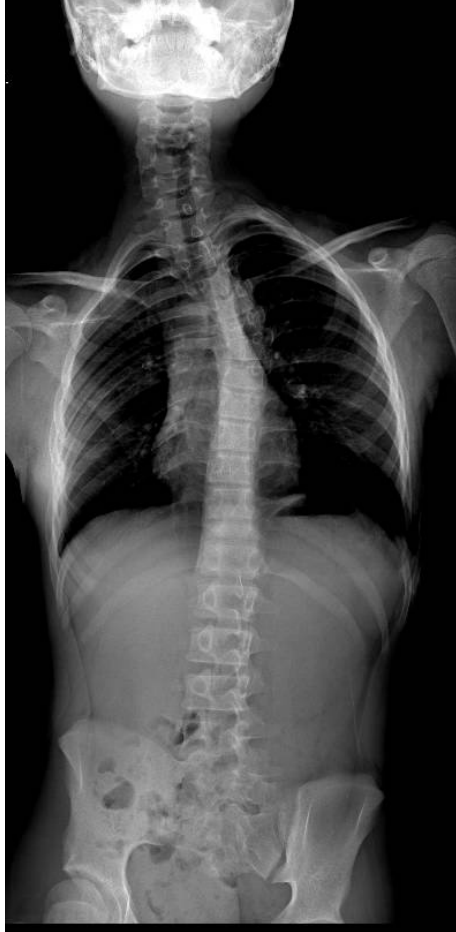Referred to us for **abdominal pain**, and diagnosis of Anorectal Malformation with recto vestibular fistula. VACTERL

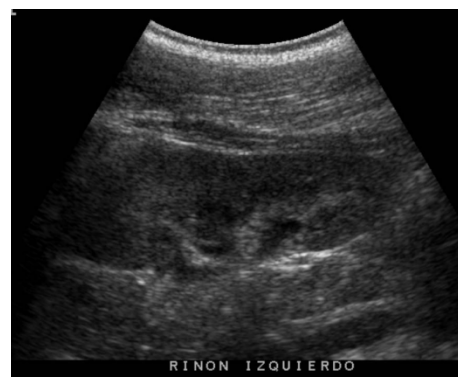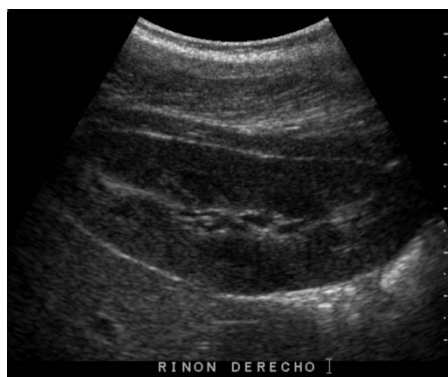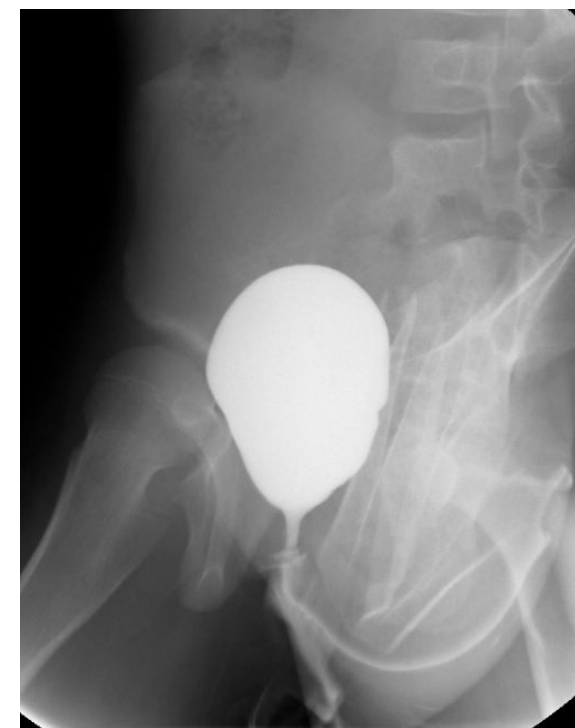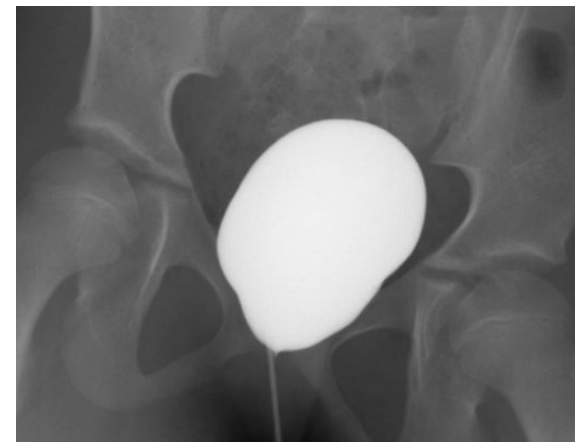
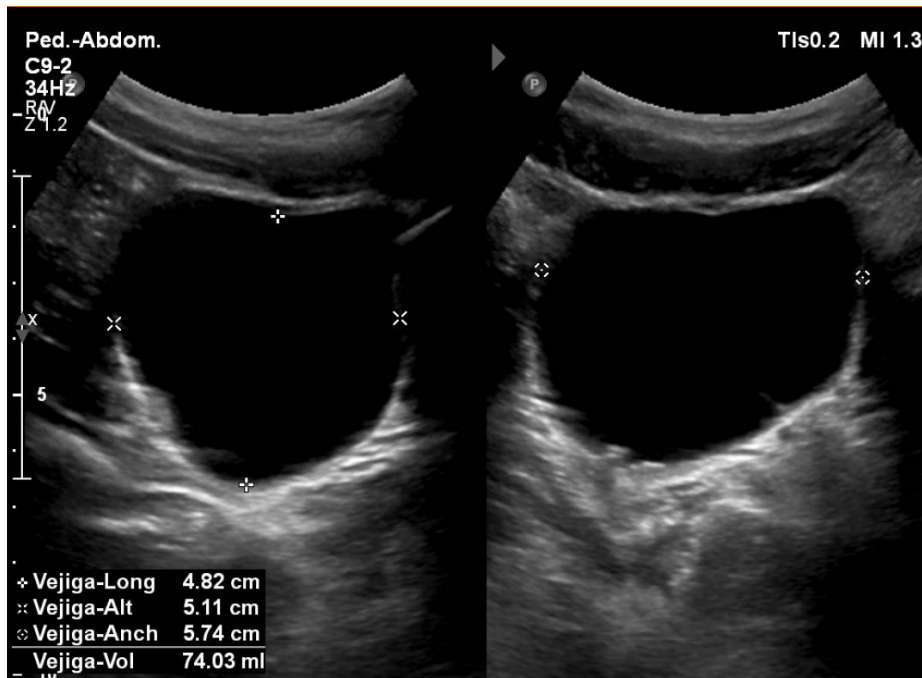
- Colostomy (at birth)
 - PSARP (1 year)
 - Colostomy closure at 14 months
-
- Bowel and urinary control (4 years) but with involuntary leaking of urine with straining. Two bowel movements per day

Clinical Appearance

- The patient had pelvic pain on physical exam (palpation)
- Anus within the sphincter complex
- Vaginal agenesis







KVV

2D

64%

Rango din. 55

P Baj.

ArmónGral



Hematometrosalpinx KS

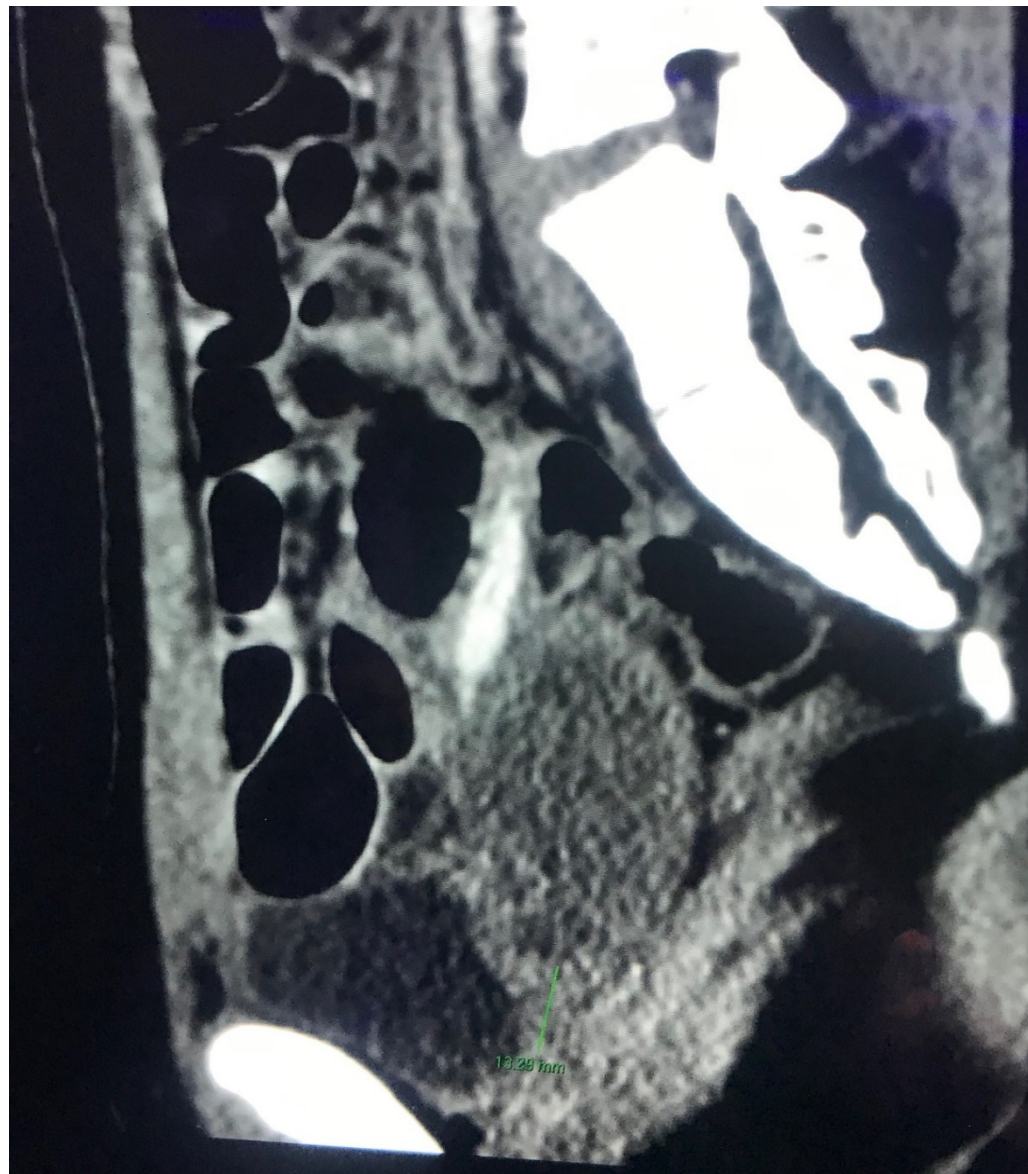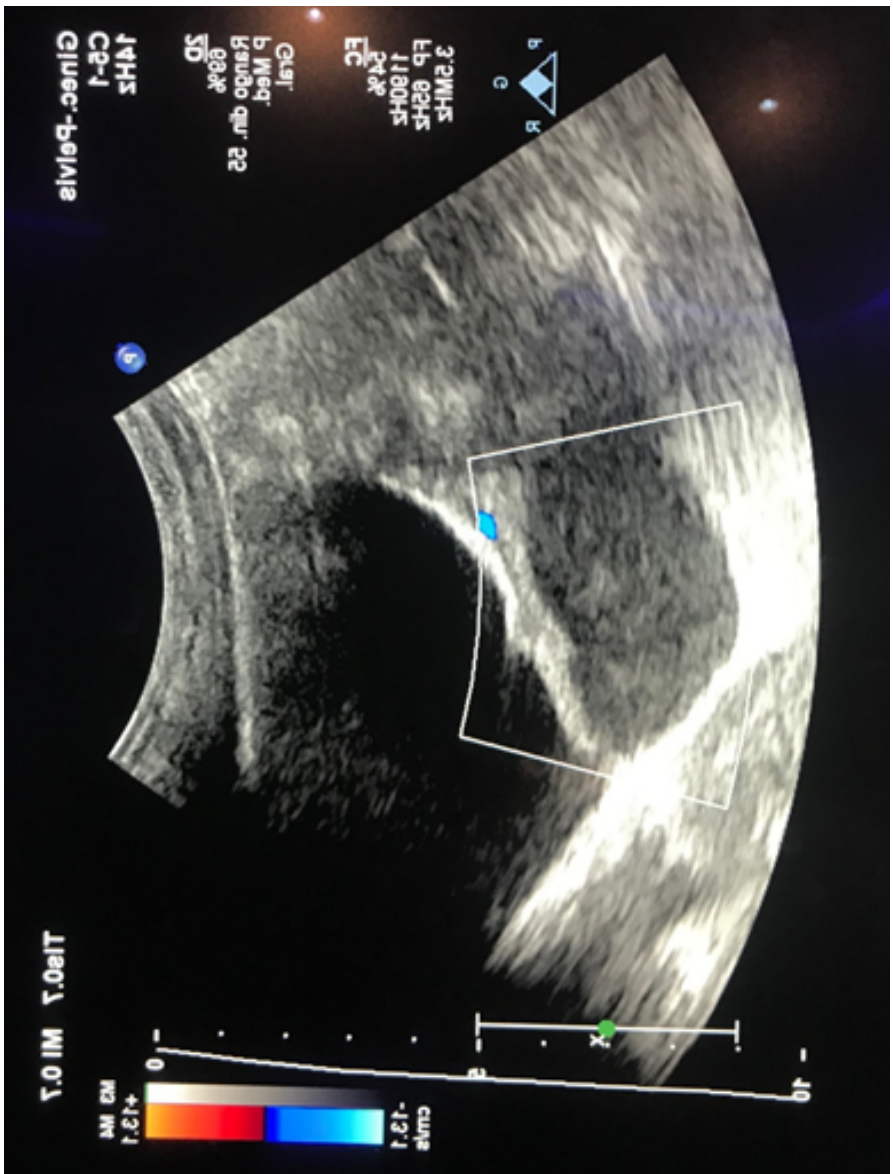
+ Dist 2.77 cm

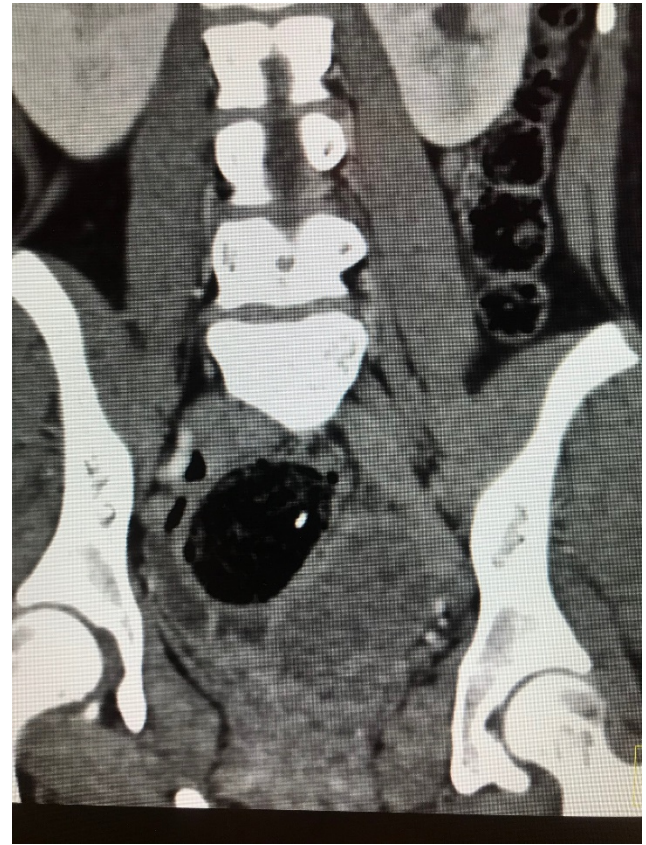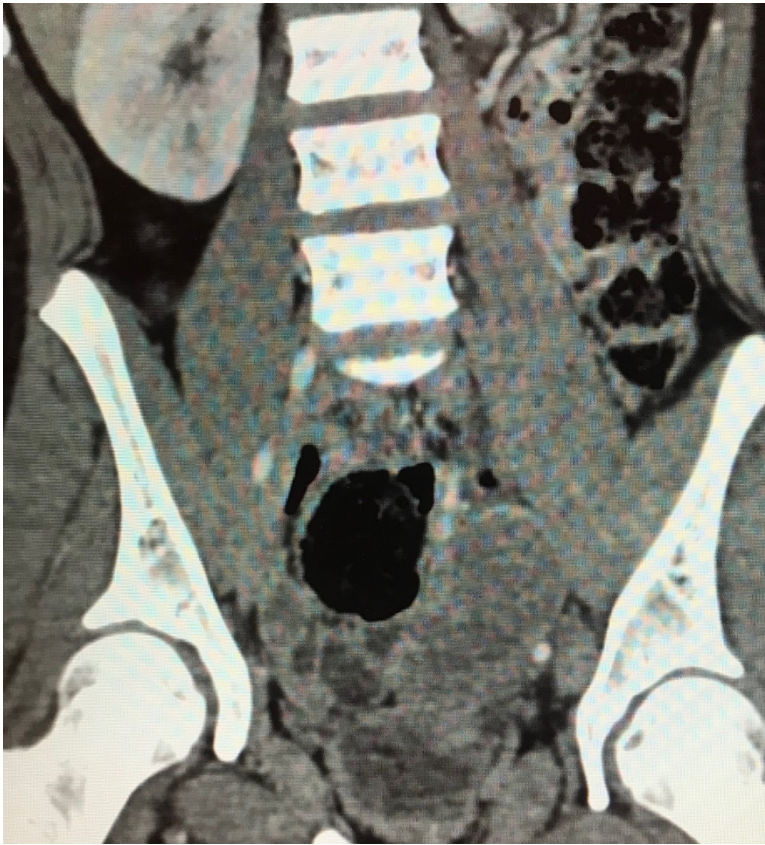- 0

- 5

- 10





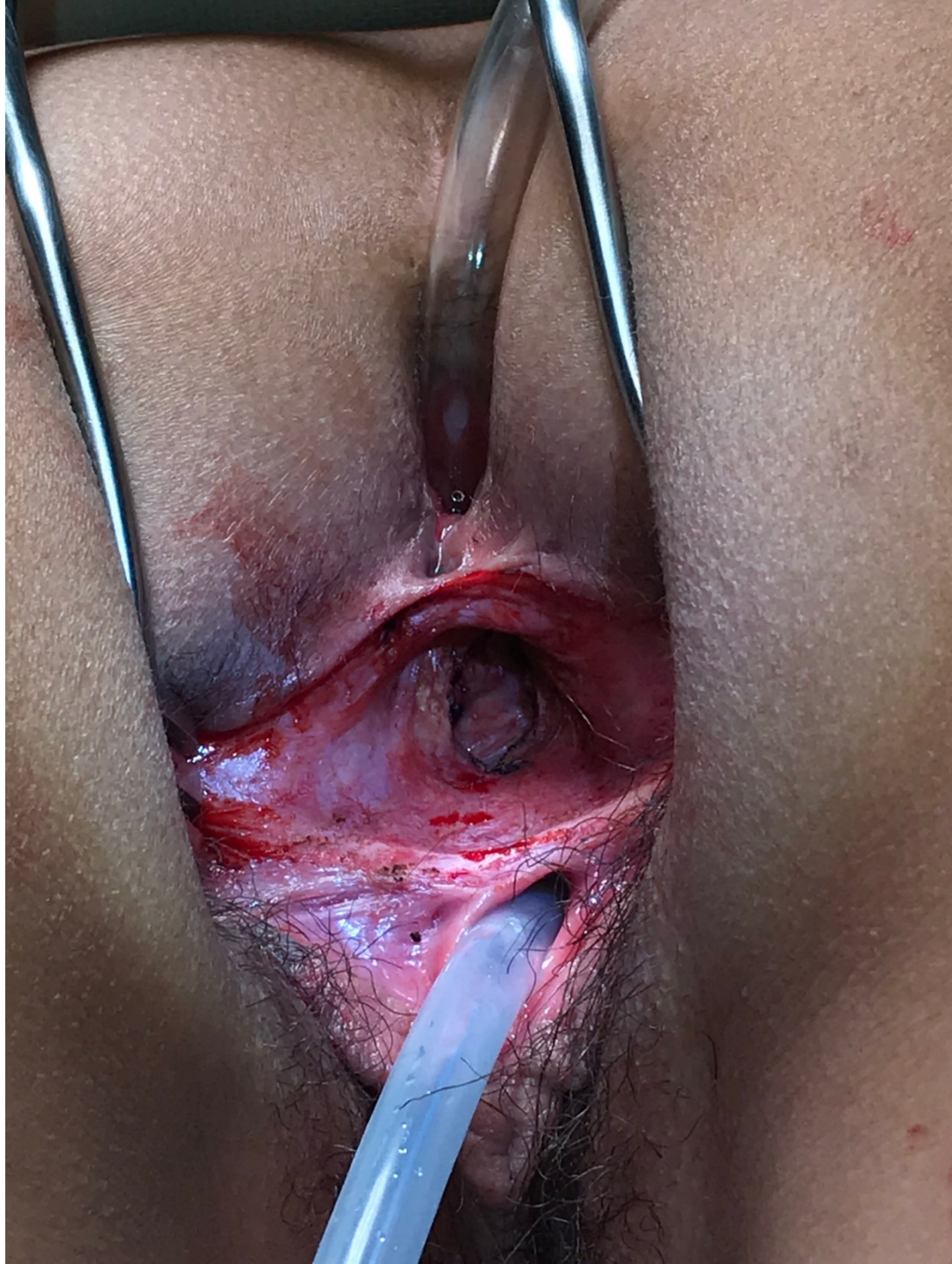
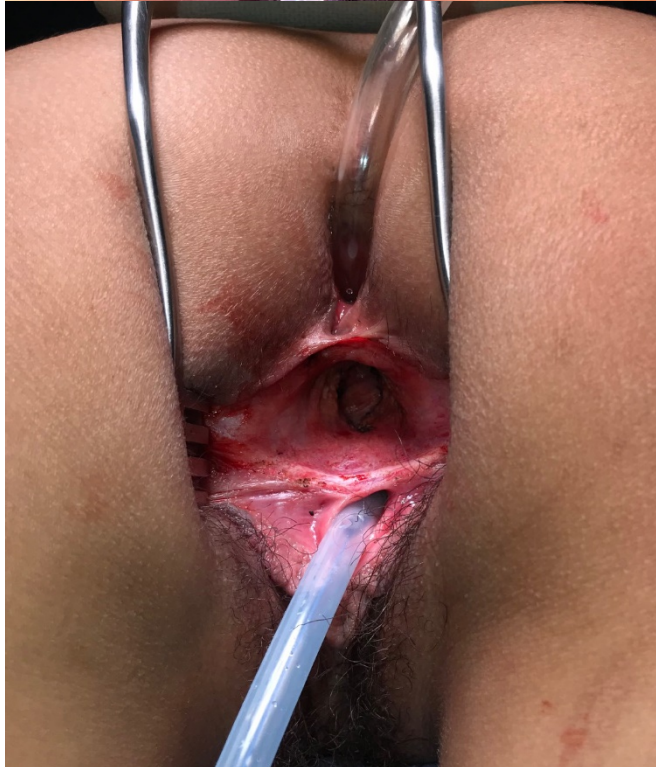
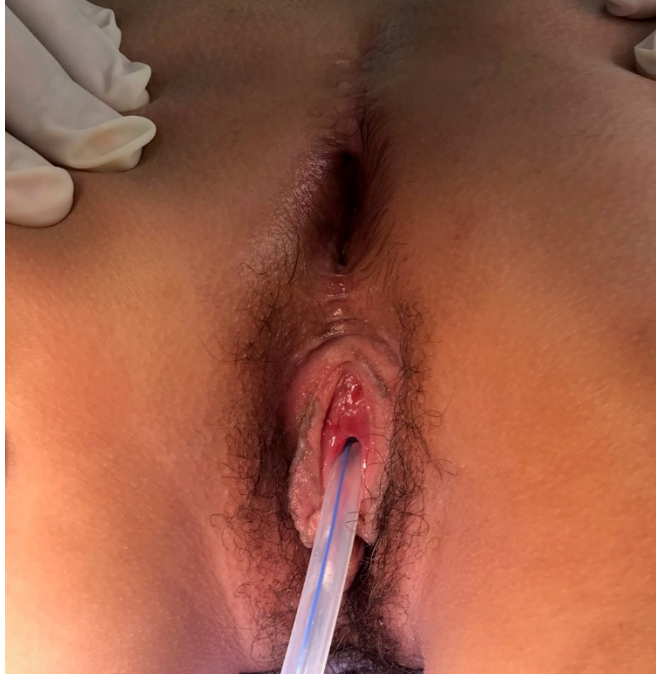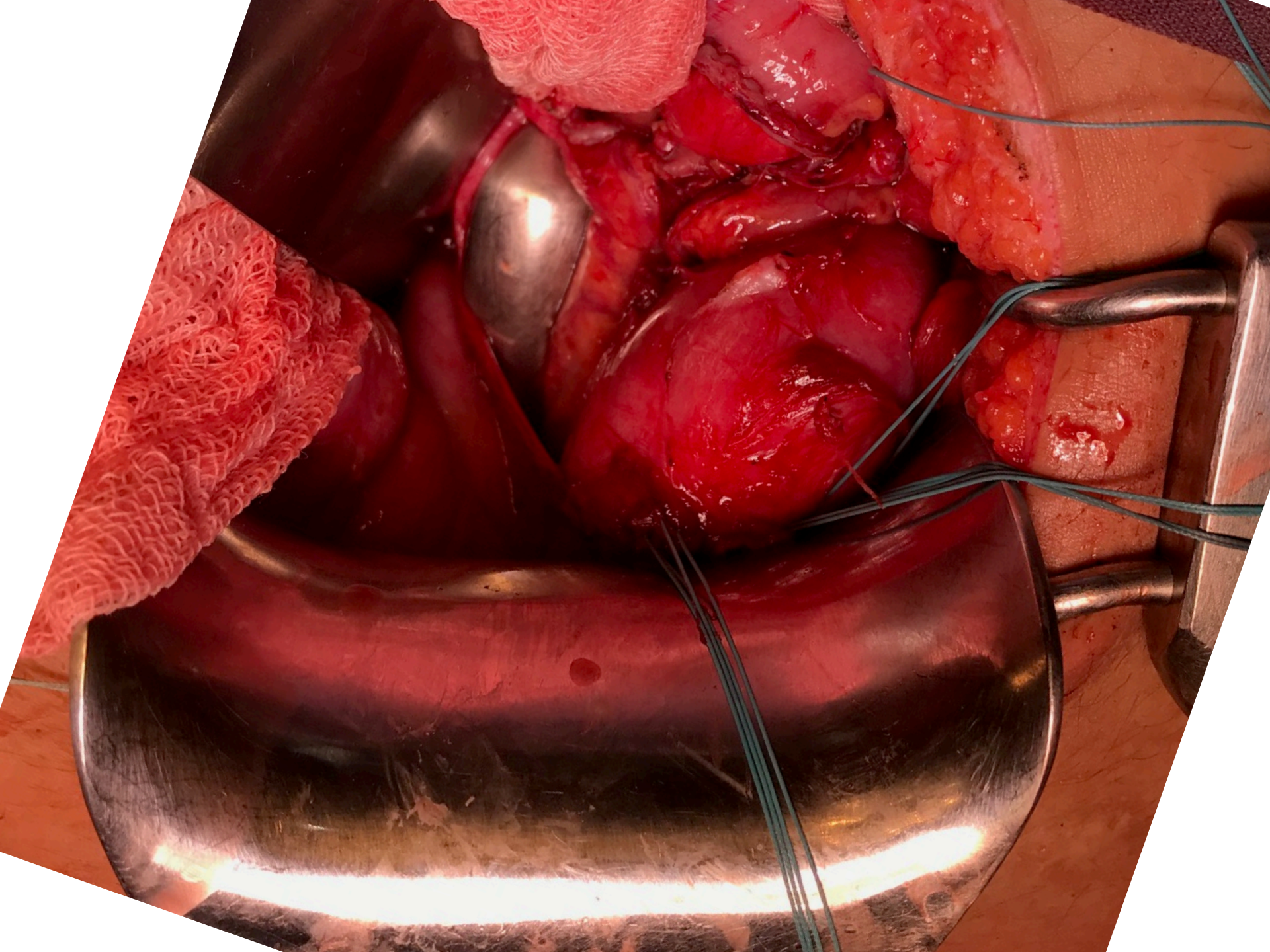
What is your first line of treatment in this patient?

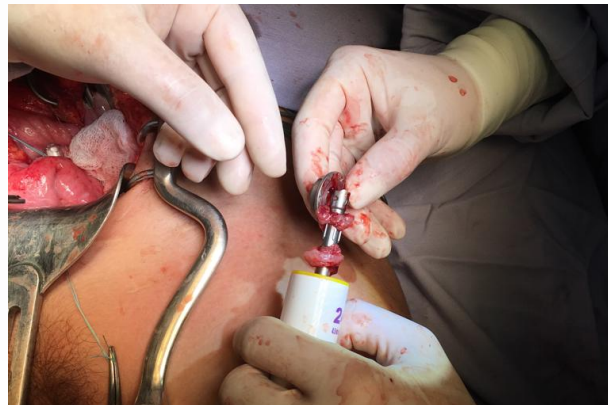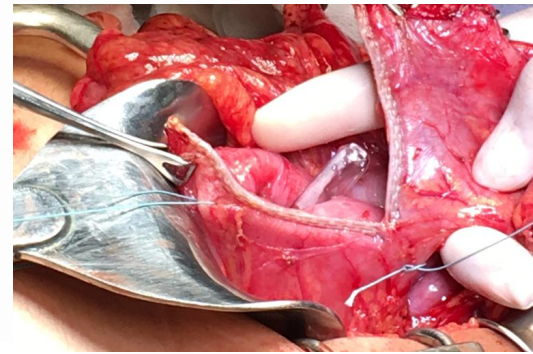
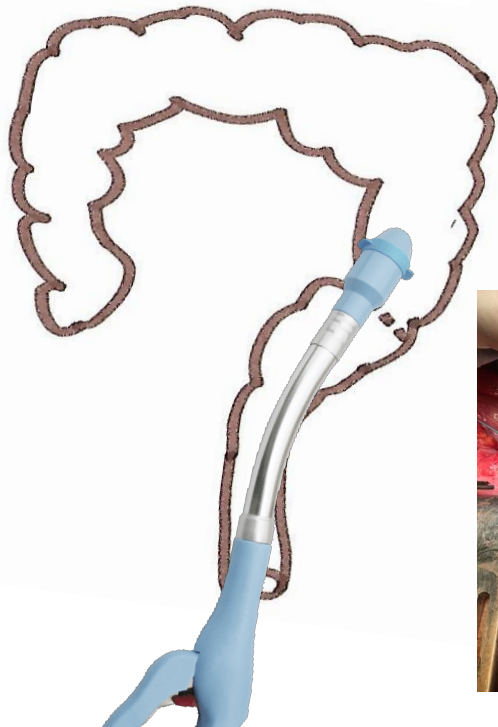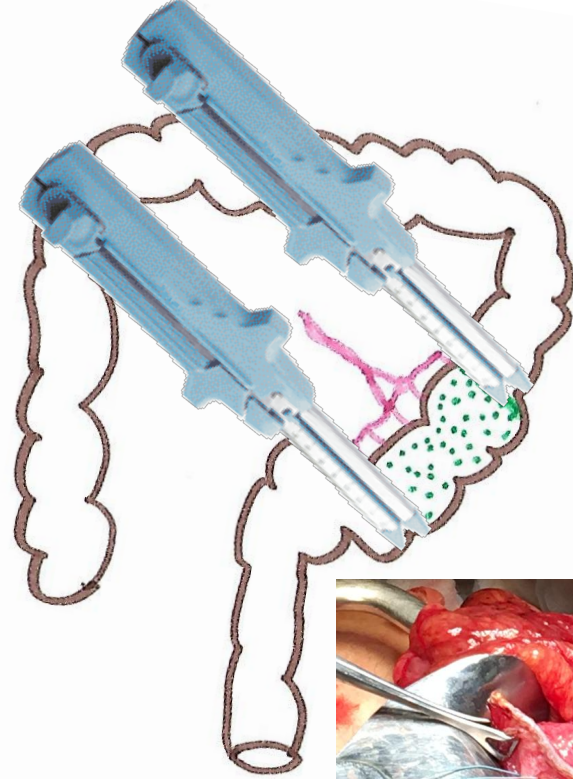
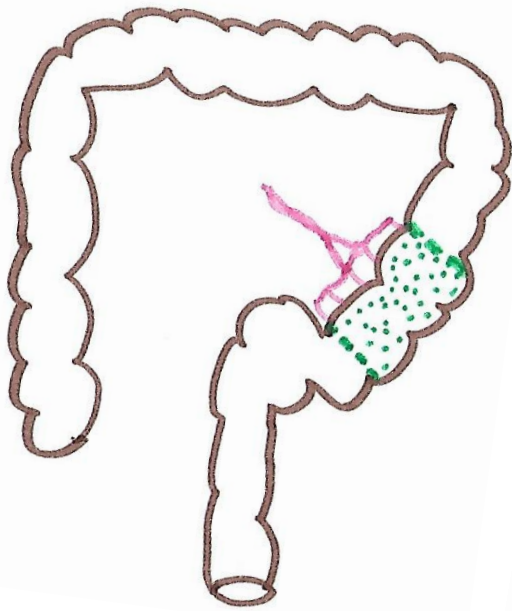
1. Follow up only
2. Hormonal suppression
3. Decompress the hematometra with a drain
4. Decompress the hematometra with a drain + hormonal suppression
5. Hysterectomy

What is your DEFINITIVE procedure?

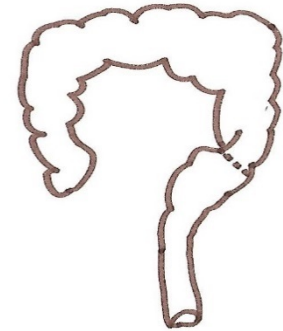
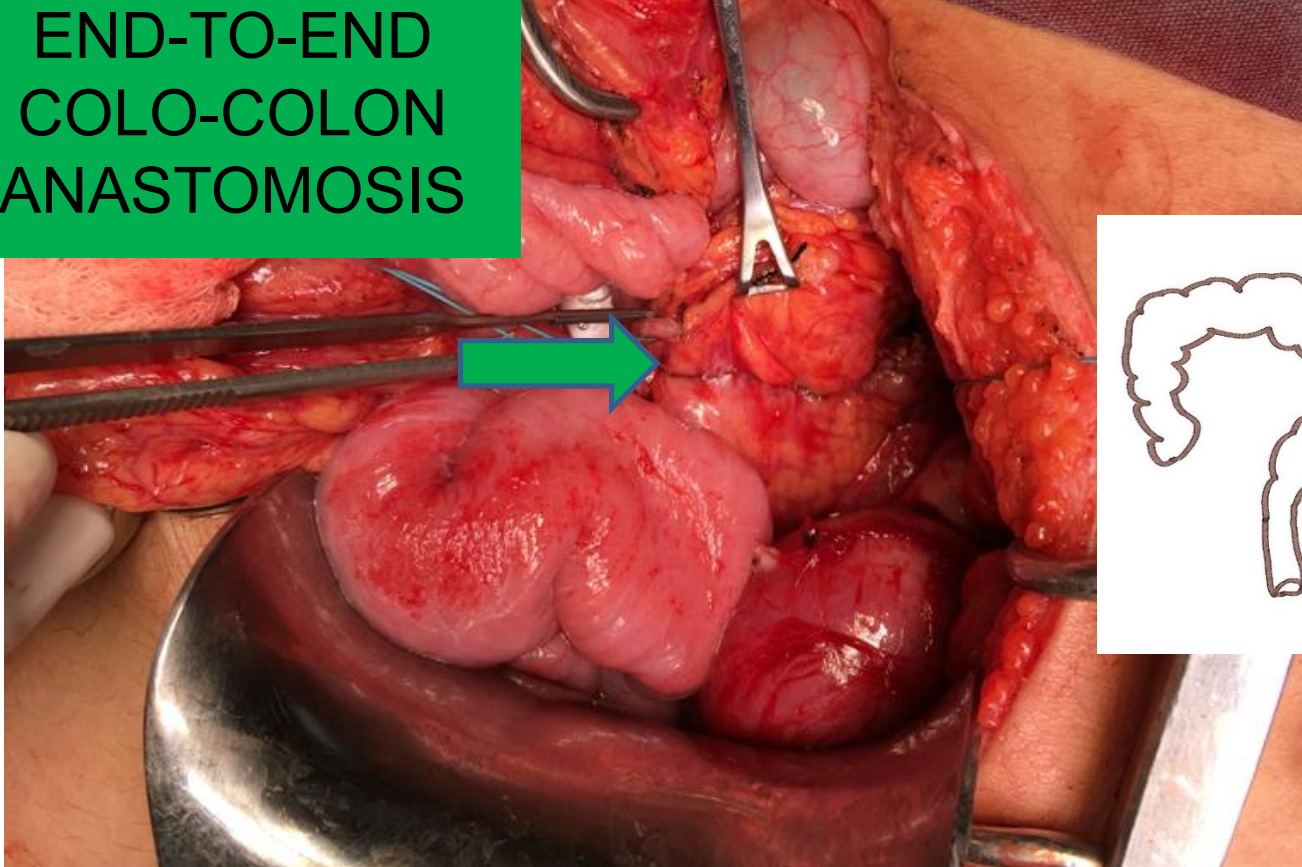
1. Vaginal replacement with ileum
2. Vaginal replacement with colon (left or sigmoid)
3. Vaginal reconstruction with Vecchietti technique
4. Vulvovaginoplasty with Williams technique
5. Only hysterectomy and vaginal replacement at other time



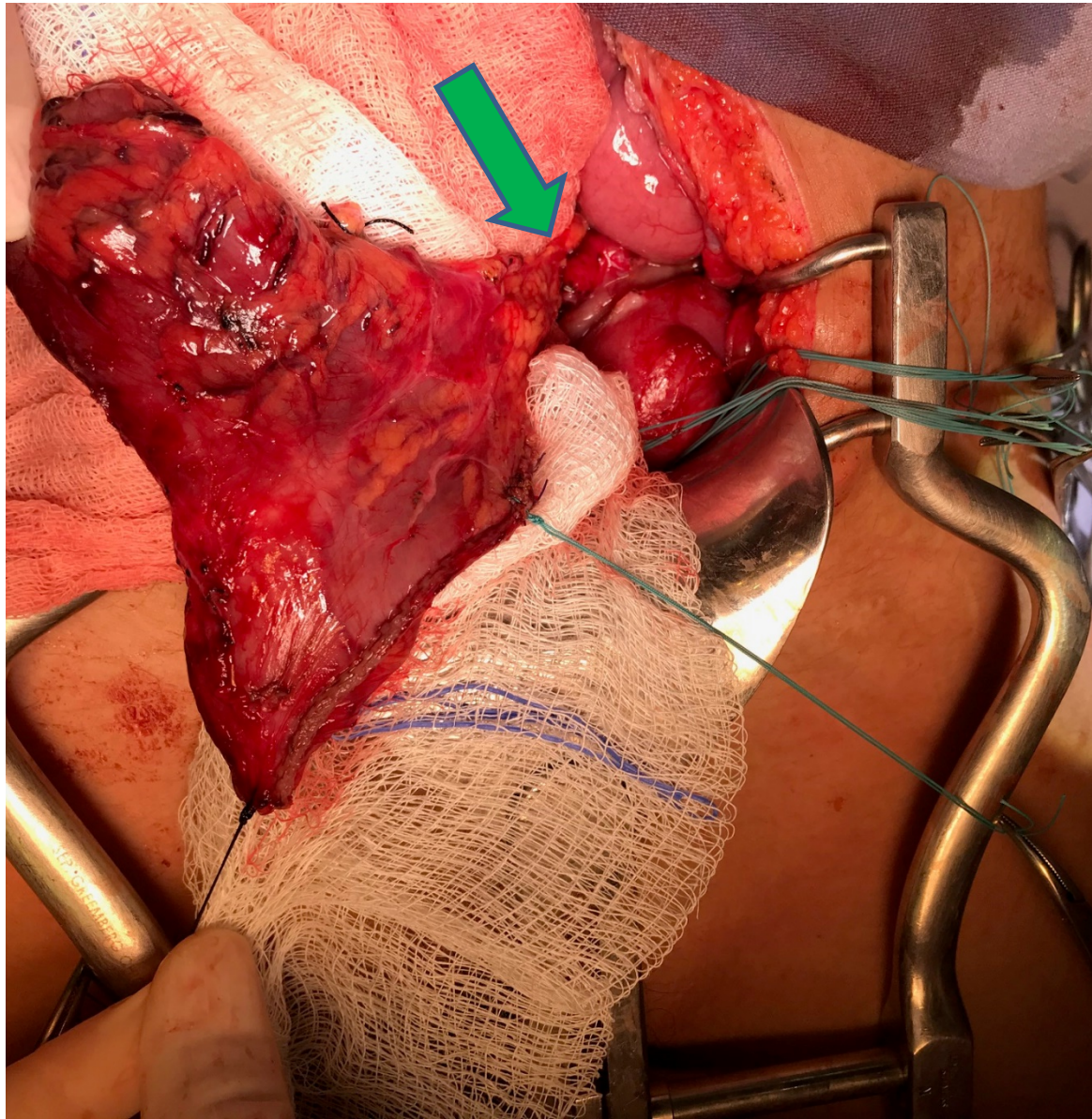


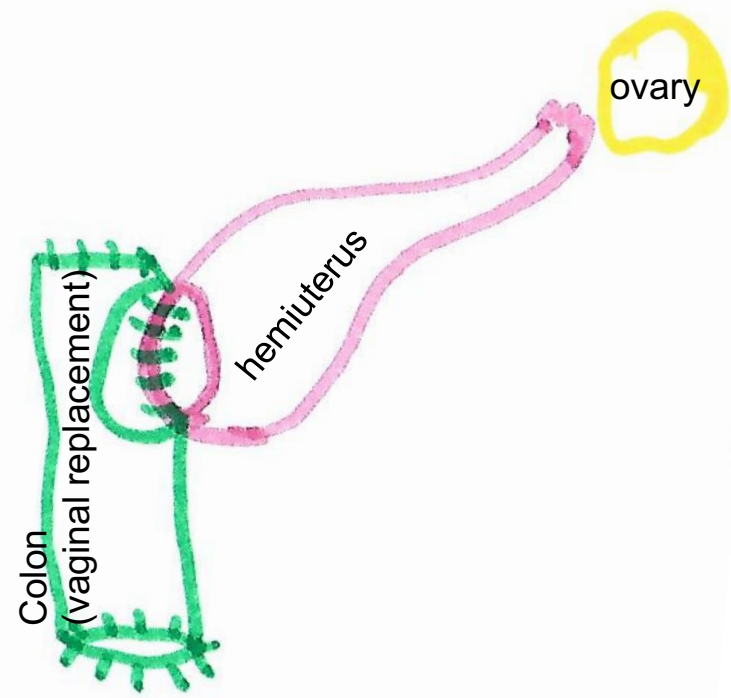
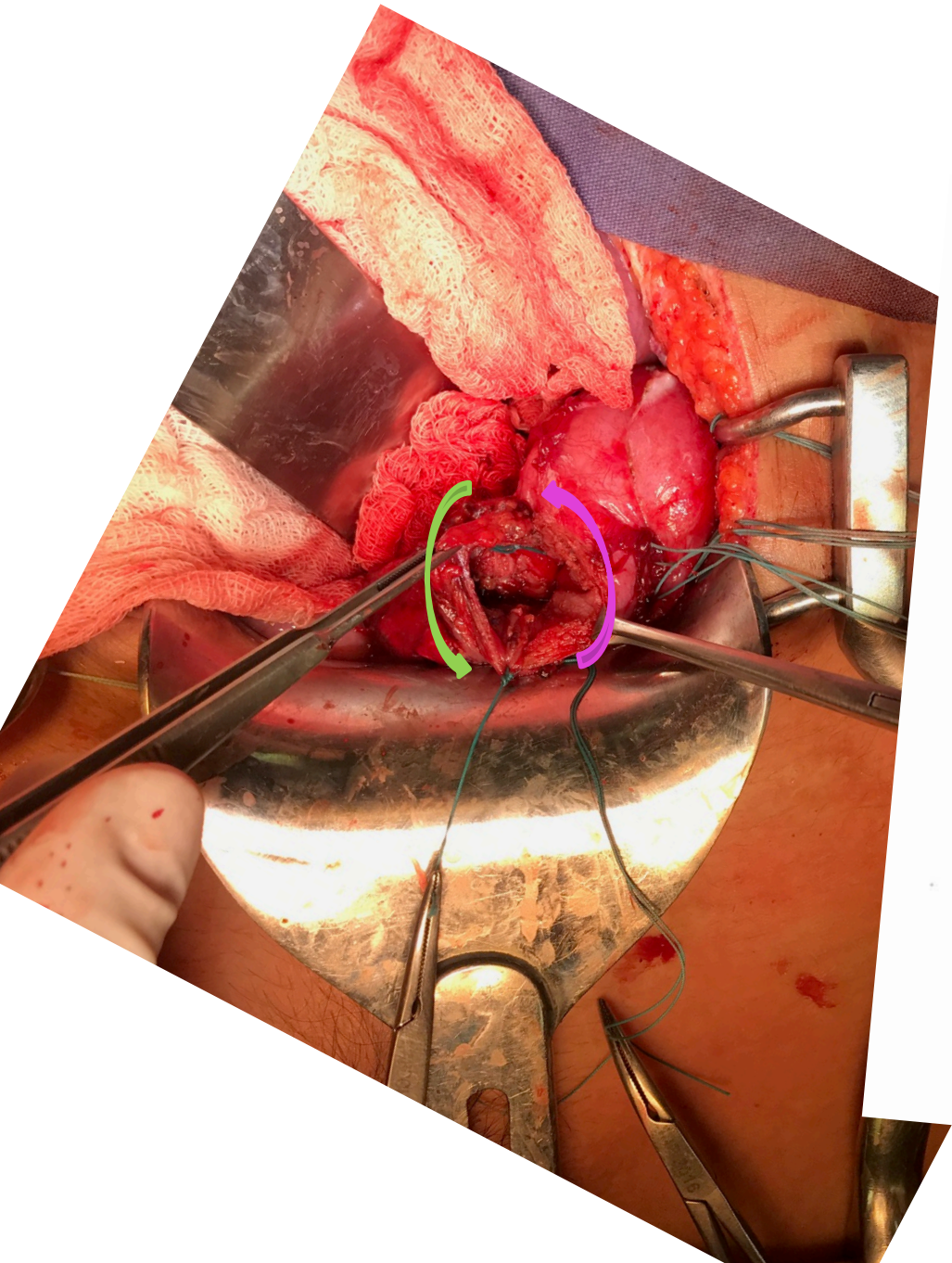


**END-TO-END
COLO-COLON
ANASTOMOSIS**



SIGMOID FOR VAGINAL REPLACEMENT





THANK YOU
santosjasso@hotmail.com

