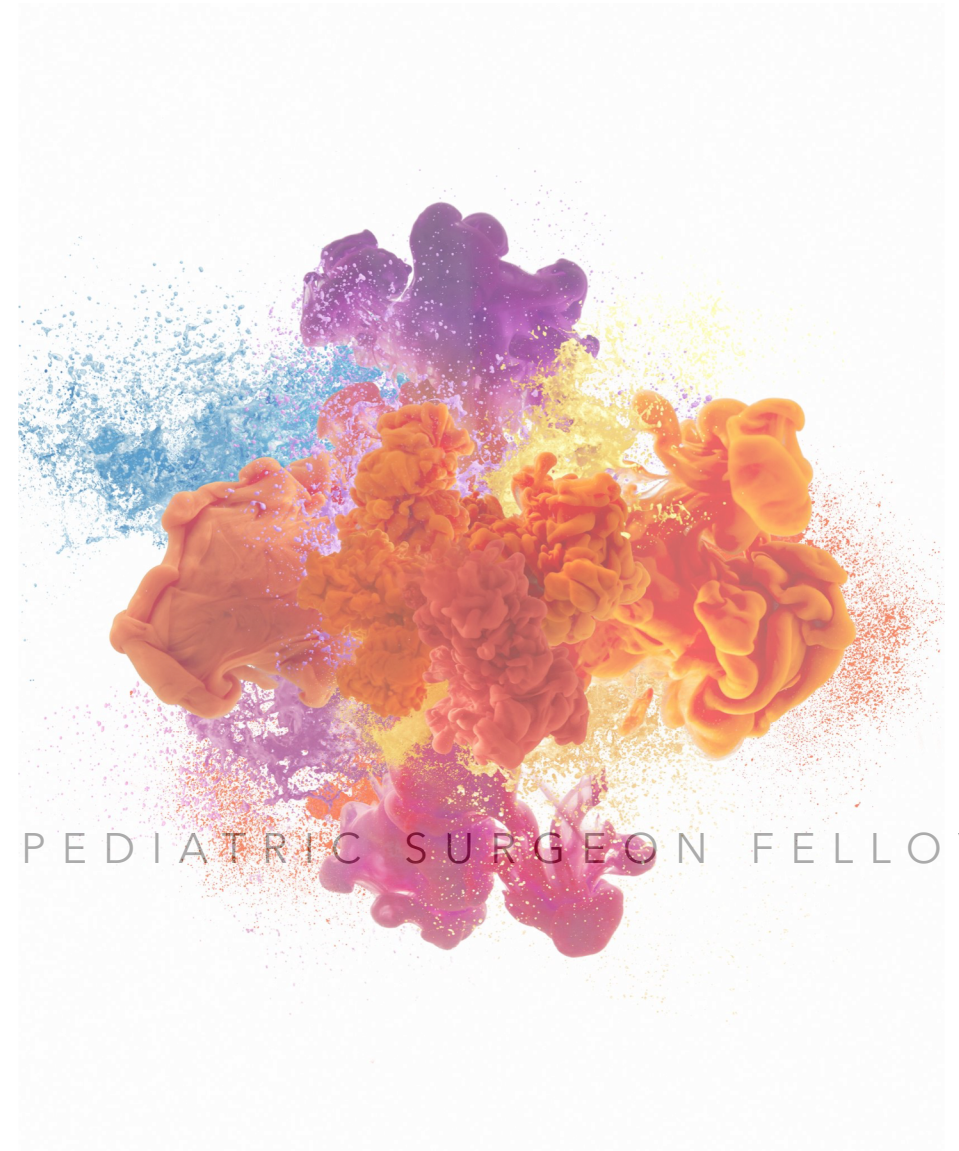

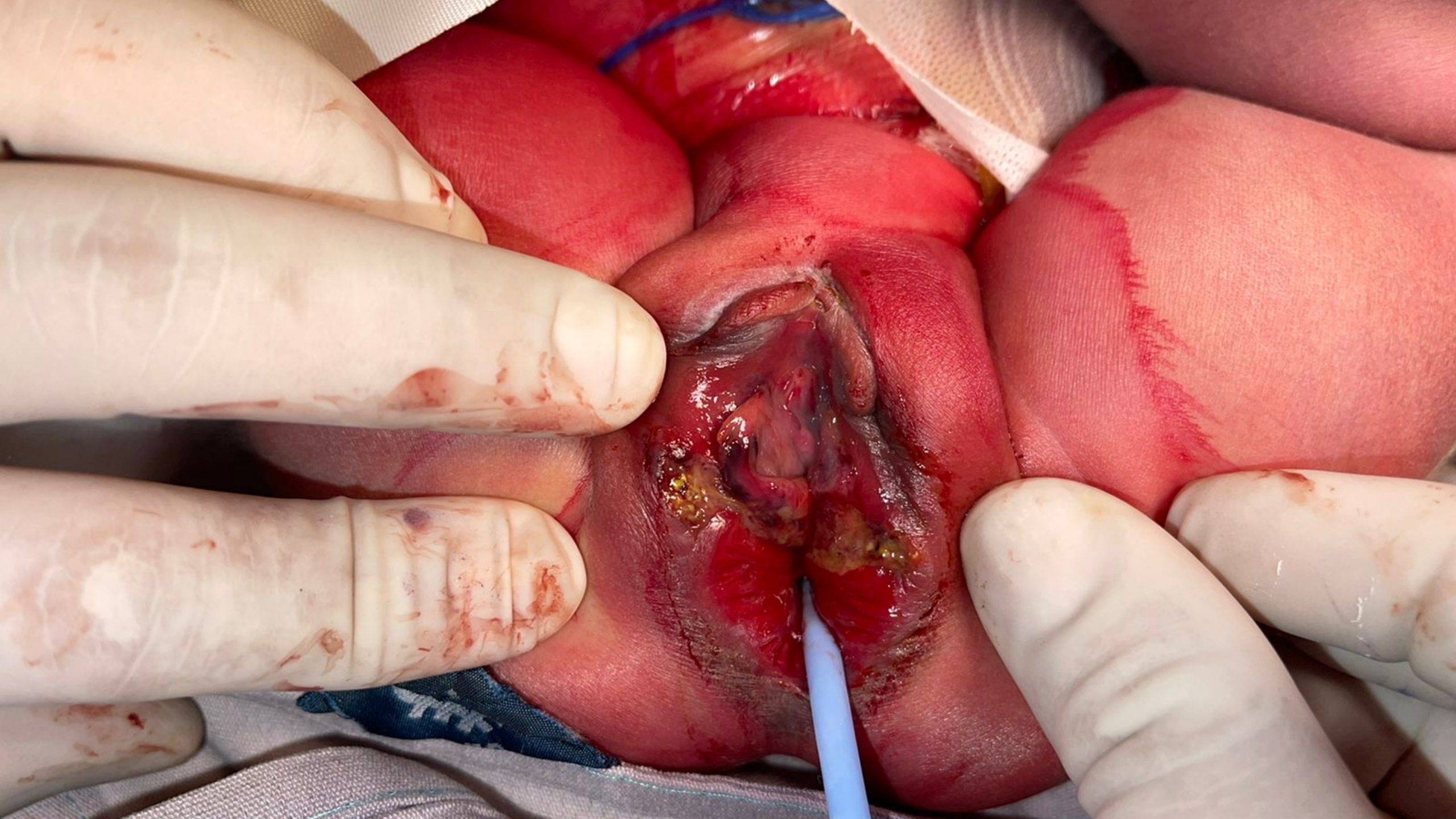COLORECTAL WEB MEETING

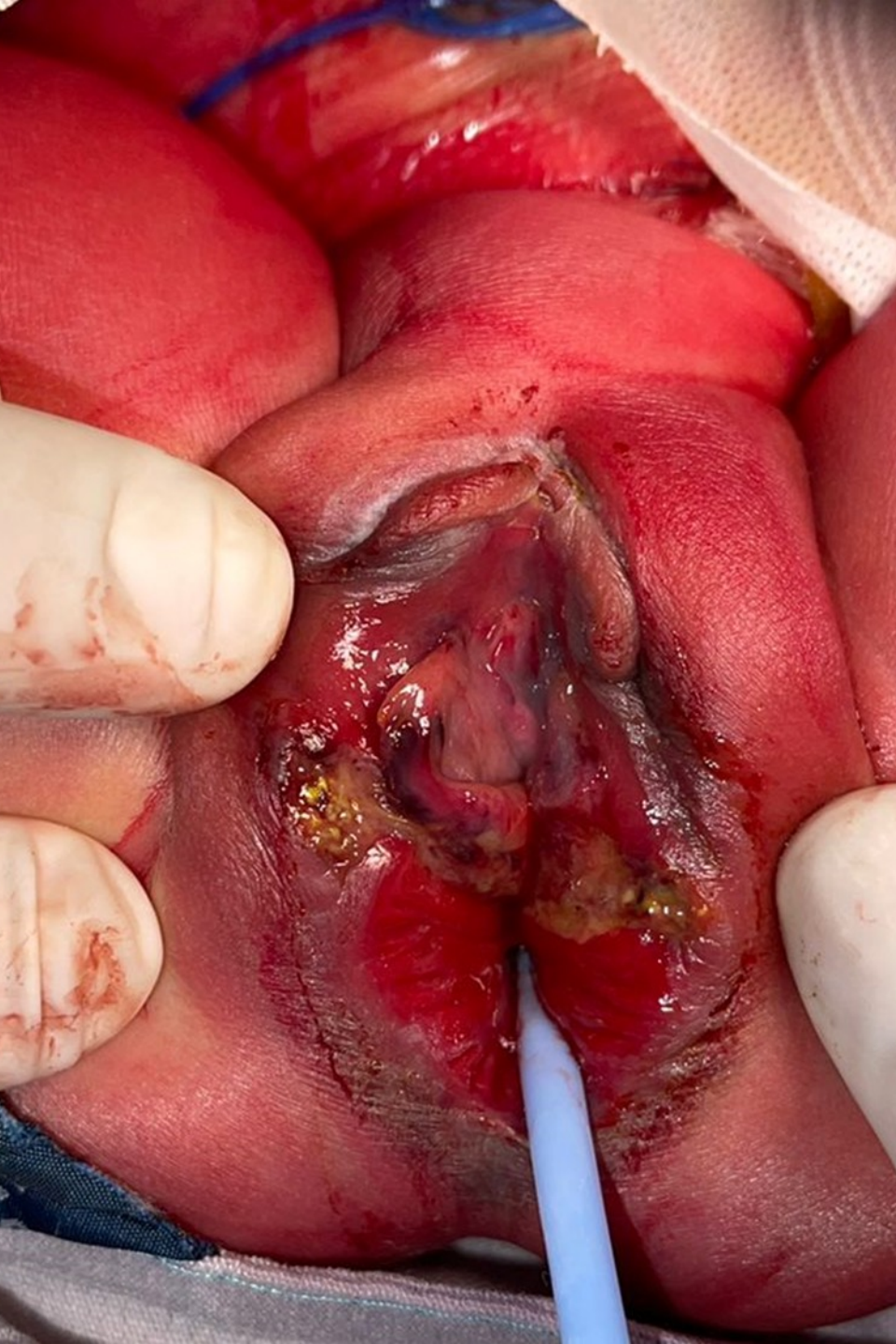
- DRA KARLA SANTOS
- DRA CAROLINA GIRALDO-COLORECTAL PEDIATRIC SURGEON FELLOW
- INSTITUTO NACIONAL DE PEDIATRÍA
- MÉXICO CITY, 2022



MEDICAL HISTORY

- 1 DAY OLD FEMALE PATIENT
- MOTHER WITH GESTATIONAL DIABETES
- RECTO-VAGINAL TEAR DURING CESAREAN SECTION

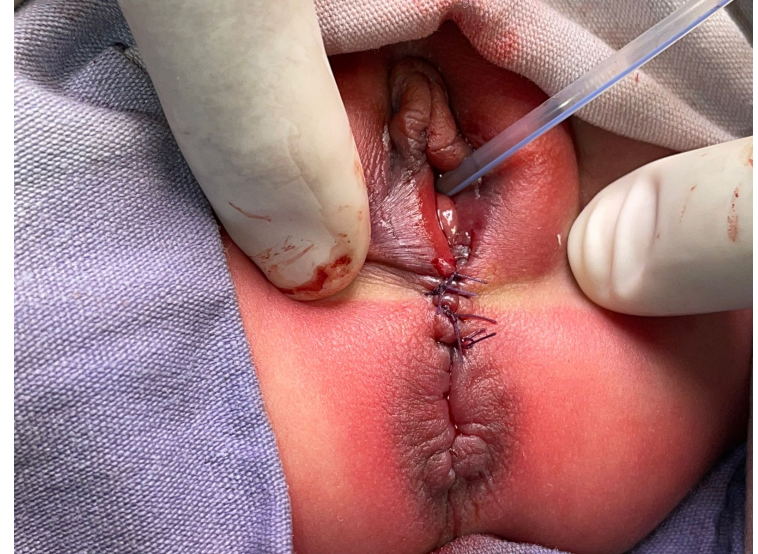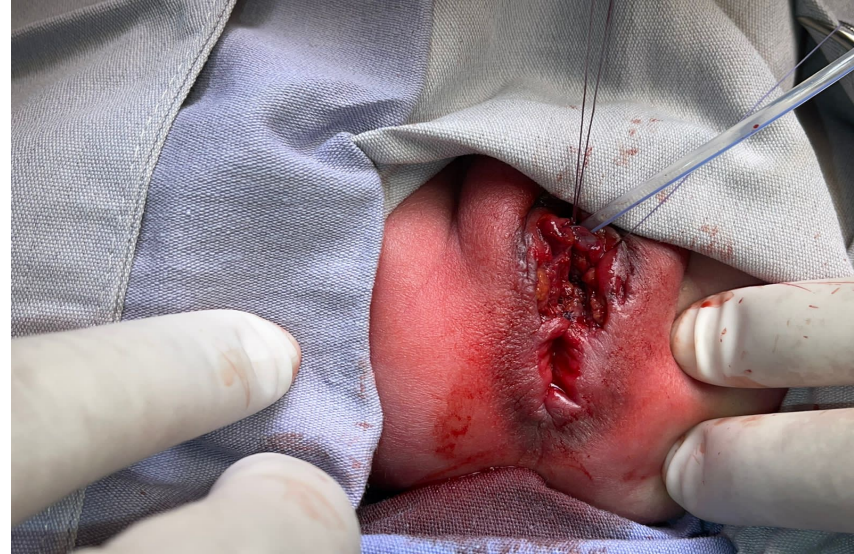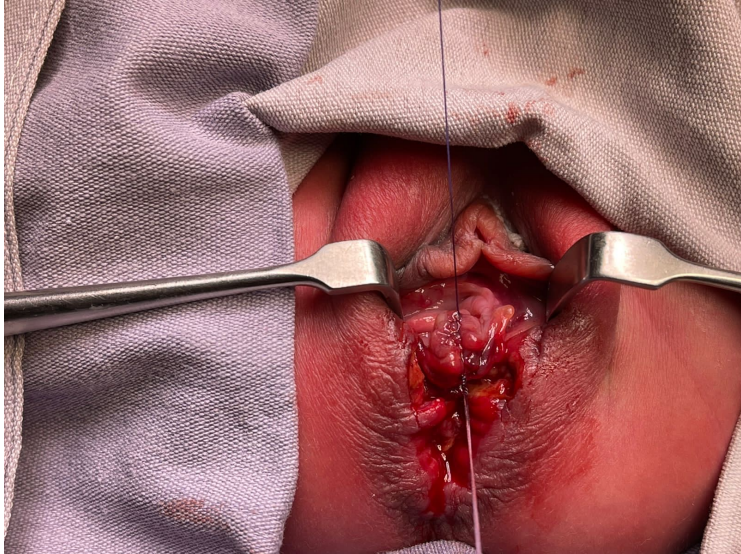




WHAT WOULD YOU DO NEXT?

- 1) COLOSTOMY
- 2) RECTO-VAGINAL PLASTY
- 3) COLOSTOMY + RECTOVAGINAL PLASTY
- 4) I DON'T KNOW

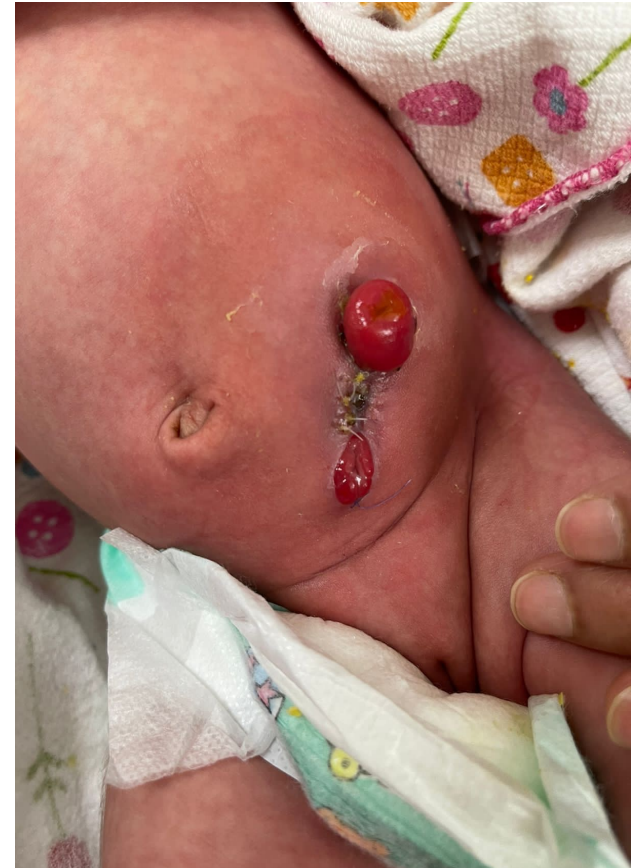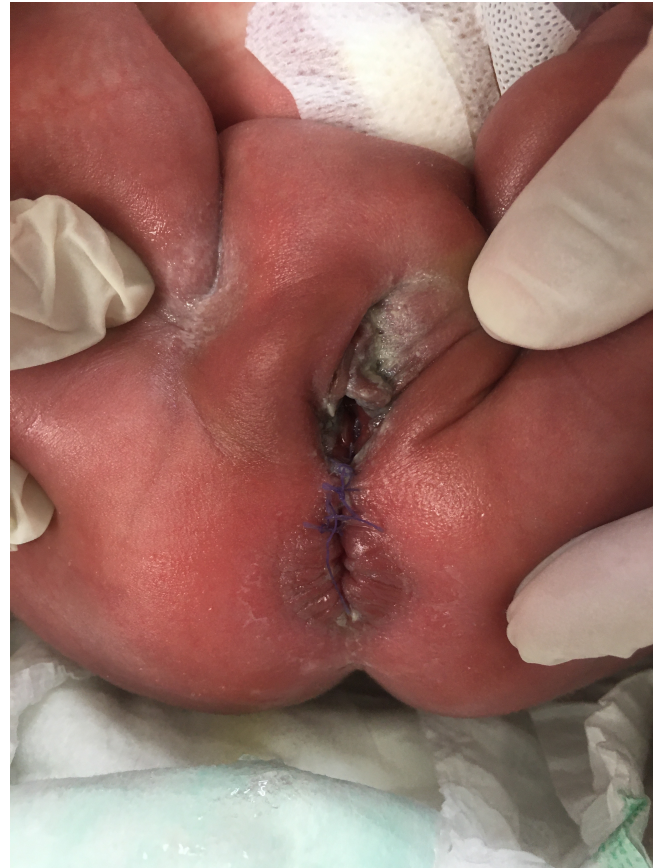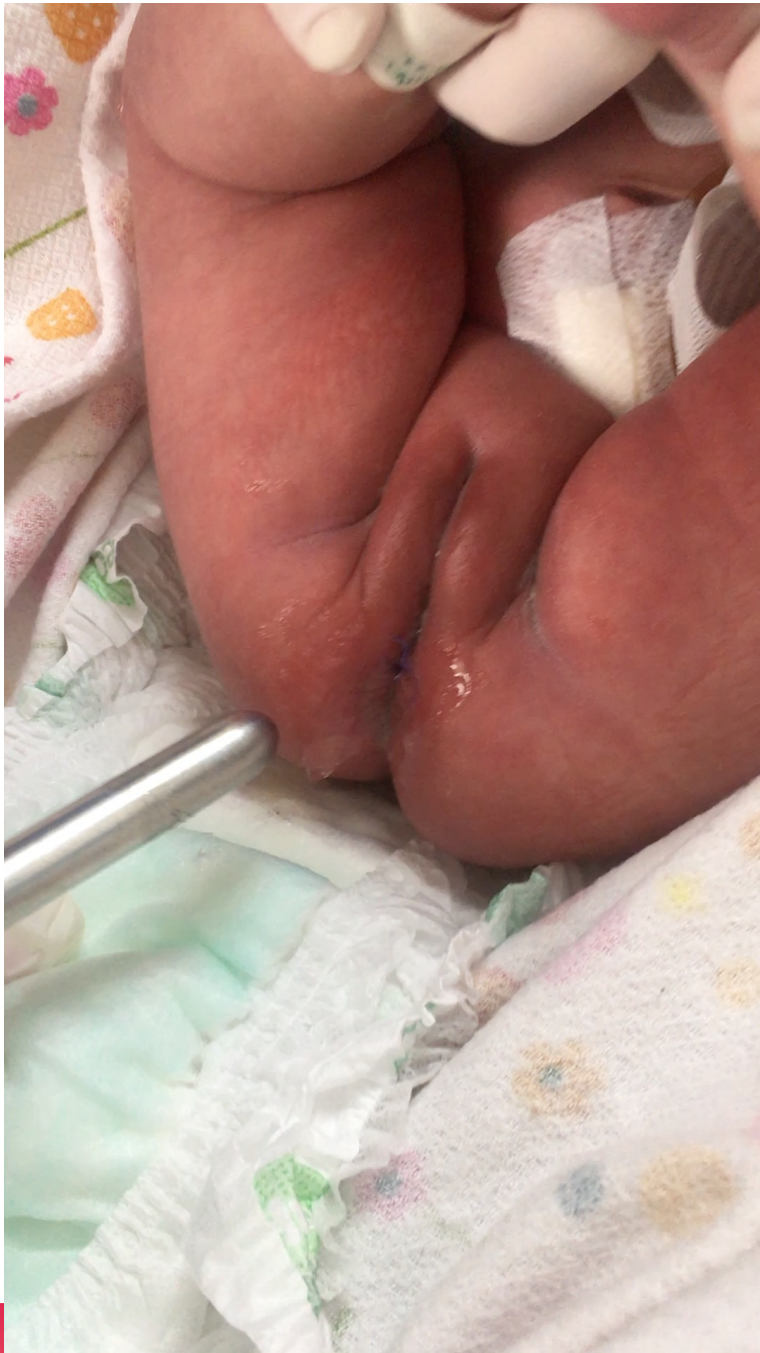THE PATIENT IS TAKEN TO THE SURGERY'S ROOM
A COLOSTOMY AND RECONSTRUCTION OF THE VAGINA
AND RECTUM IS PERFORMED



RECONSTRUCTION OF RECTUM IS PERFORMED FIRST,
THEN PERINEAL BODY AND VAGINA
AN ABSORBIBLE SUTURE 4/0 WAS USED

20TH POSTOPERATIVE DAY

ANAL CALIBRATION WT HEGAR NUMBER 12
PARTIAL DEHISCENCE OF THE SKIN BETWEEN
STOMAS



THANK YOU