

# Case # 3

---

Andrea Bischoff, MD



Children's Hospital Colorado

INTERNATIONAL CENTER FOR  
**COLORECTAL AND  
UROGENITAL CARE**

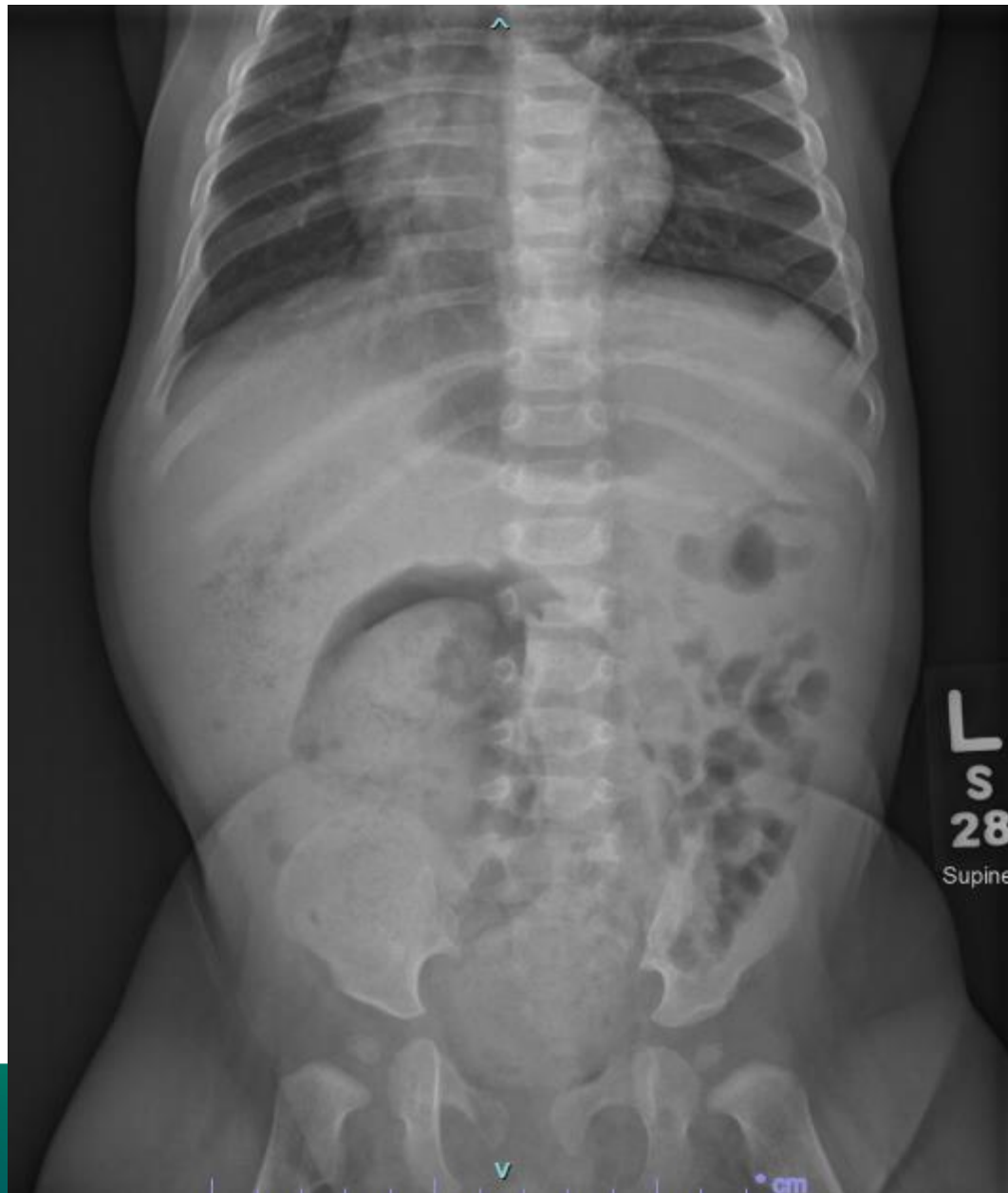

8 months old male patient  
with constipation since 2  
weeks of life

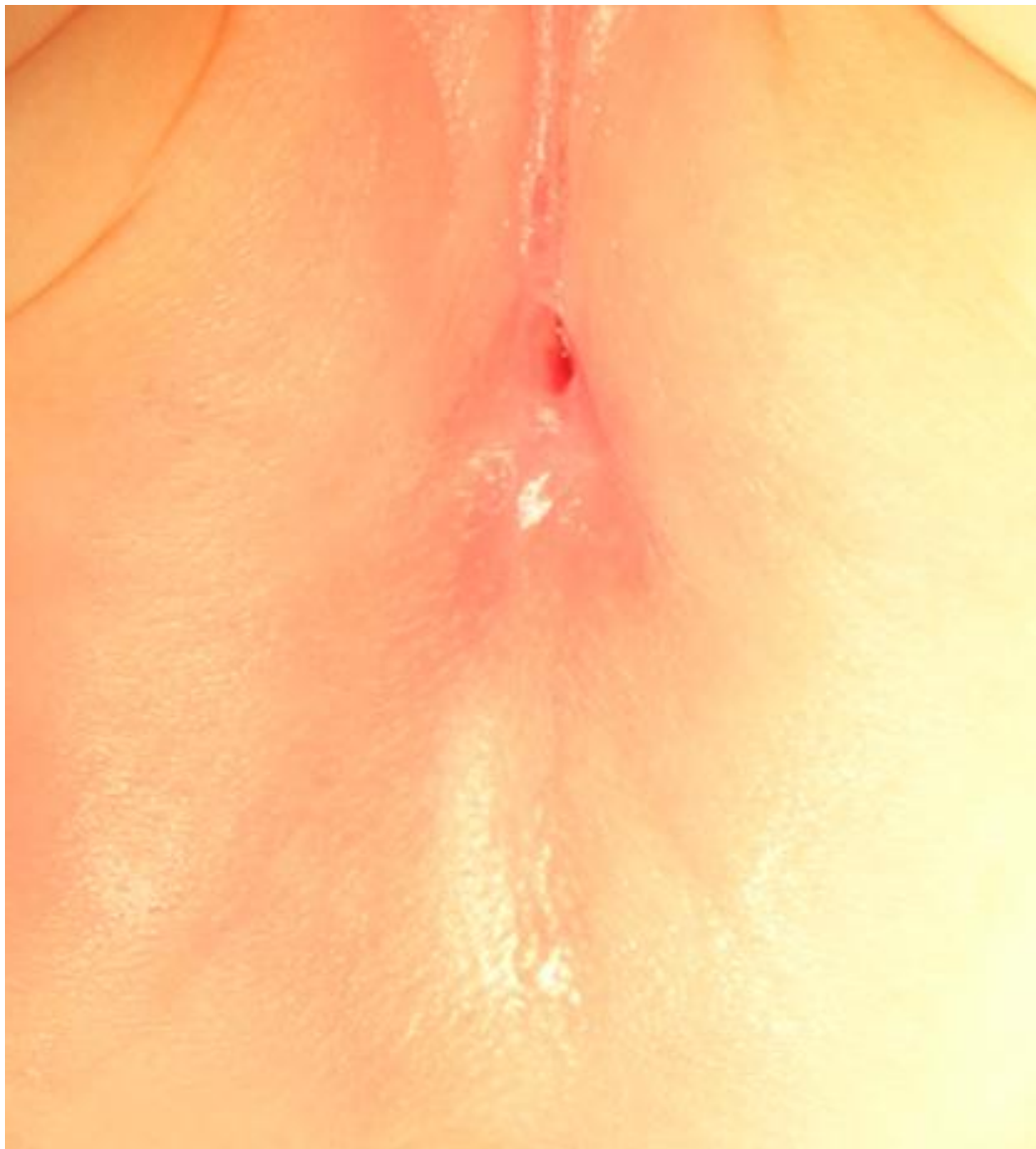# With this history, what would like to do?



1. Rectal biopsy and contrast enema
2. Physical exam
3. Manometry
4. I don't know



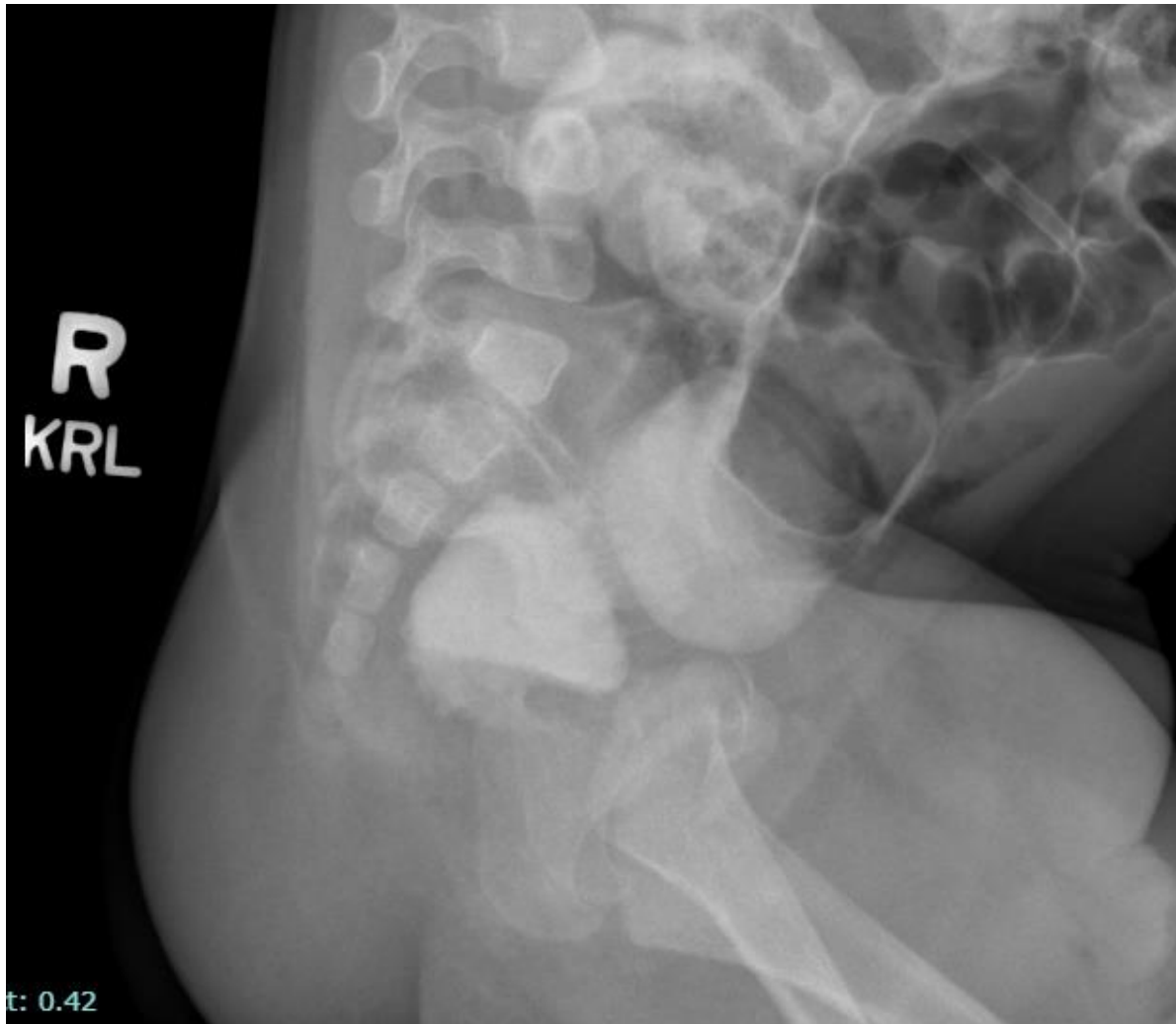
ATIONAL CENTER FOR  
**RECTAL AND**  
**UROGENITAL CARE**

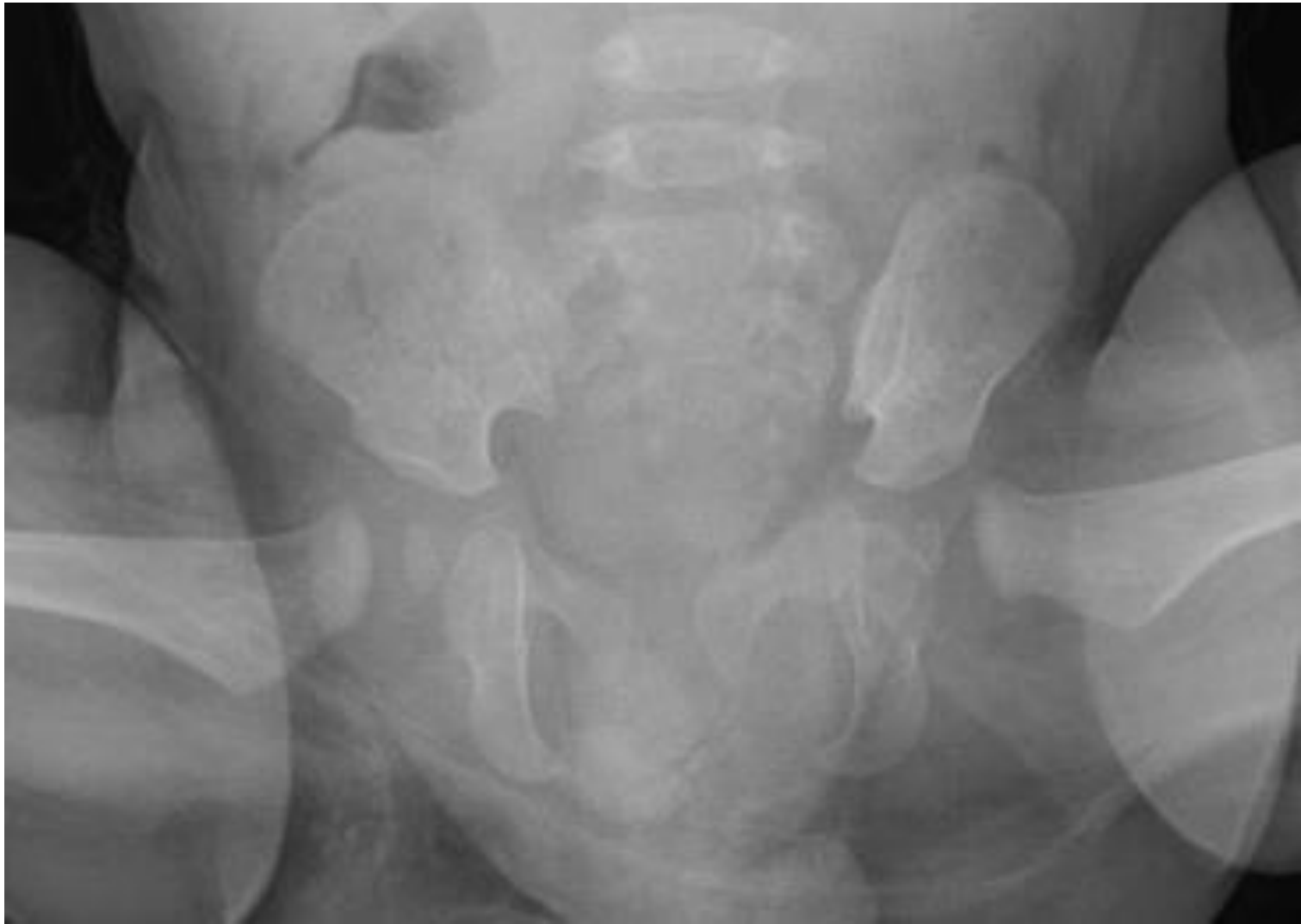

# What studies would you like to order now?

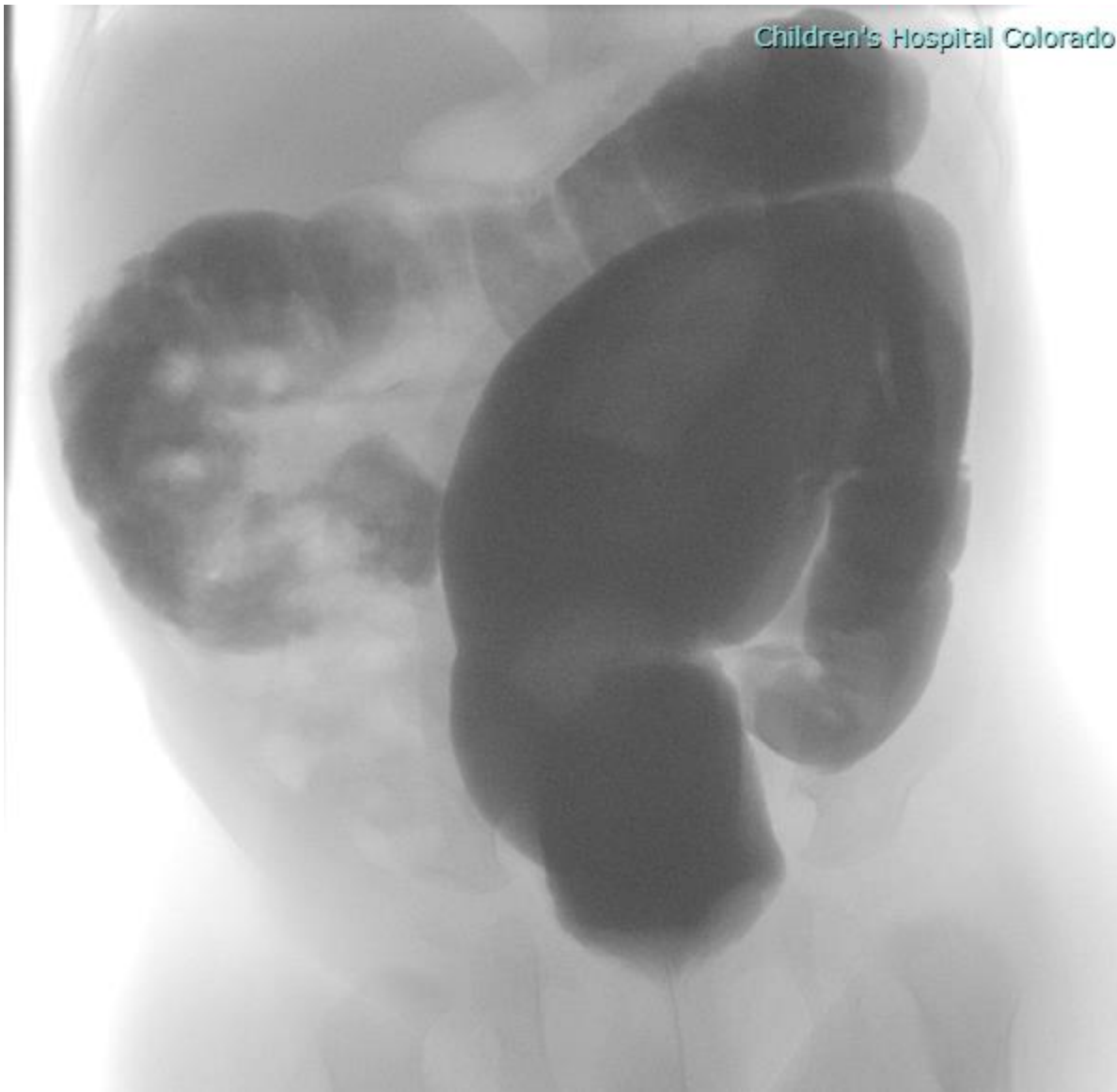

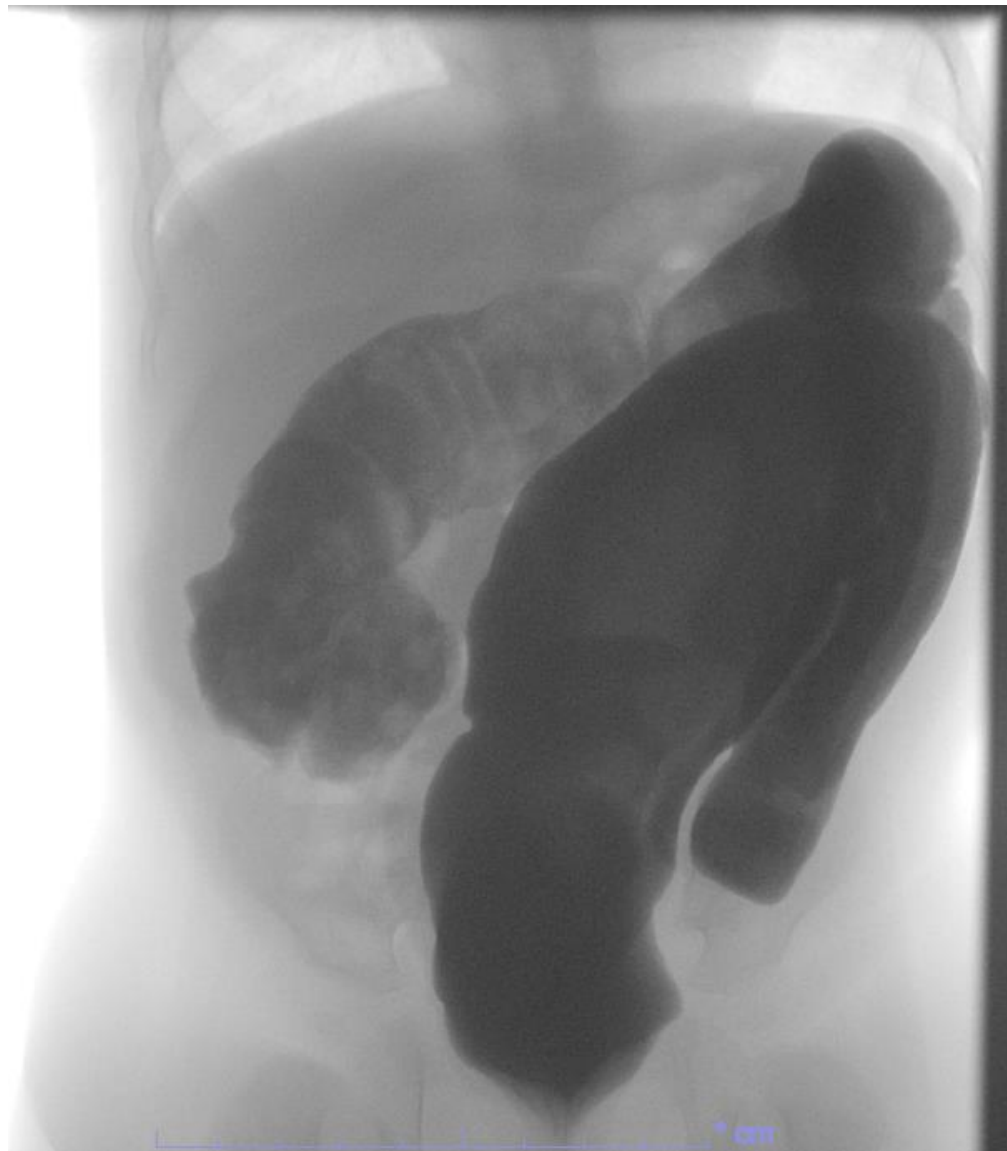1. Sacral x-ray AP and Lateral
2. Spinal US
3. Spinal and Pelvis MRI
4. Contrast enema
5. Kidney ultrasound
6. Four of the above

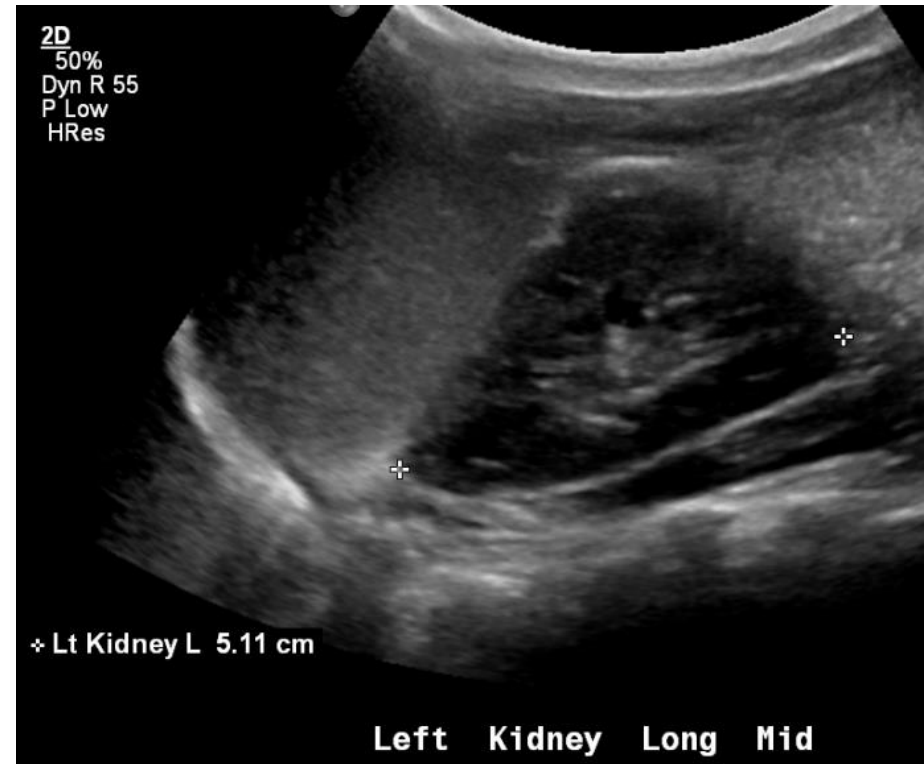
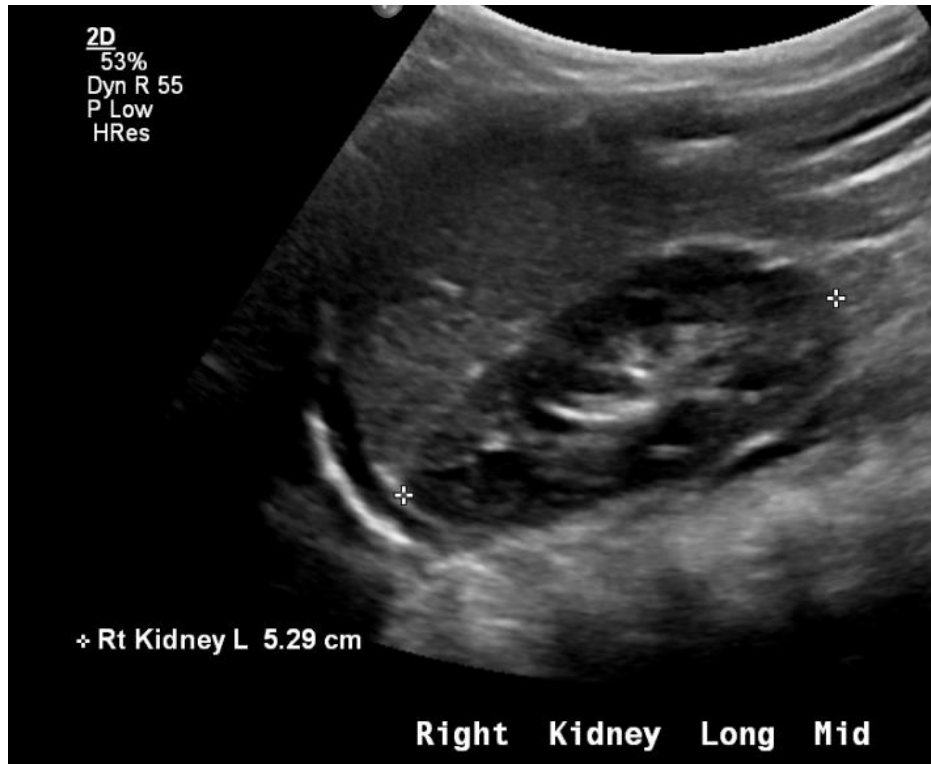


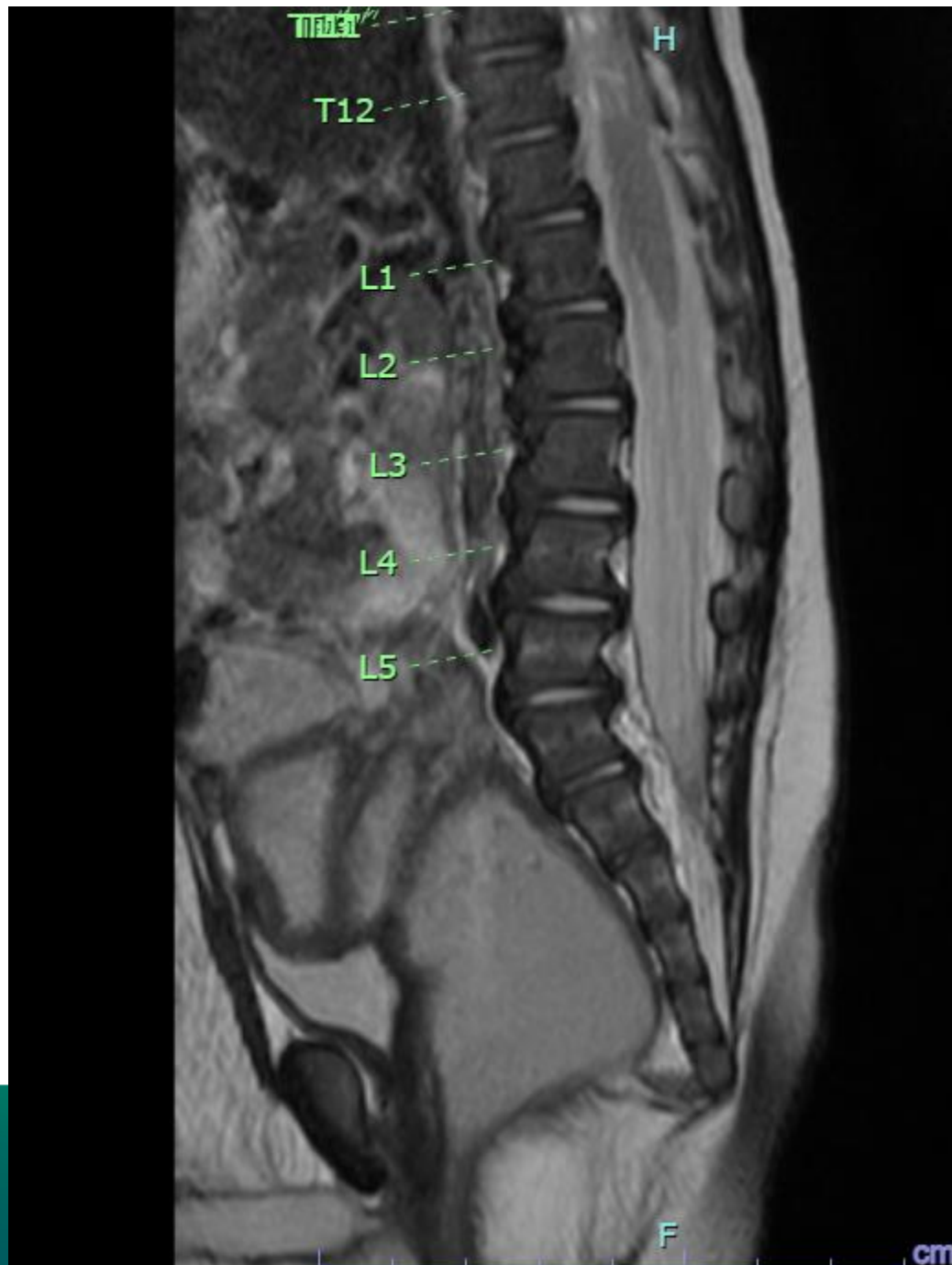


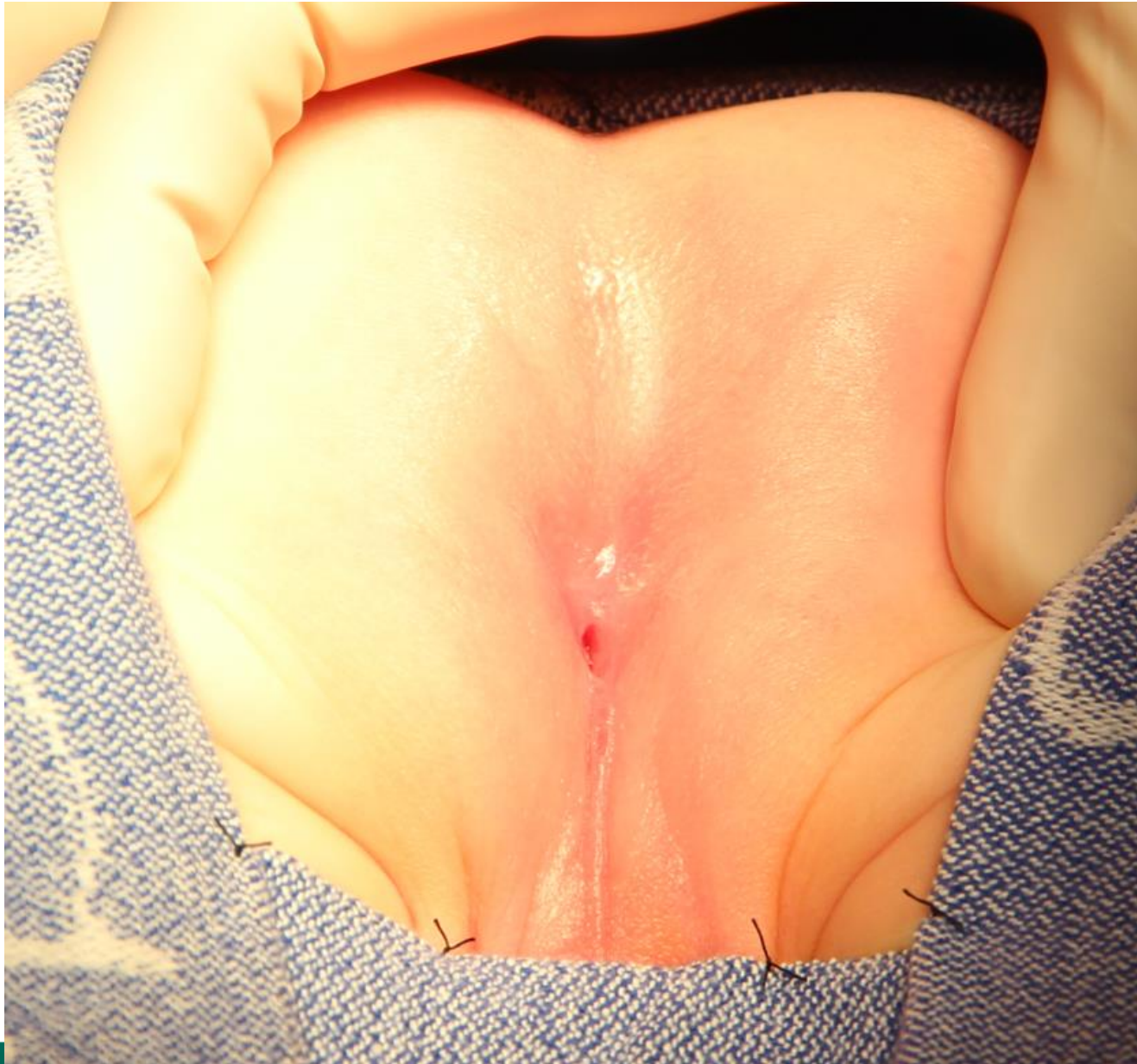





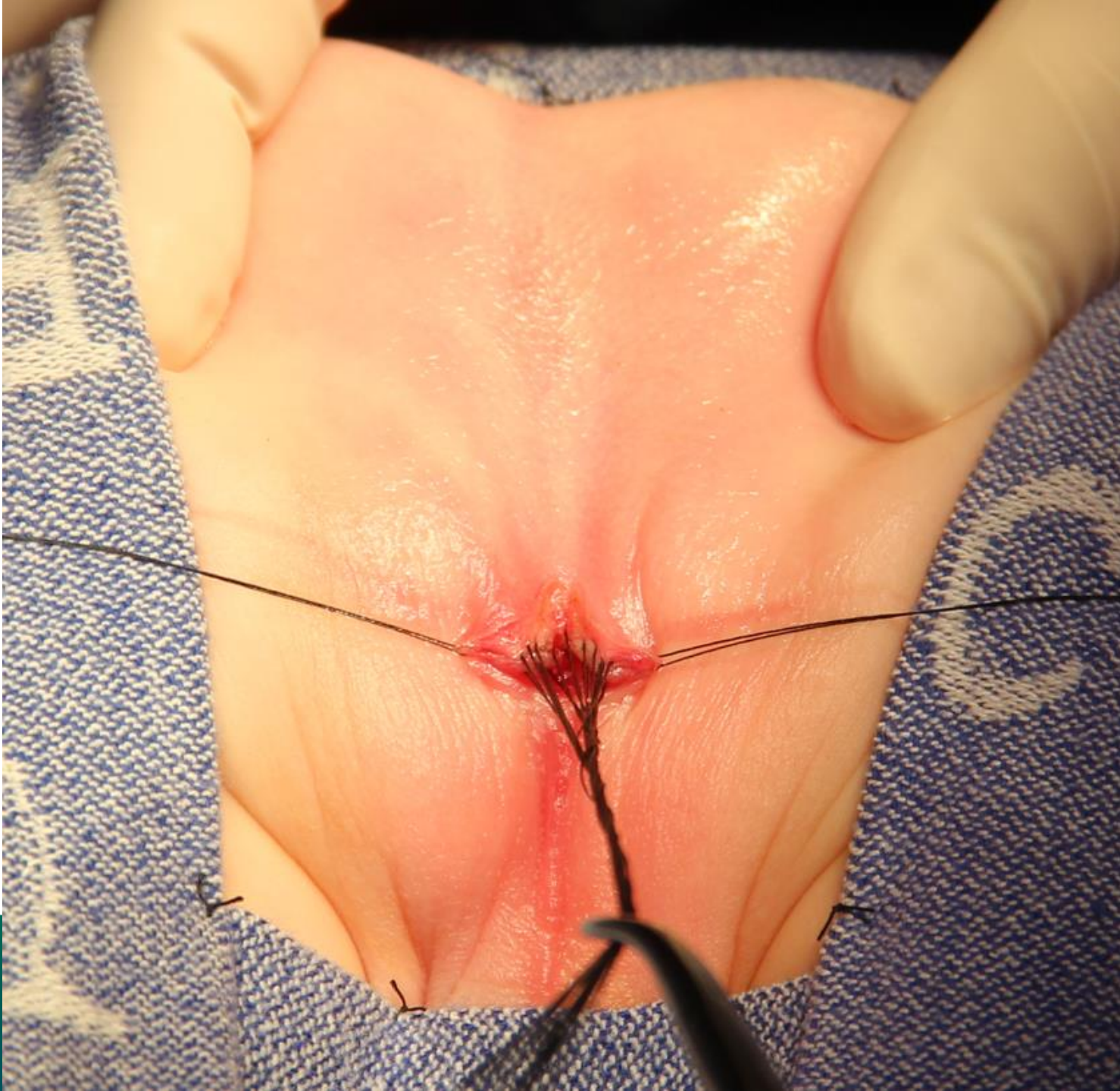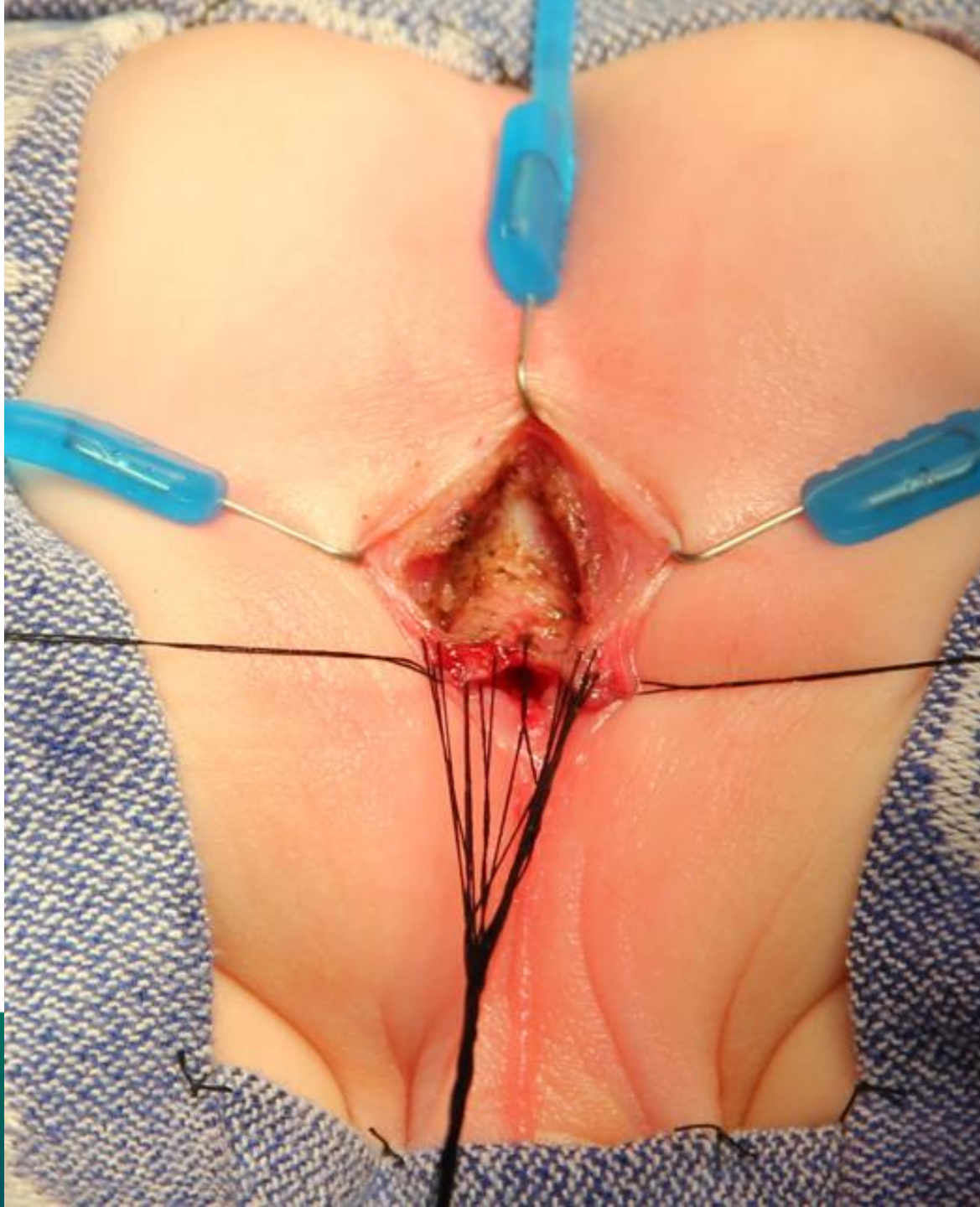




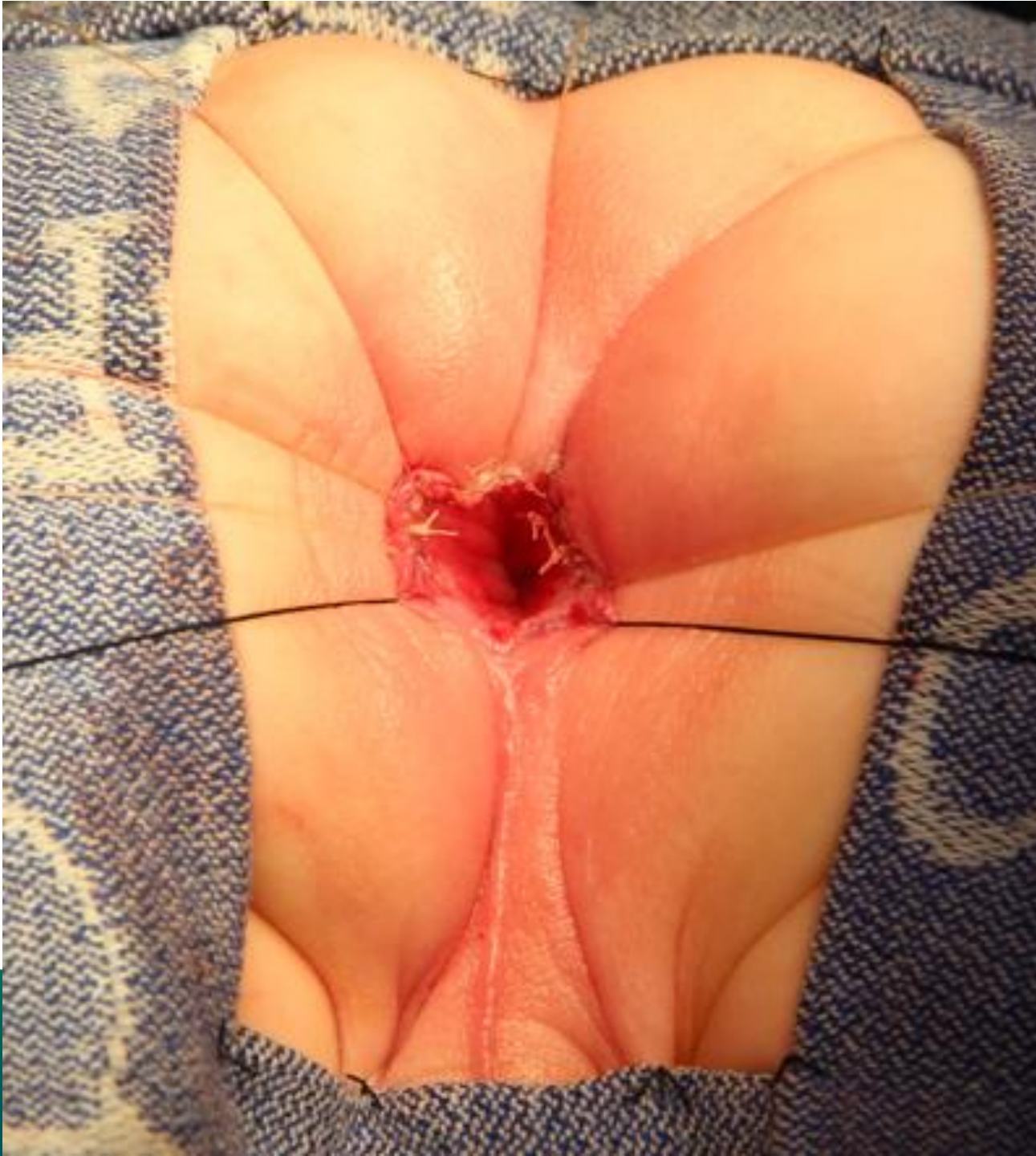
INTERNATIONAL CENTER FOR  
**COLORECTAL AND  
UROGENITAL CARE**



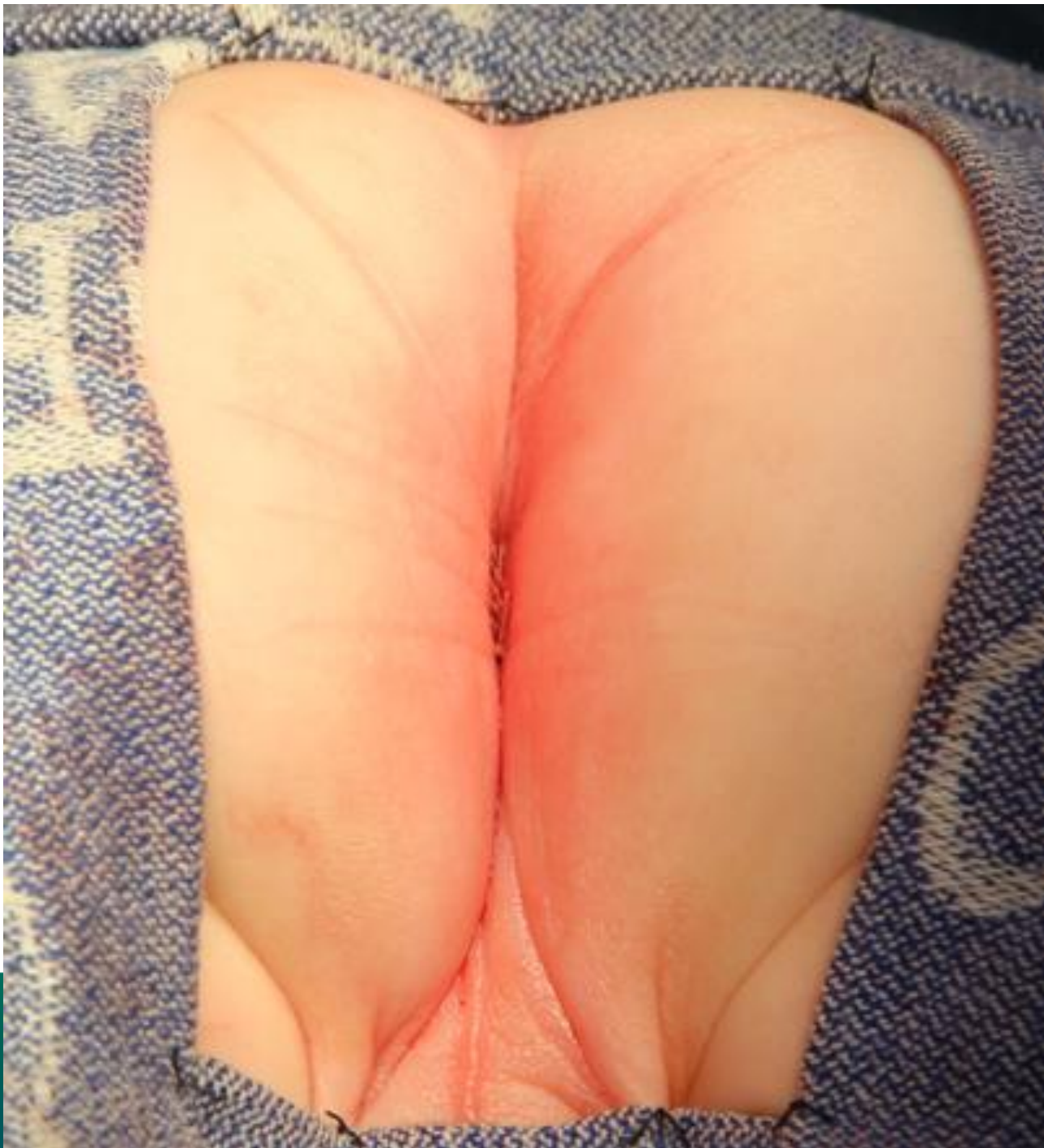




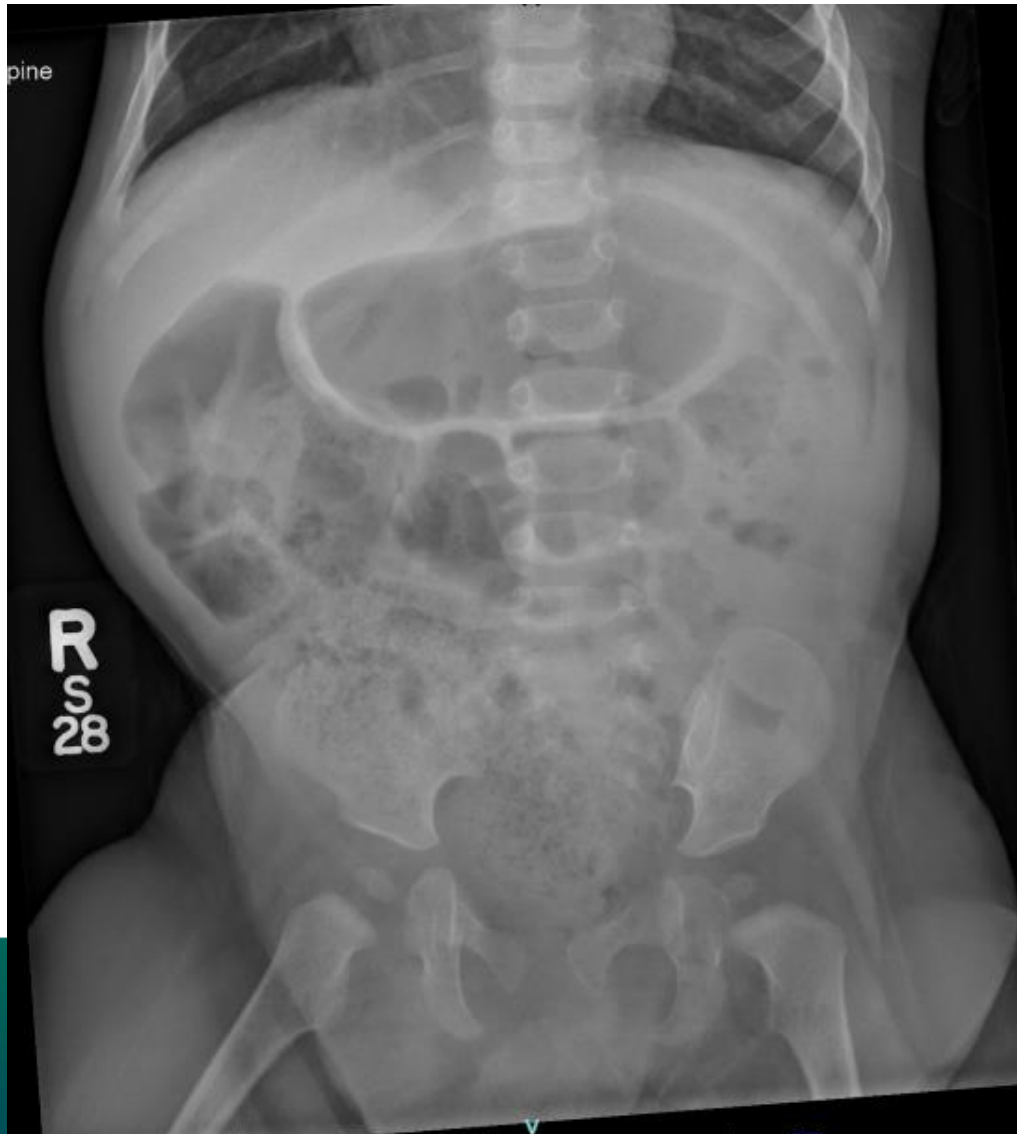






# Follow up 11 days after surgery



- Started anal dilations
- Pedialax given in clinic
- Started him on senna (8.6 mg) with the goal of daily bowel movement