

# Case #5

---

Andrea Bischoff

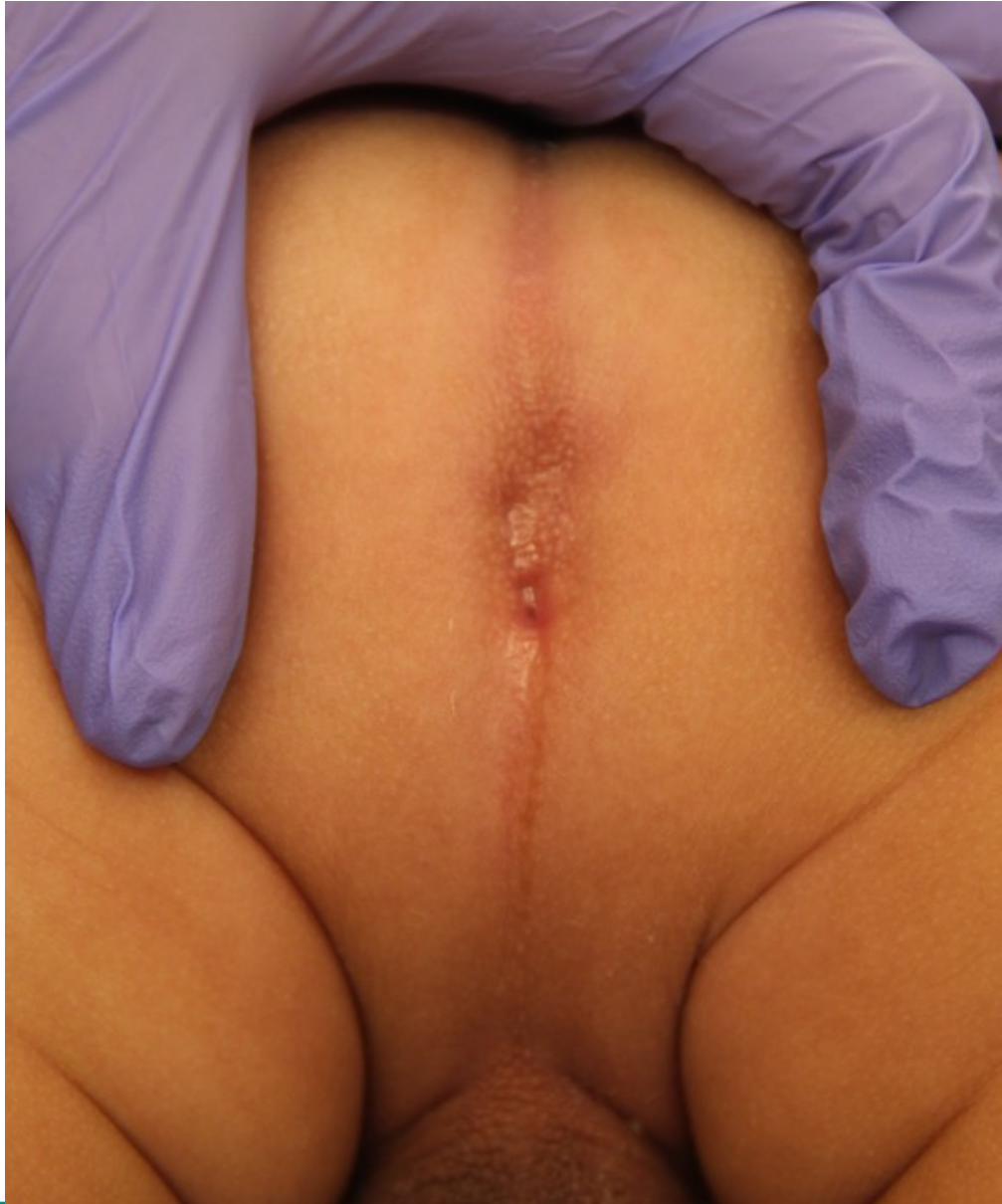

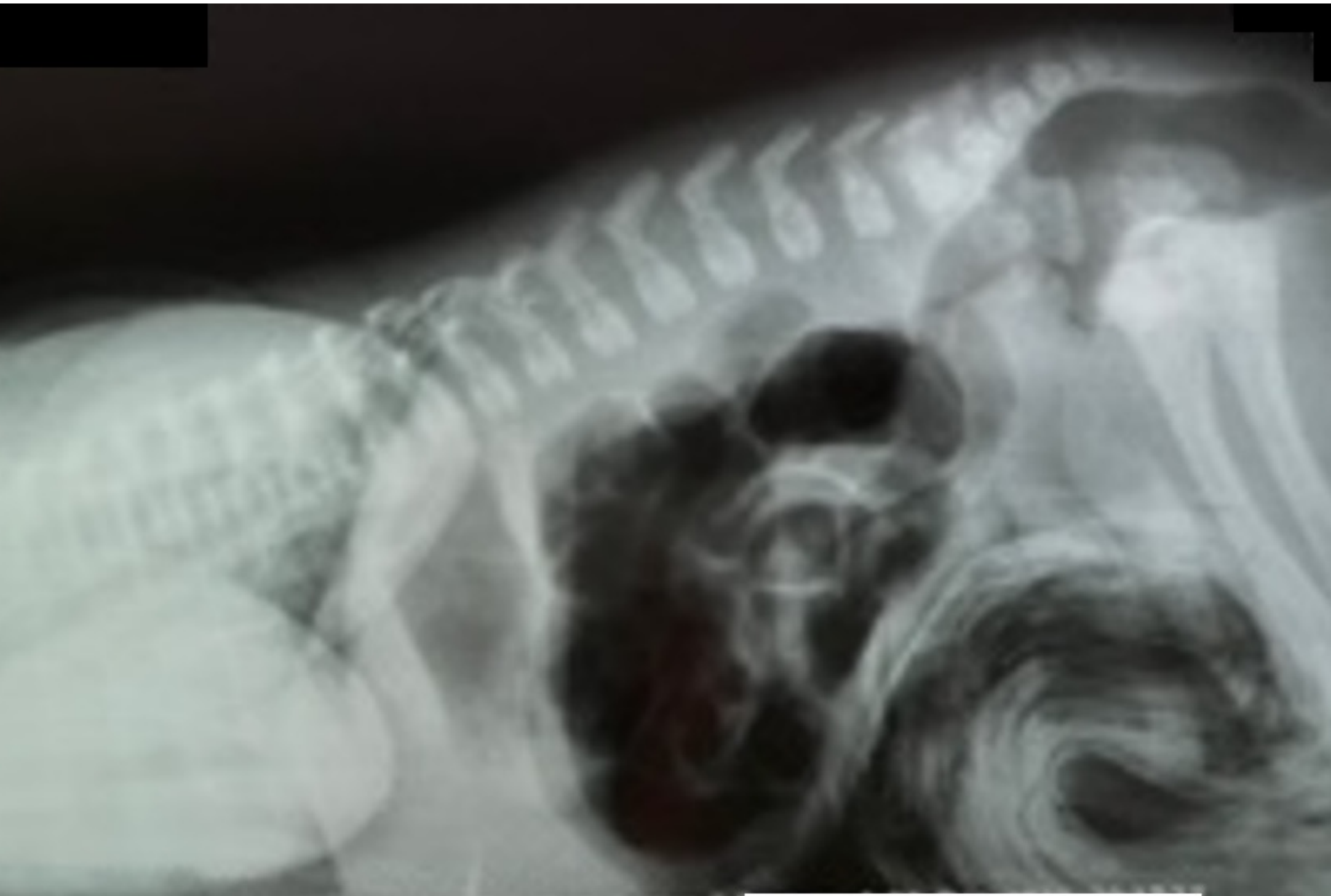
Children's Hospital Colorado

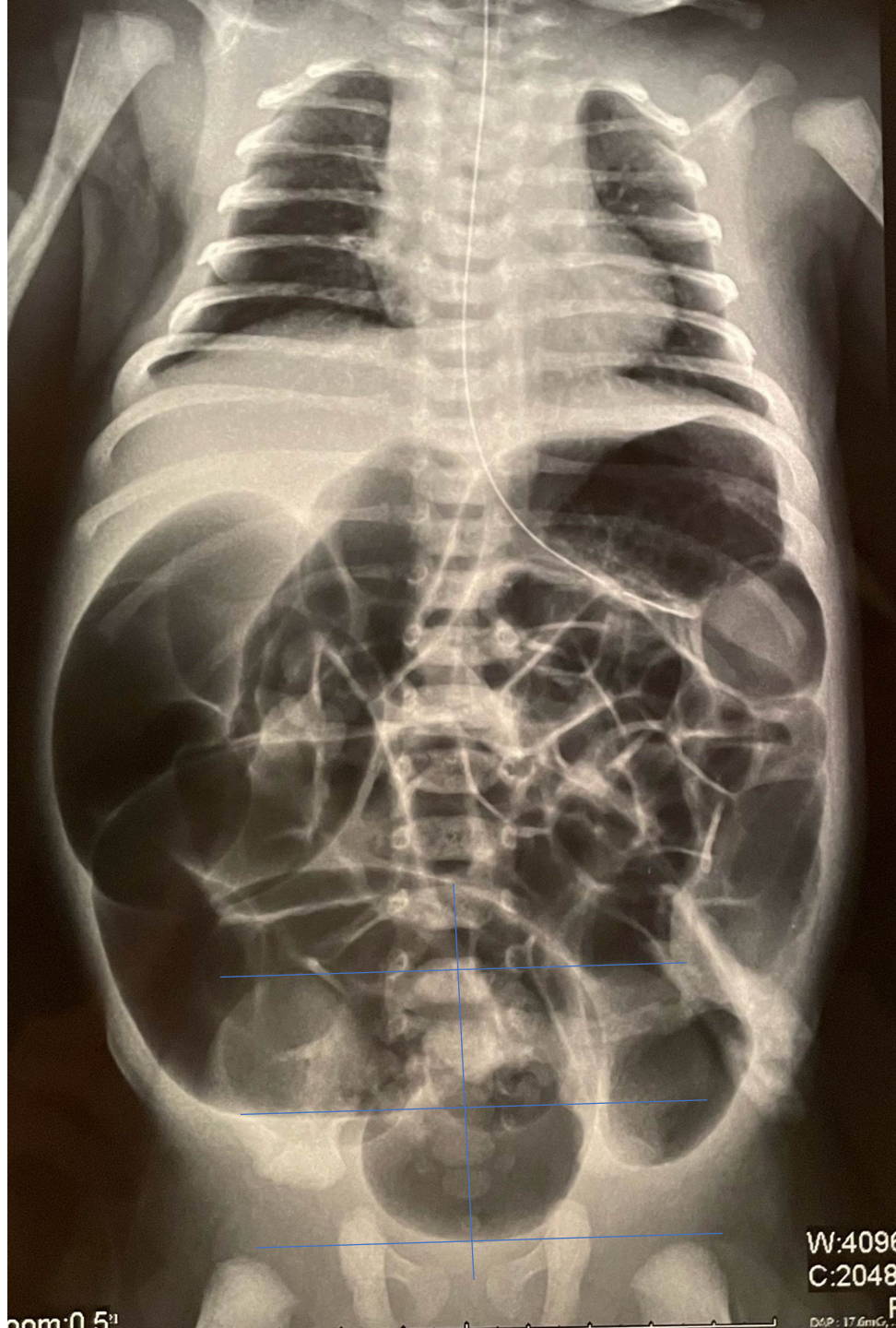
INTERNATIONAL CENTER FOR  
**COLORECTAL AND  
UROGENITAL CARE**

Newborn, male patient, what is the diagnosis?

1. Recto-perineal
2. Recto-urethral bulbar
3. Imperforate anus without fistula
4. I don' know







W:4096  
C:2048

nom:0.5"

DSP: 17.6mCr...

