



Complex Anorectal Malformation

Luis Mauricio Figueroa Gutiérrez, Andrés Felipe Marín Giraldo, Juan Felipe Osorno Moncayo, Jorge Alexander Solarte Henao

Universidad del Valle, Cali Colombia

- Female patient
- 10 years 8 months

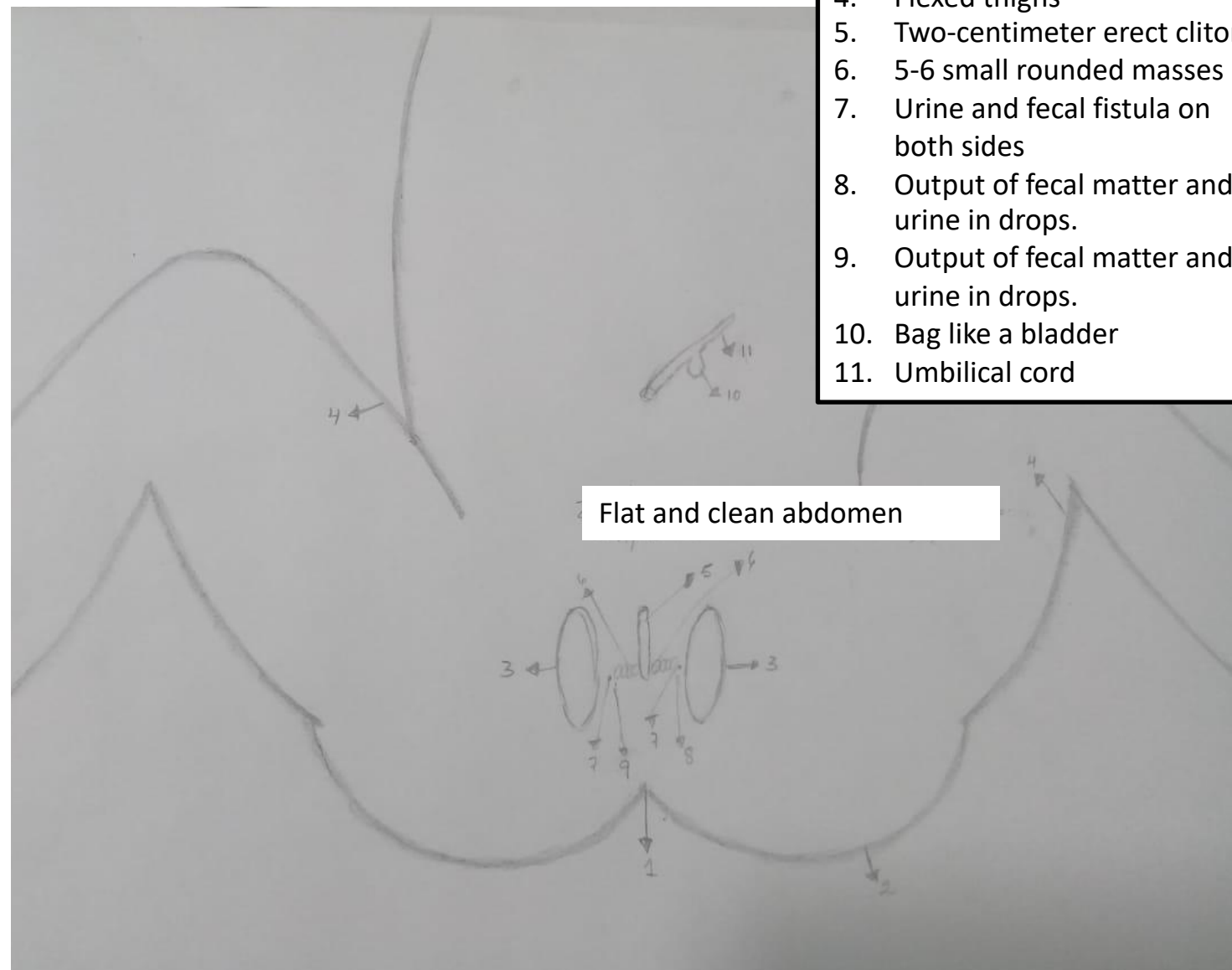


Drawing of the mother

At birth
(2009)

Postnatal surgery:
Colonic duplication,
bladder duplication,
vaginal duplication
Reconstruction:
anoplasty, bladder
duplication closure.

1. Imperforate anus
2. Nice rounded buttocks
3. Labia majora separated
4. Flexed thighs
5. Two-centimeter erect clitoris
6. 5-6 small rounded masses
7. Urine and fecal fistula on both sides
8. Output of fecal matter and urine in drops.
9. Output of fecal matter and urine in drops.
10. Bag like a bladder
11. Umbilical cord



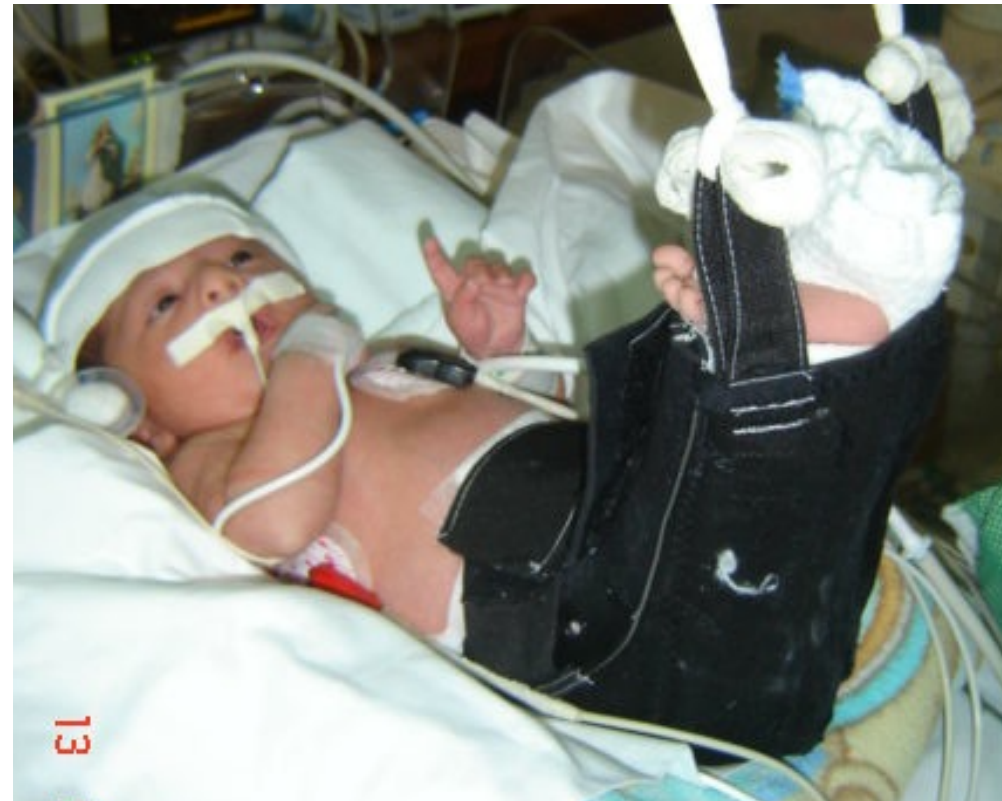
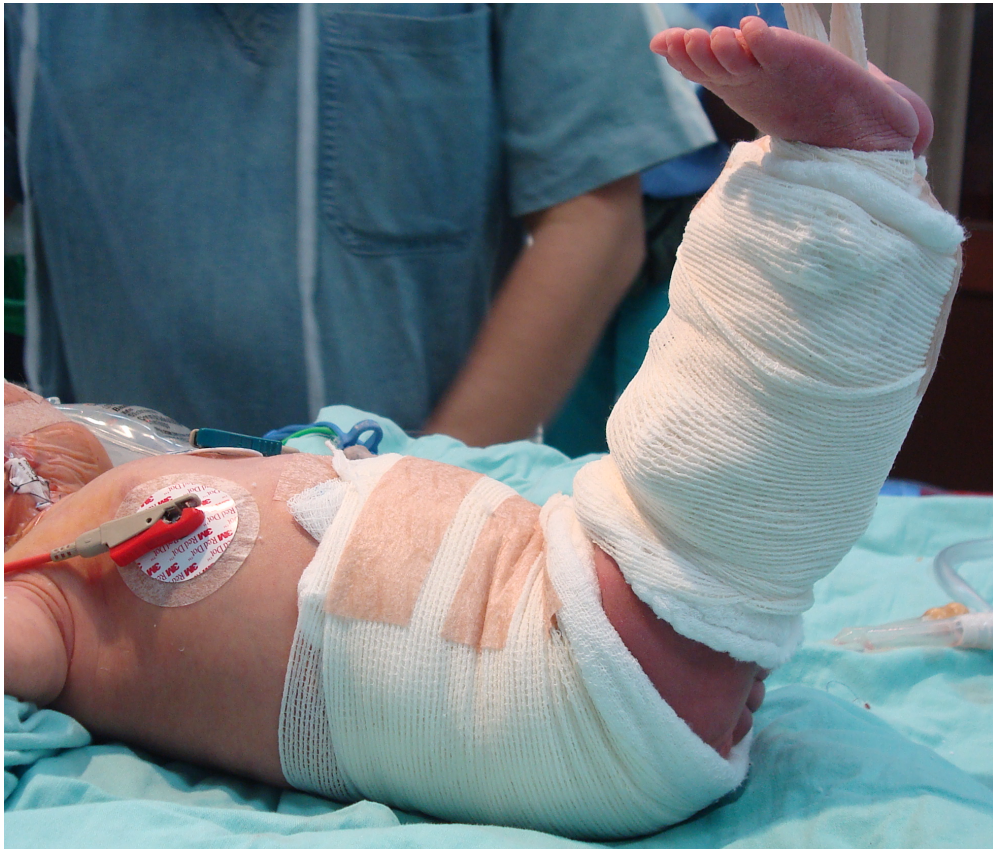
What is her possible anomaly?

1. Complex Anorectal malformation
2. Cloaca
3. Cloacal exstrophy: Omphalocele, Exstrophy, Imperforated anus and Spinal defects (OEIS)
4. Covered Cloacal exstrophy
5. Bladder Exstrophy-Epispadias-Cloacal Exstrophy Complex (BEEC)
6. I don't know

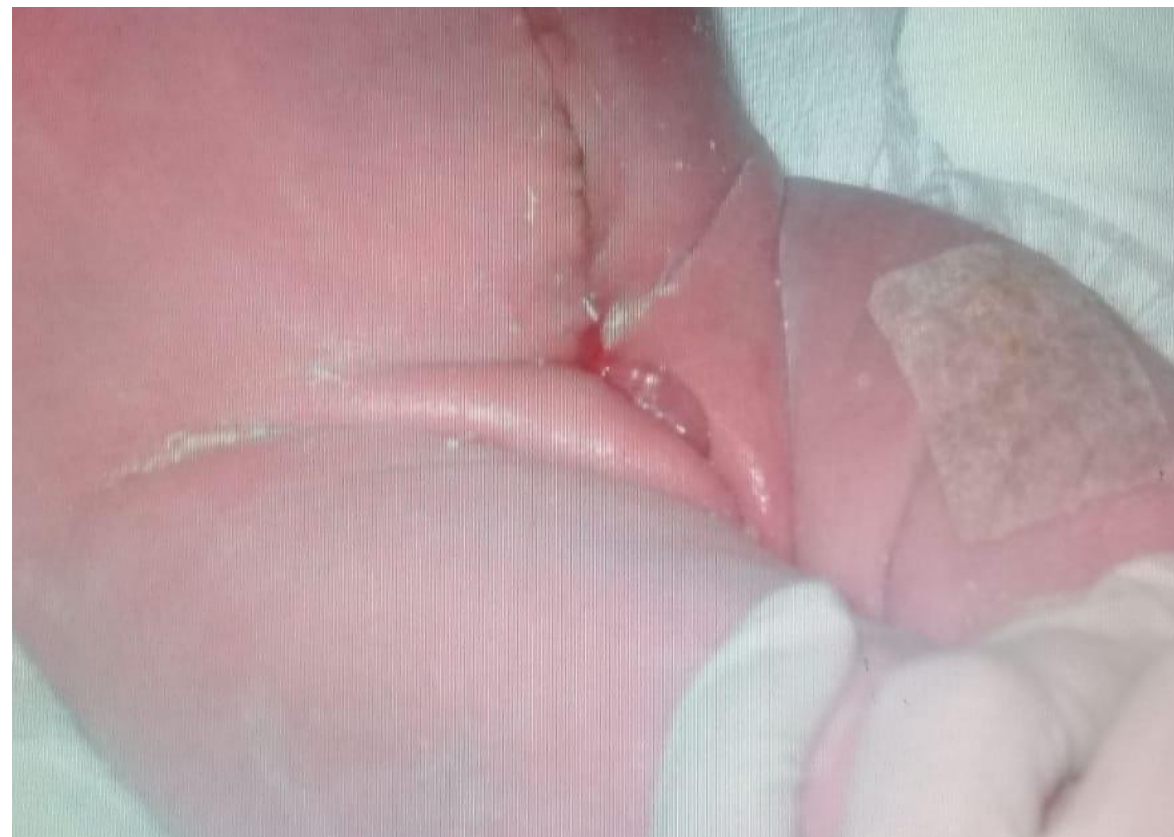
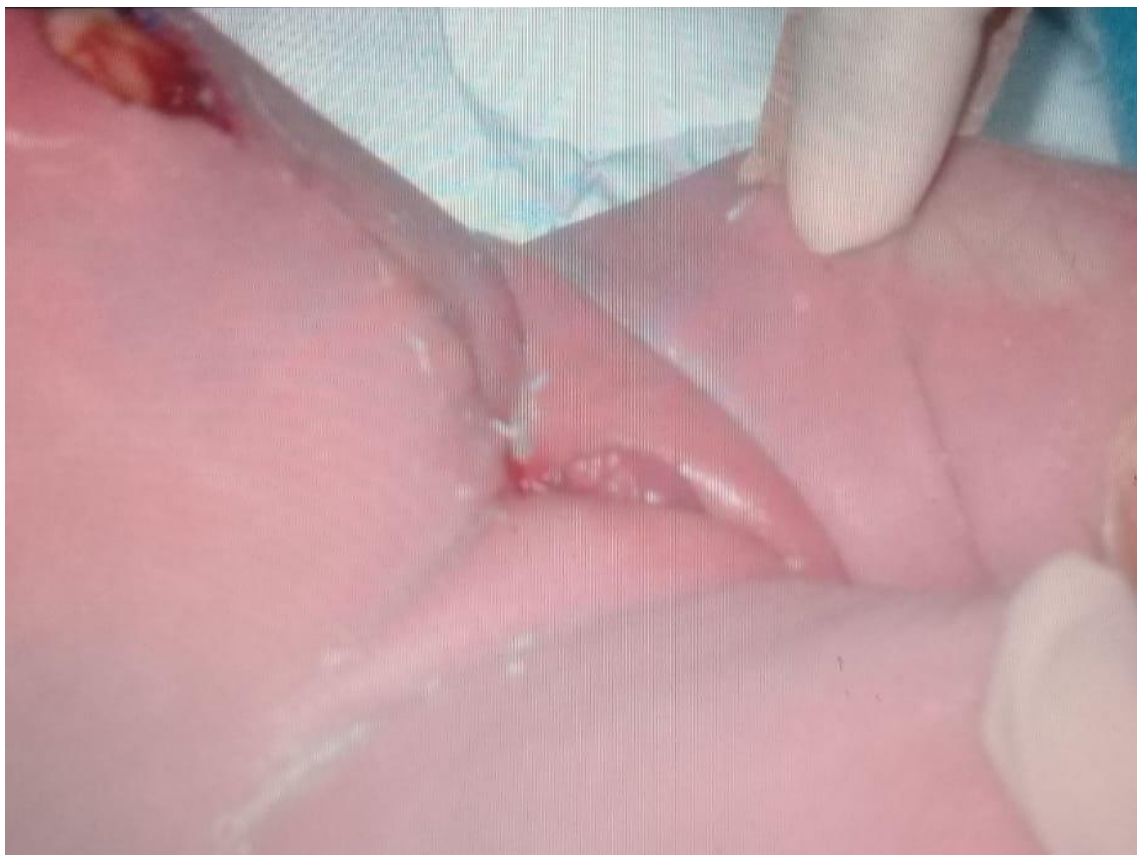
Immobilization for 4 weeks





Post-operative result

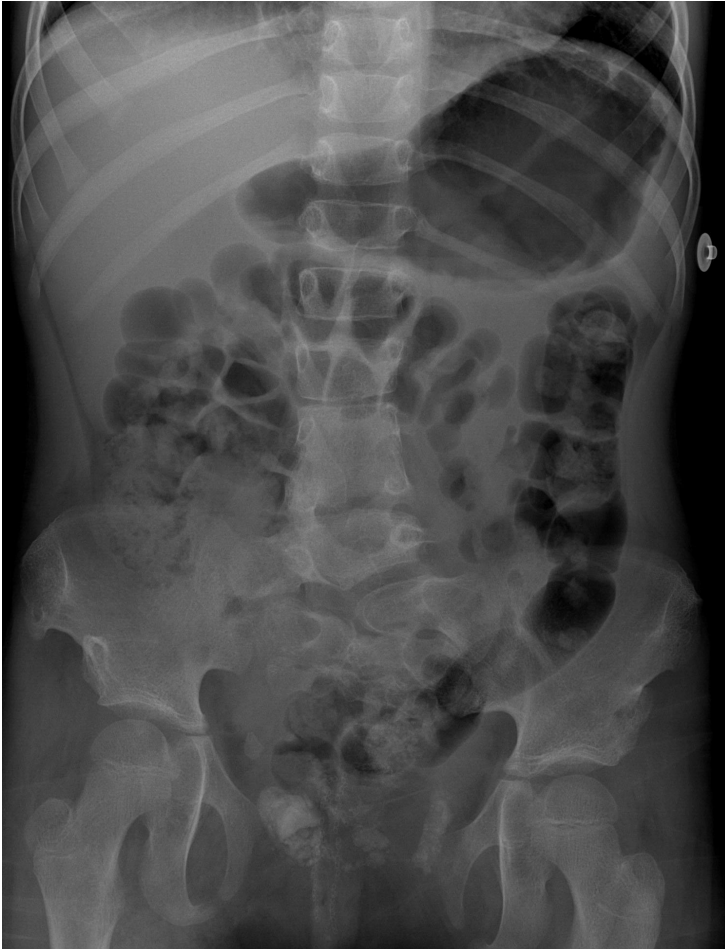




At 5 months old: Rectal prolapse repair and Urethroplasty

At 9 months old: Ileostomy closure

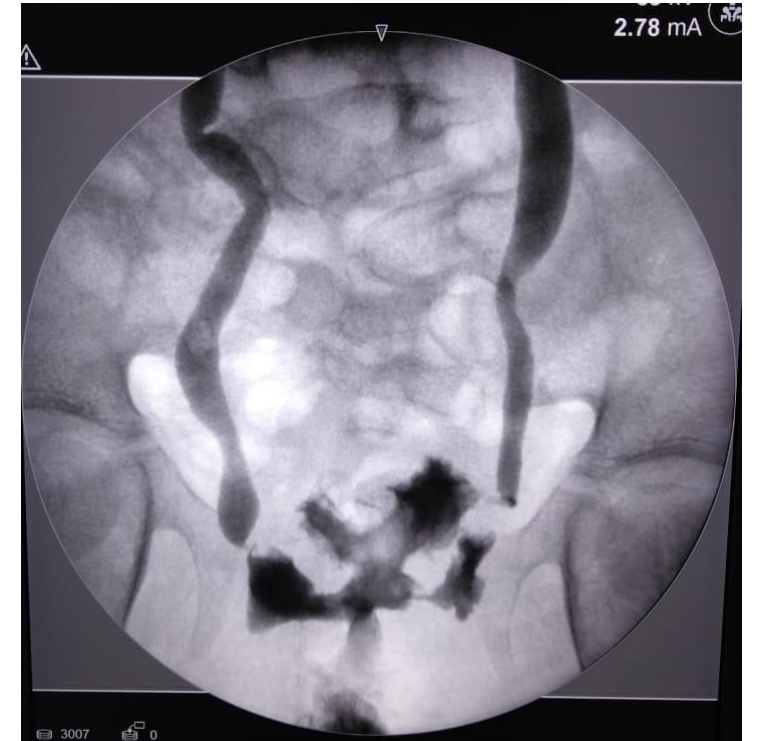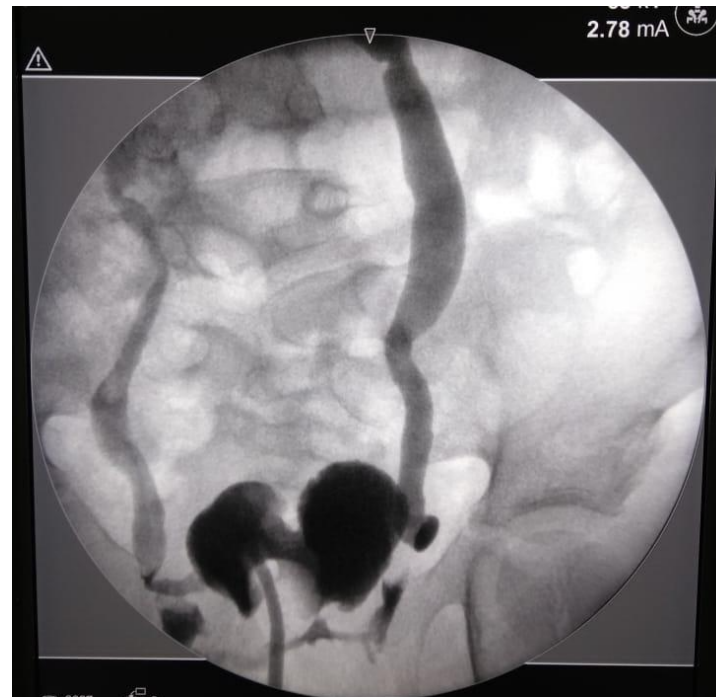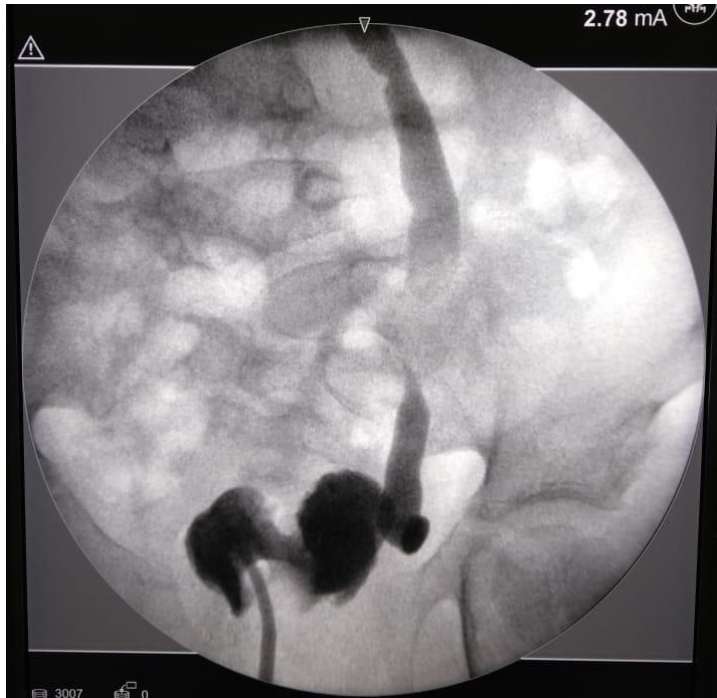At 5 years old: Osteotomy, external tutor,
urethroplasty, vaginoplasty



Which
anormalities
do you see at
the image?

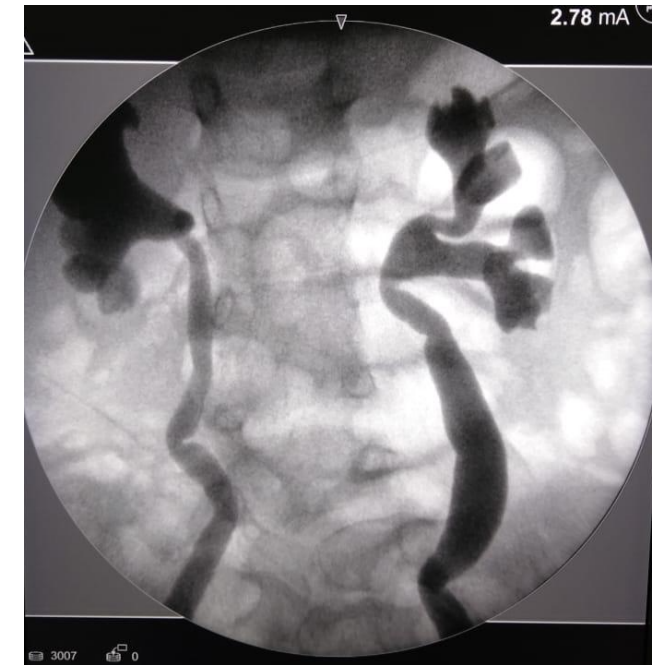
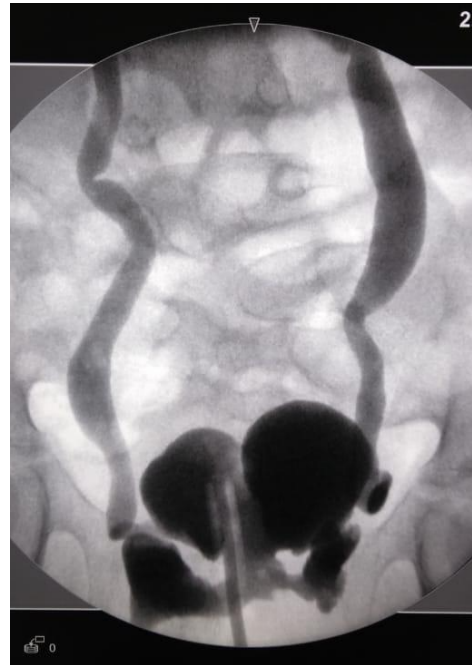
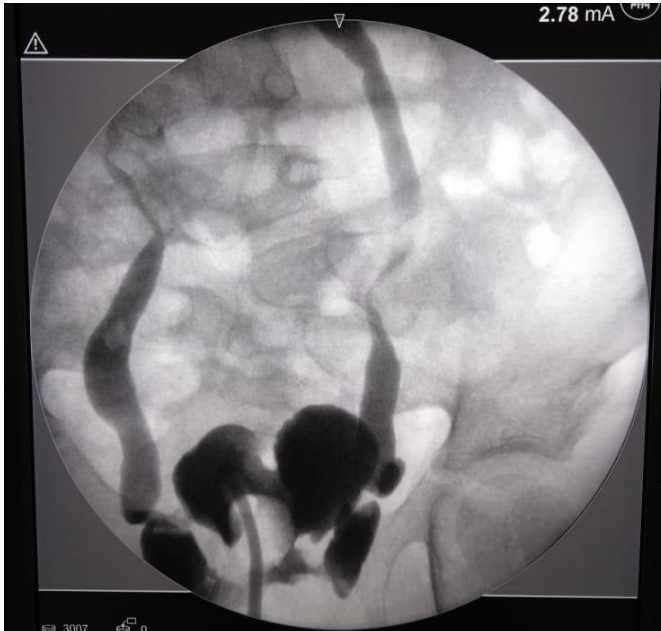2018: Cystoscopy and Cystography



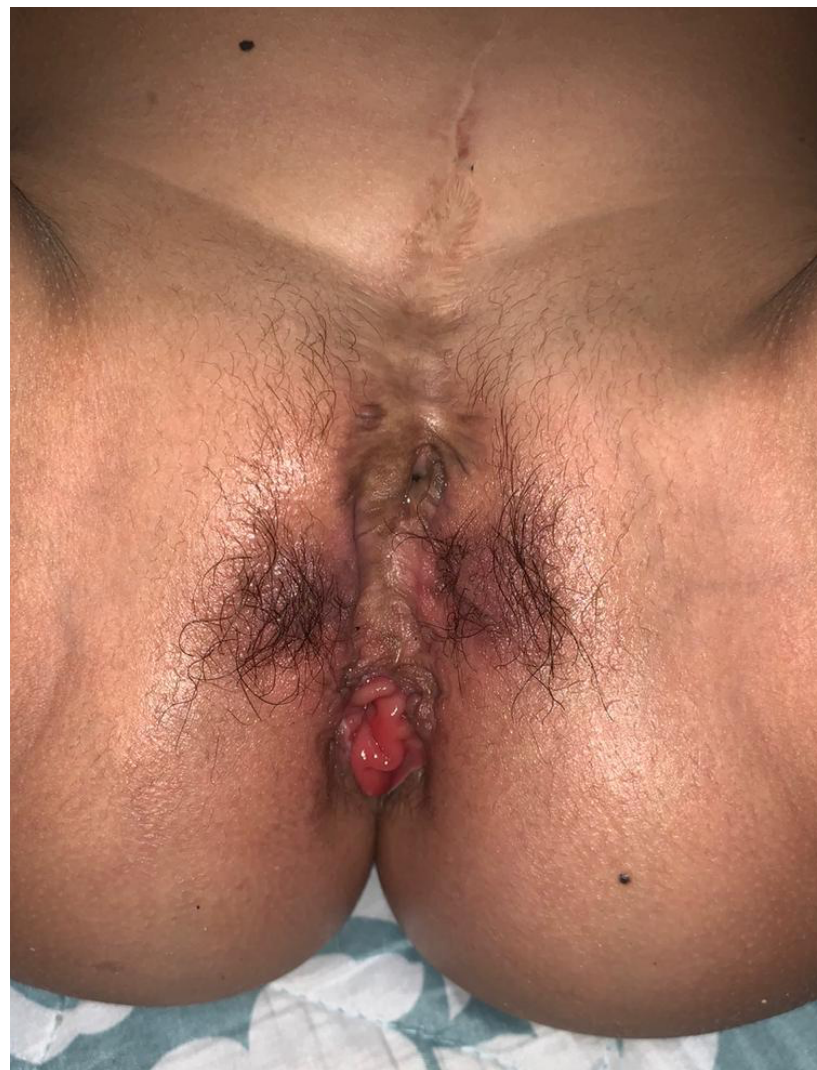
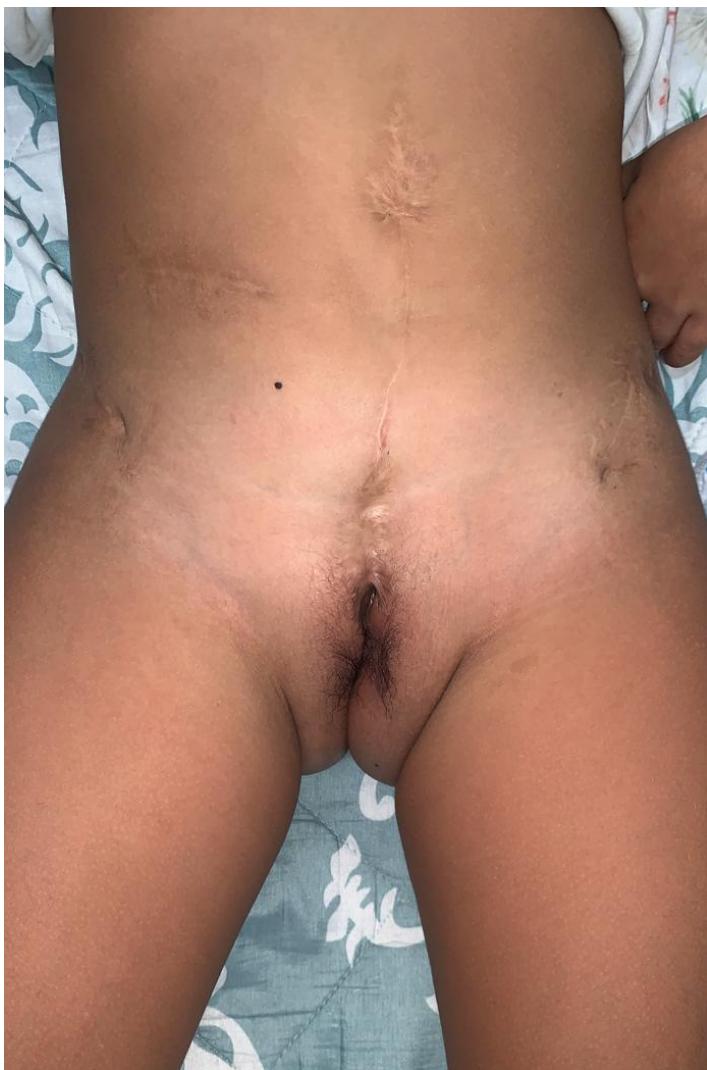
Cystoscopy and Cystography: Bladder and vagina with stones, small septum between bladder and two vaginas with cervix seen in each hemi-vagina, bilateral VUR grade four



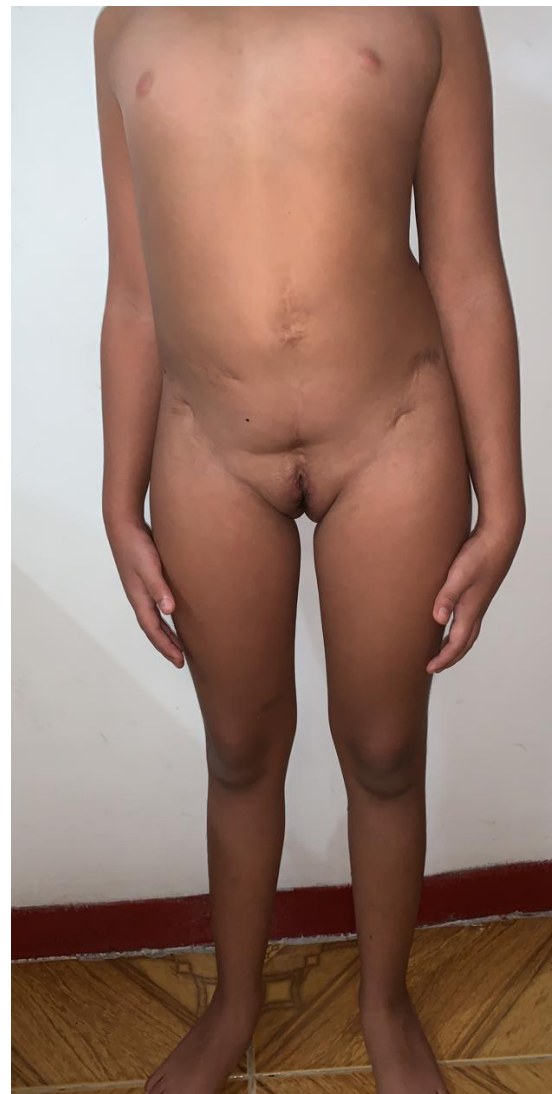

May 16 2020





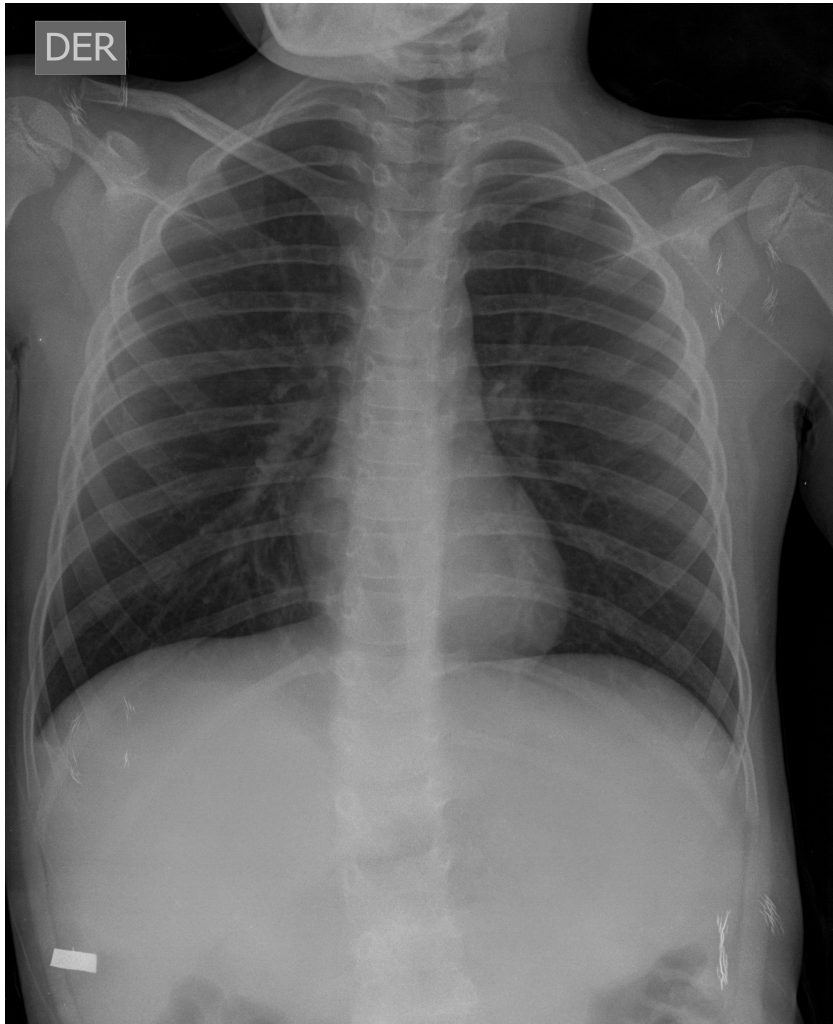
2020



Fecal continent
Urinary incontinent
Tethered cord
Hidden dysraphism
Bilateral VUR (IV)
Bladder and vaginal
communication



May 2020



Which abnormalities
do you see at the
image?



What procedure would you propose for reconstruction?

- a. Bladder augmentation and Mitrofanoff?
- b. Anorectoplasty and Malone procedure?
- c. Bladder augmentation, Mitrofanoff, bladder neck closure, bilateral ureteral reimplantation and Vaginoplasty?
- d. I don't know