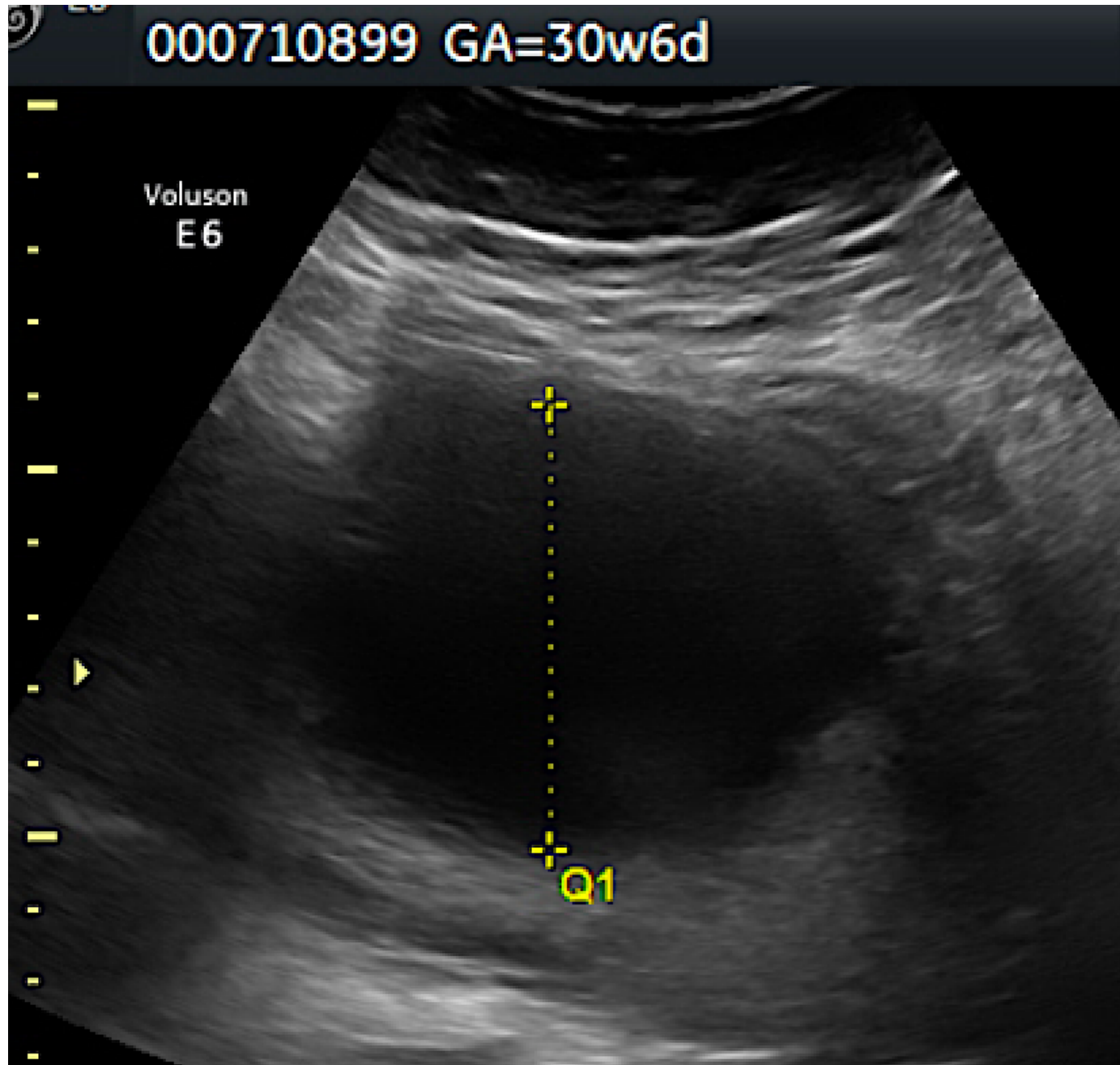




28-year-old pregnant woman at 30-weeks gestational age. She is in your clinic because on prenatal ultrasound an abdominal tumor was seen in the fetus.

Fetal ultrasound of a female @ 30 weeks gestational age





With this image of the prenatal ultrasound, what is your diagnosis?

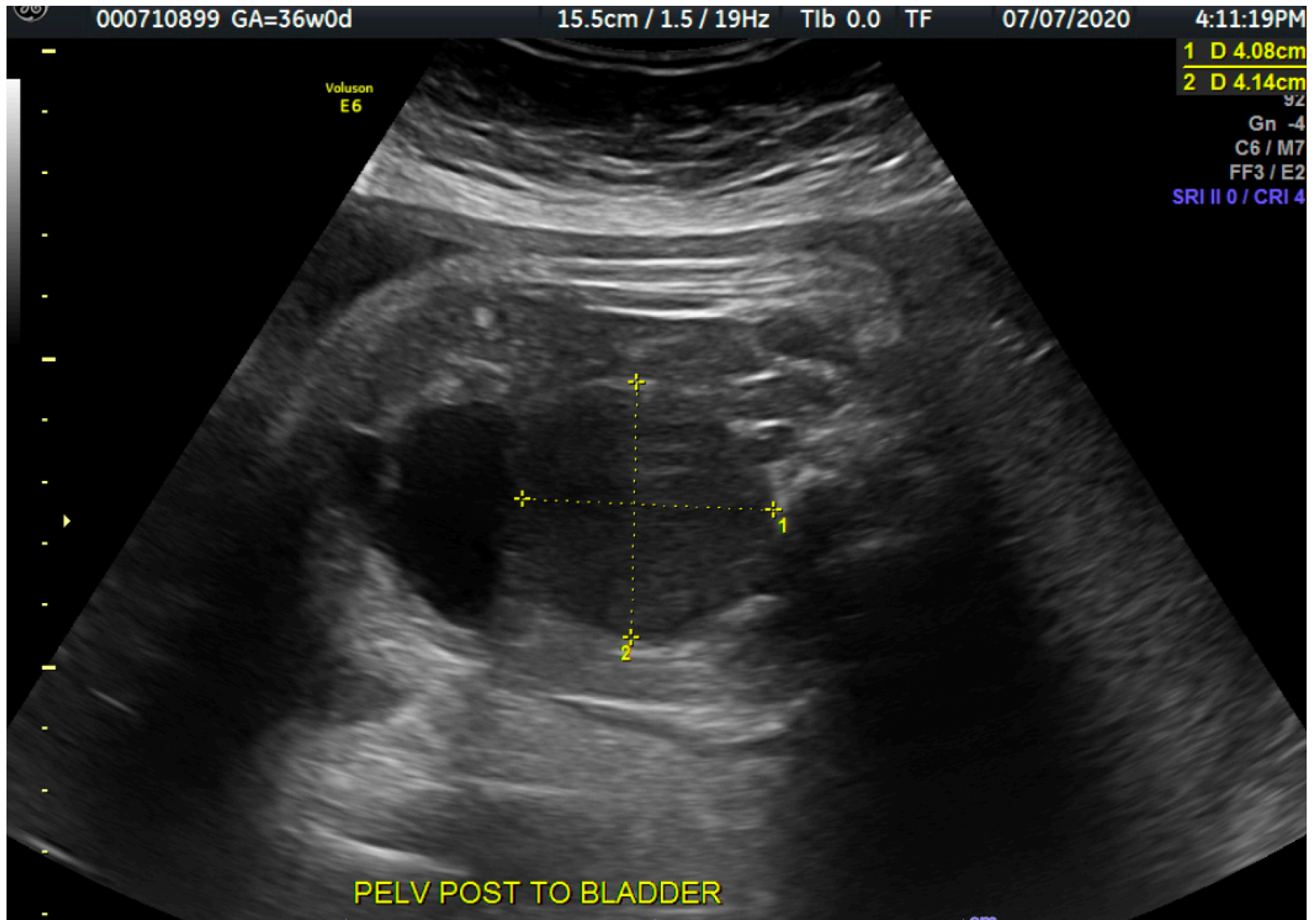
- a) Ovarian cyst
- b) Mesenteric cyst
- c) Hydrocolpos
- d) Ascites
- e) Cloaca
- f) I don't know

Parents want your advice and are asking what to do...



- a) Fetal surgery
- b) Stop the pregnancy
- c) Repeat the ultrasound in 6 weeks
- d) Drainage
- e) I do not know

Fetal ultrasound of a female @ 36 weeks gestation age





With this image of the prenatal ultrasound, what is your diagnosis?

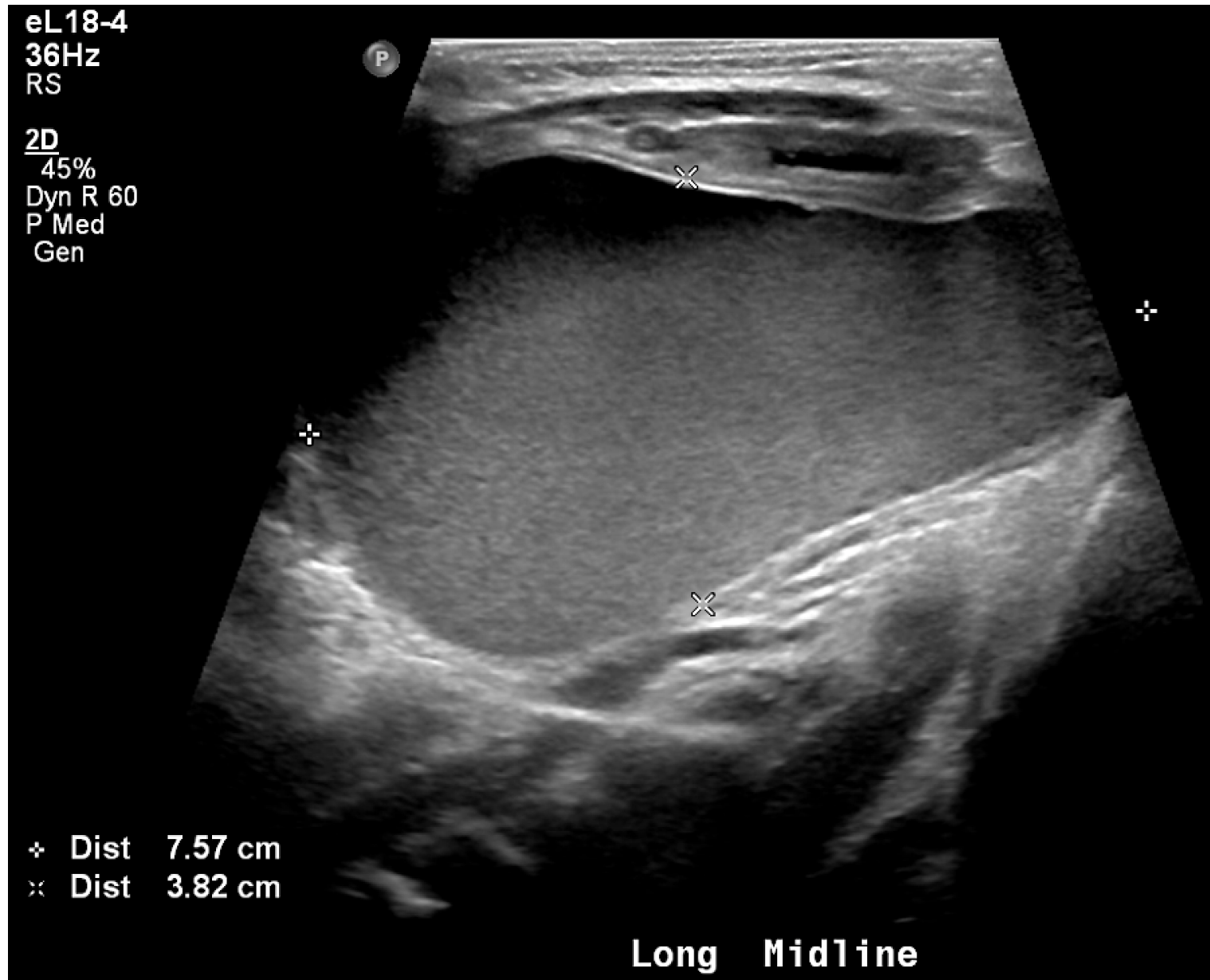- a) Ovarian cyst
- b) Hydronephrosis
- c) Hydrocolpos
- d) Ascites
- e) Cloaca



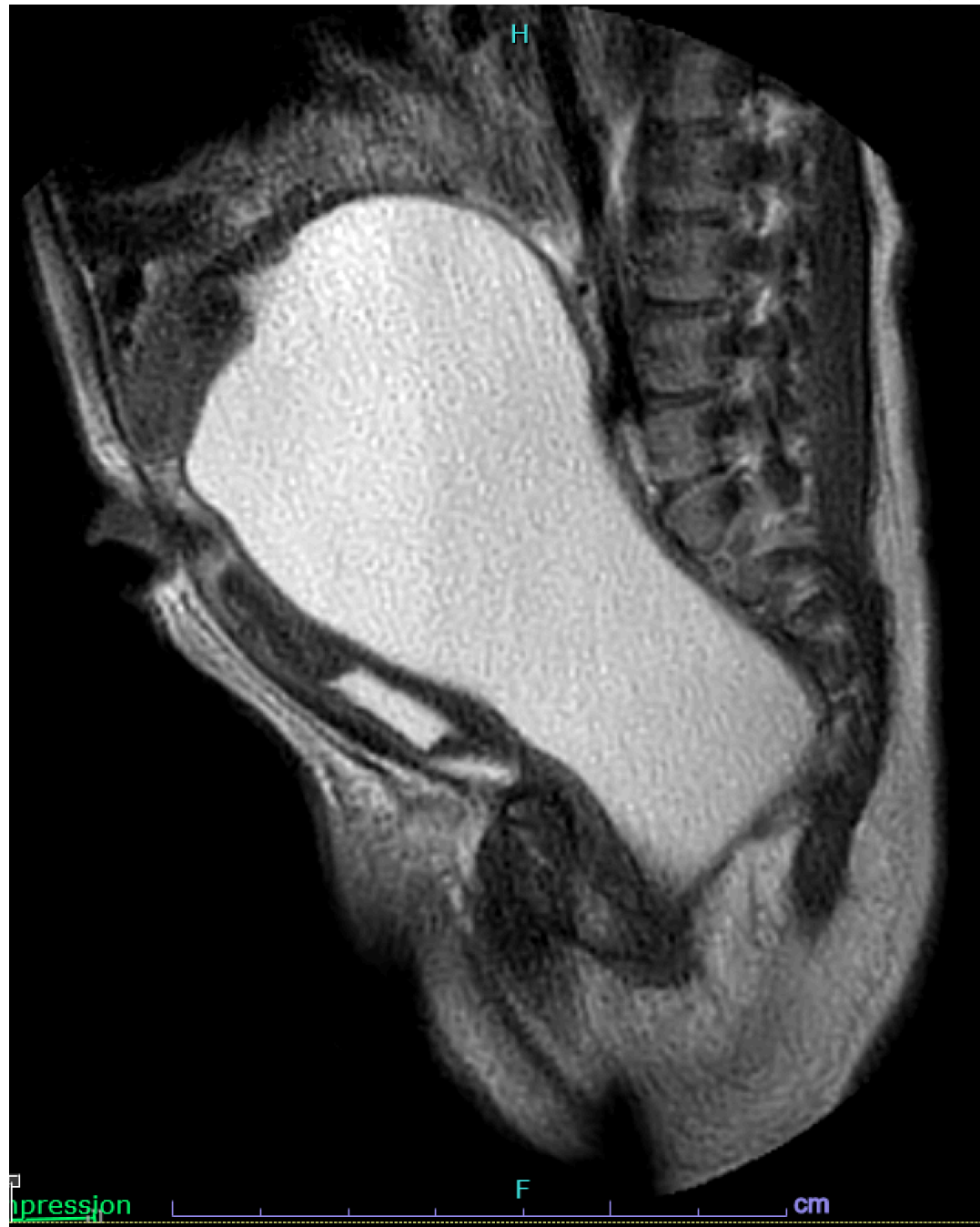The parents want your advice and are asking what to do...

- a) Fetal surgery
- b) Stop the pregnancy
- c) Request an MRI
- d) Drainage
- e) I do not know

Abdominal ultrasound of a female @ 2 day of age



CT scan of a female @ 2 day of age



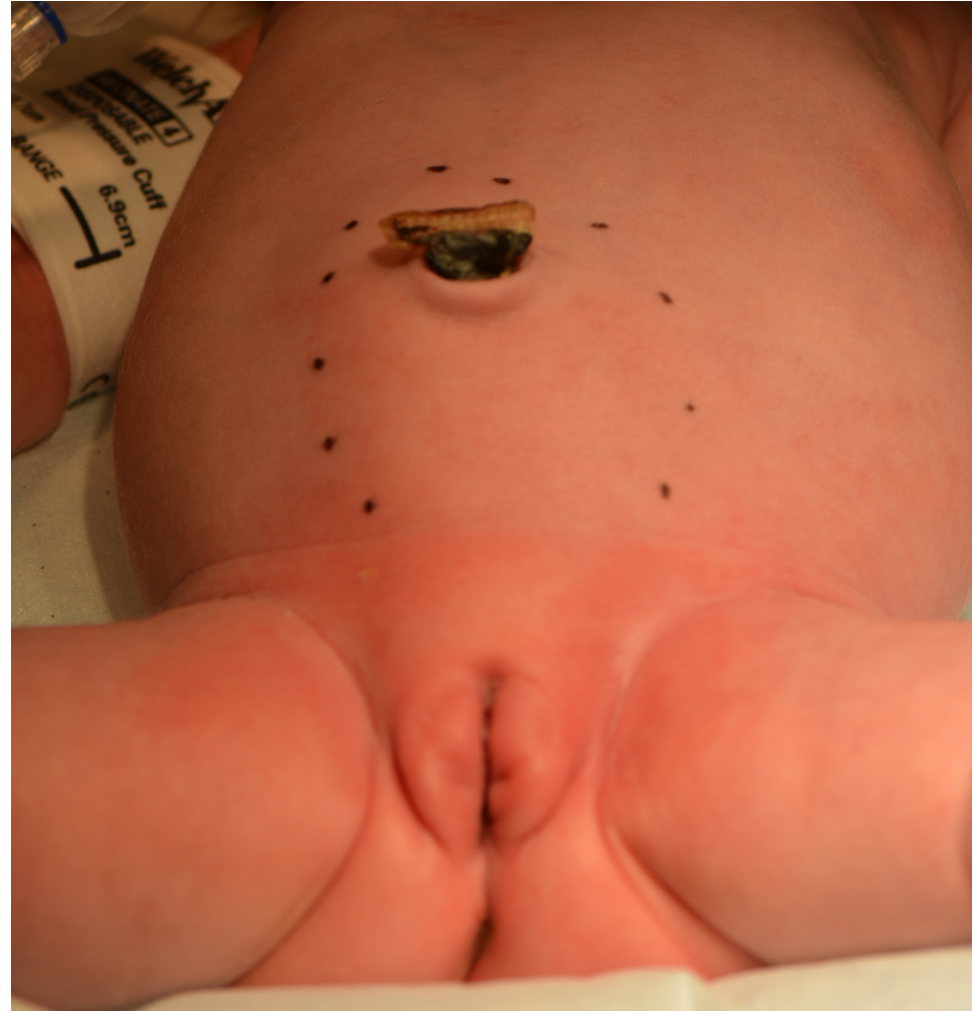

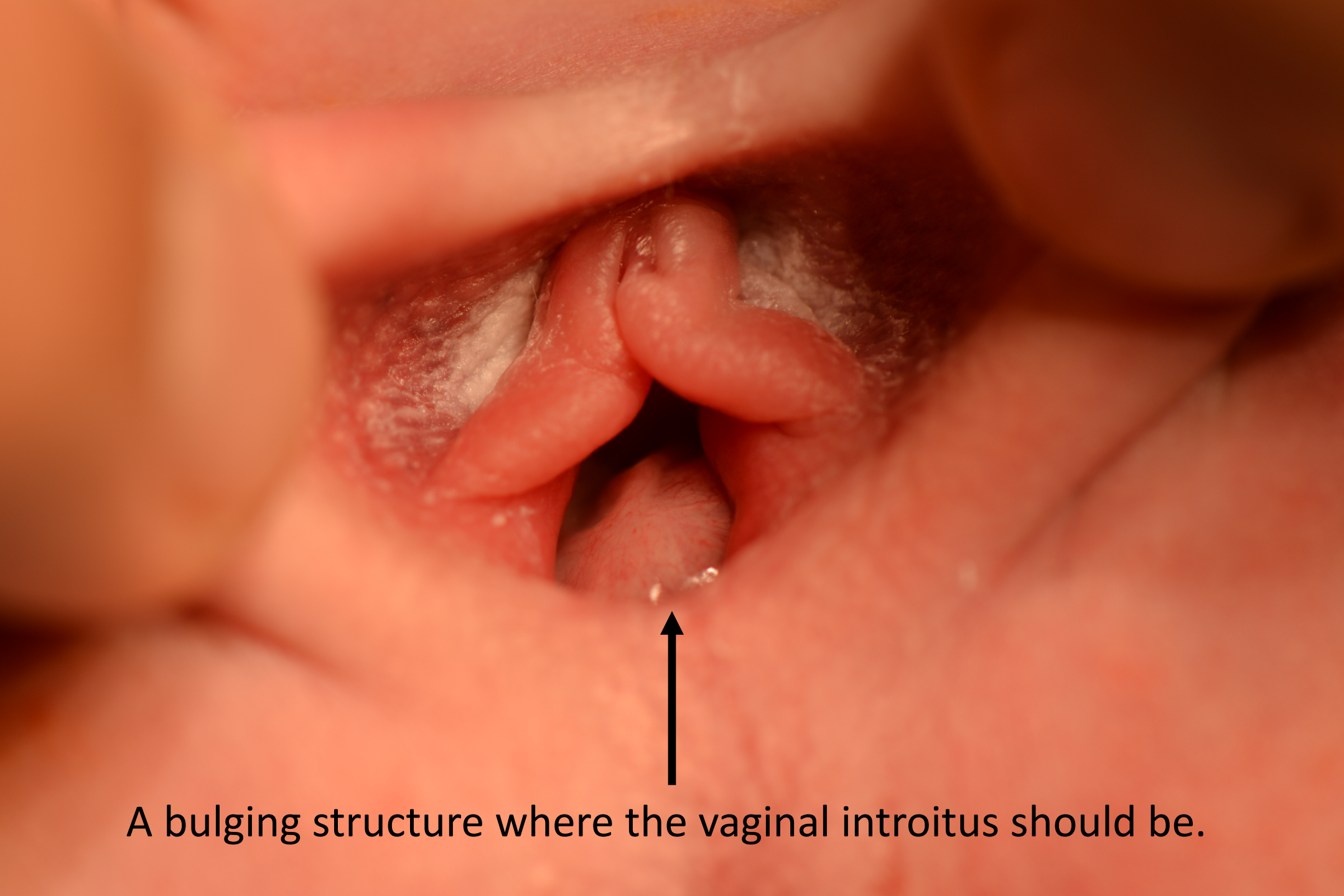
With these images, what would be your clinical evaluation?

- a) Corroborate the permeability of the anus
- b) Corroborate the permeability of the urethra
- c) Exploratory laparotomy
- d) Thorough examination of the vulva
- e) I do not know

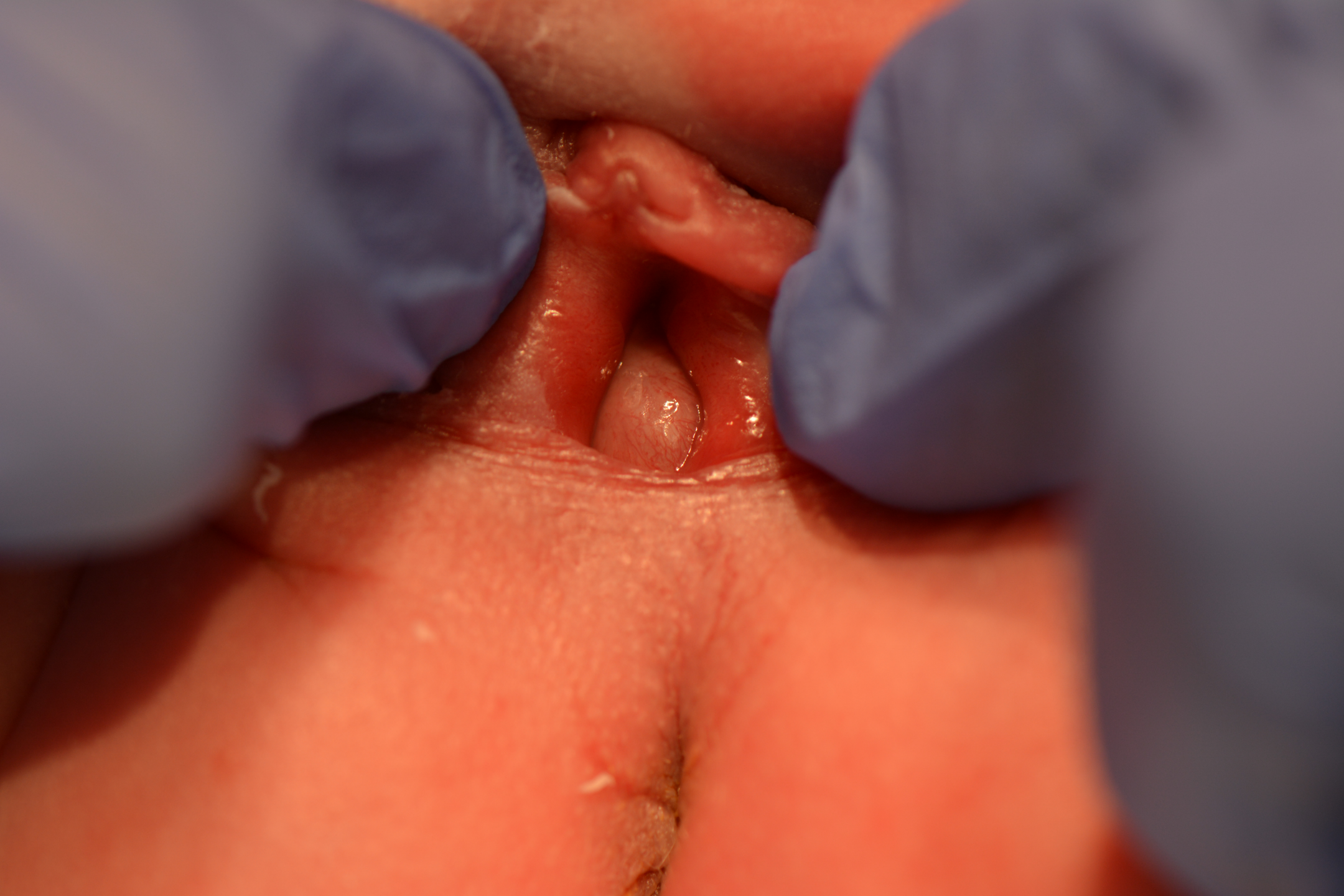The clinical evaluation demonstrated

- a) Normal anus
- b) Normal urethra
- c) Abdominal mass





A bulging structure where the vaginal introitus should be.





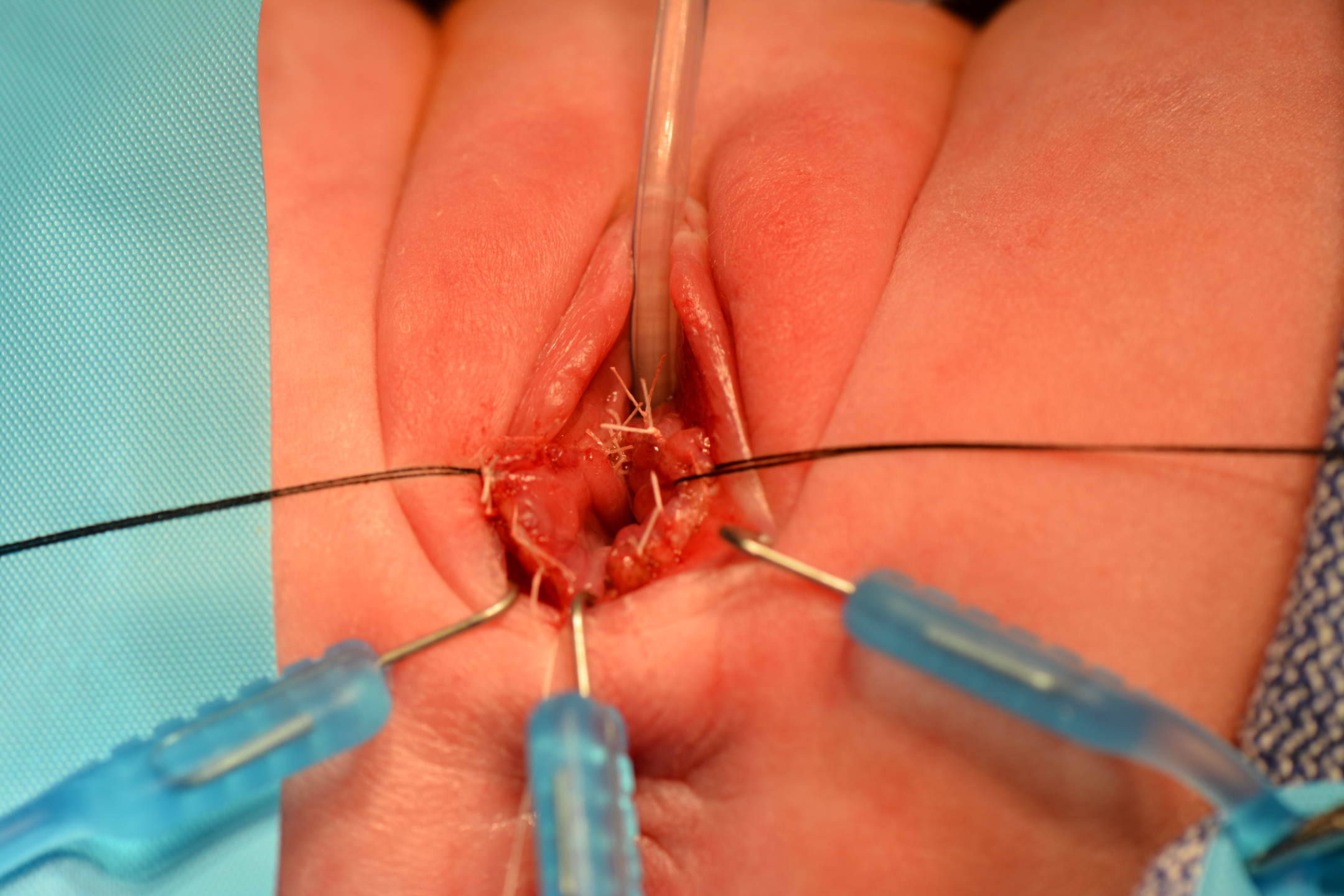
With these findings, what is your diagnosis?

- a) Low transverse vaginal septum/Imperforate hymen
- b) Hydrocolpos
- c) Cloaca
- d) b and c



With this diagnosis, what would be your plan?

- a) Place a drain with interventional radiology
- b) Laparoscopic drainage
- c) Open drainage with laparotomy
- d) Perineal exploration with vaginal mobilization vs. introitoplasty
- e) Vaginal replacement





Ameh EA, Mshelbwala MP, Ameh N. Congenital Vaginal Obstruction in Neonates and Infants: Recognition and Management. **J Pediatr Adolesc Gynecol 24 (2011) 74-78.**

Bischoff A, Alaniz V, Trecartin A, Peña A. Vaginal reconstruction for distal vaginal atresia without anorectal malformation: is the approach different? **Ped Surg Int 35 (2019) 963-966.**