



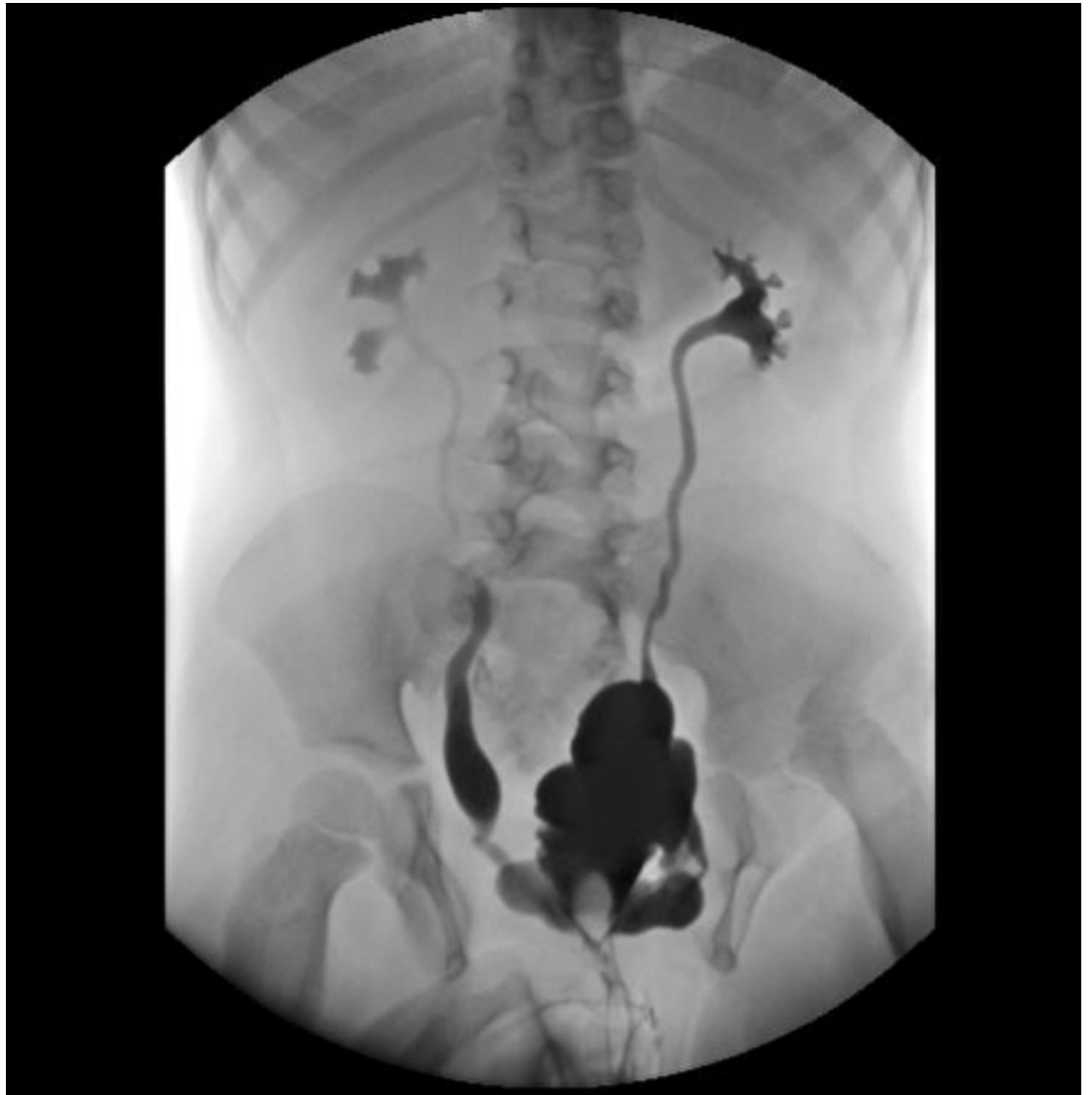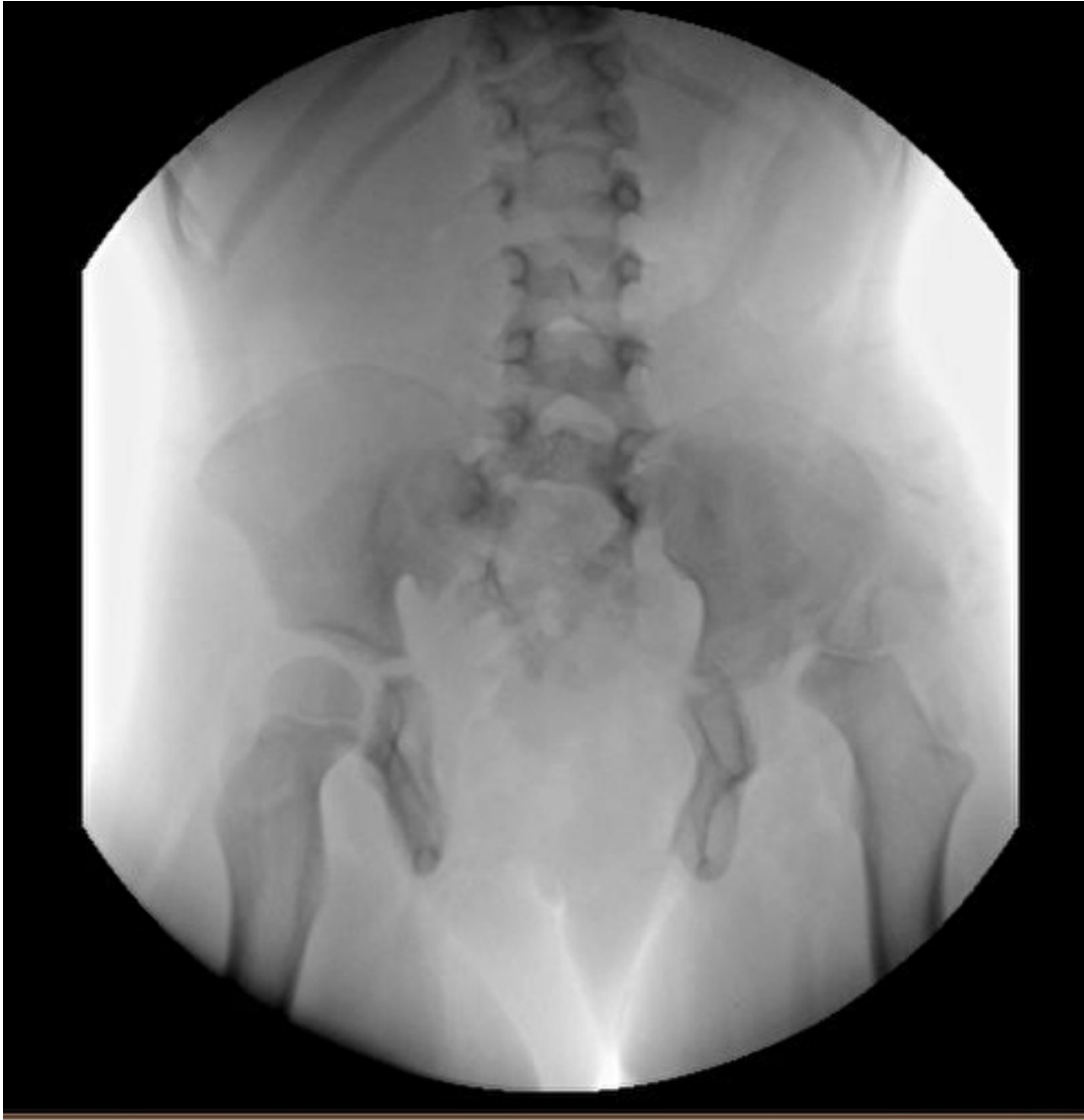COLORECTAL WEB MEETING

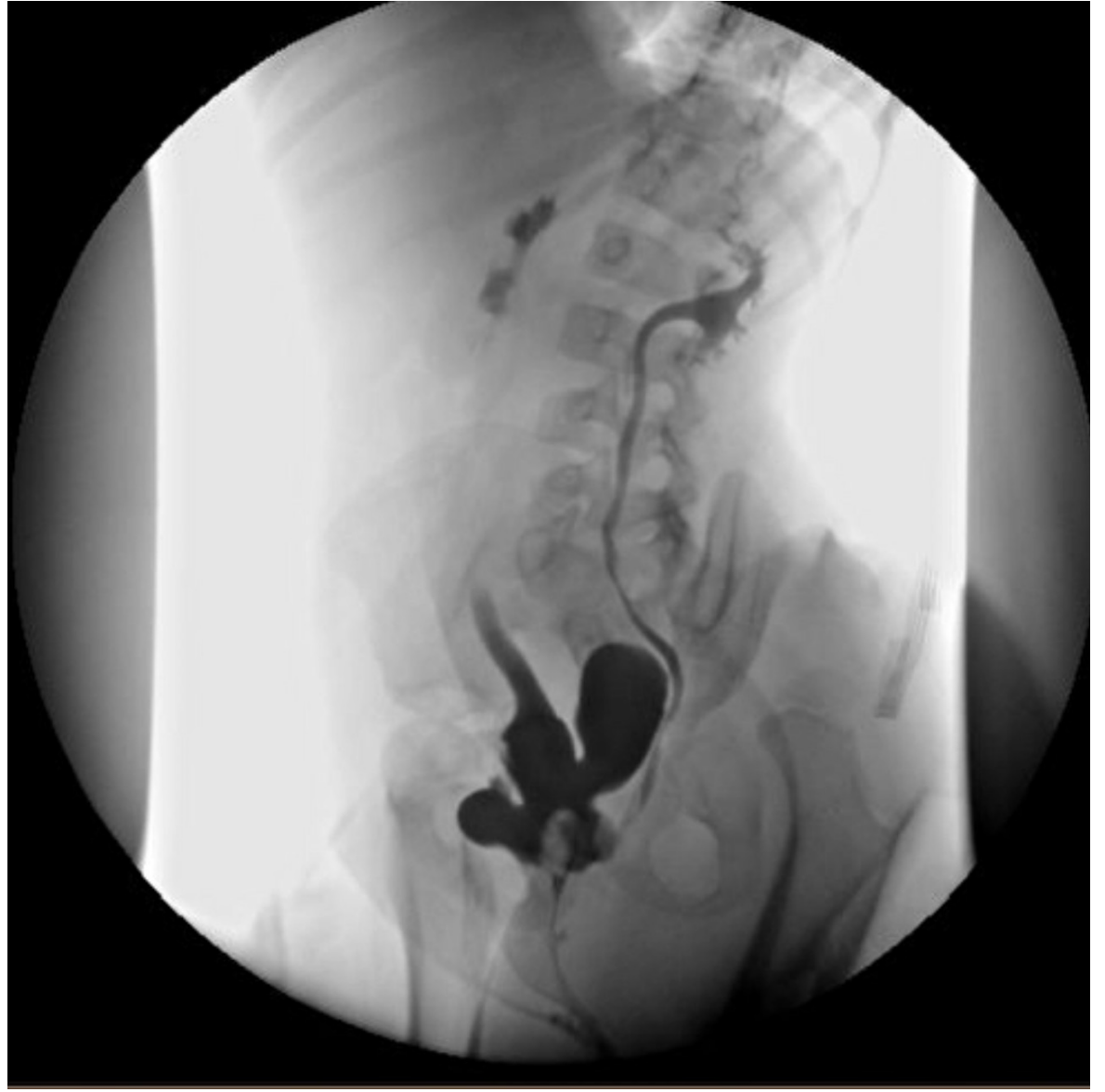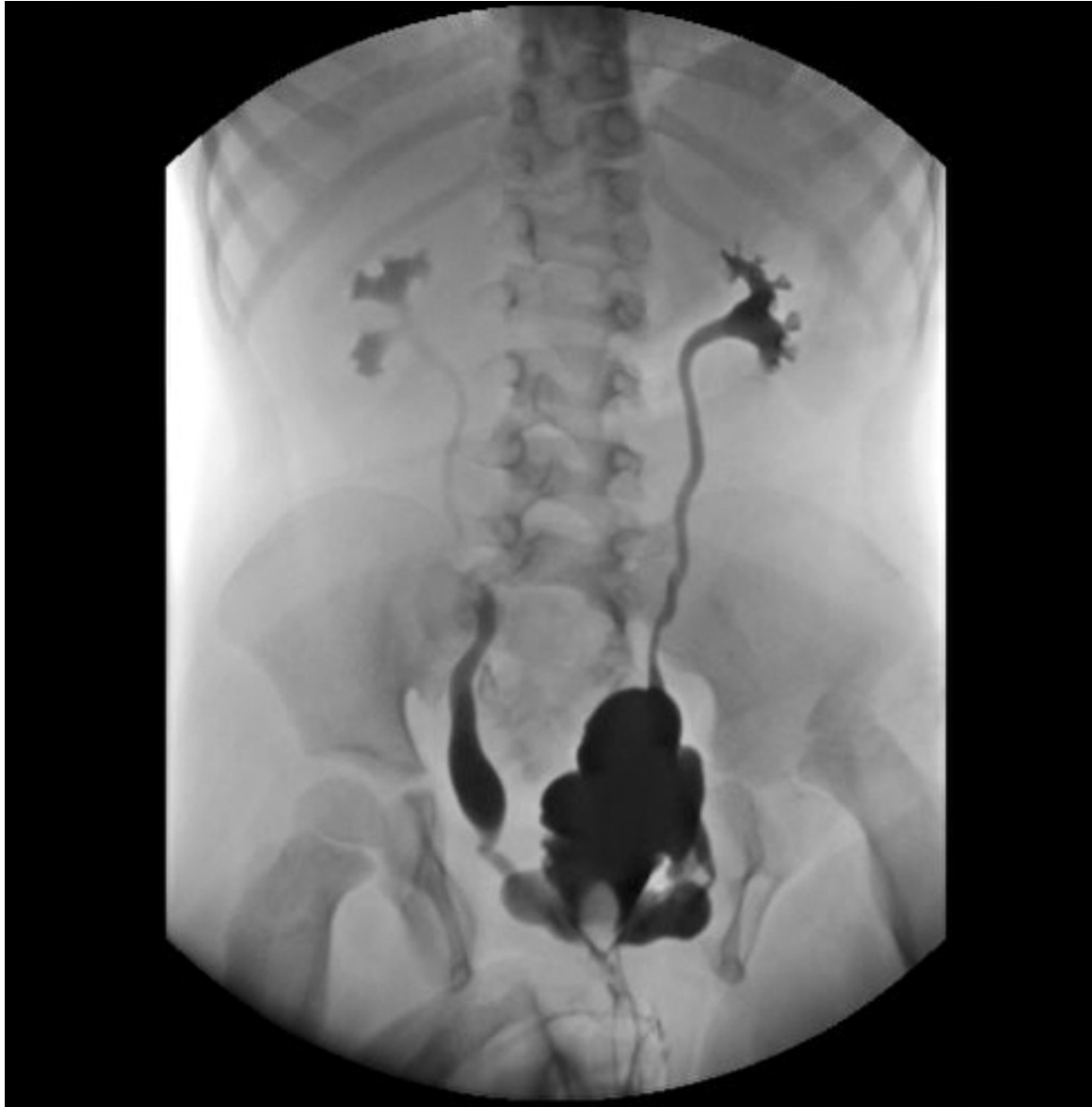- Karla Santos-Jasso MD, MSc, PhD
- Chanel Ugarte-Ignacio Chavarria MD (C-F)
- September 2023-National Institute of Pediatrics

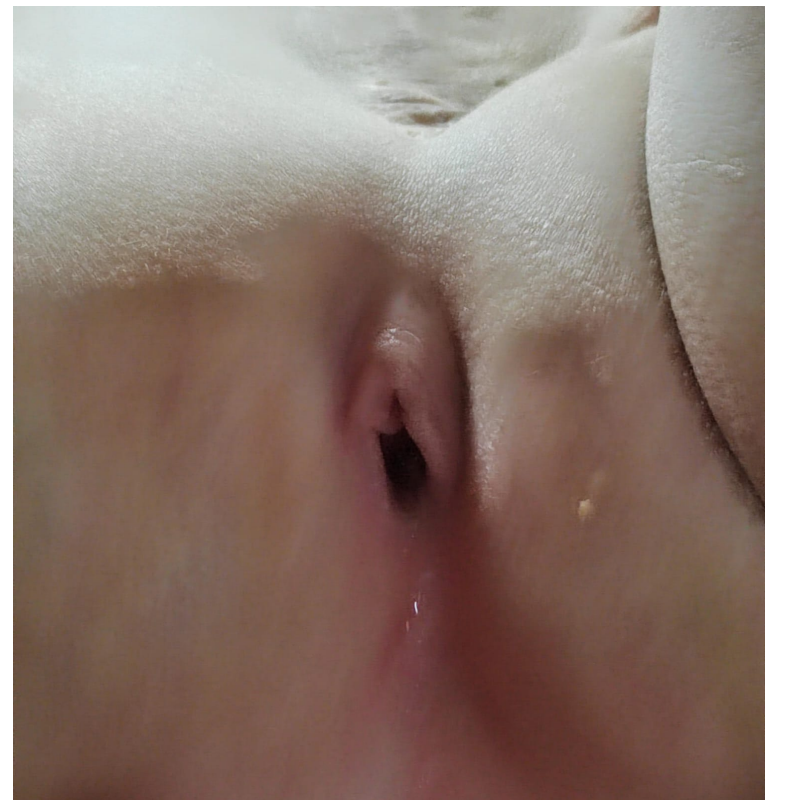
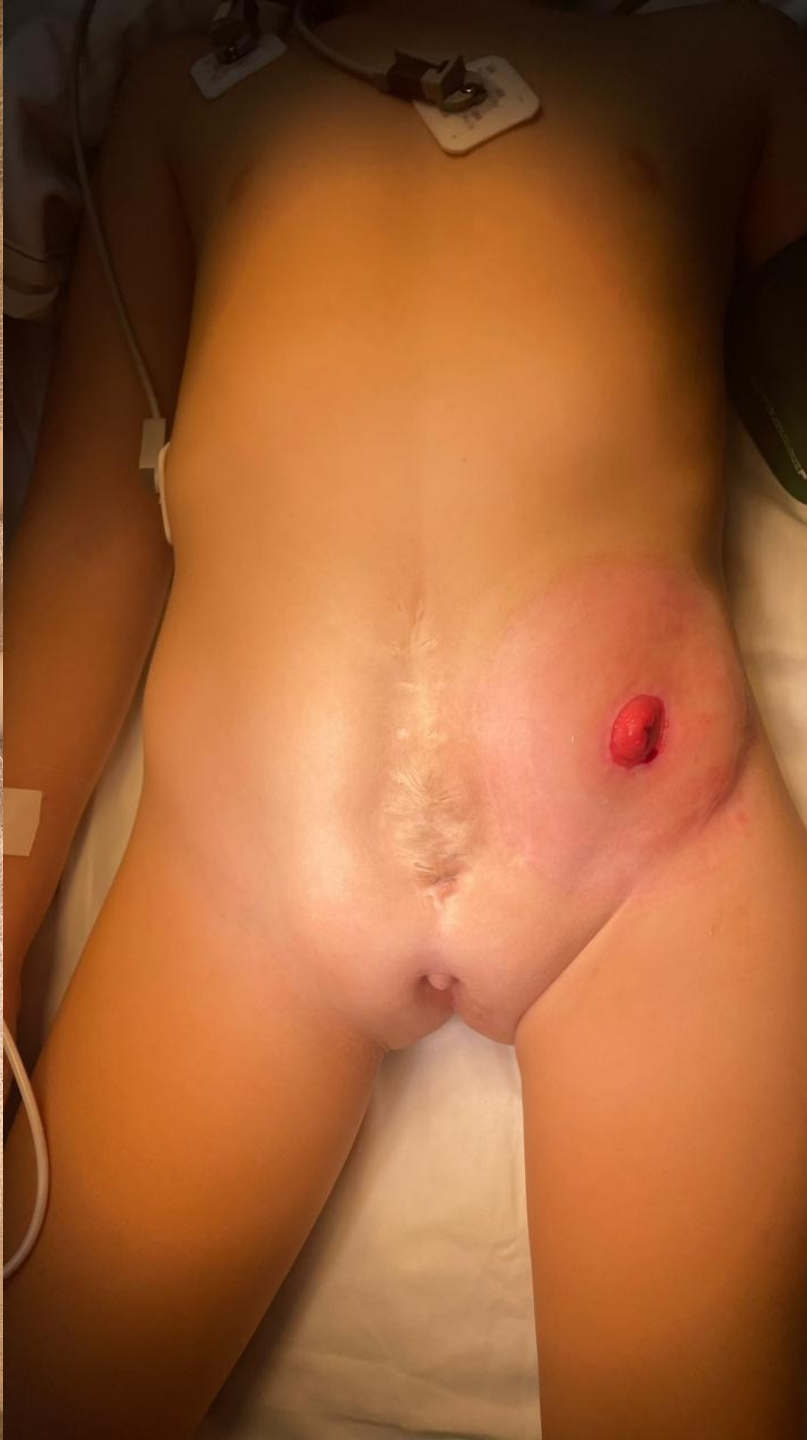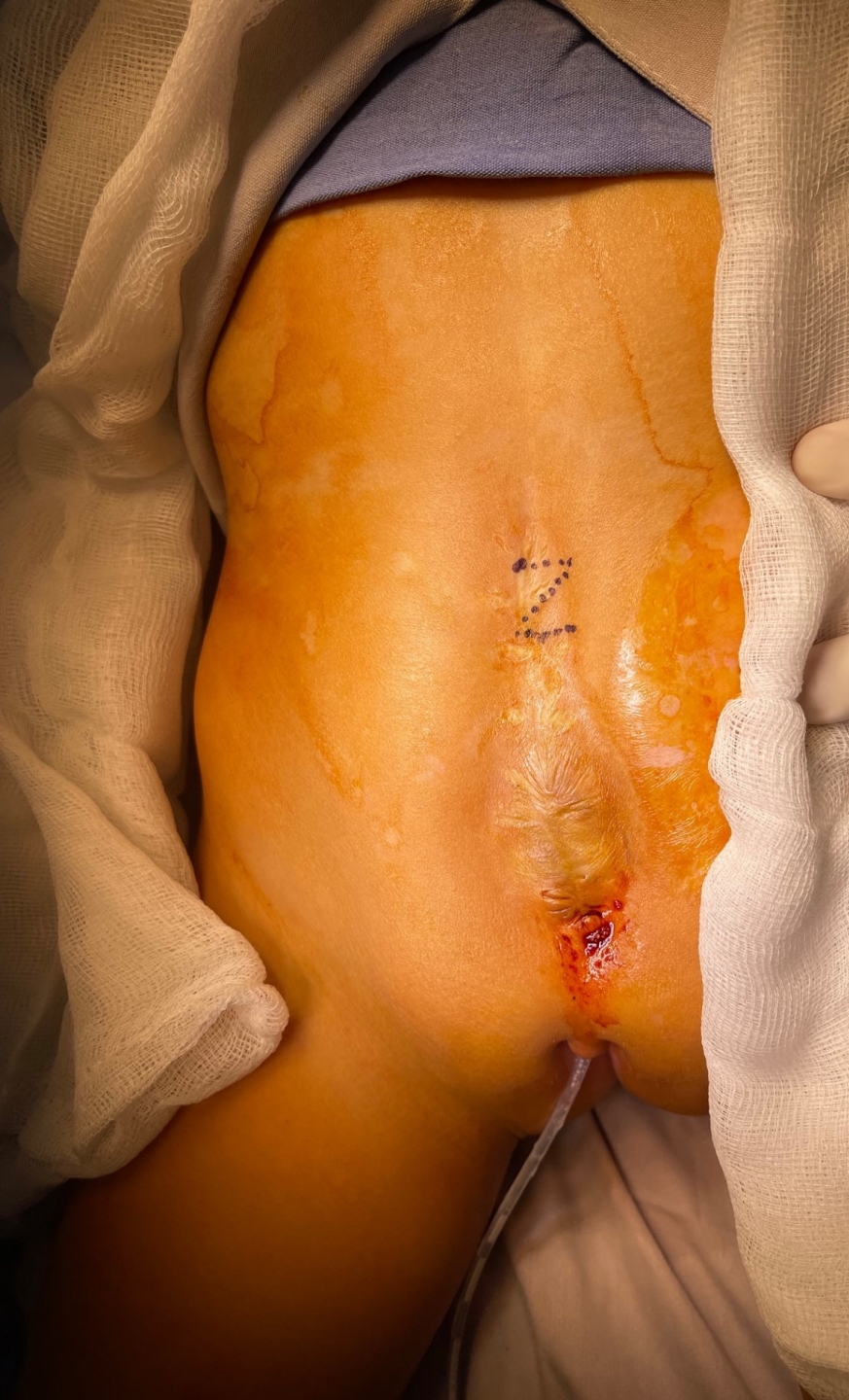6 YO, GIRL

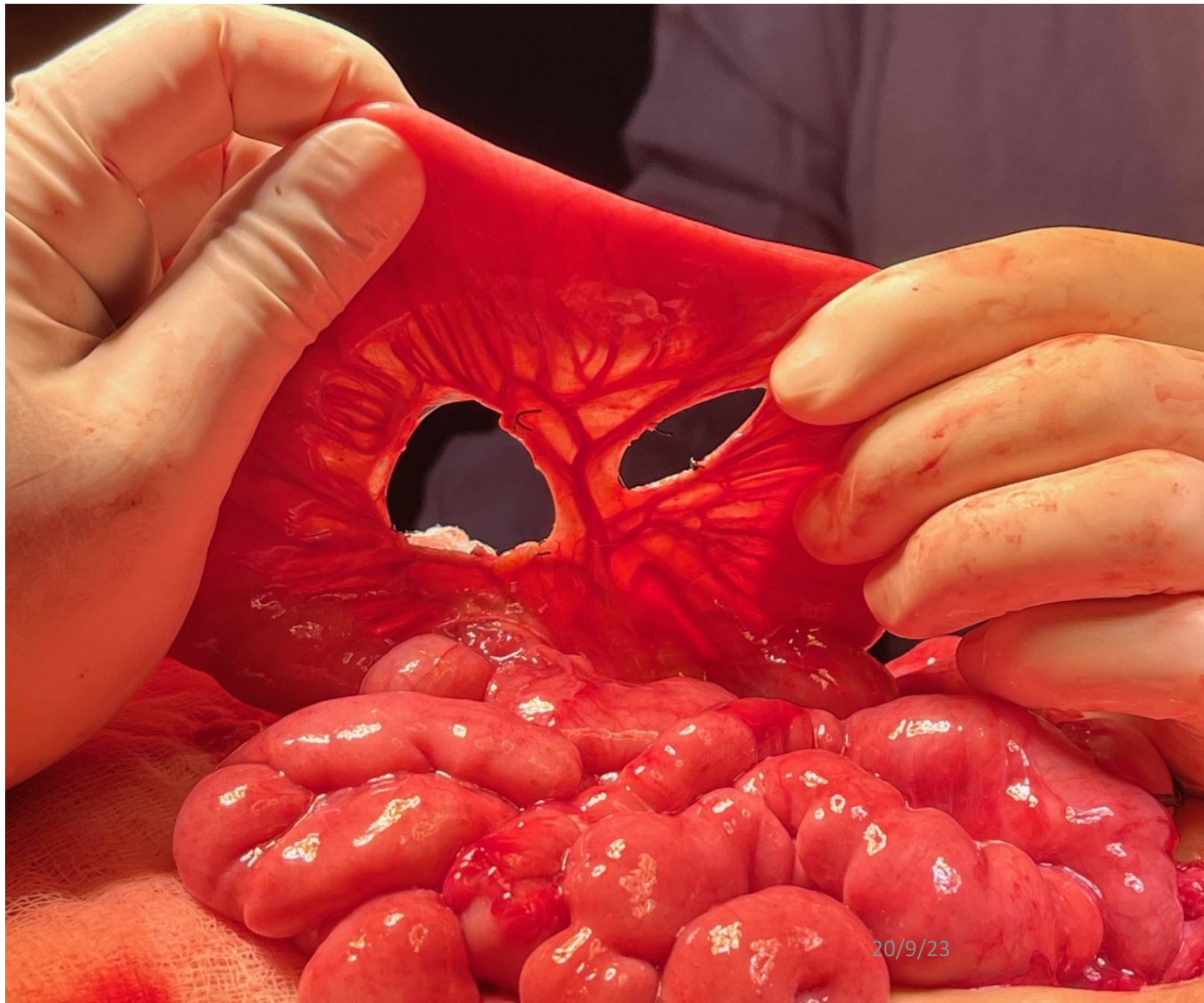OIES (ONPHALOCELE + CLOACAL
EXSTROPHY +
LIPOMENINGOCELE + HYP
DISPLASIA)

1. Ileostomy + vesicostomy +
uterostomy + bladder closure
2017
2. Lipomenincocele repair
3. spinal cord disassembly
4. closure of cerebrospinal fluid
fistula
5. cystoscopy in perineal area
with patent left ureter, no left
meatus, no cervix




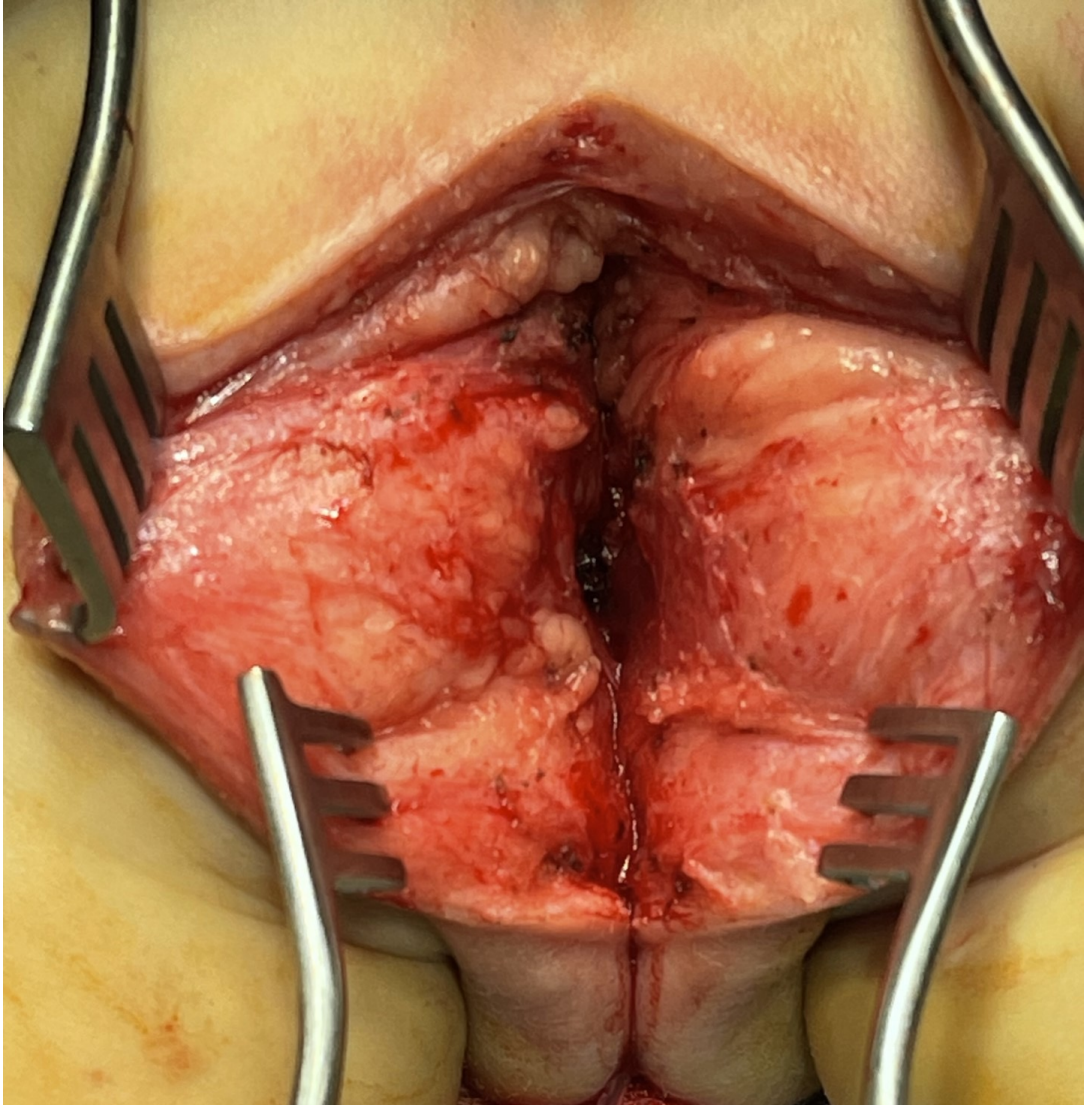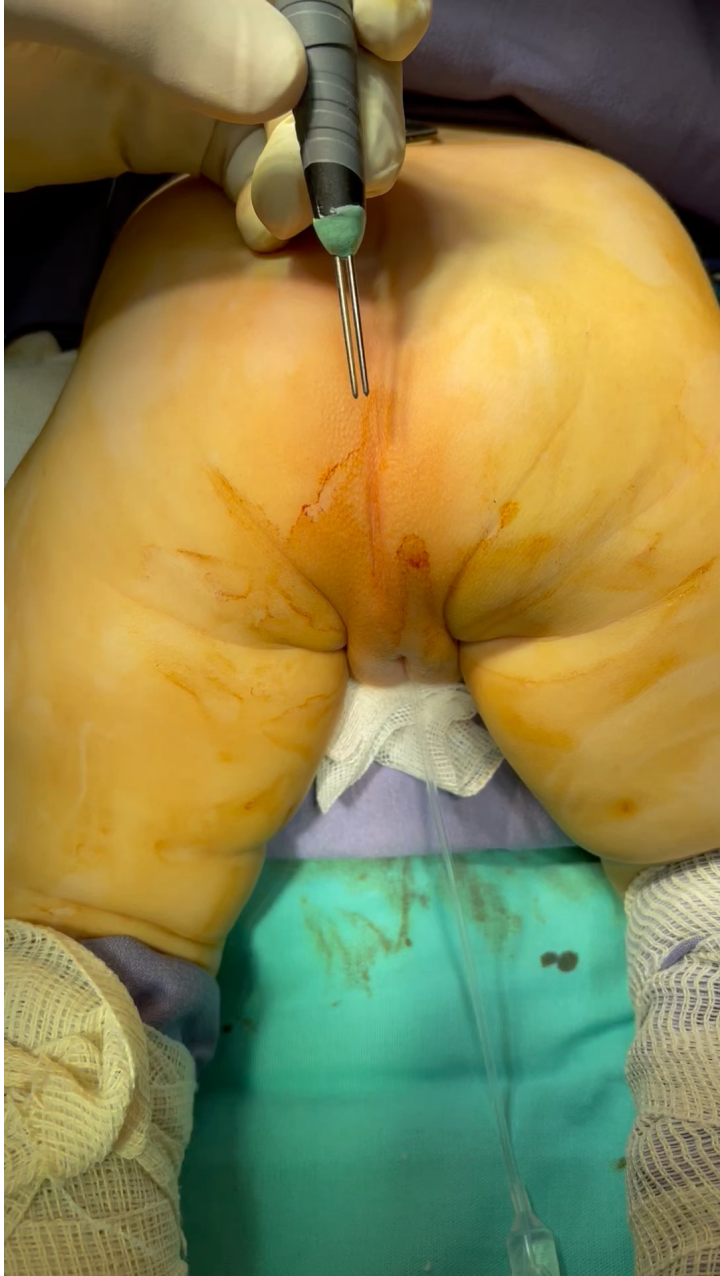


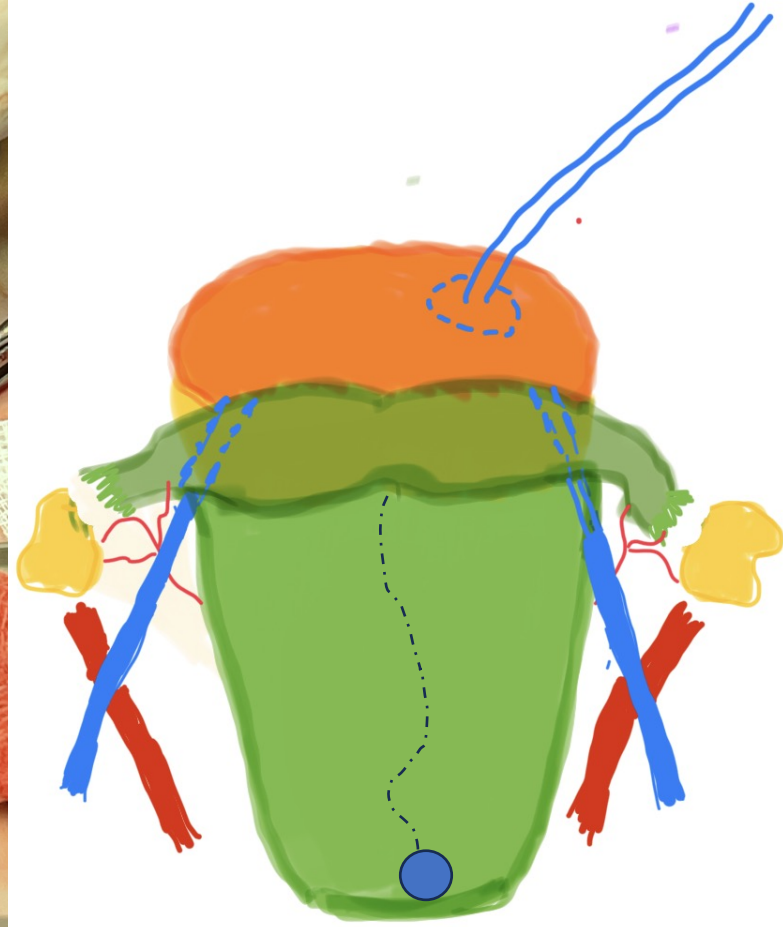
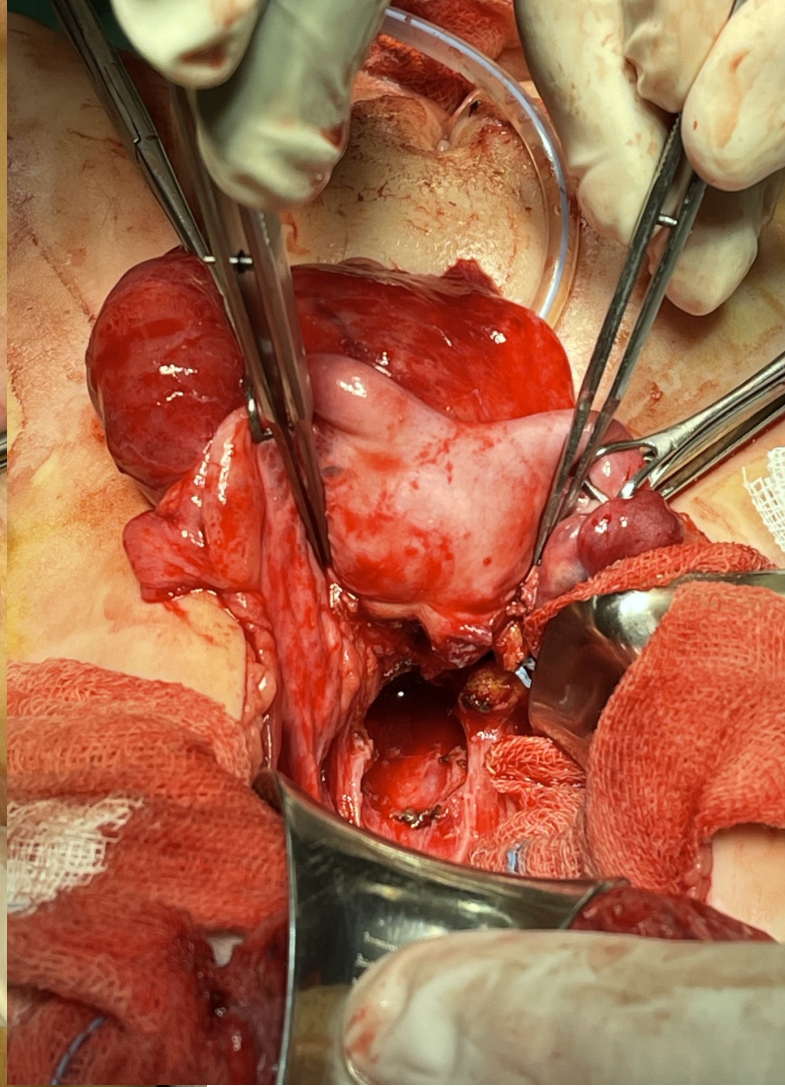
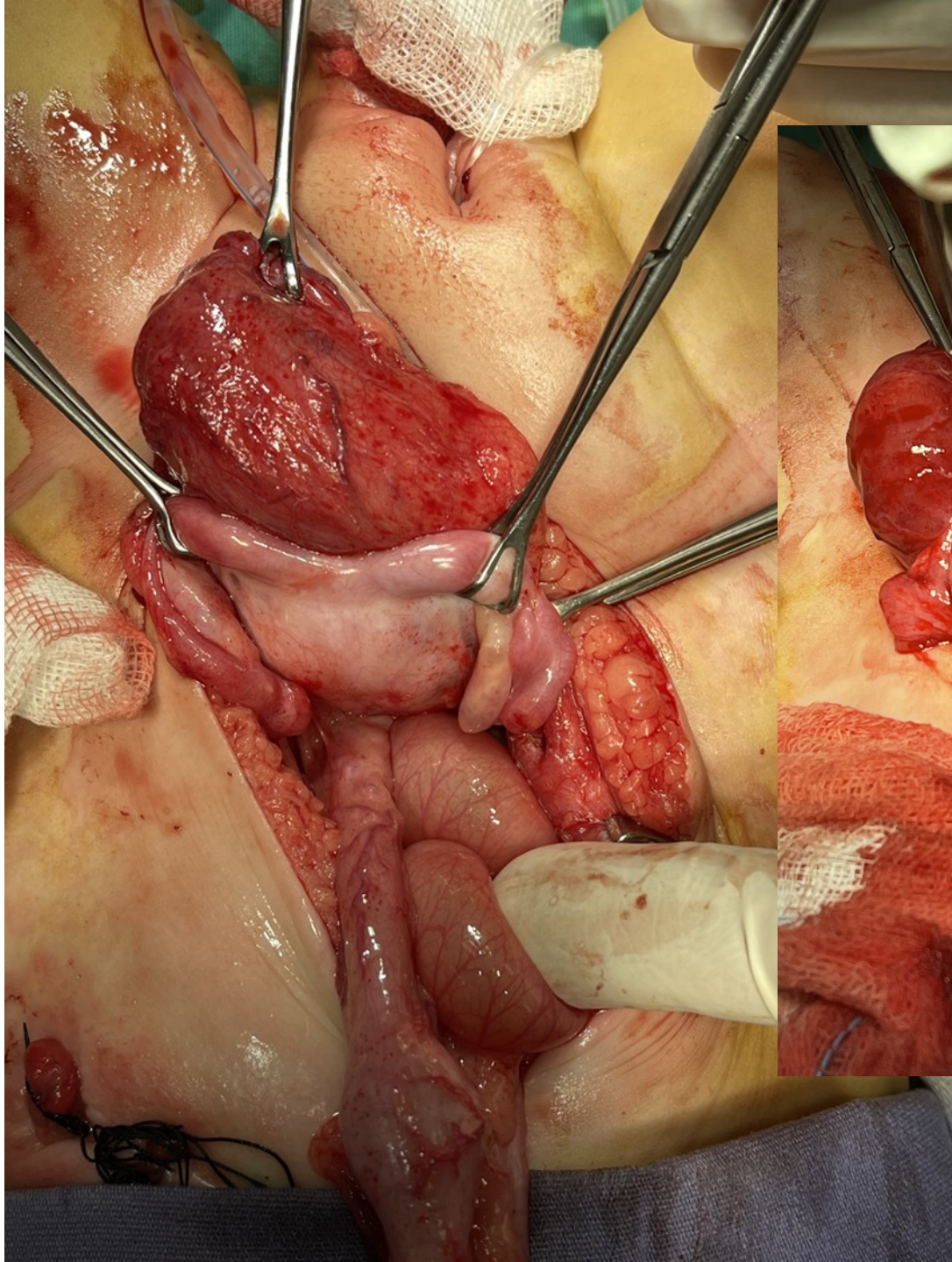


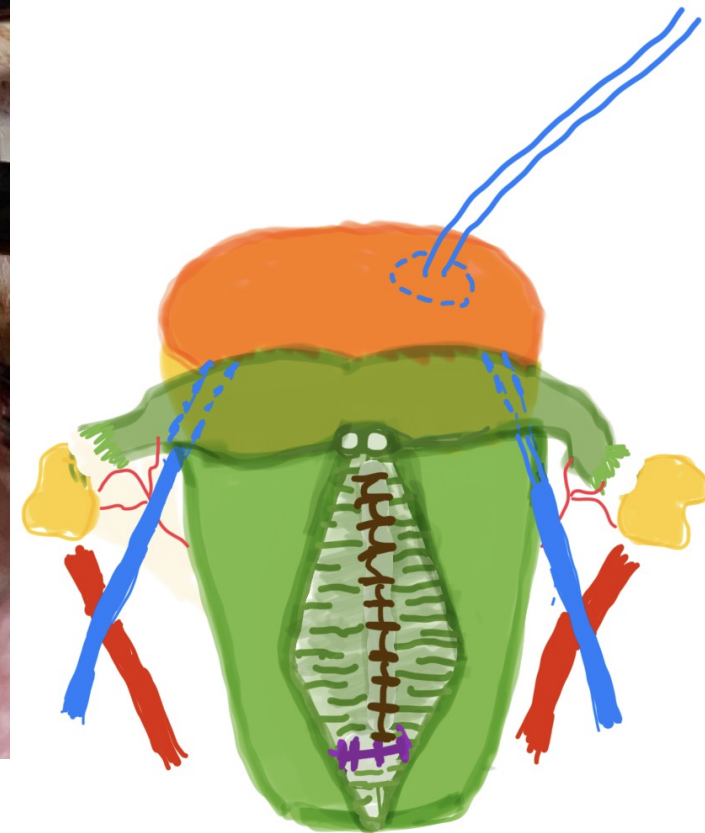
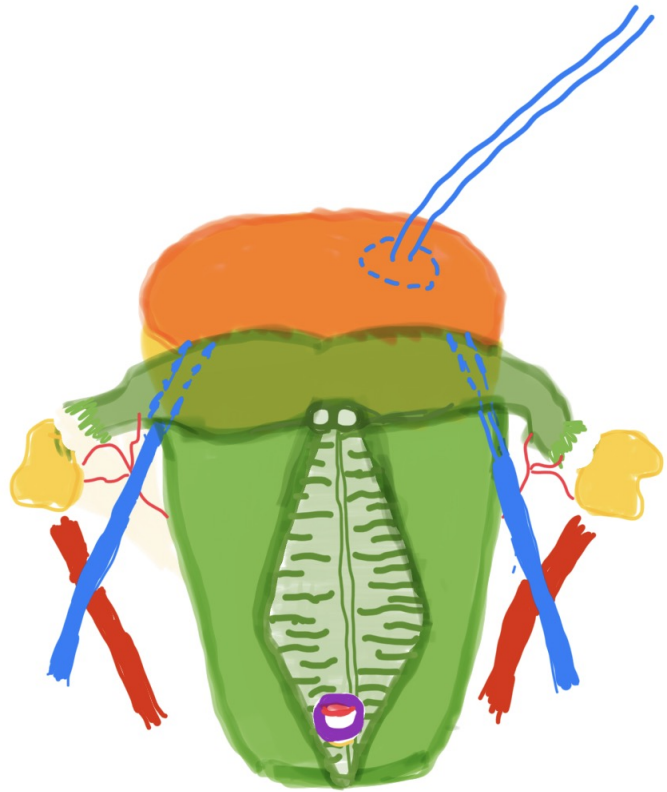
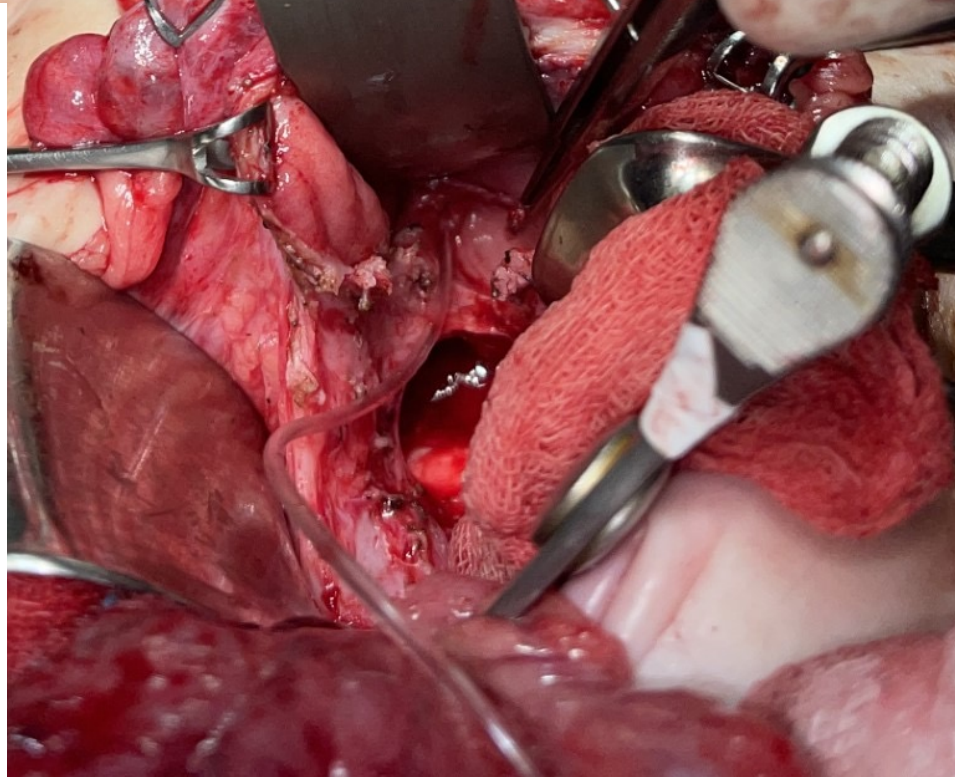
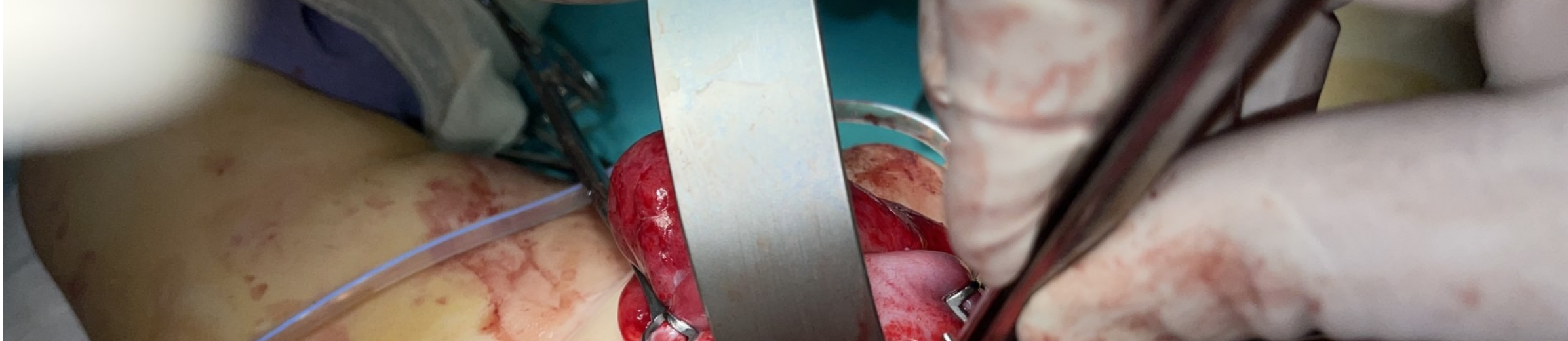

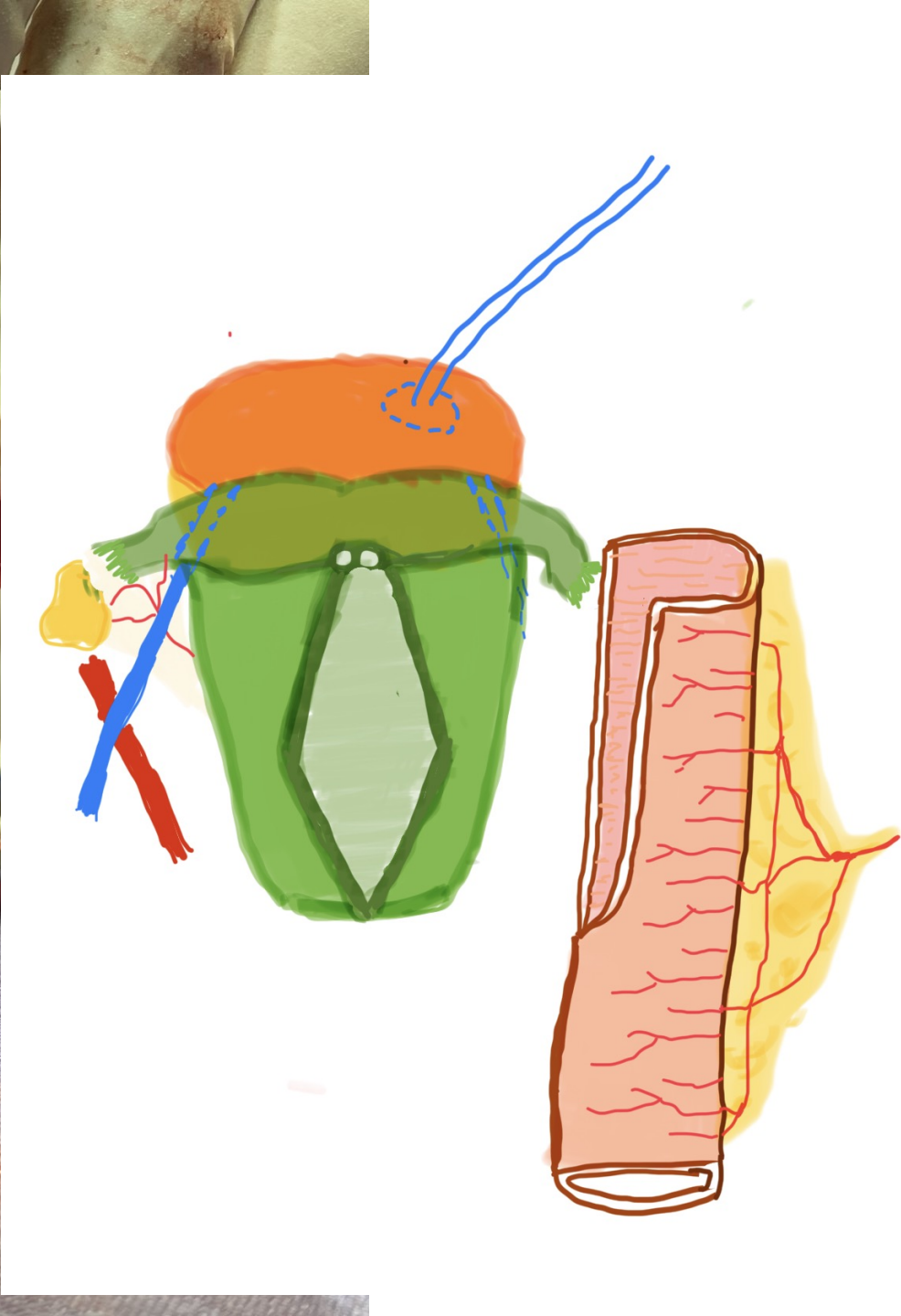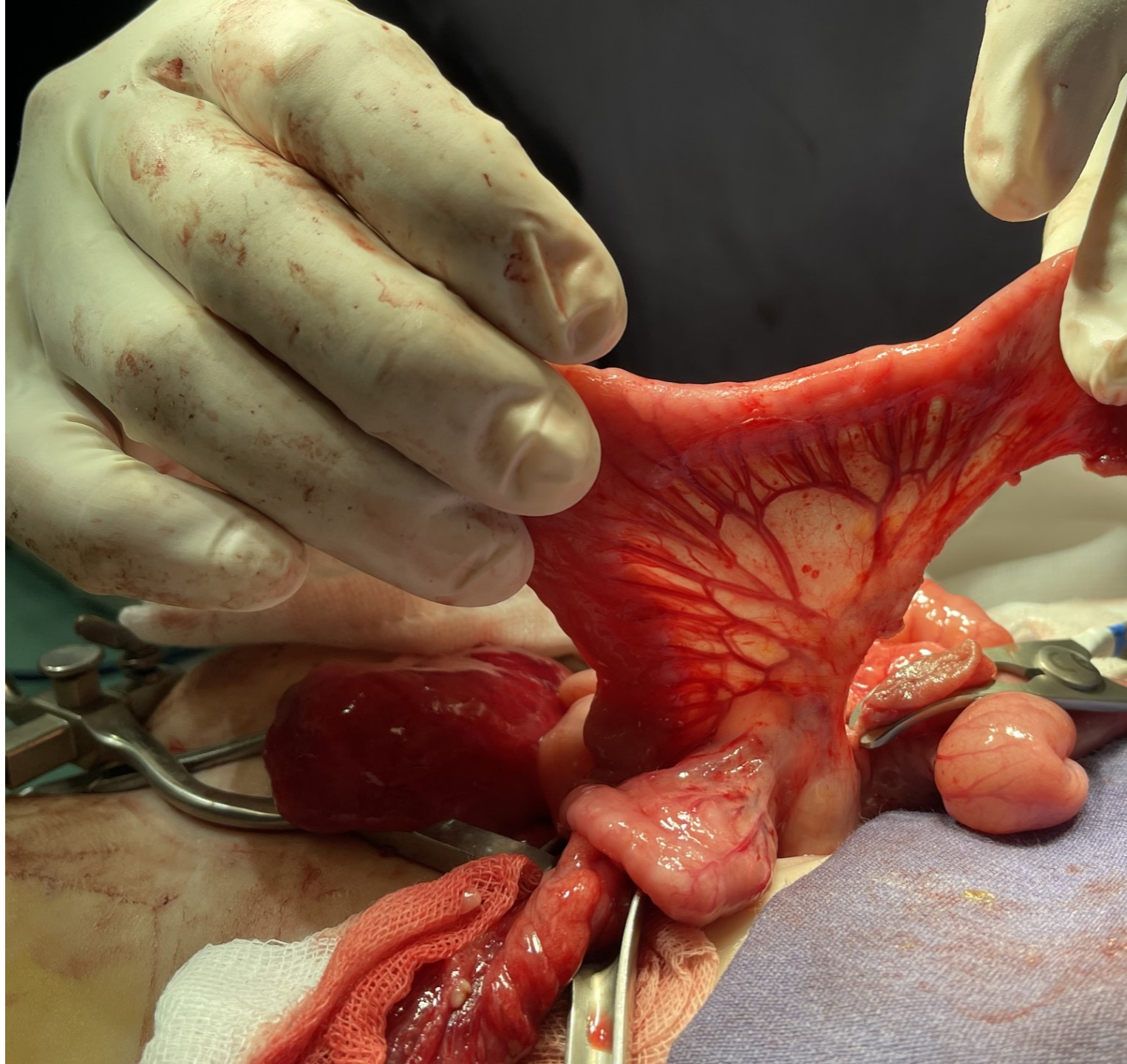
20/9/23

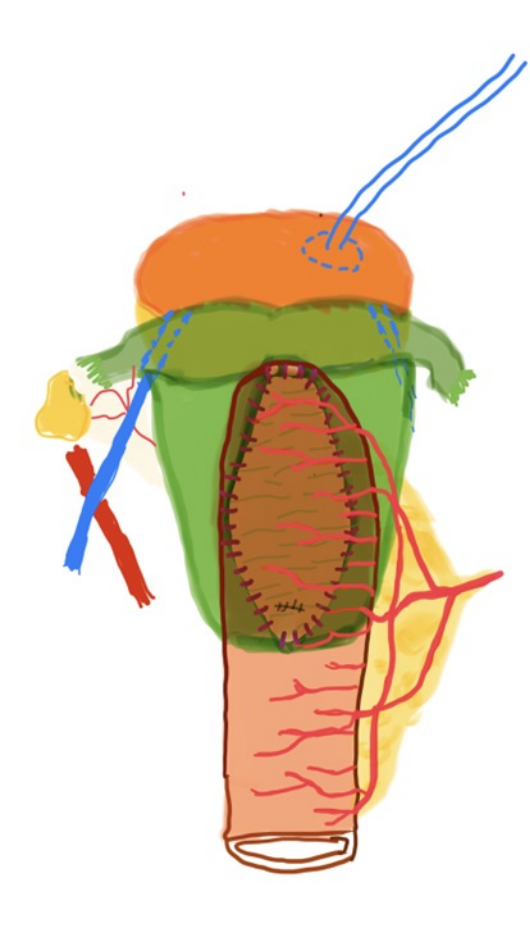
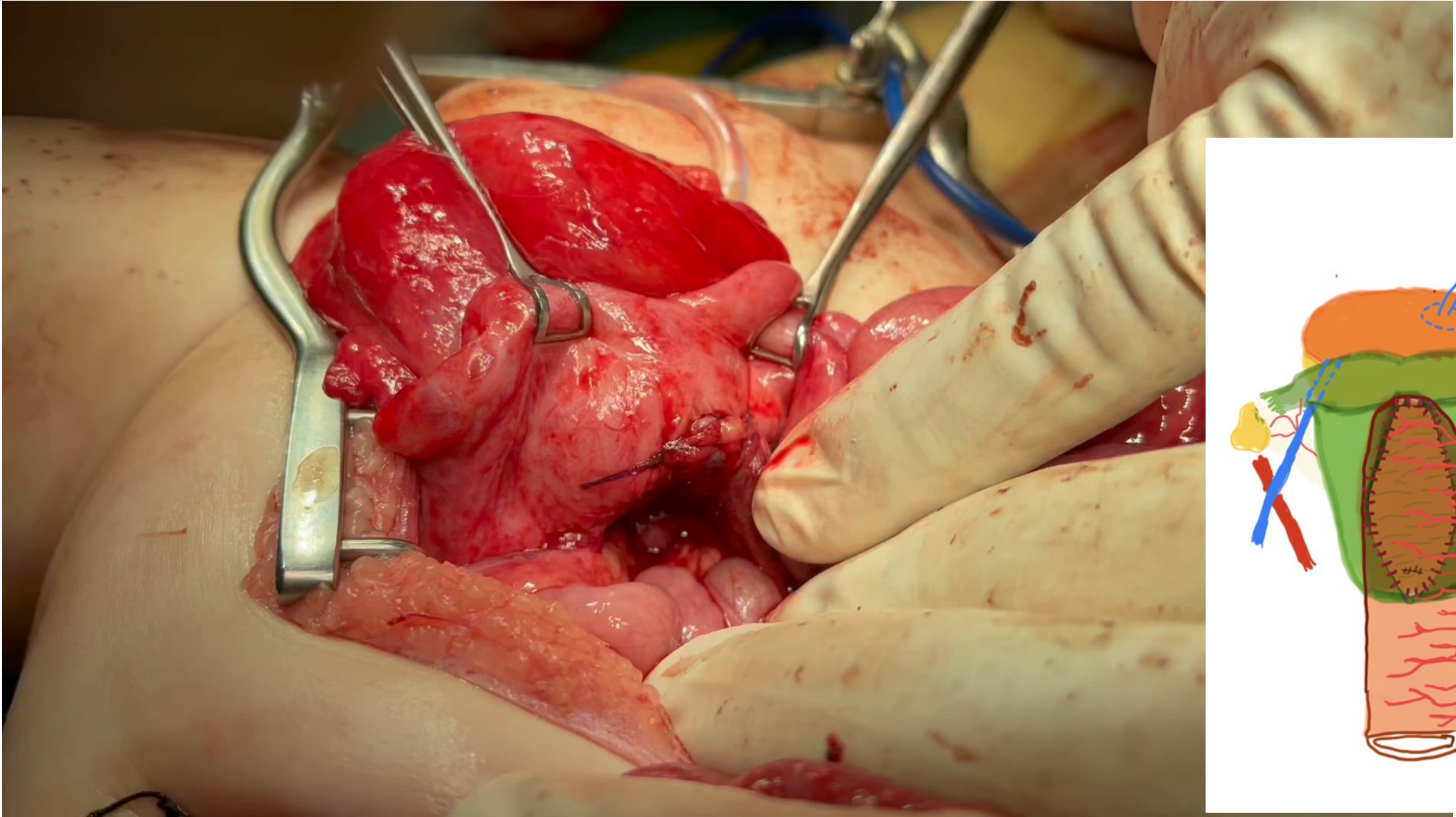


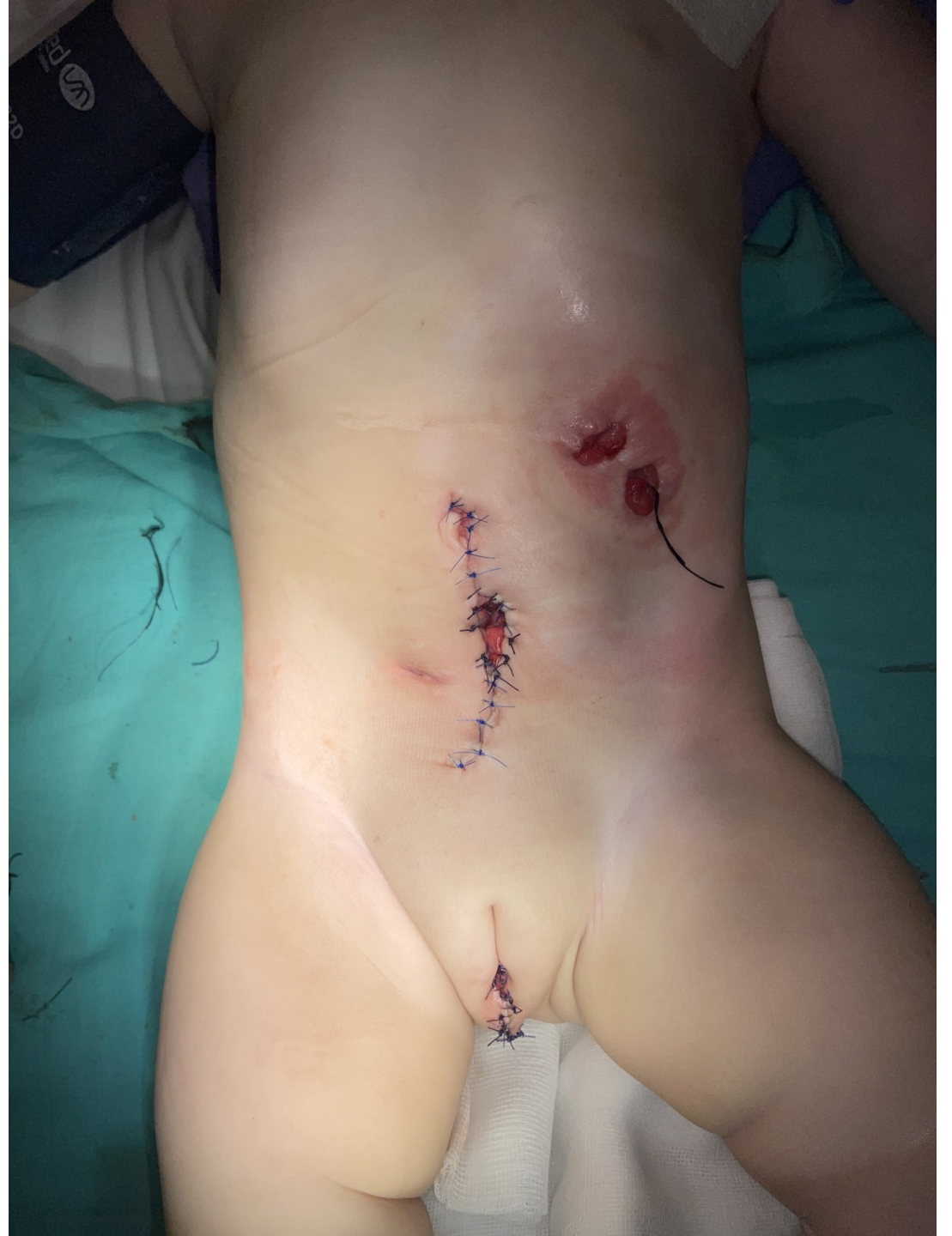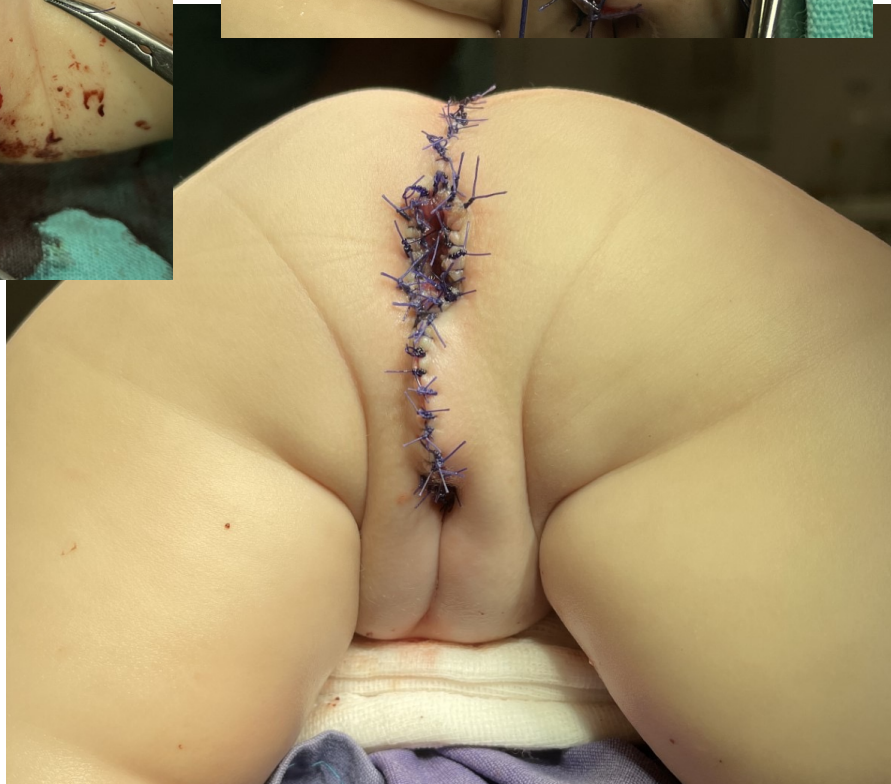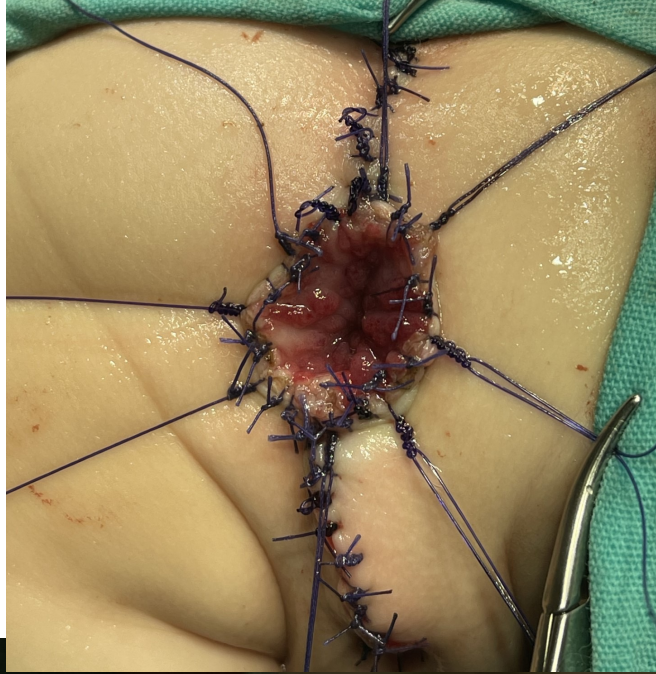
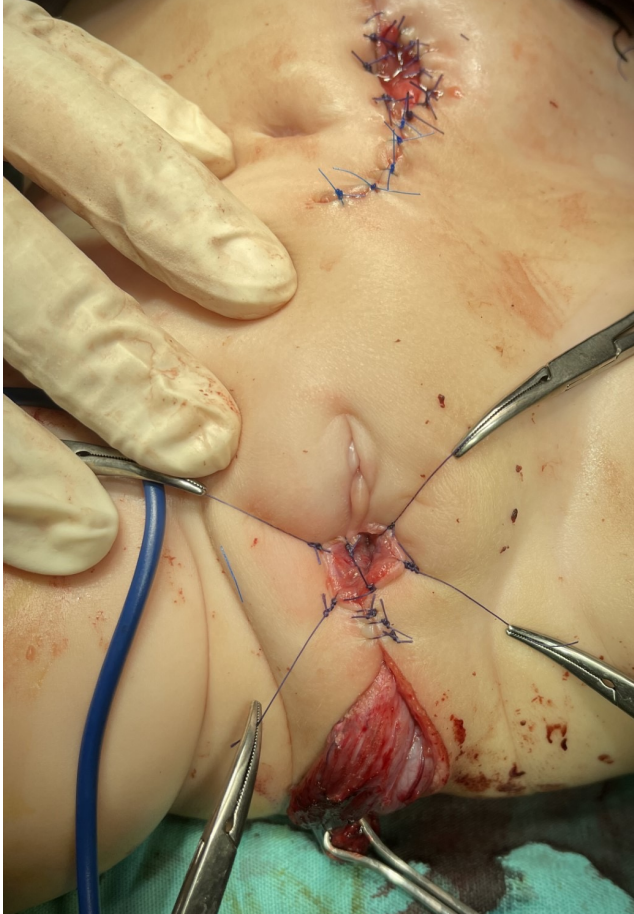












Discussion

- Vaginal switch was not possible because it could not separate the vaginas from the bladder without injuring the ureters.
- we need to have multiple resources for vaginal replacement
- Cystoscopy is a good resource that would help identify the urethra, but our smaller cystoscope did not pass through the urethra and it was not possible to advance a guide.
- Cloaca are a box of surprises