

Colorectal Web Meeting

Carlos Tijerina, MD

María Zornoza MD, Alejandro Ruíz MD

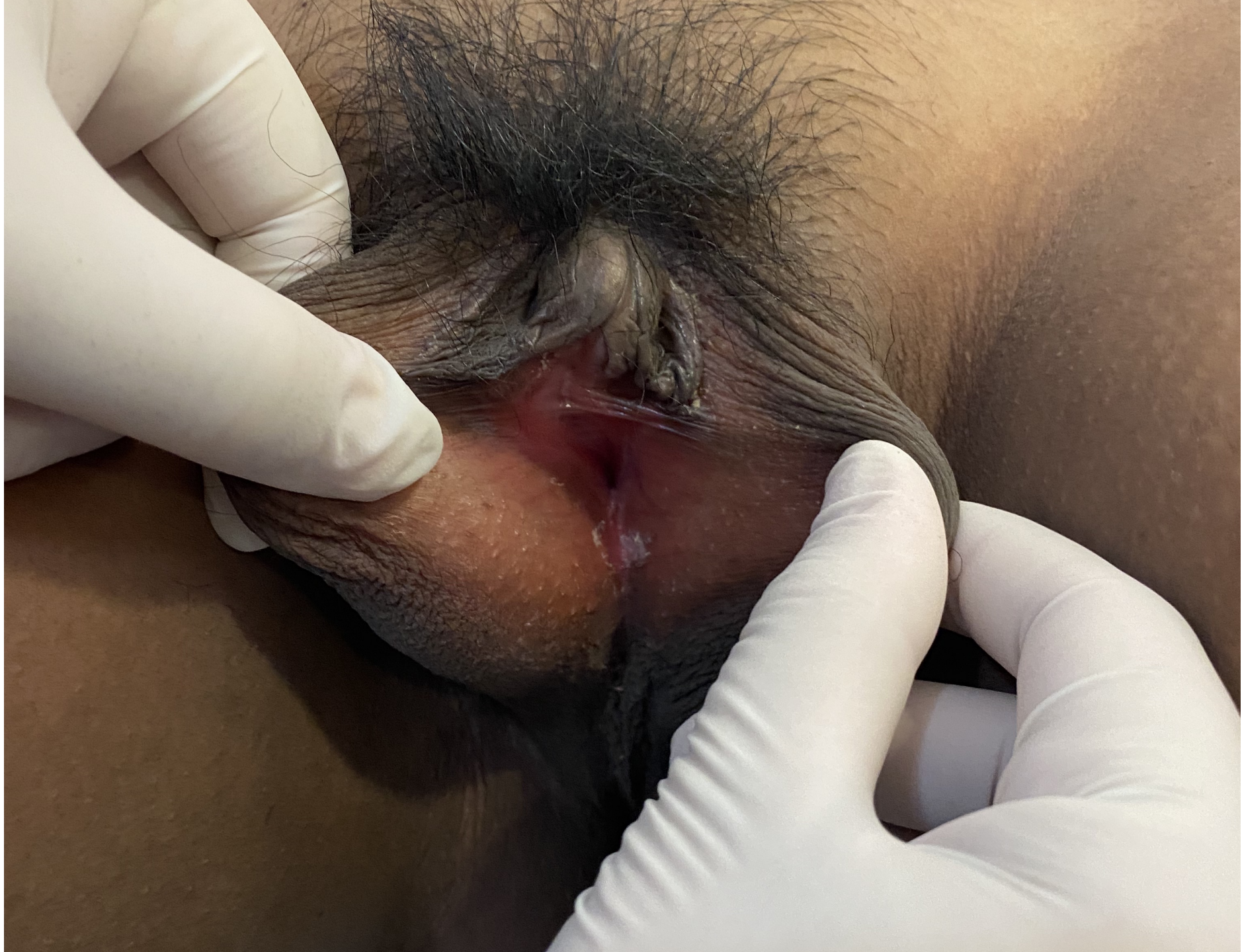Centro Colorrectal para Niños

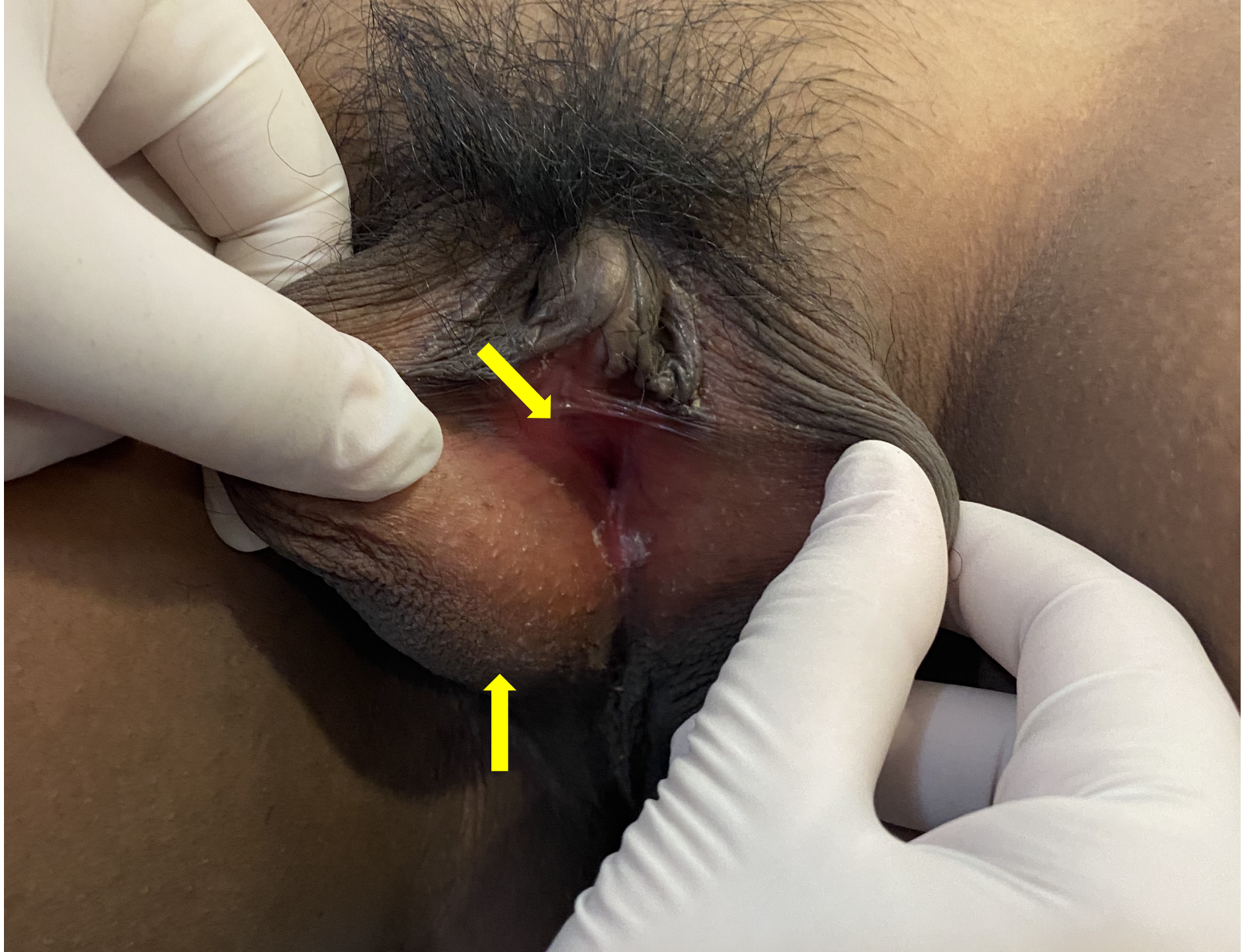Background



- Female, 13 years old
- Genital anomaly
- Inguinal mass







What is your diagnosis?

1. Normal anatomy
2. Cloaca
3. Urogenital sinus
4. Perineal hypospadias
5. Disorder of sex development
6. I don't know

What studies would you like to order?

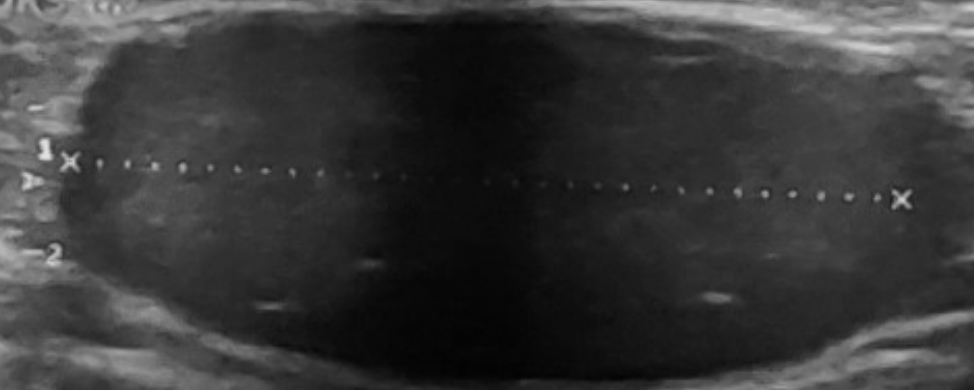


1. Pelvic ultrasound
2. Voiding cystourethrogram
3. Hormone test
4. Karyotype
5. All of above

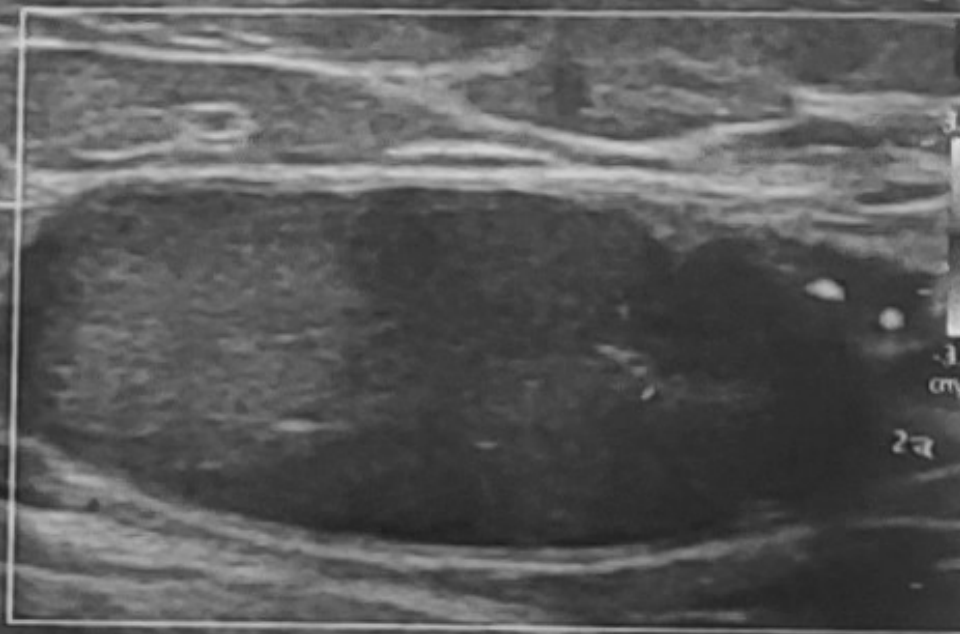
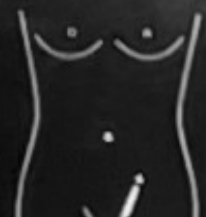Lab test

- Karyotype 46 XY
- No congenital adrenal hyperplasia (CAH)
- Normal Luteinizing hormone (LH) and Follicle-stimulating hormone (FSH)
- Normal testosterone and estradiol test

24 9:00
HAR
AP 100%
DG 40%
Fq 12MHz
FR 40.71 Hz
ORC 100

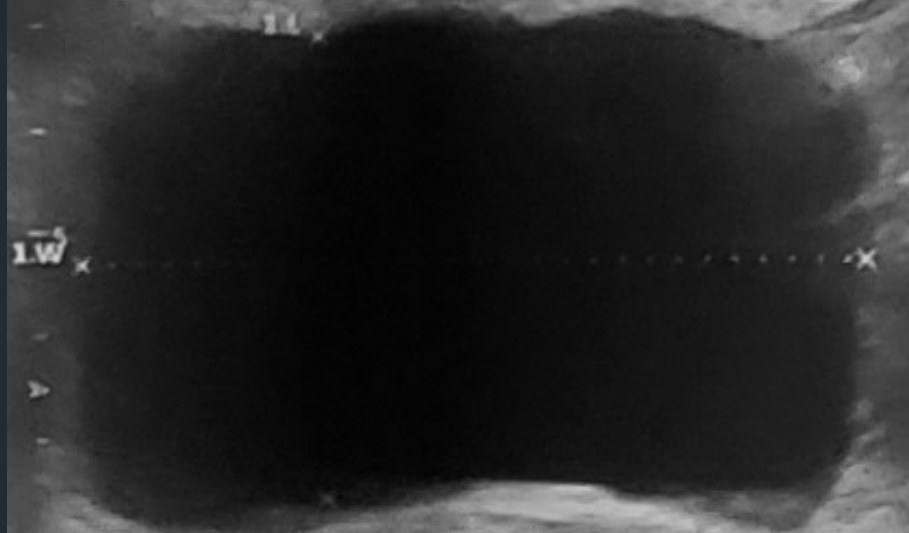


REG INGUINAL IZO



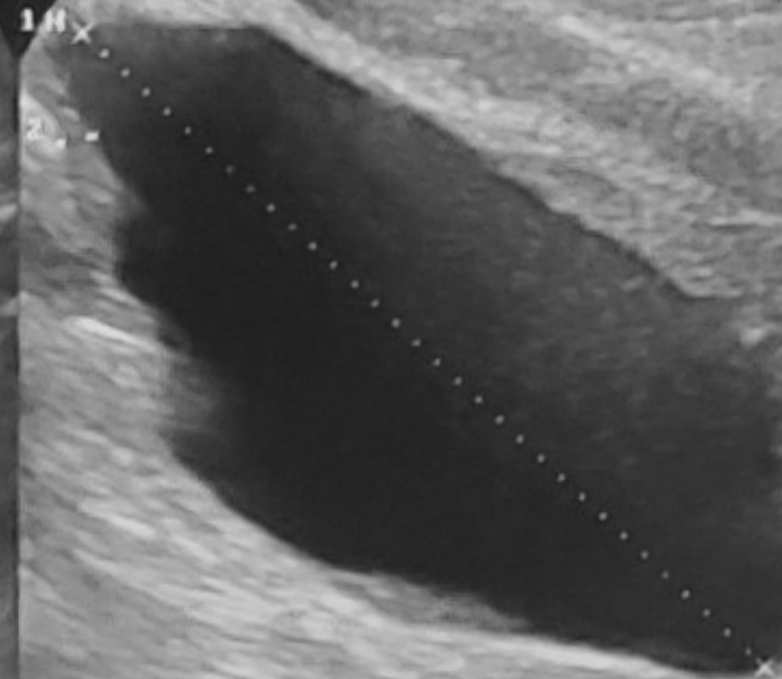Testiculu
1 Distancia 2.86cm

P 13 20
AB
P 100%
G 50%
q 4.5M
R 20
R 9



VEJIGA

-10



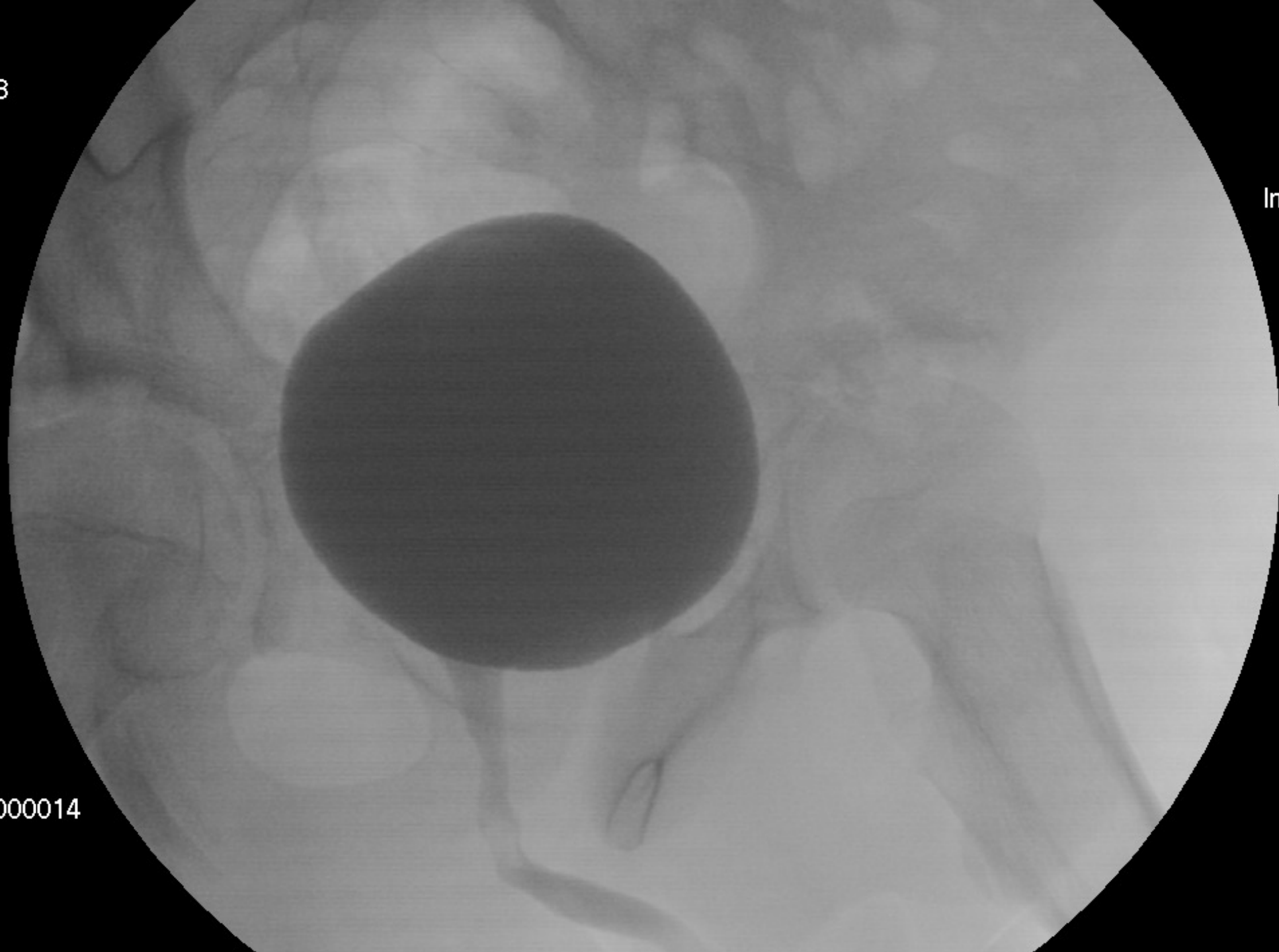
Abdominal General

1 Volume	147.79cm ³
L	4.47cm
W	7.30cm
H	8.65cm
2 Distace	0.32cm

8

Im

000014



What procedures would you like to do?



1. Cystoscopy
2. Laparoscopy
3. Laparoscopy and mass biopsy
4. 1 & 3
5. None
6. All of above

Cystoscopy



- Male urethra and normal veru montanum
- Normal bladder
- No urogenital sinus

Laparoscopy

- No Müllerian structures
- Bilateral thin vas deferens
- Biopsy of gonads
 - Report
 - Right normal testicle
 - Left normal testicle

What is your diagnosis?

1. 46,XX DSD
2. 46,XY DSD
3. Ovotesticular DSD
4. Mixed gonadal dysgenesis
5. Pure gonadal dysgenesis

Diagnosis



- 46,XY DSD
 - Partial androgen insensitivity syndrome

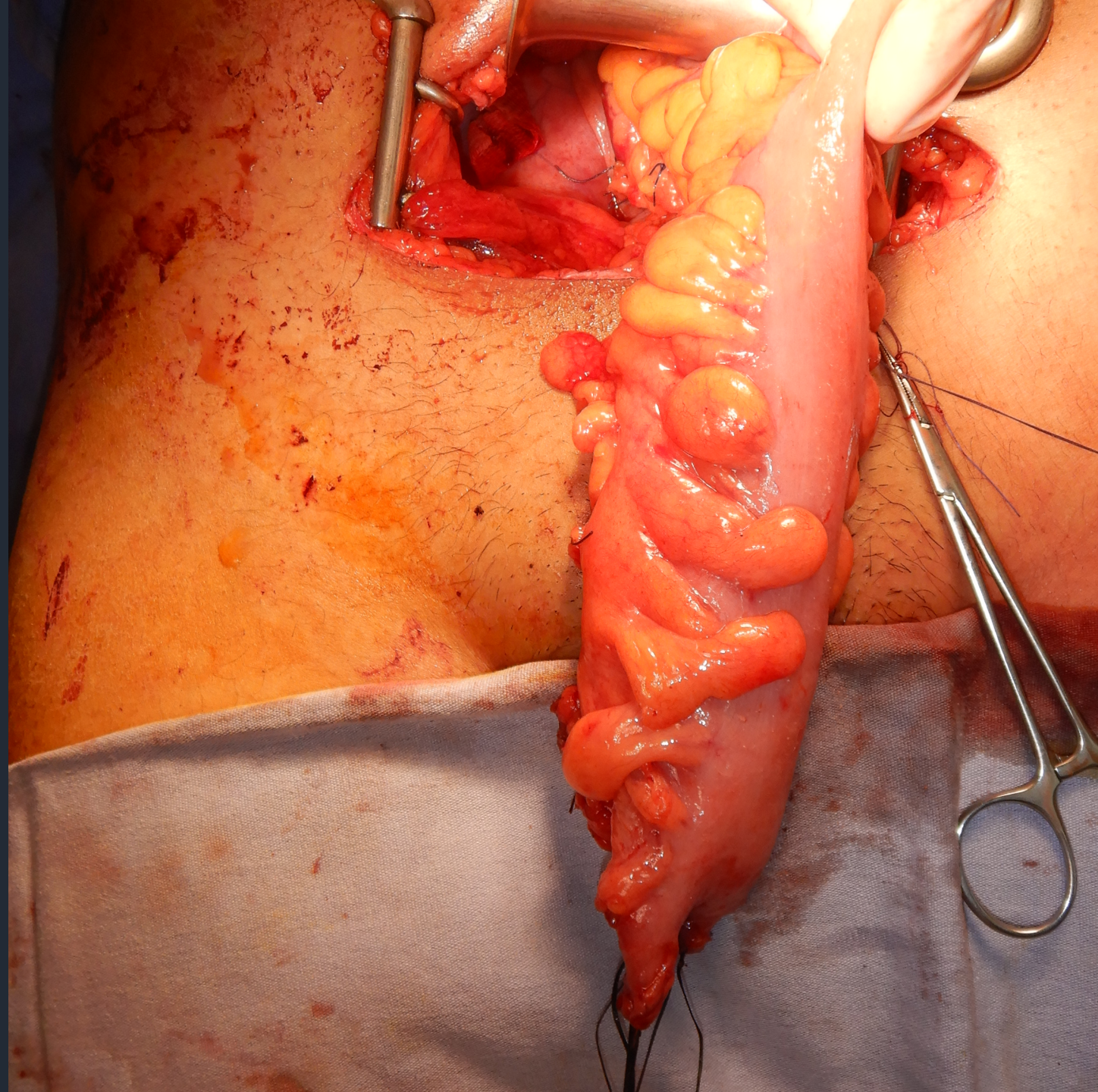
DSD committee

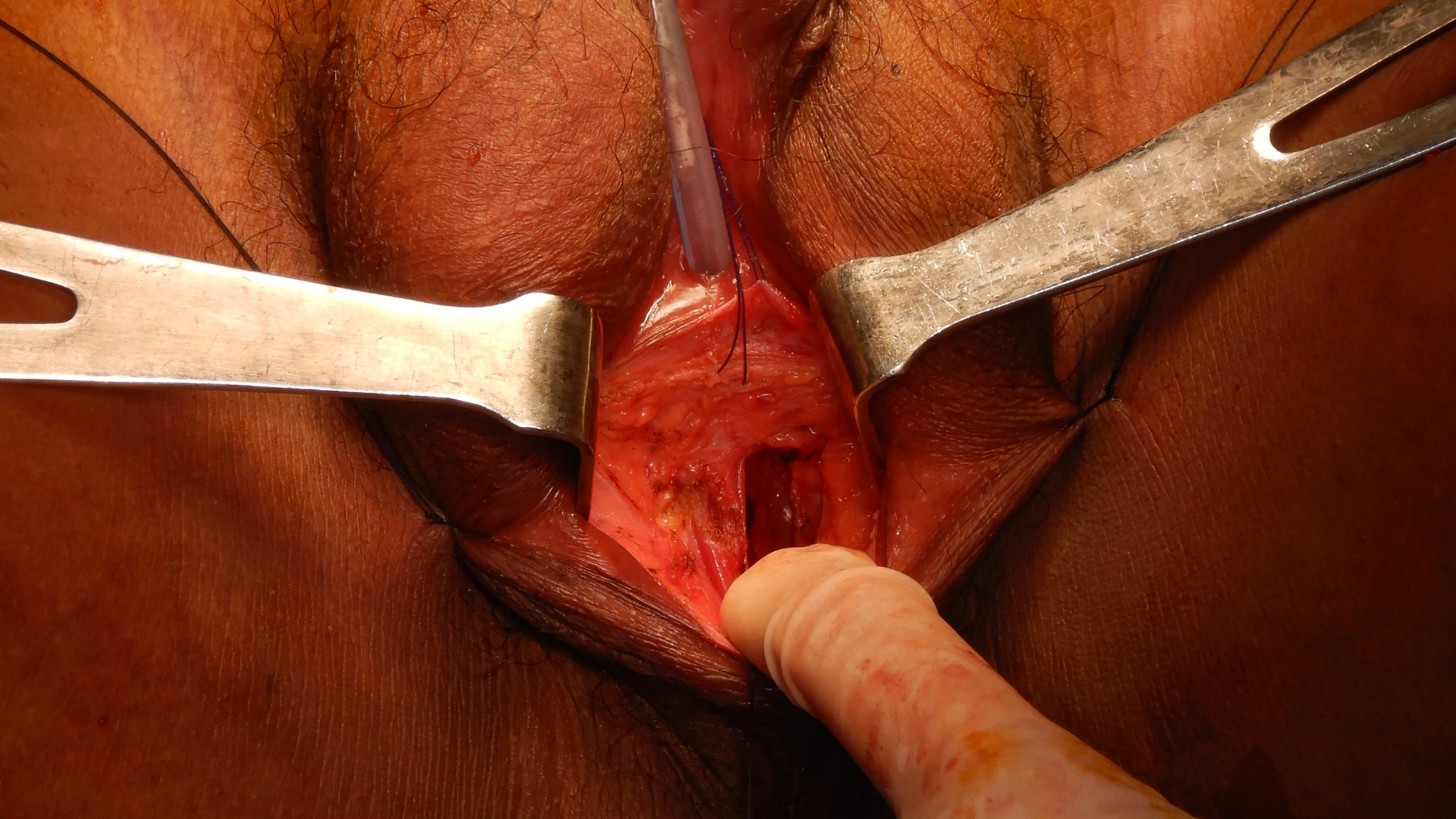

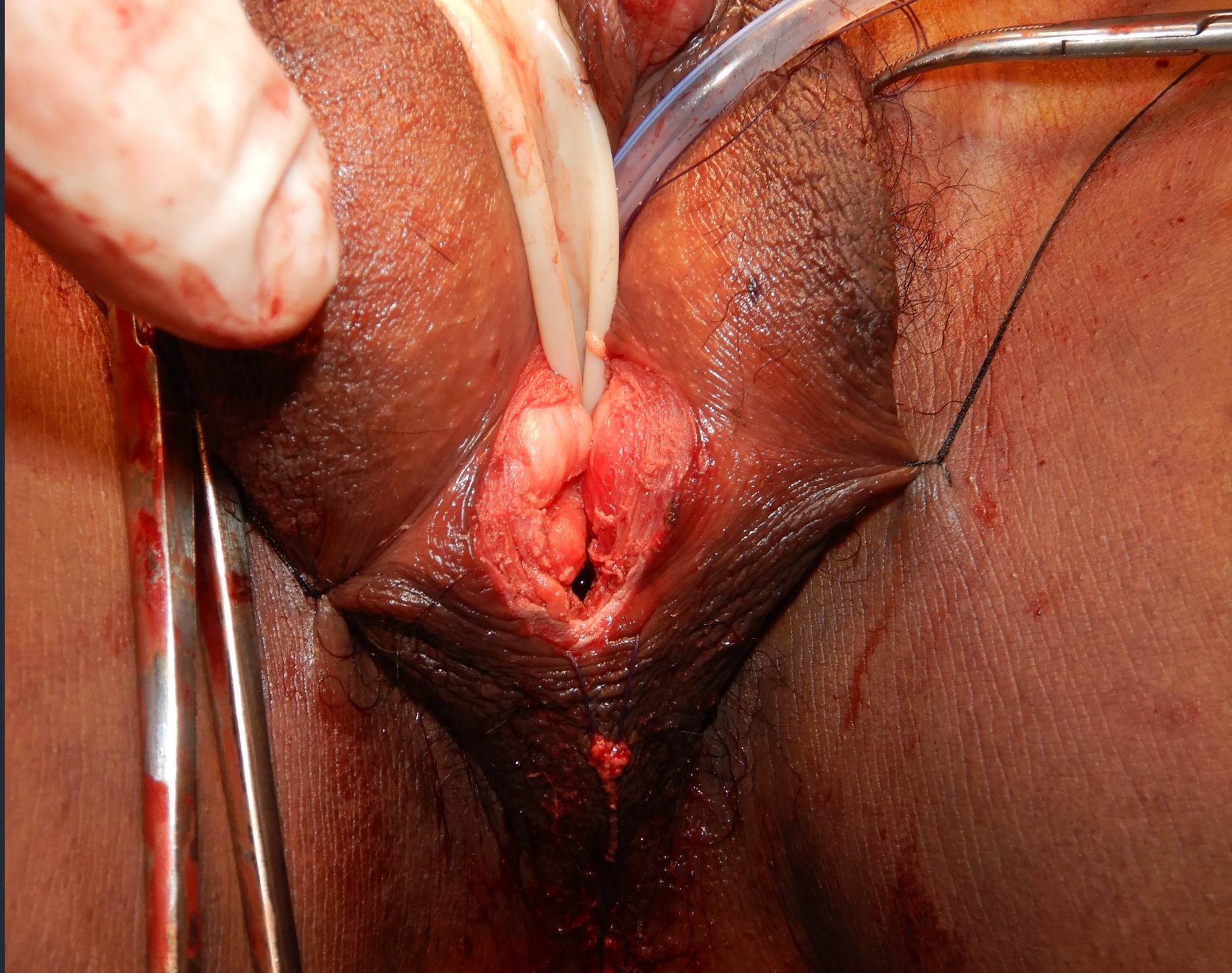- One year of psychological follow-up before surgery
- Mental health: female role
- Female

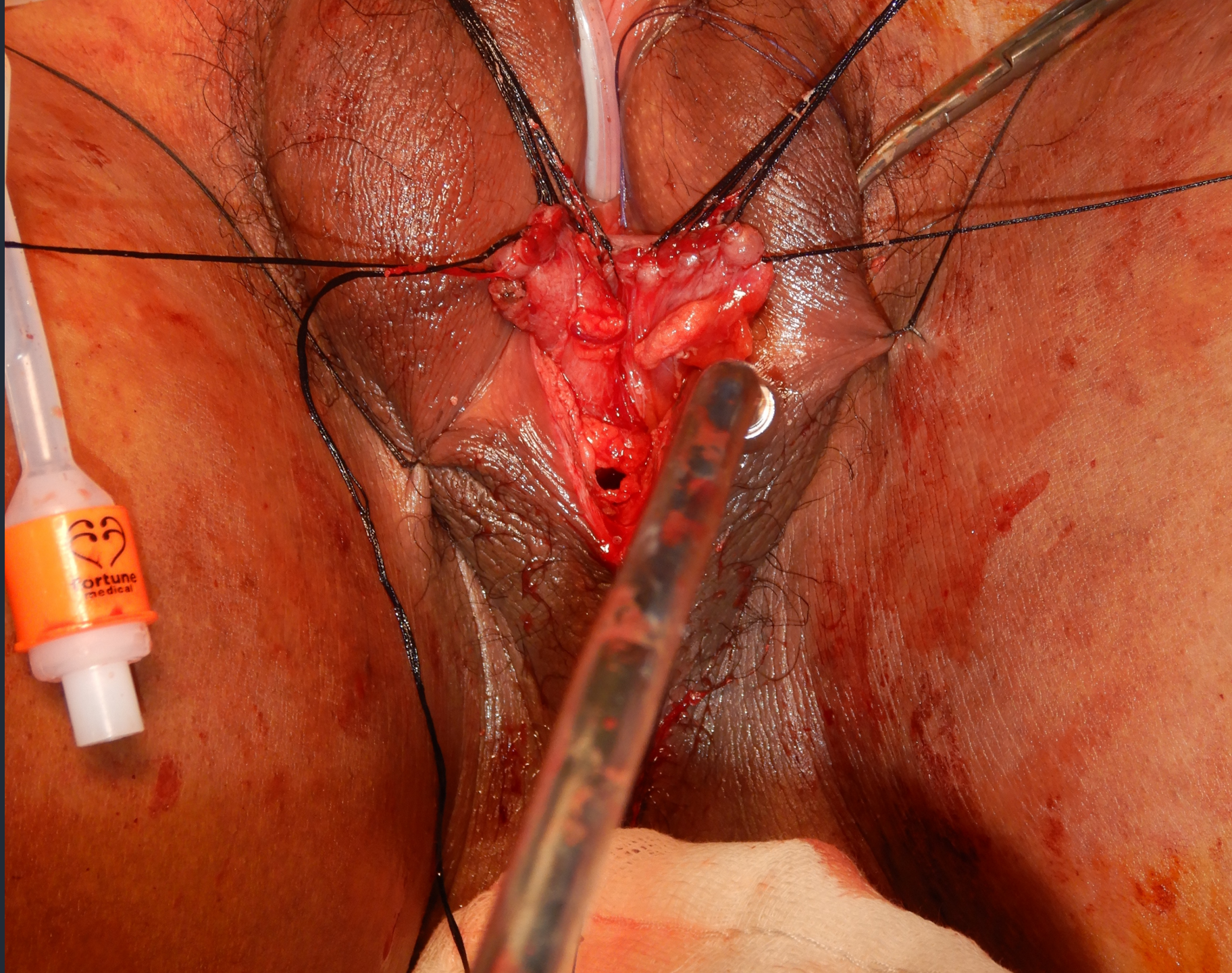
What is your plan?

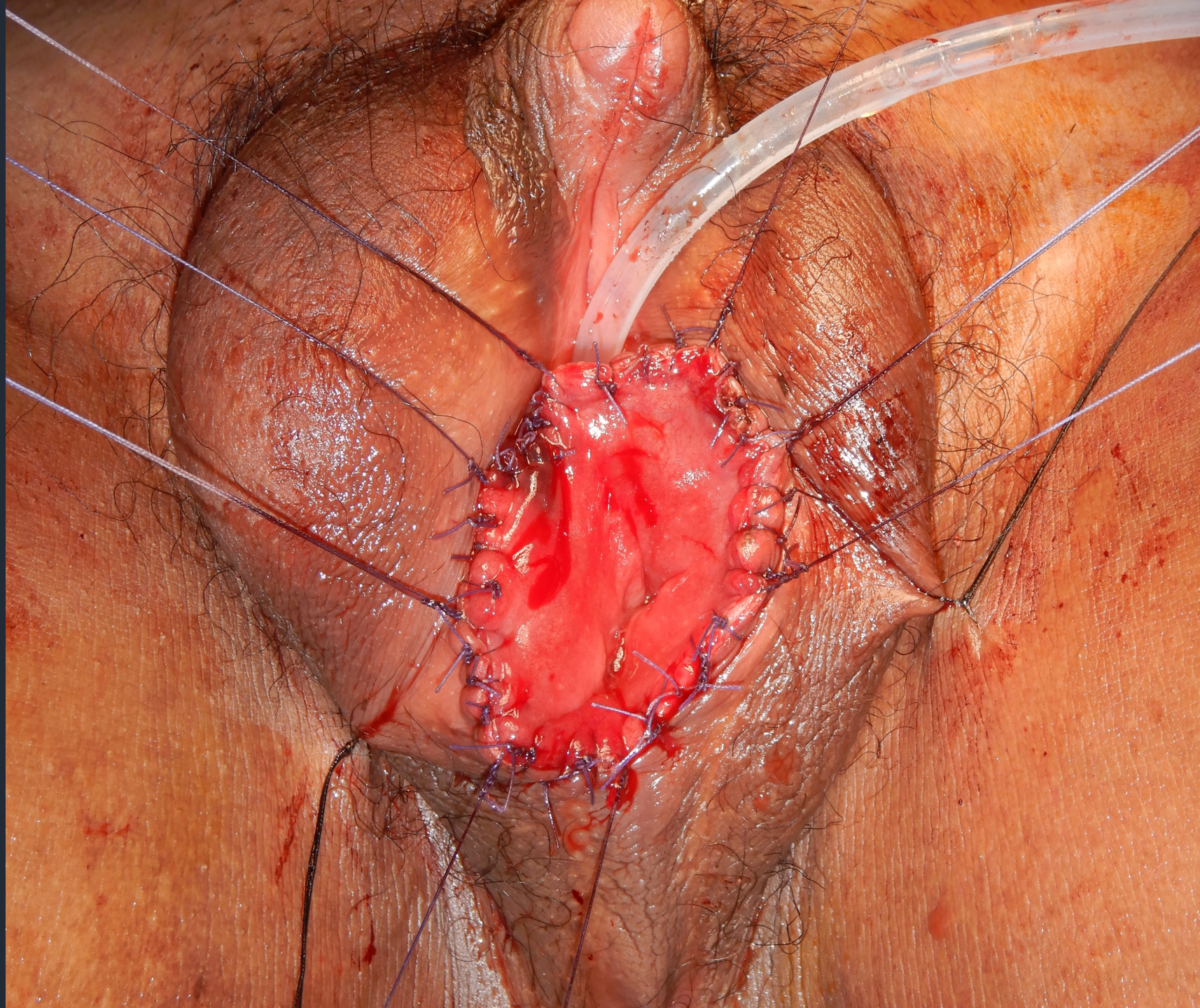
1. No surgery
2. Vaginoplasty
3. Genitoplasty
4. Gonadectomy
5. 2, 3 & 4
6. Other plan

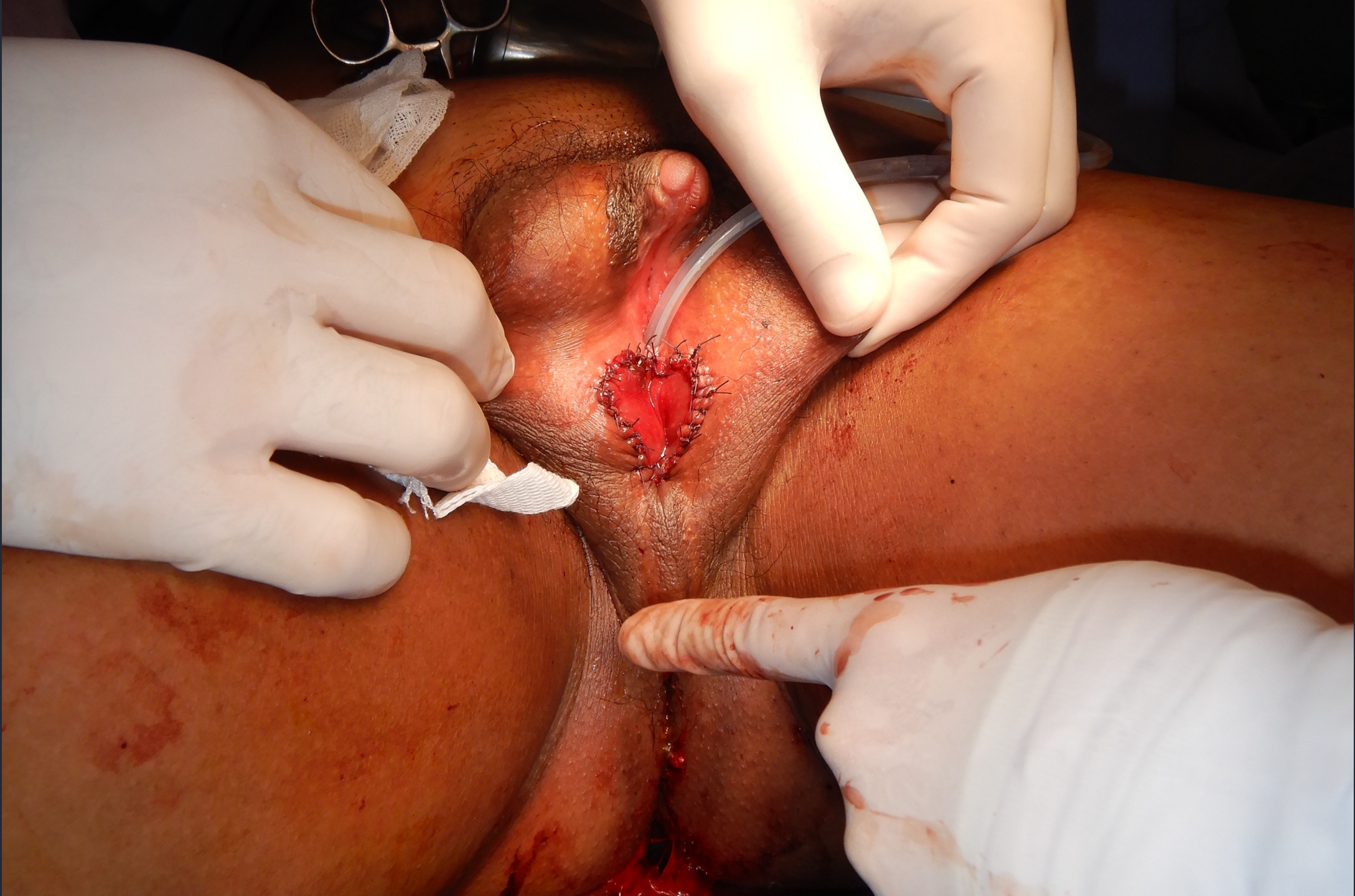

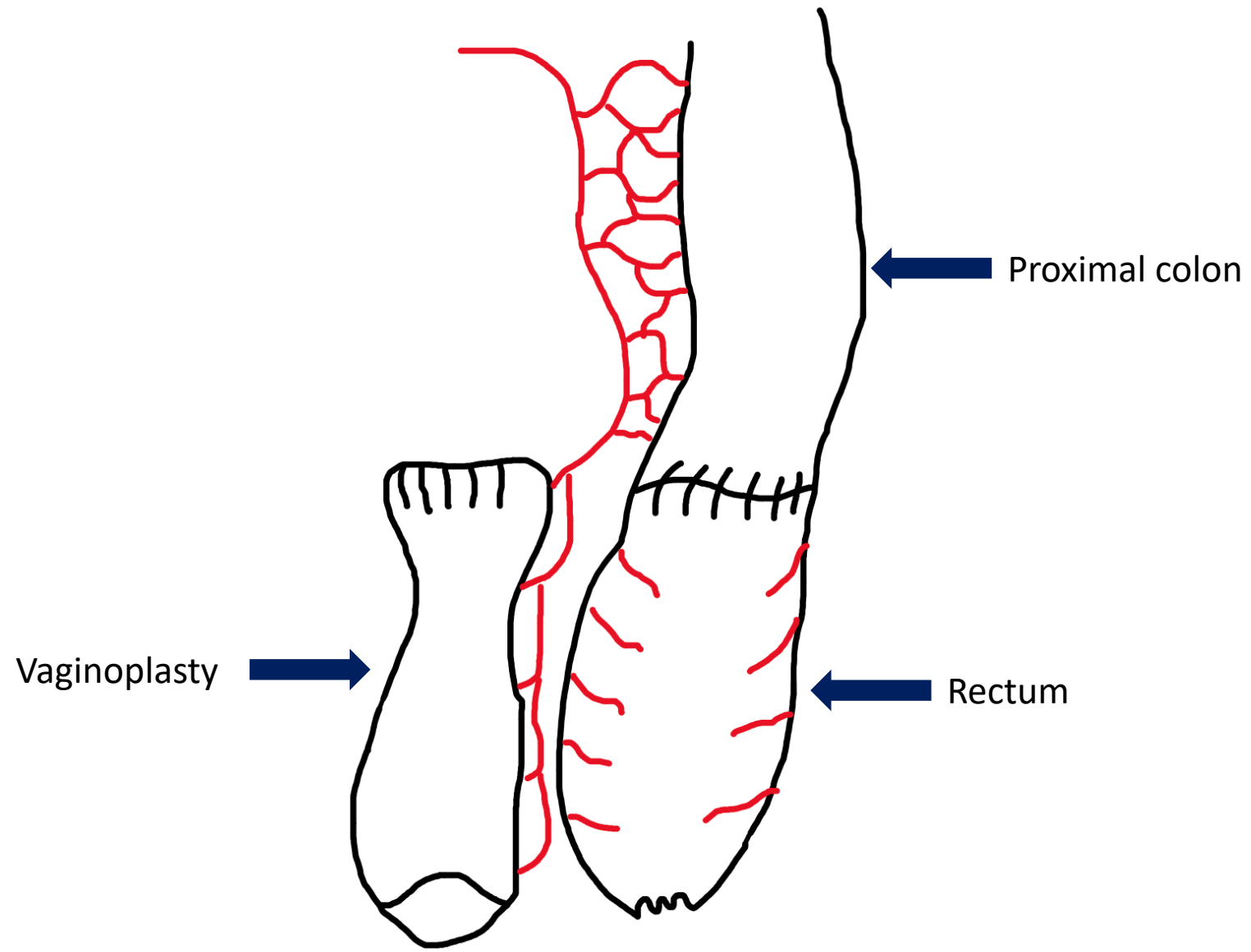







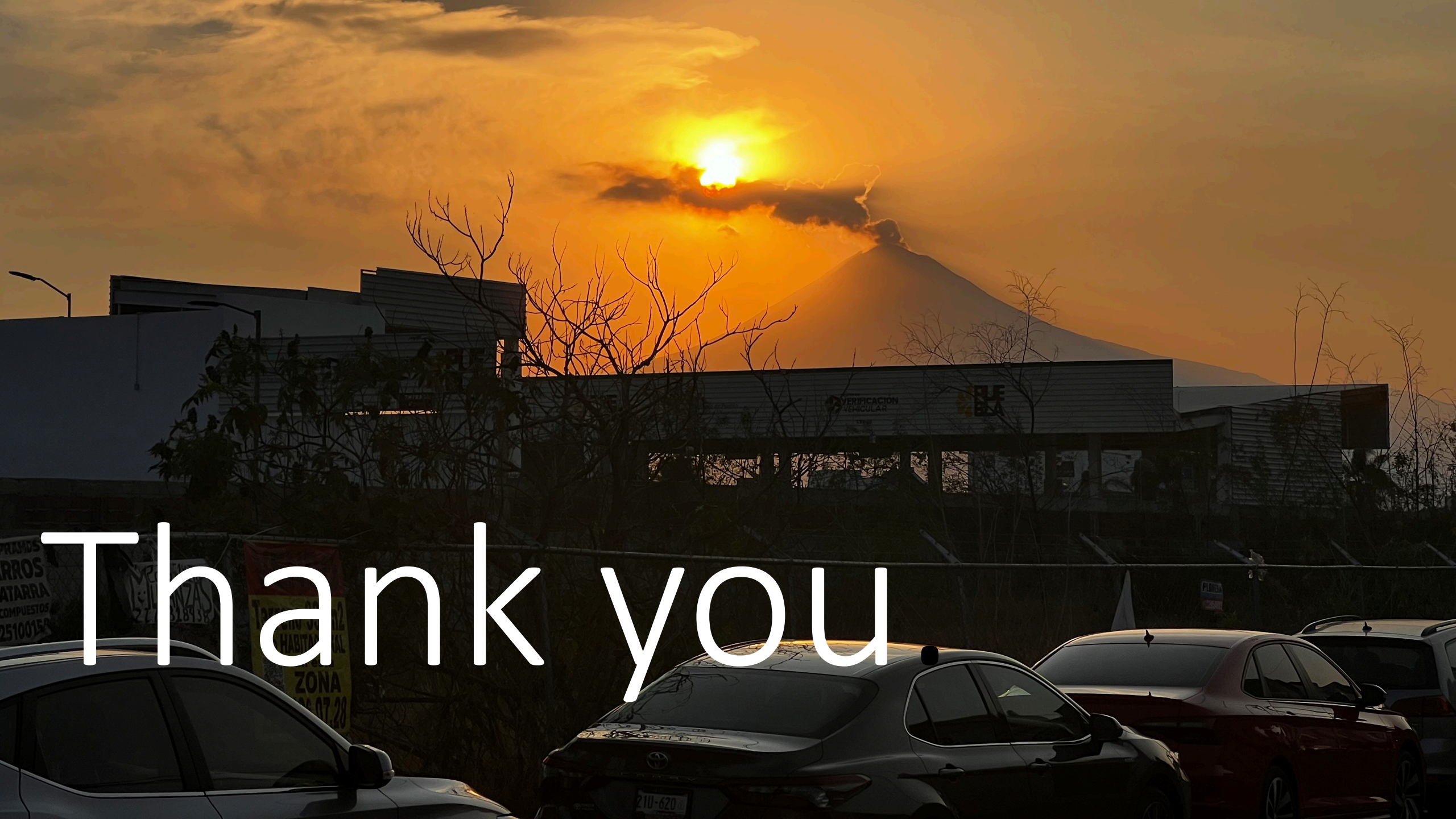




Do you treat patients with DSD?

1. Yes
2. No



Thank you