

# **COMPLEX CLOACAL MALFORMATION**

**SARRA AGGOUN, MD**

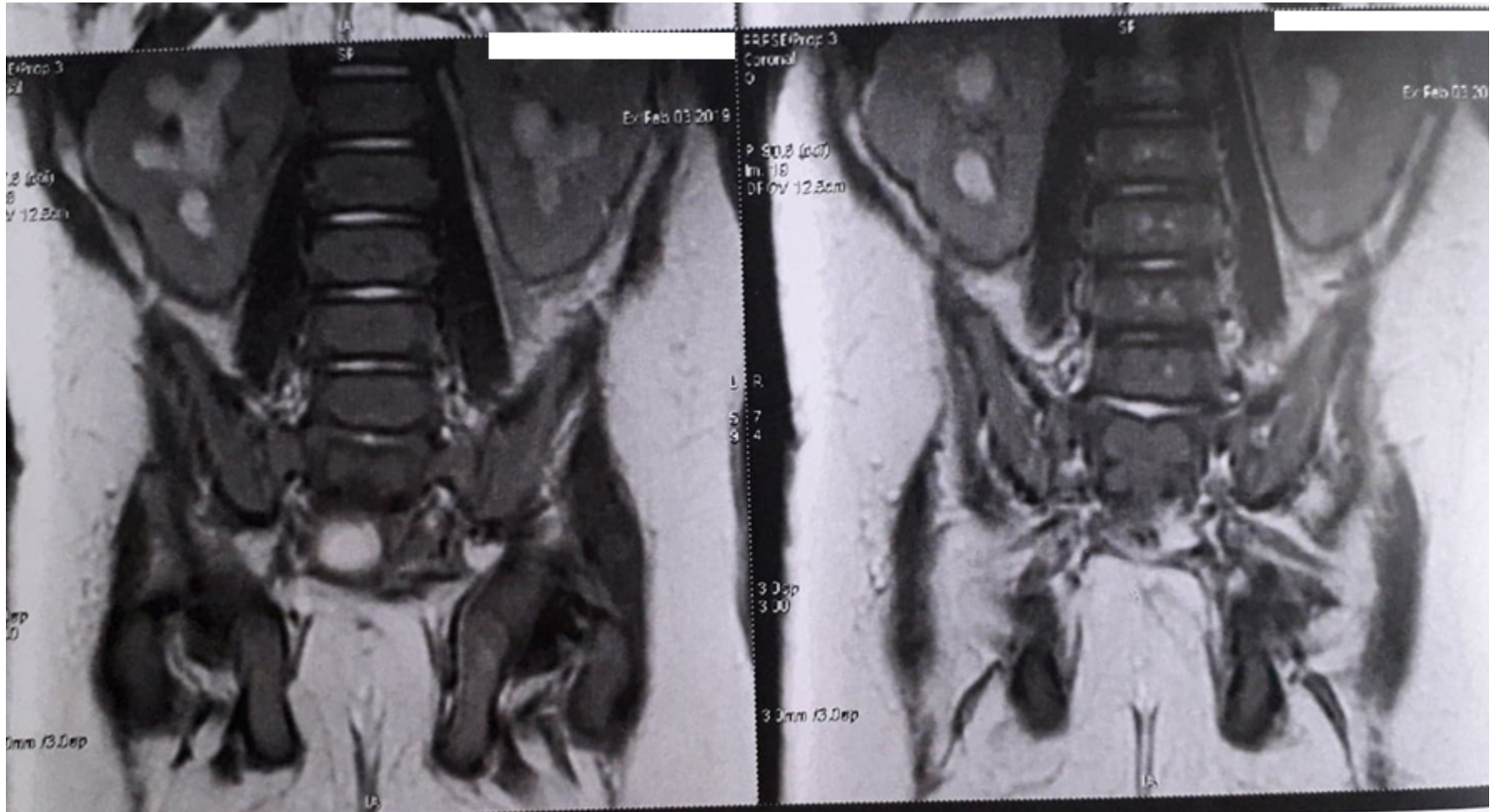
- 2-day-old female was admitted with bilious emesis, abdominal distention, and failure to pass meconium.
- Birth weight was 3.5 kg
- Physical examination = single perineal opening

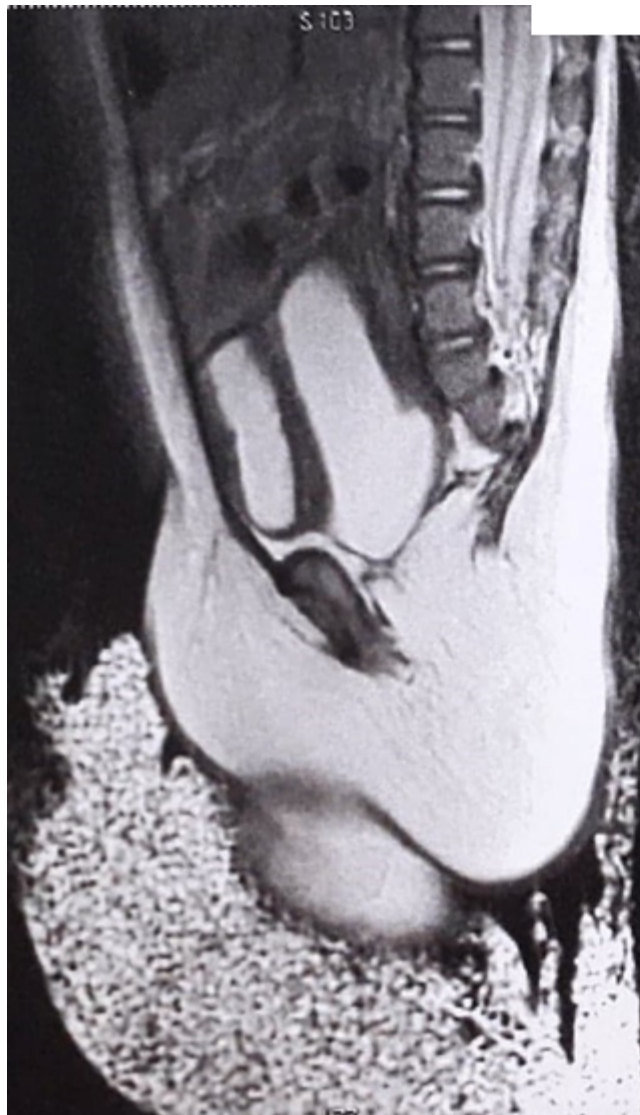- She underwent diverting colostomy, cystostomy and hydrocolpos drainage.

- Post operatively, baby developed cyanosis of extremities and required oxygen.
- Echocardiogram was done and she was diagnosed with Tetralogy of Fallot.

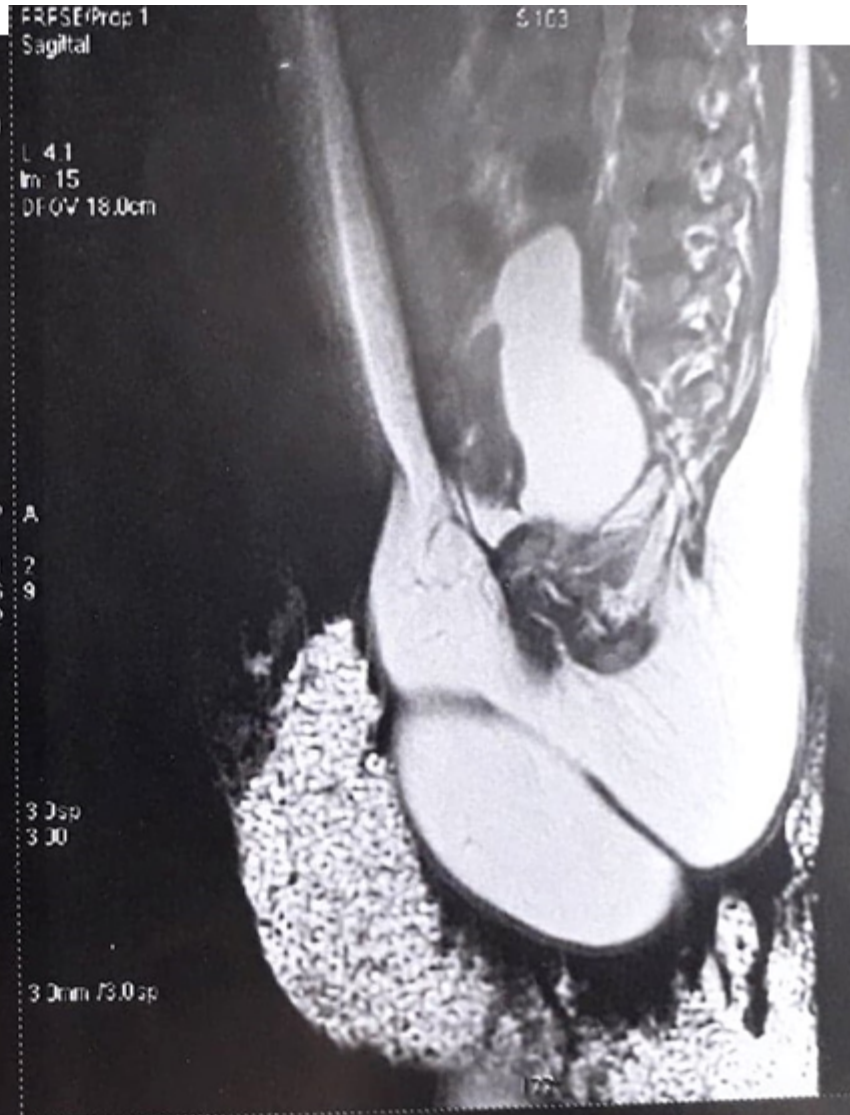- The patient was referred to the pediatric cardiovascular surgery department, but surgery was postponed until correction of anorectal malformation.

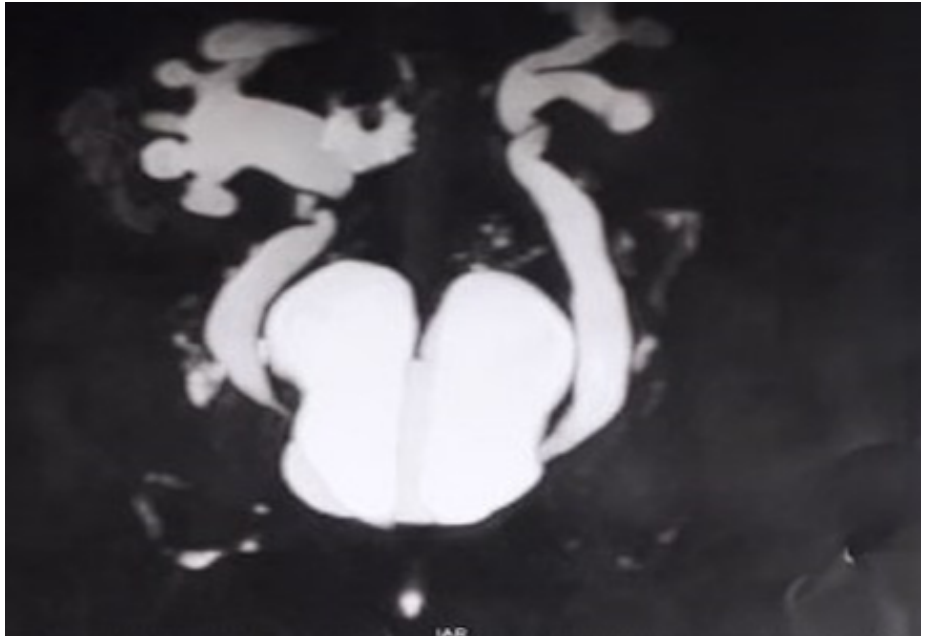
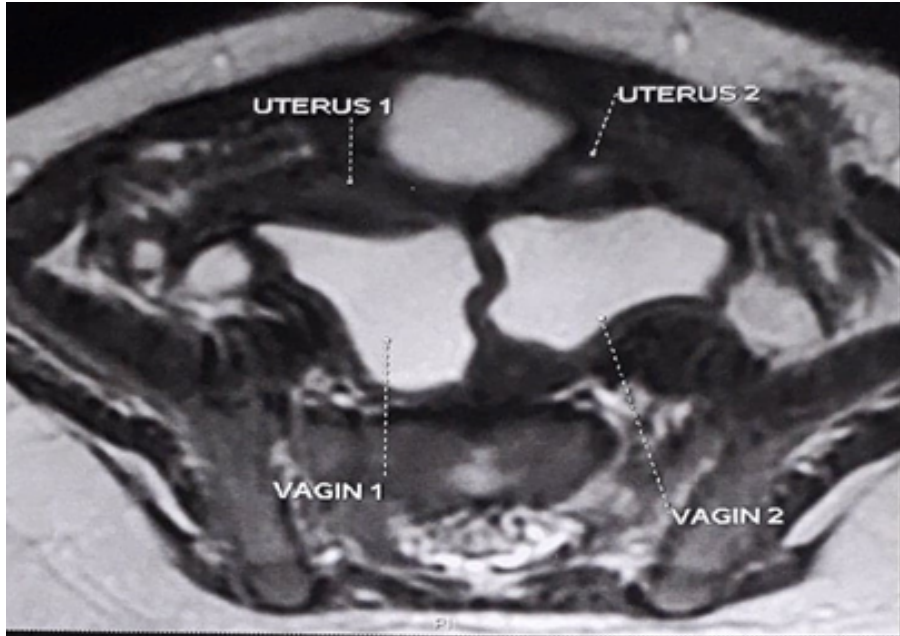
# MRI RESULTS



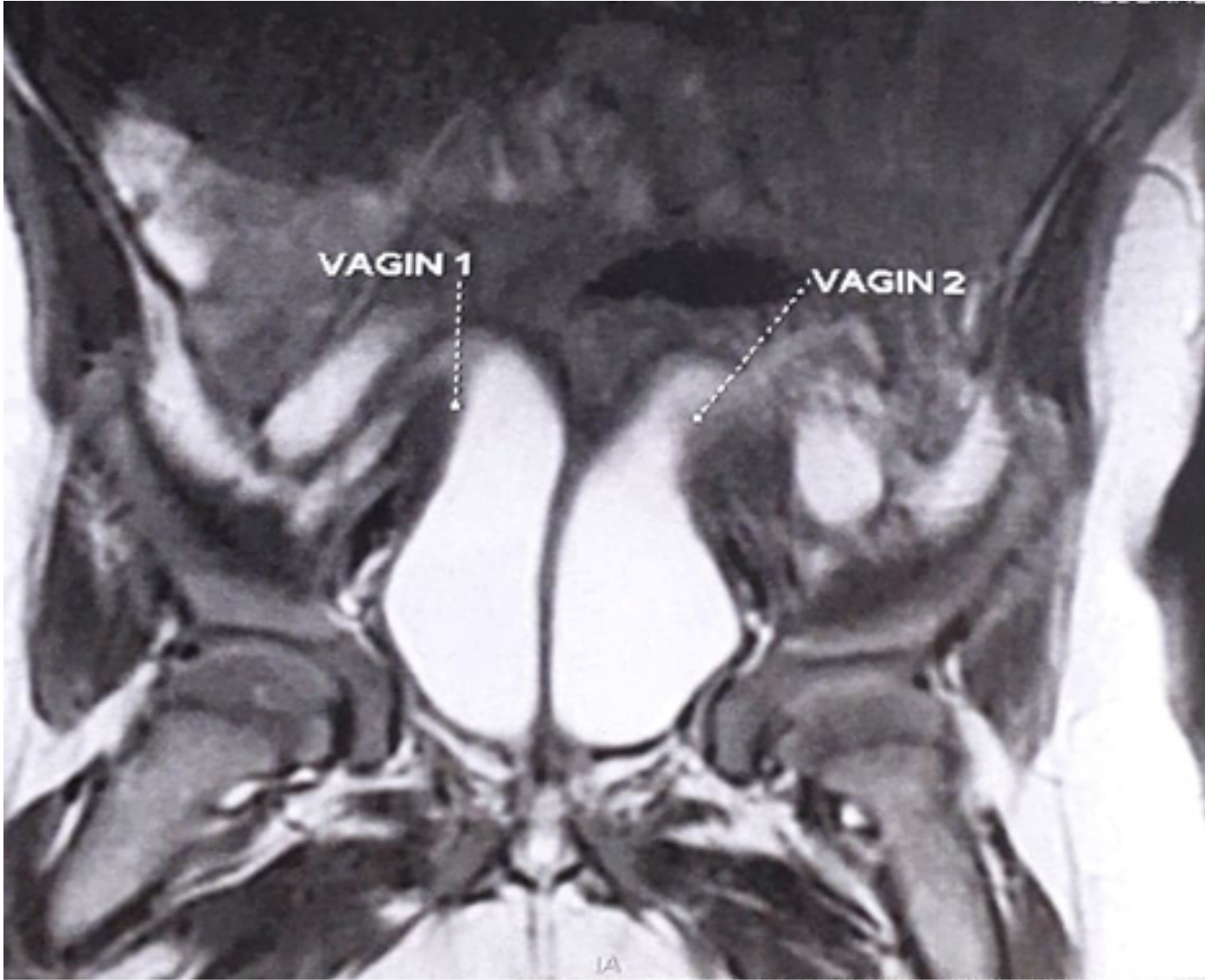


Ex: Feb 03 2019









- **WHAT WOULD BE THE SURGICAL STRATEGY FOR THIS PATIENT?**

- **THANK YOU**