



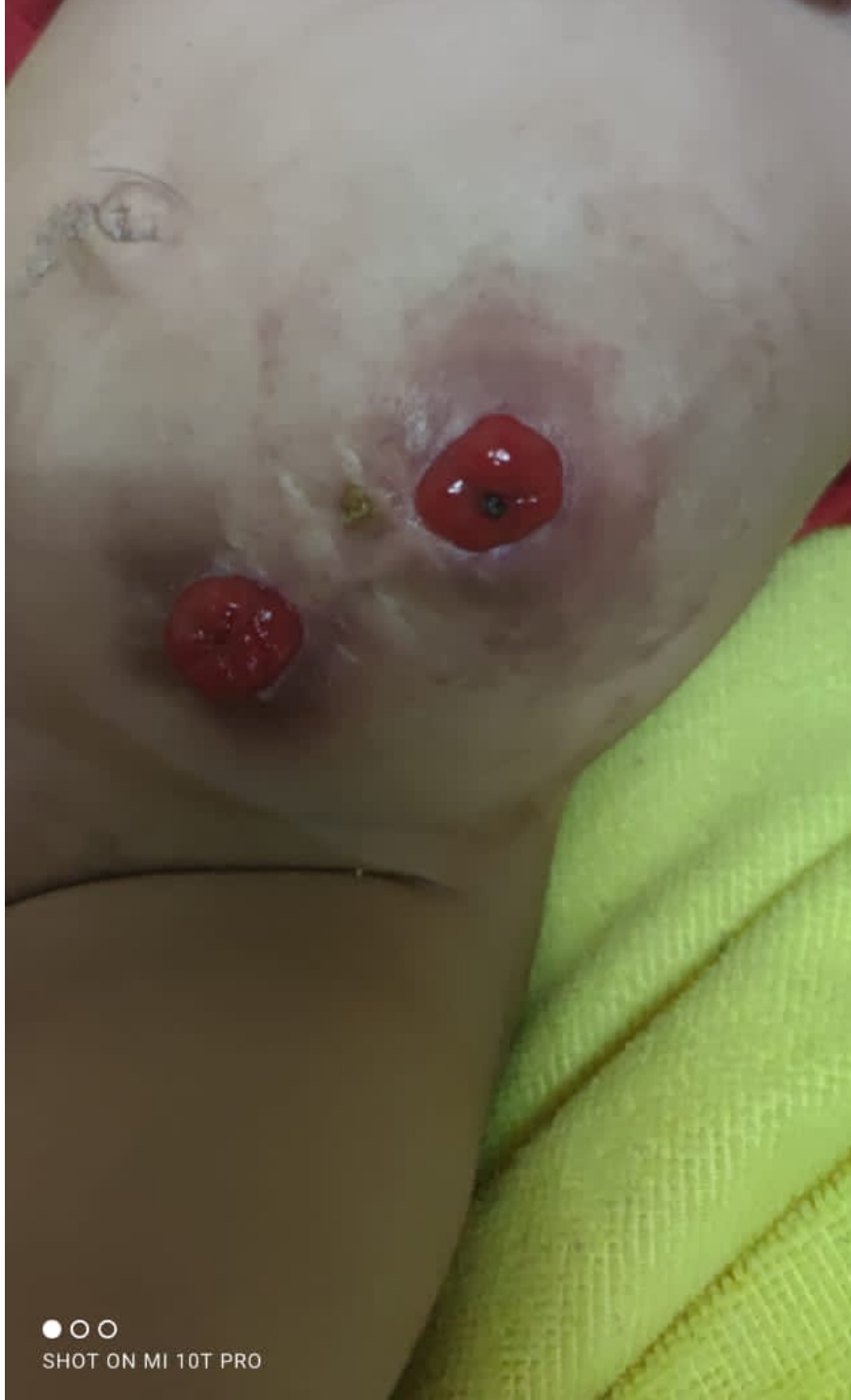Anorectal malformation with an uncommon preoperative complication

Puebla, México.

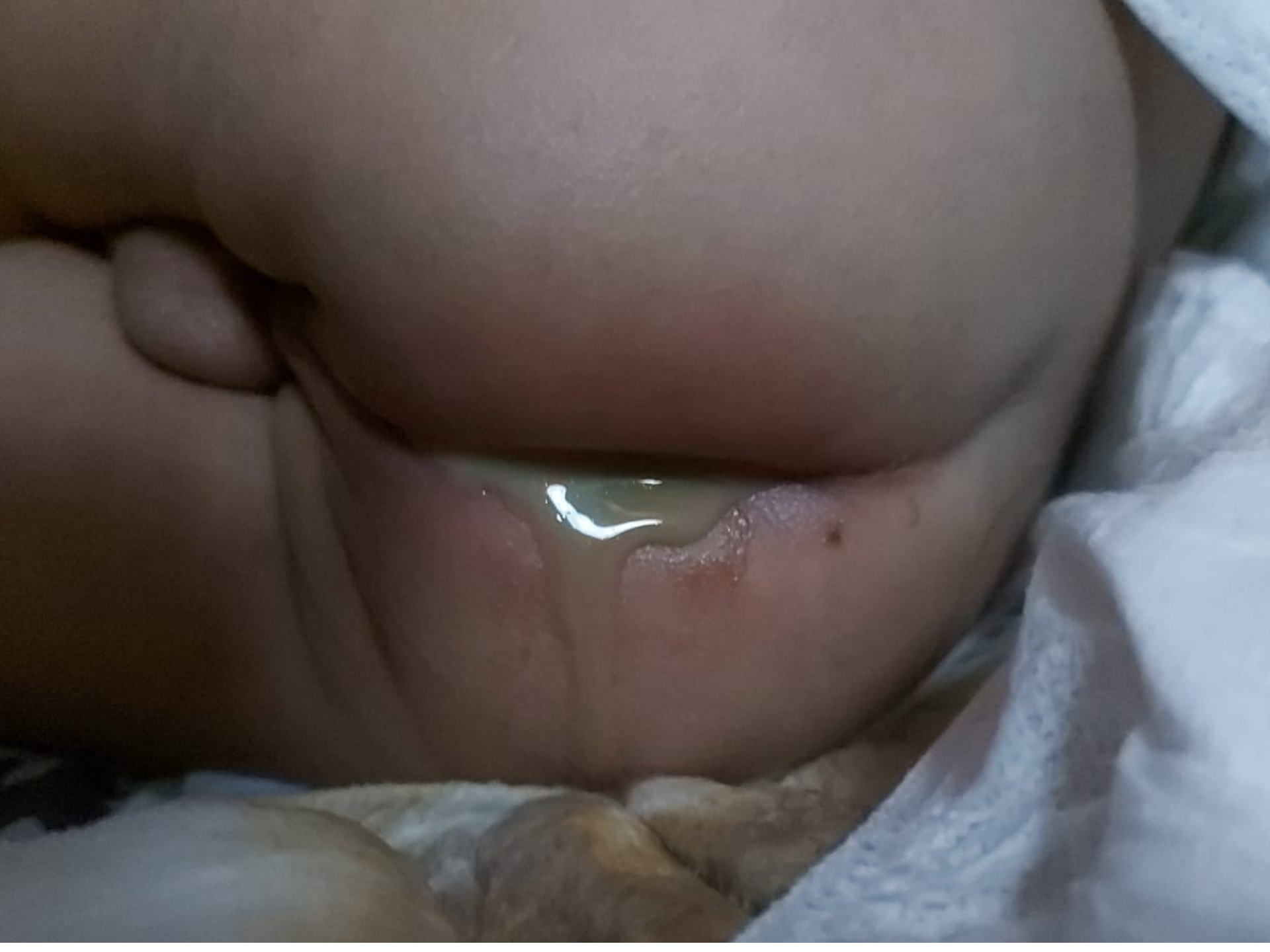Dra. María Zornoza

Dr. José Alejandro Ruíz

- Male, 9 months old.
- Anorectal malformation without fistula.
- Colostomy at birth.



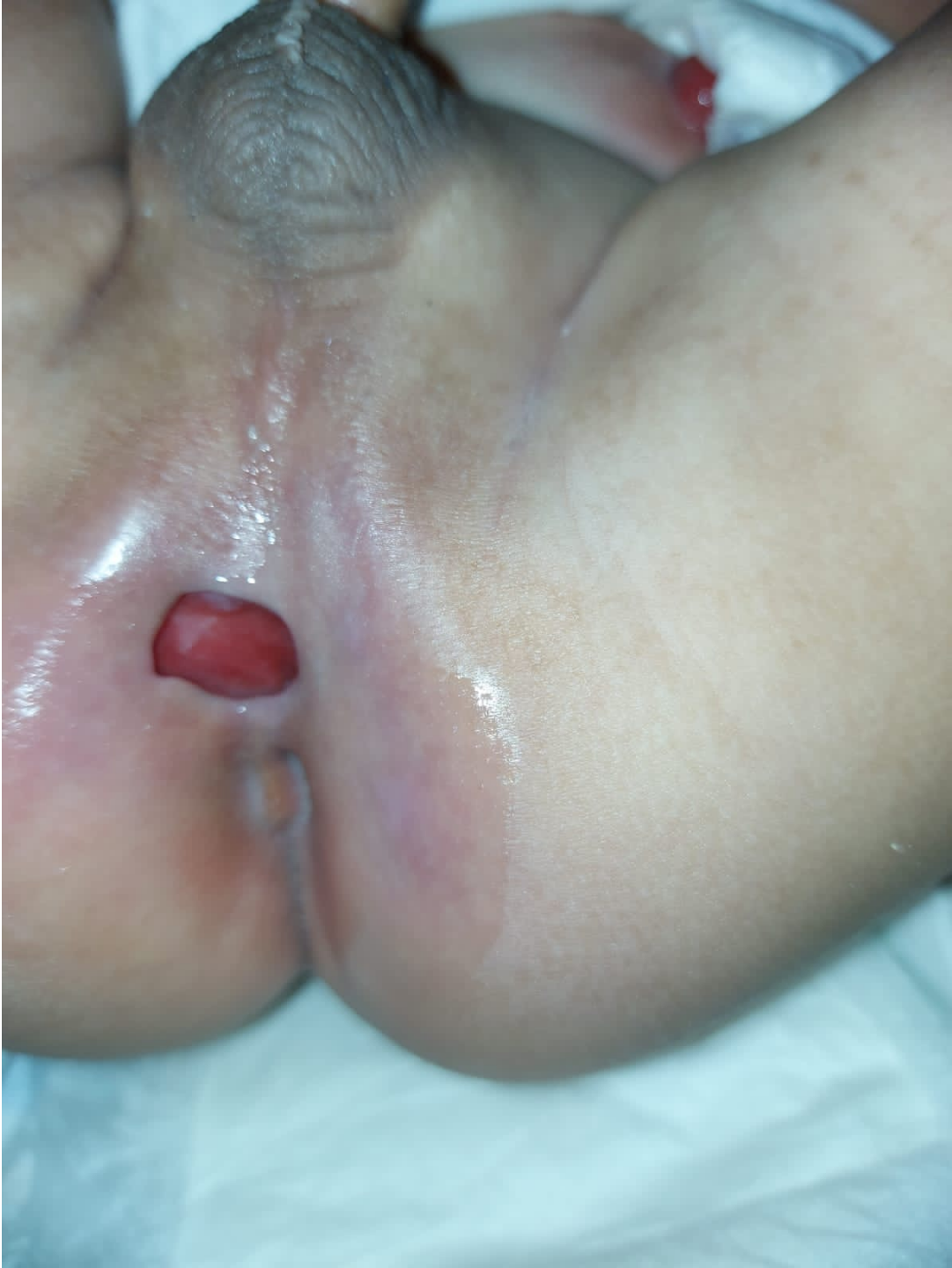SHOT ON MI 10T PRO





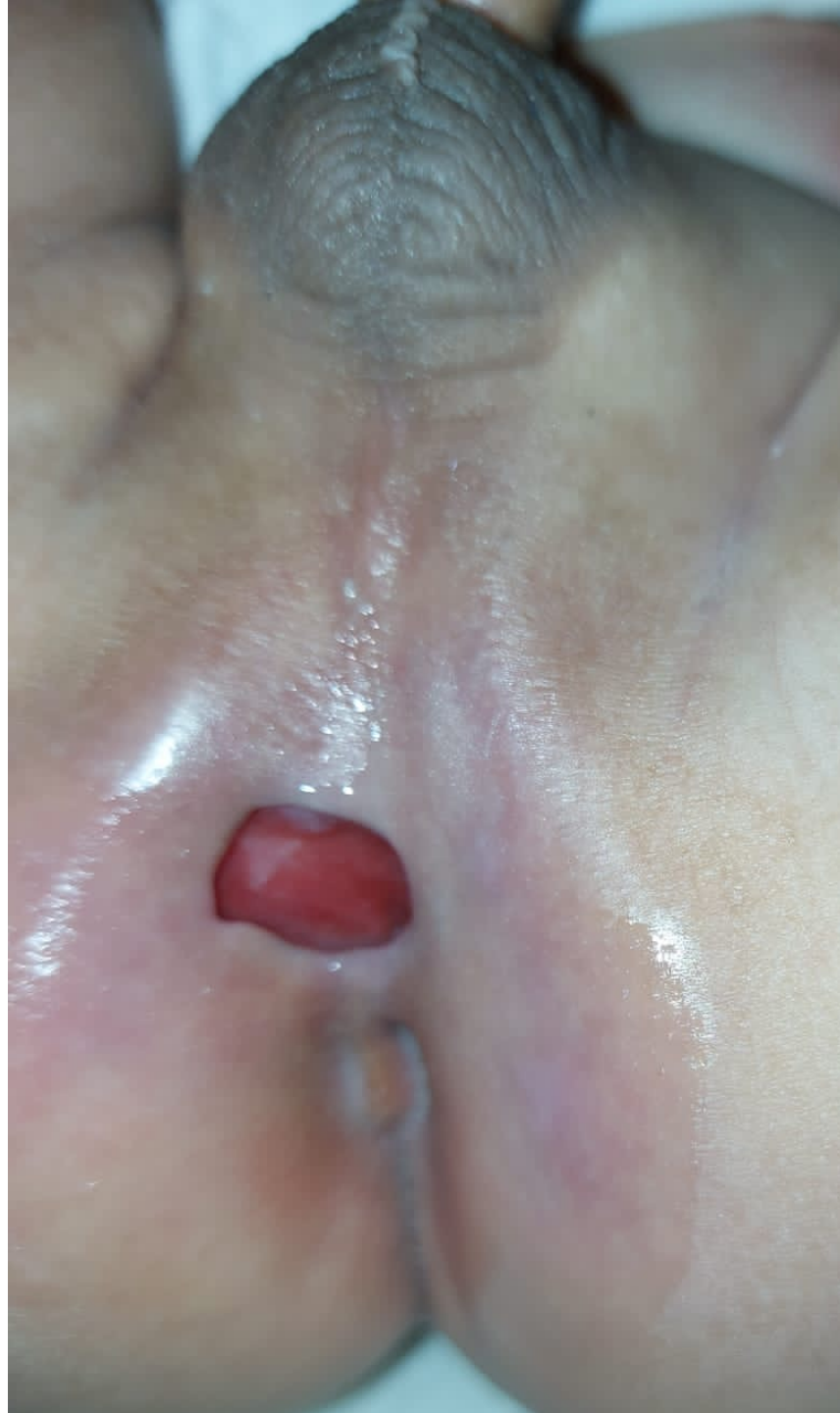Based on the image and video, what is your recommendation?

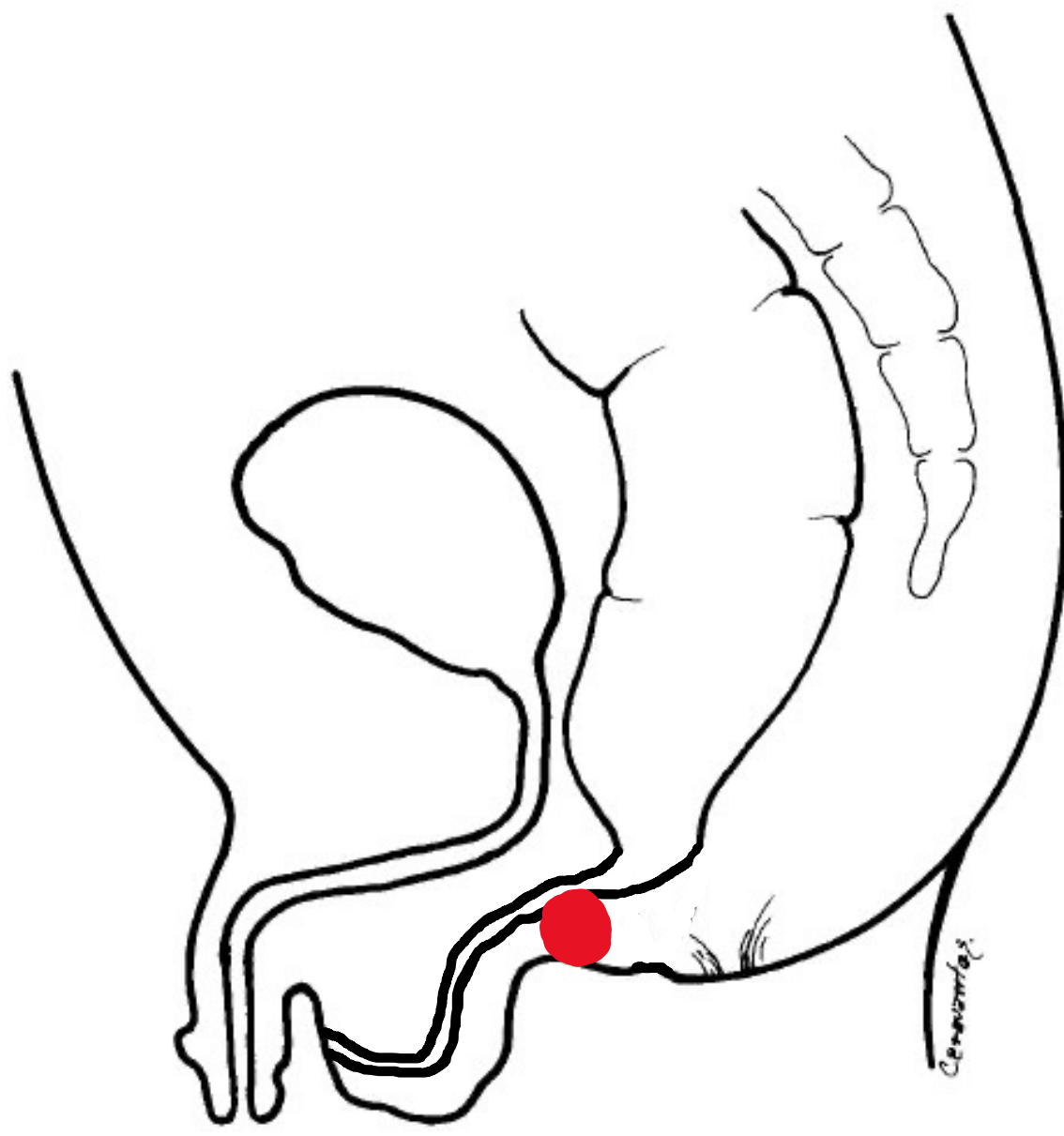
1. Clean the area and take a picture
2. Send the patient to emergency
3. Start antibiotics
4. Admit the patient to the hospital
5. None of the above

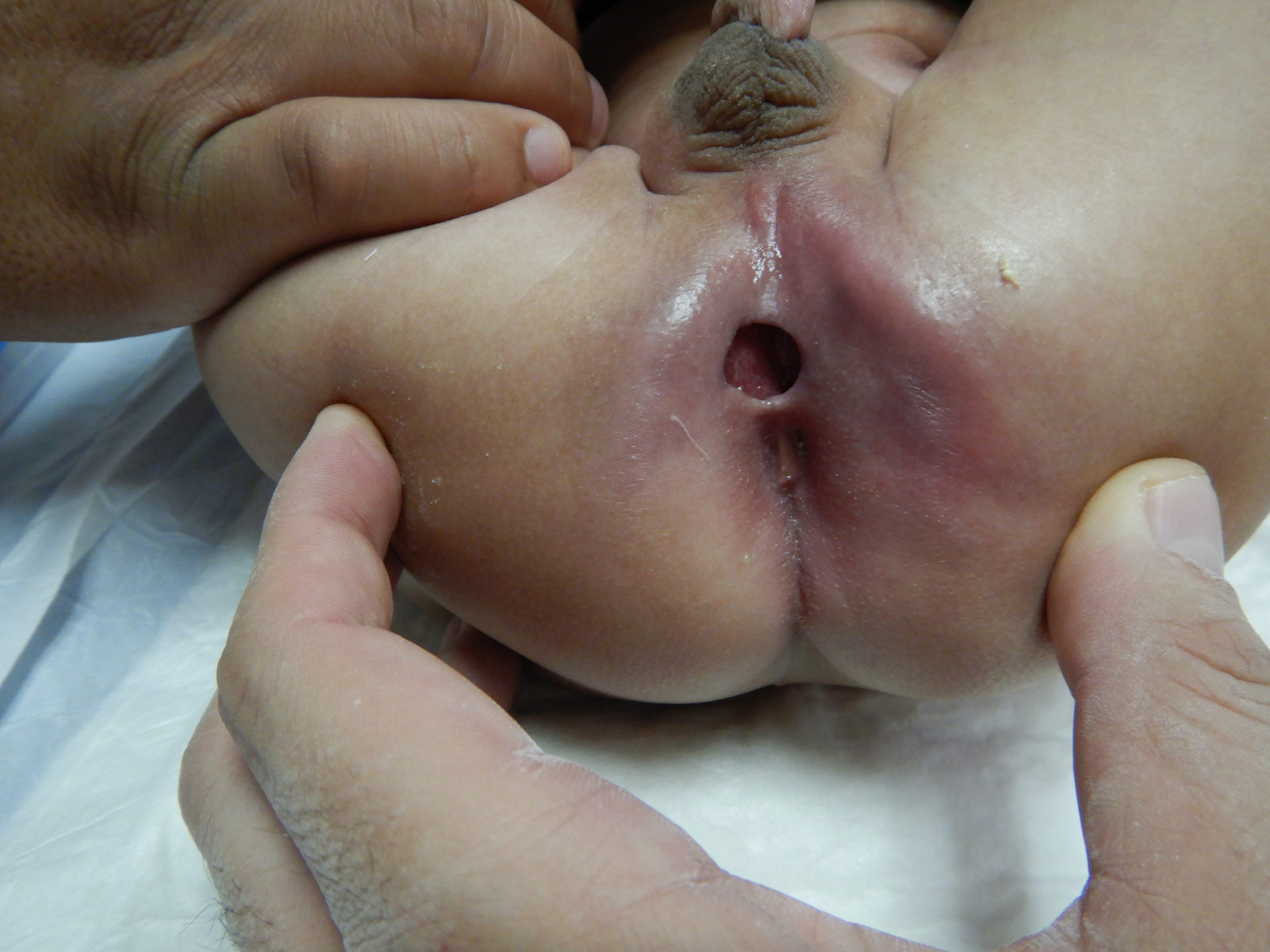

What is your diagnosis?

1. ARM with fistula
2. ARM without fistula
3. Fournier gangrene
4. I don't know







ID: Unknown
Sex: Male

CISTOGRAFIA

N

IMAGEN= 01

CISTOGRAFIA

Study ID: 0

Acq: 4/08/2021

Acq: 12:01:06.000000

500 pix

Frame: [1] 1 / 53

Zoom: 62.35%

WindowLevel: 255/127

Pixel: No value - Outside image

RF (1024x1024)

12:01:06

04-AGO-21

RAYOS X VIAZCAN

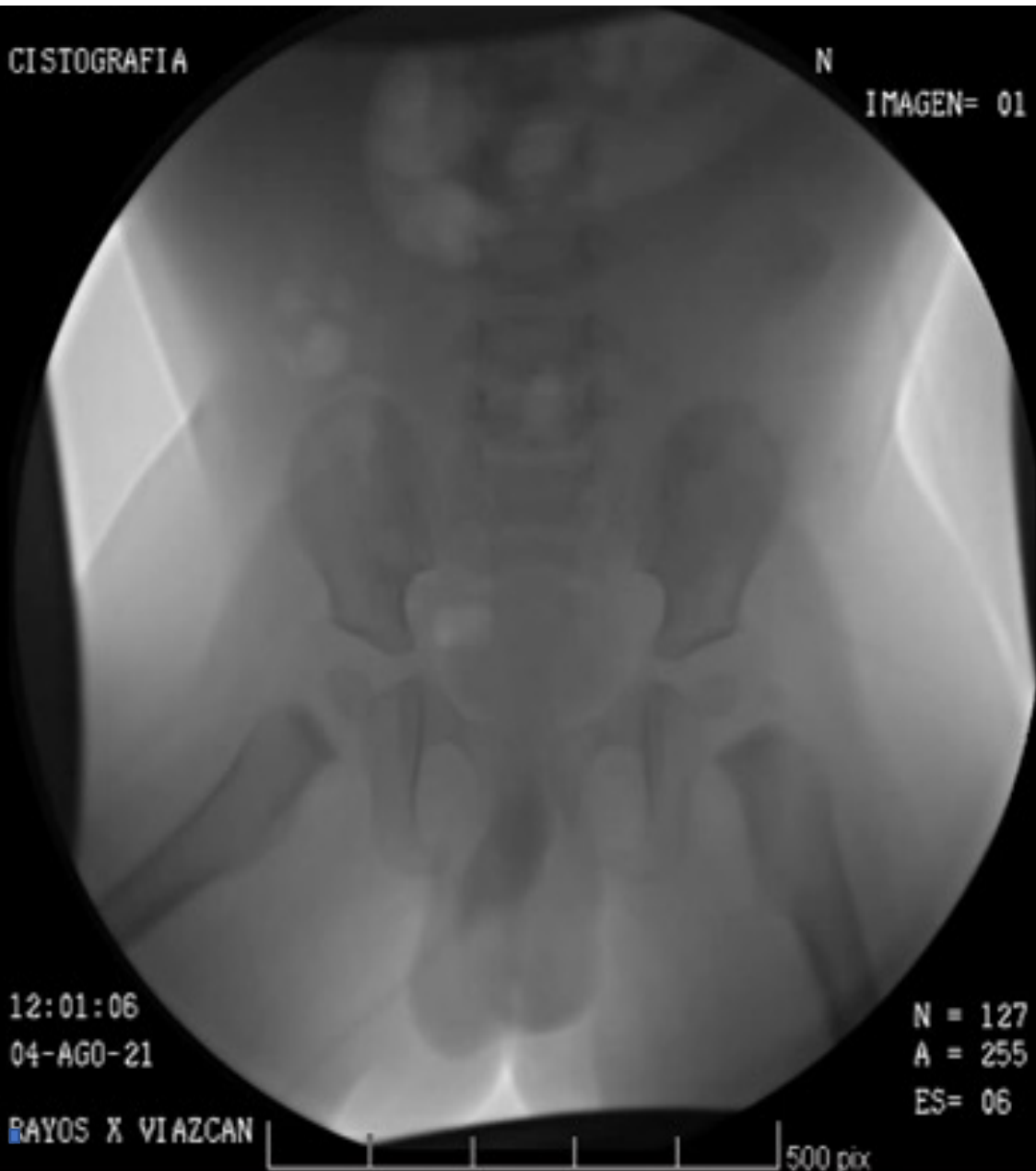N = 127

A = 255

ES= 06

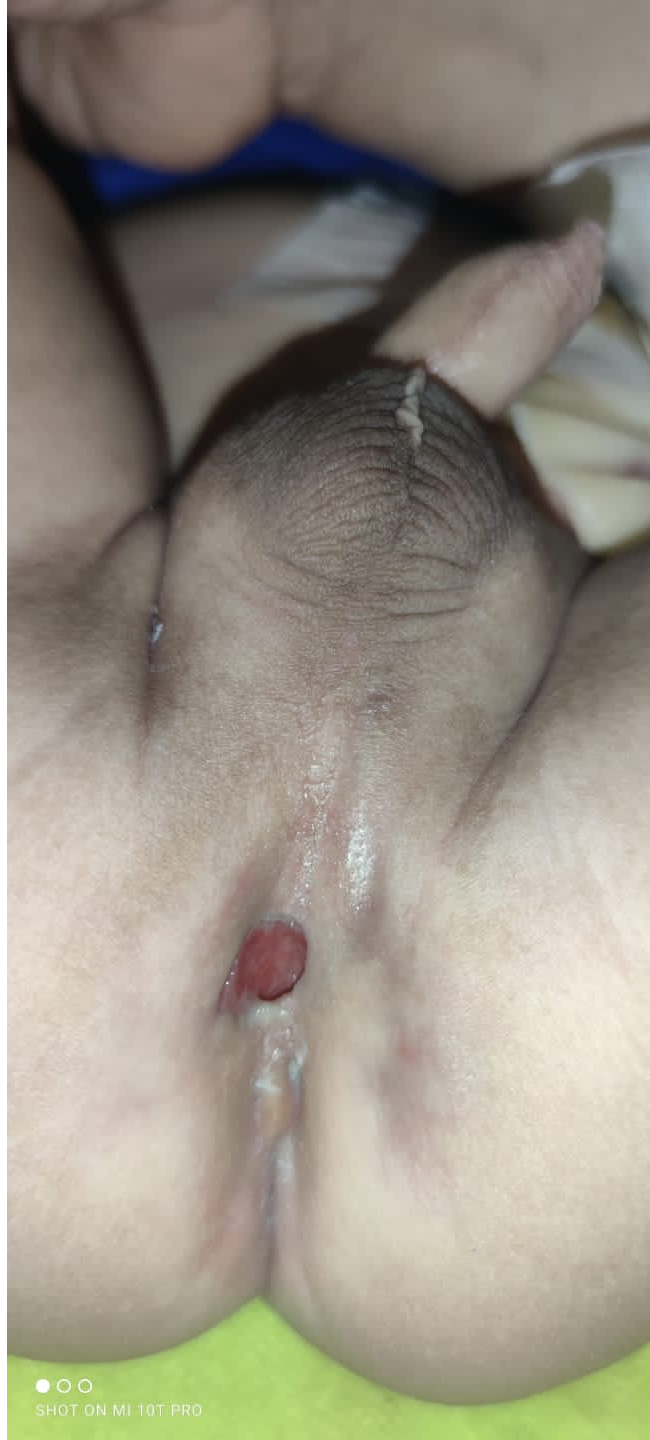500 pix

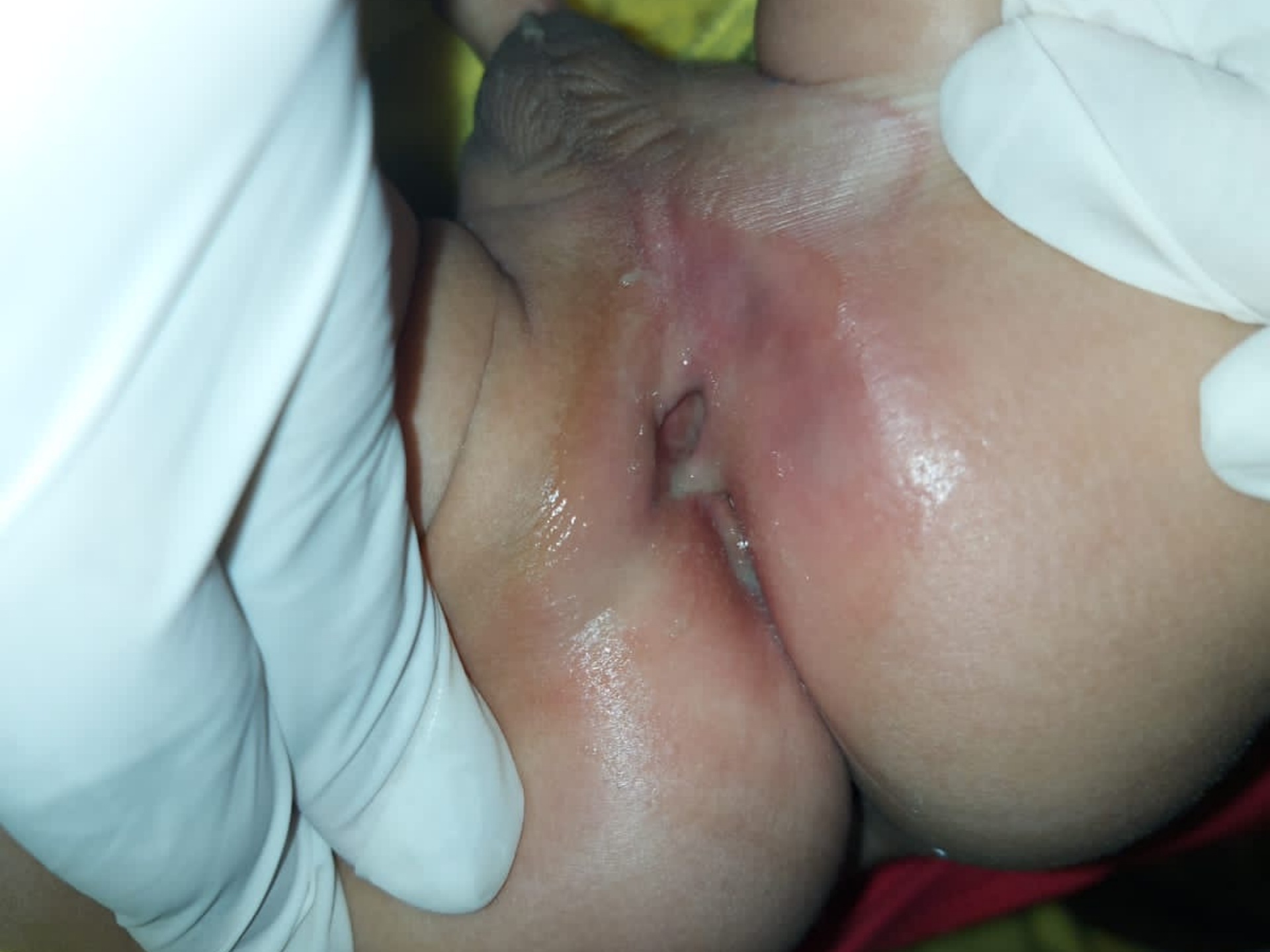Series Nb: 1

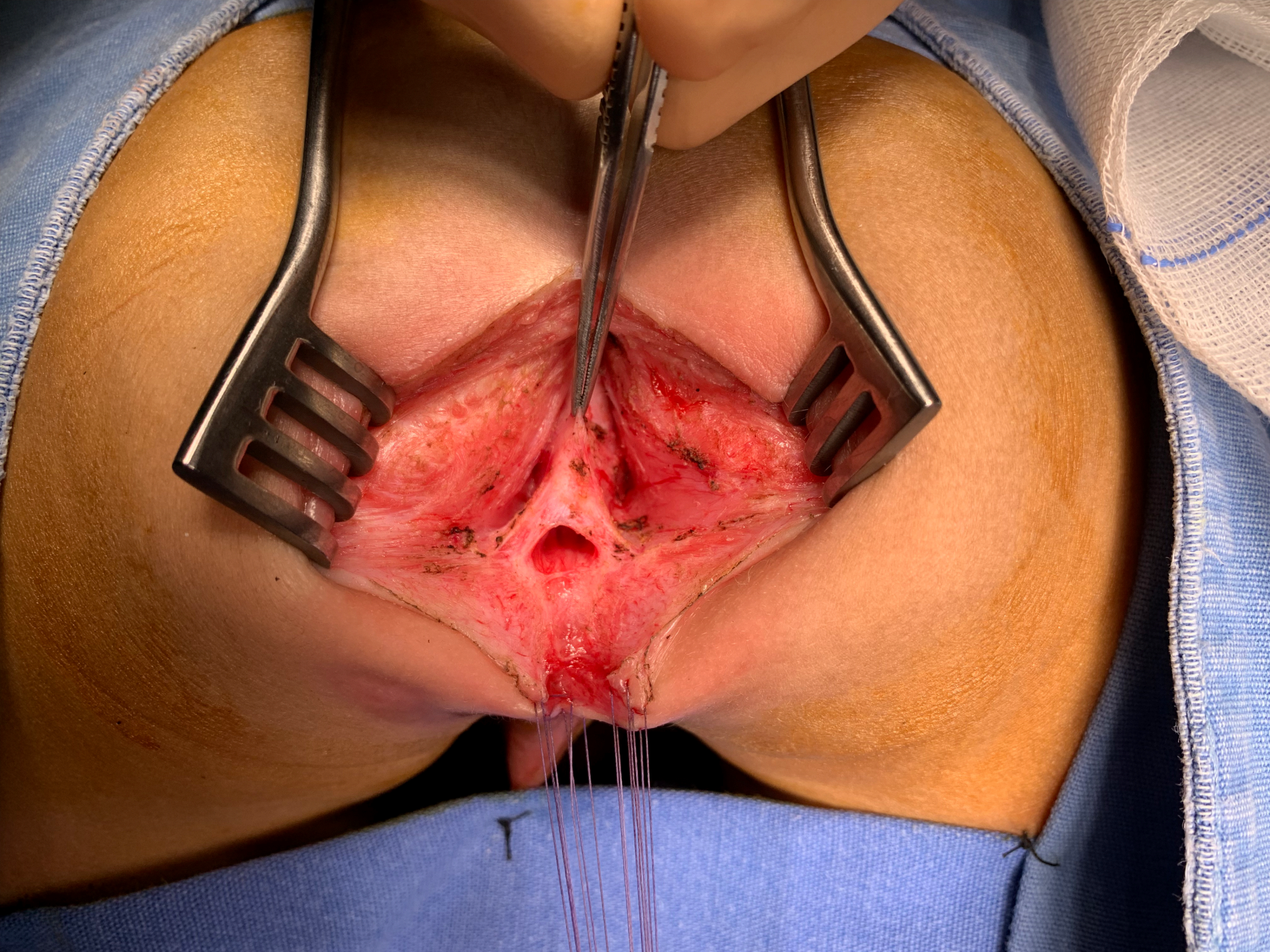


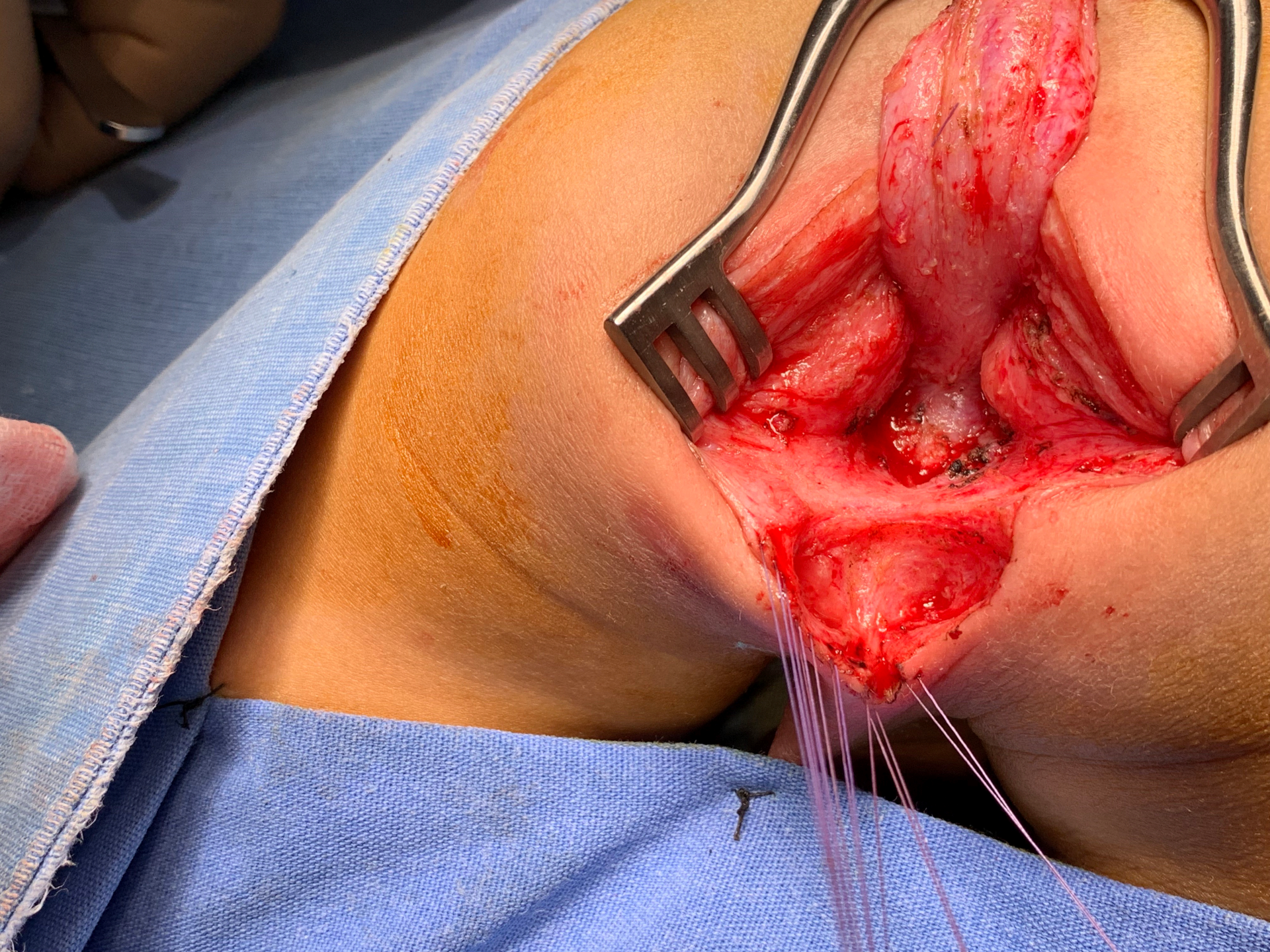
With this clinical picture and distal colostogram, what is your recommendation?

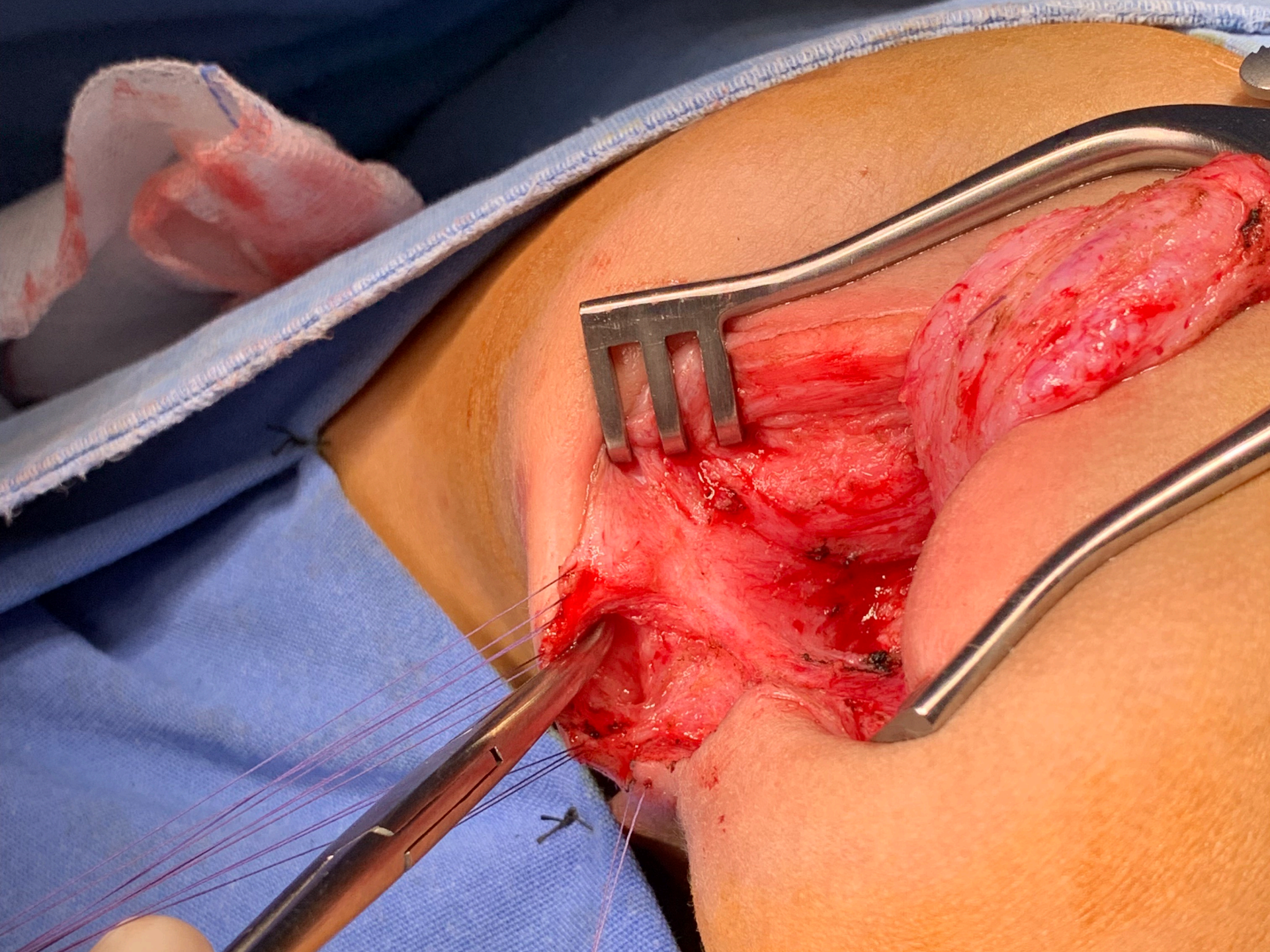
1. Start irrigations and antibiotics
2. Take the patient to OR for a clean out
3. Local treatment
4. Take the patient to OR for PSARP and repair the recto-urethral fistula
5. I don't know

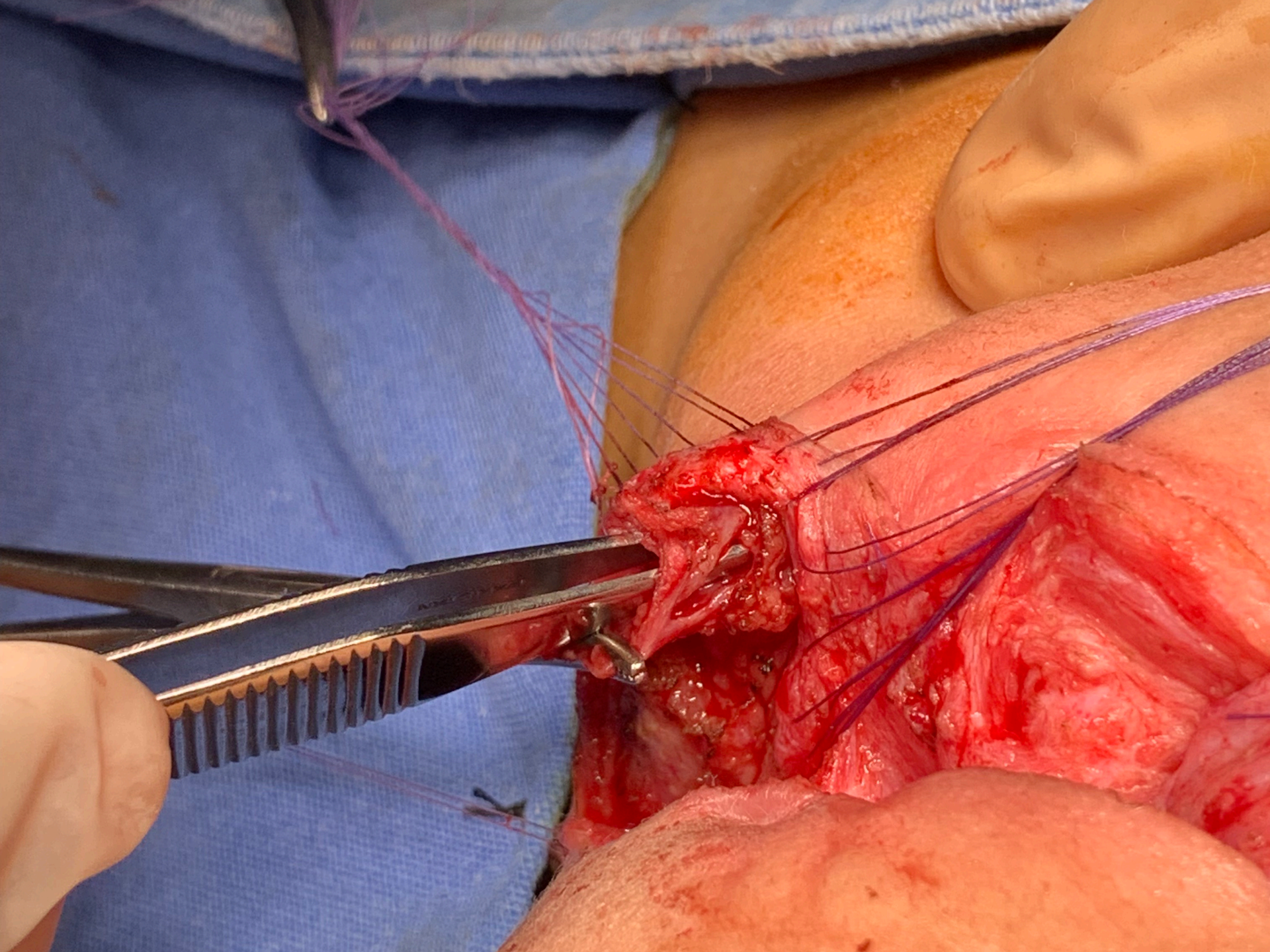


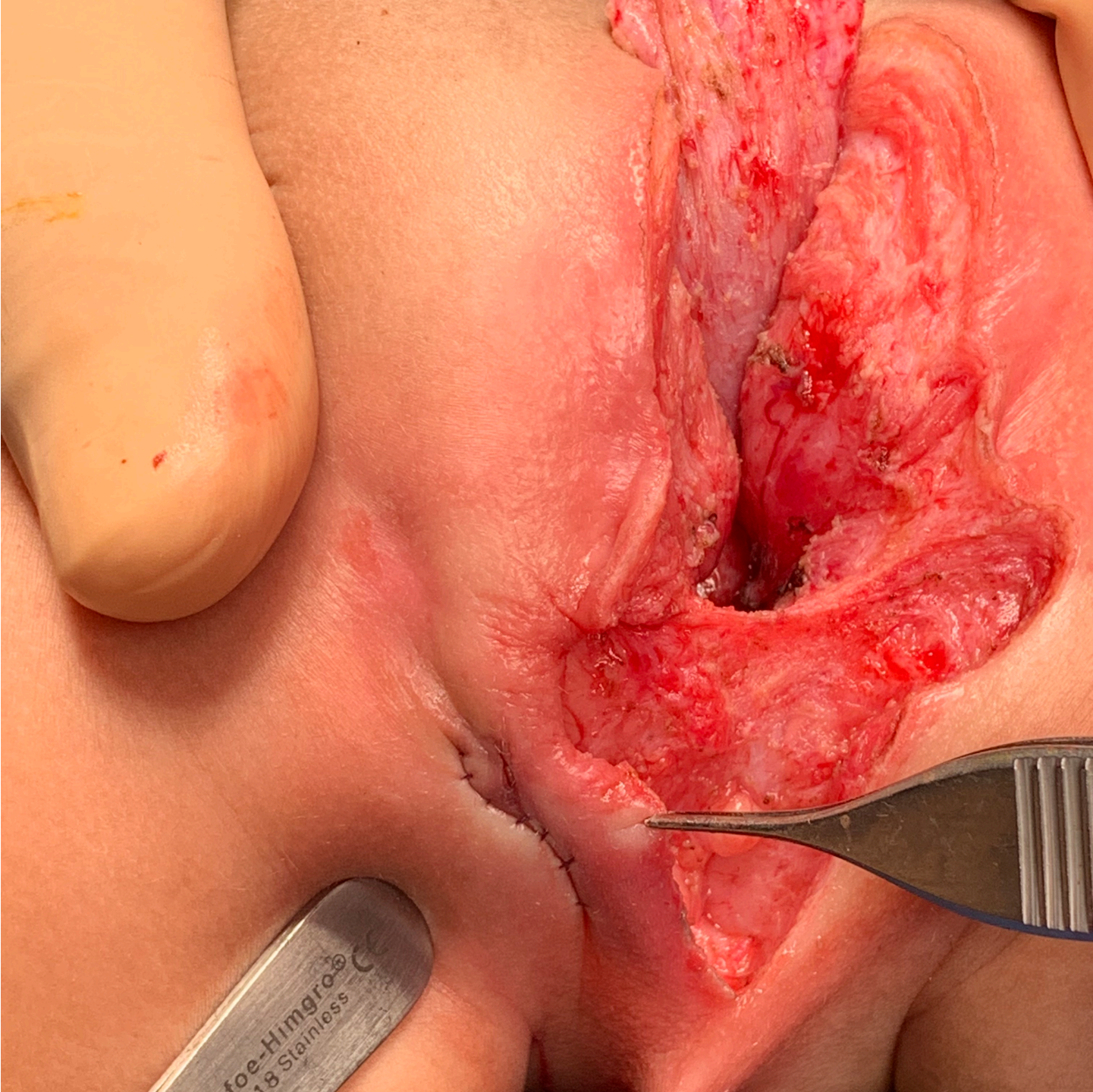


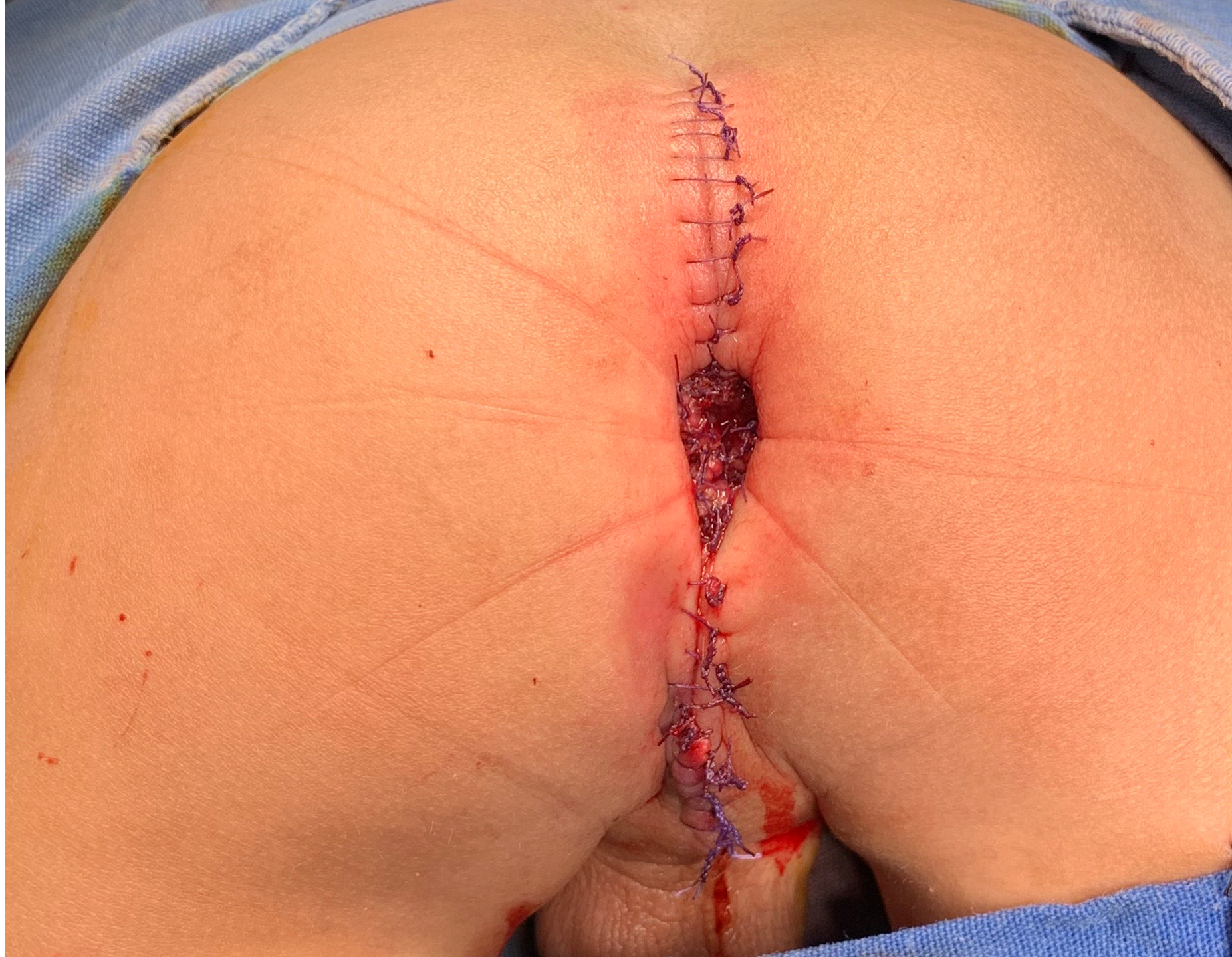


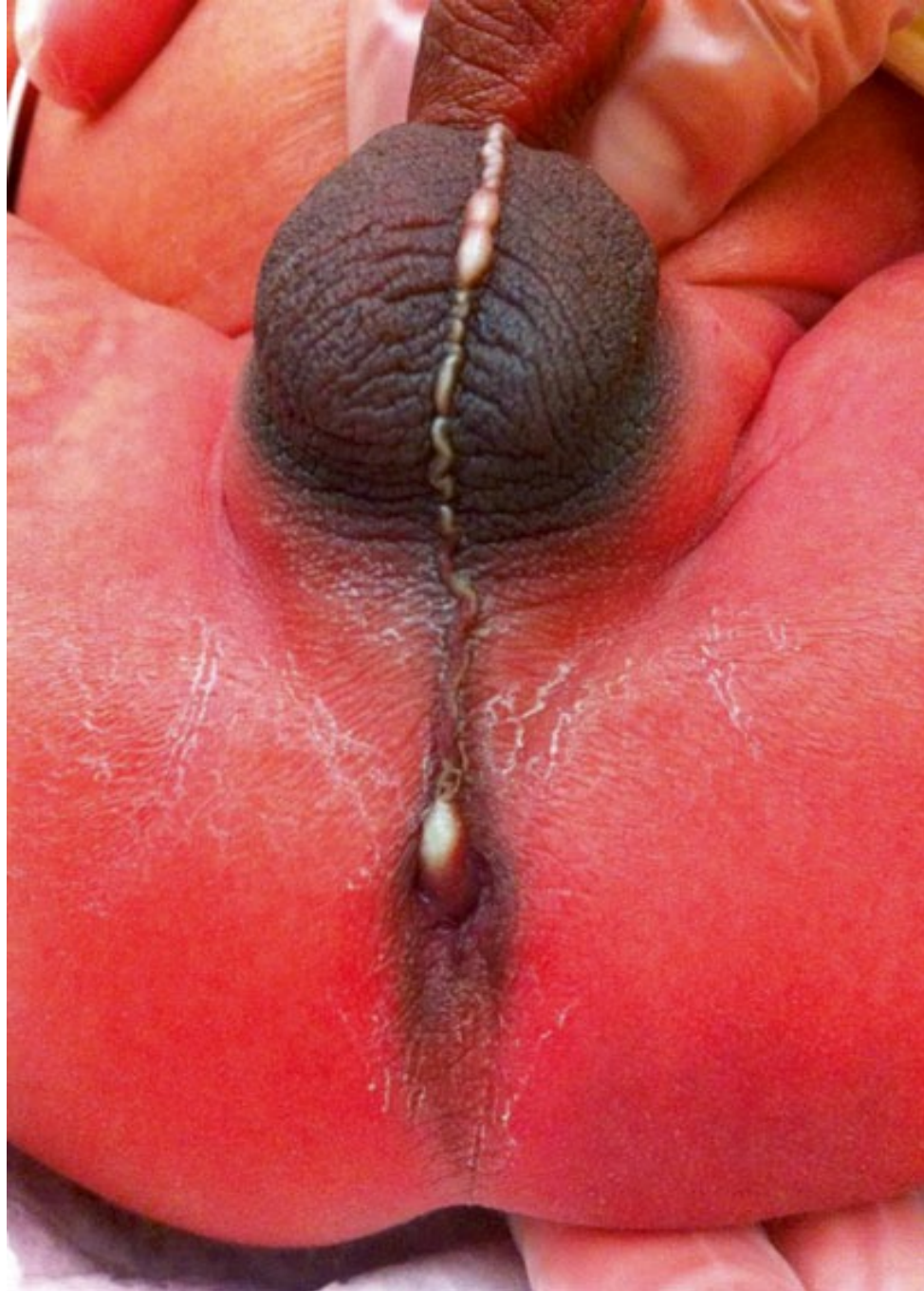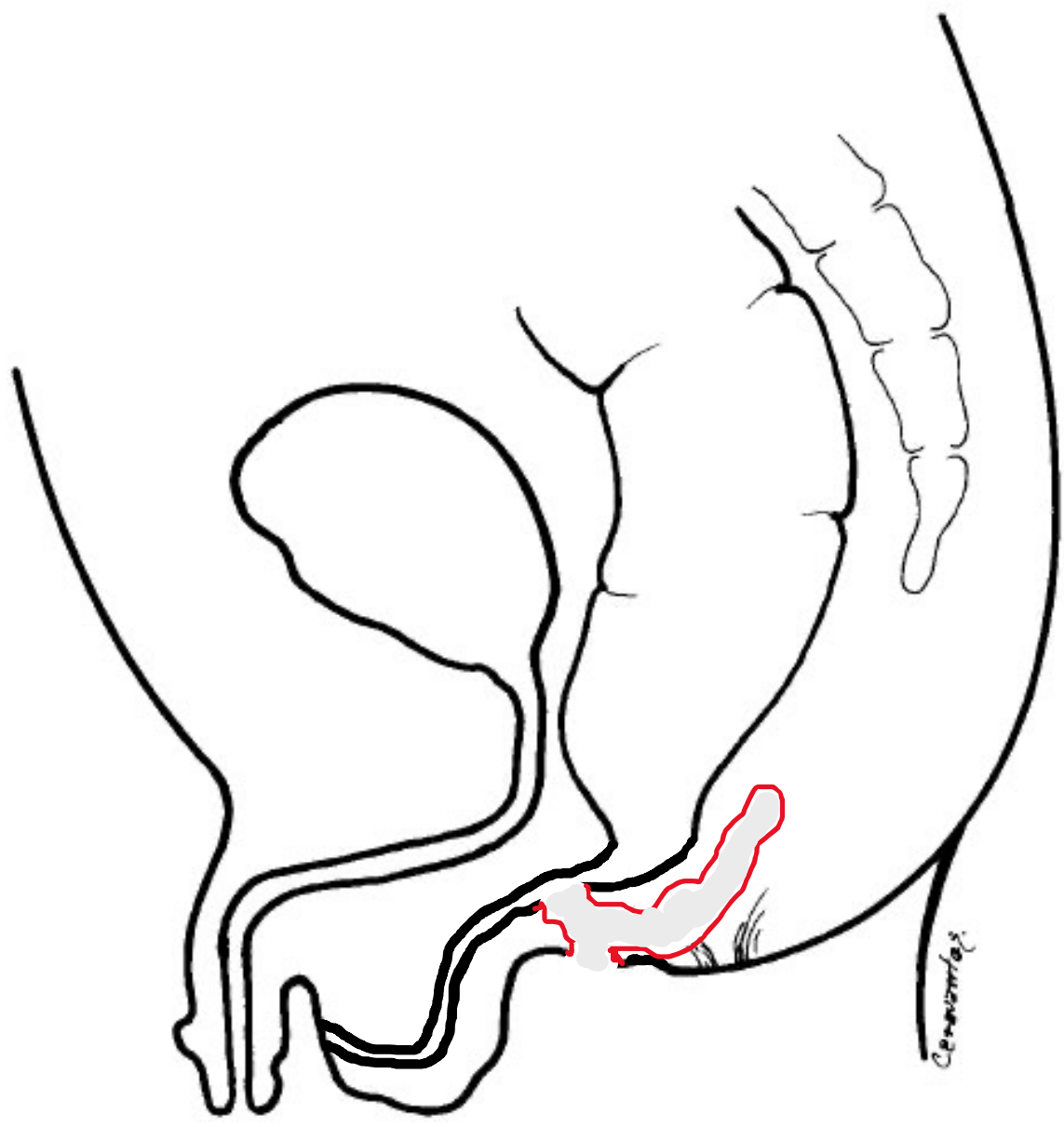












Cenamor



Thank you

Puebla, México.

Dra. María Zornoza

Dr. José Alejandro Ruíz