

Case #1

Lea Wehrli

November 18, 2021



Children's Hospital Colorado

INTERNATIONAL CENTER FOR
**COLORECTAL AND
UROGENITAL CARE**



7 yo female patient born and operated
due to a recto-perineal fistula at the
newborn period



In her chart it is noted that the patient has urethral, bladder and vaginal duplication.



- Now the patient comes at the age of 7 due to persistent stool accidents



What would be your next steps?

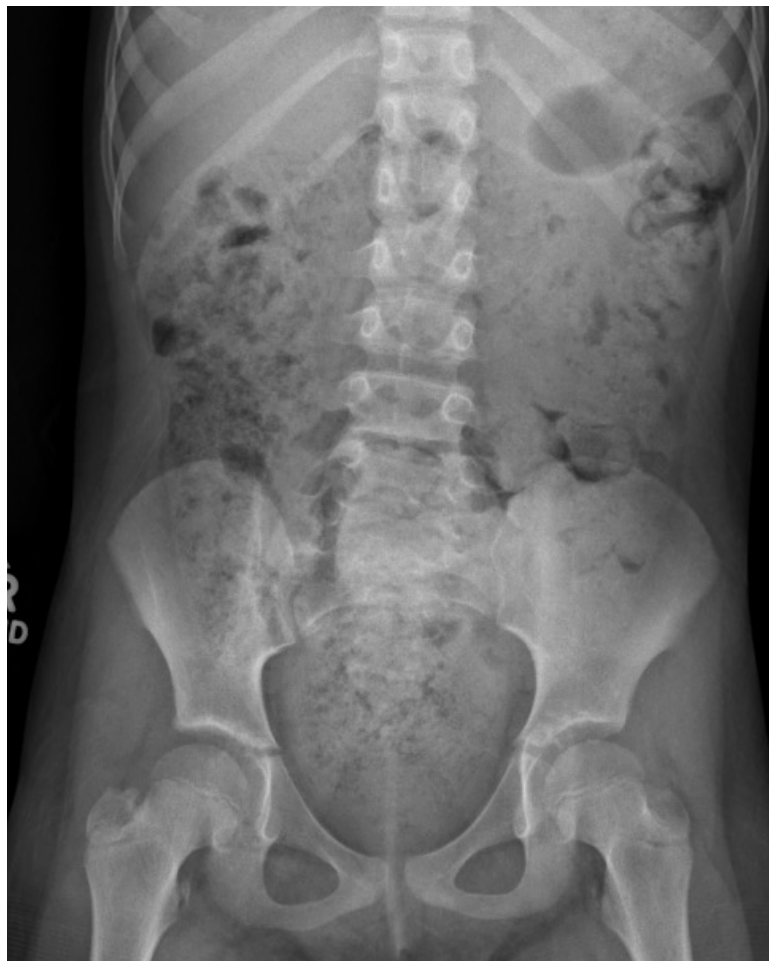1. Abdominal X-ray
2. Contrast enema
3. Exam under anesthesia
4. All of the above

What further diagnostics to evaluate her urogenital situation should this girl have?

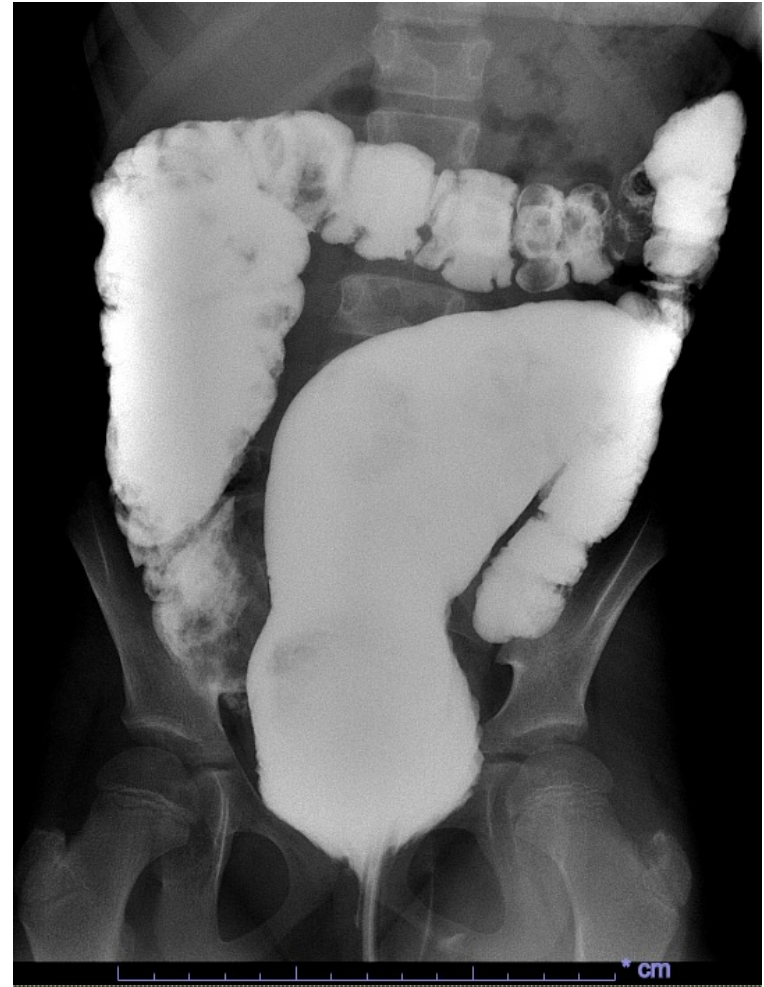
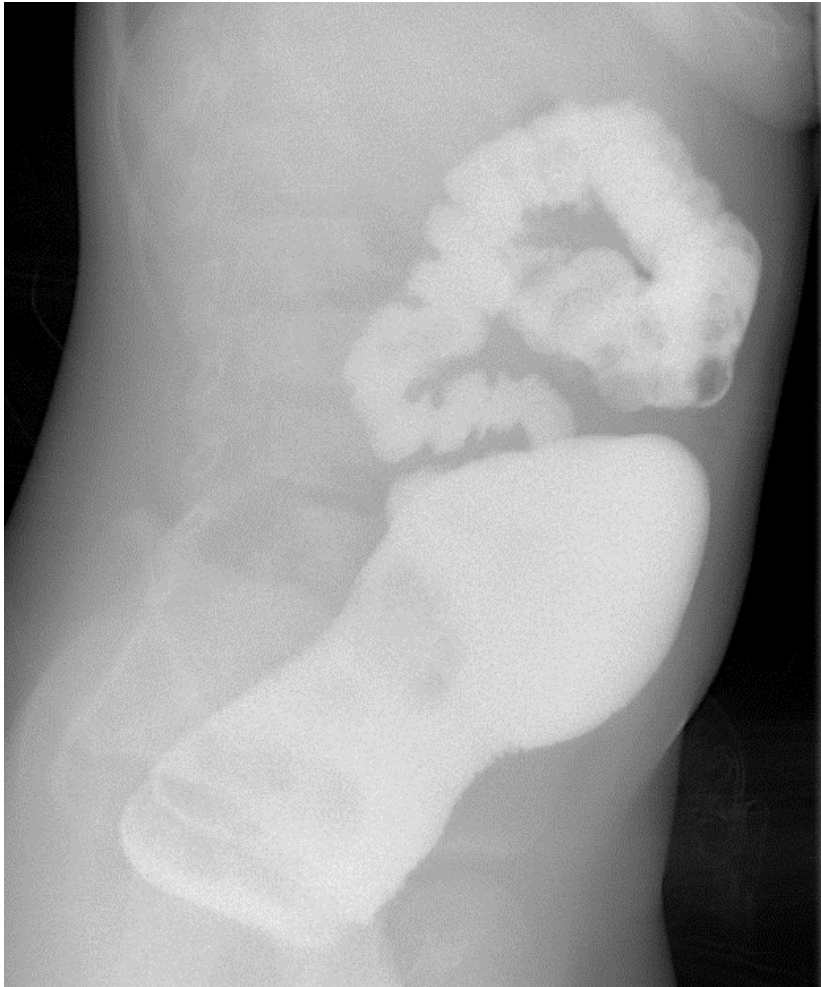

1. US
2. Cystoscopy
3. Vaginoscopy
4. All of above

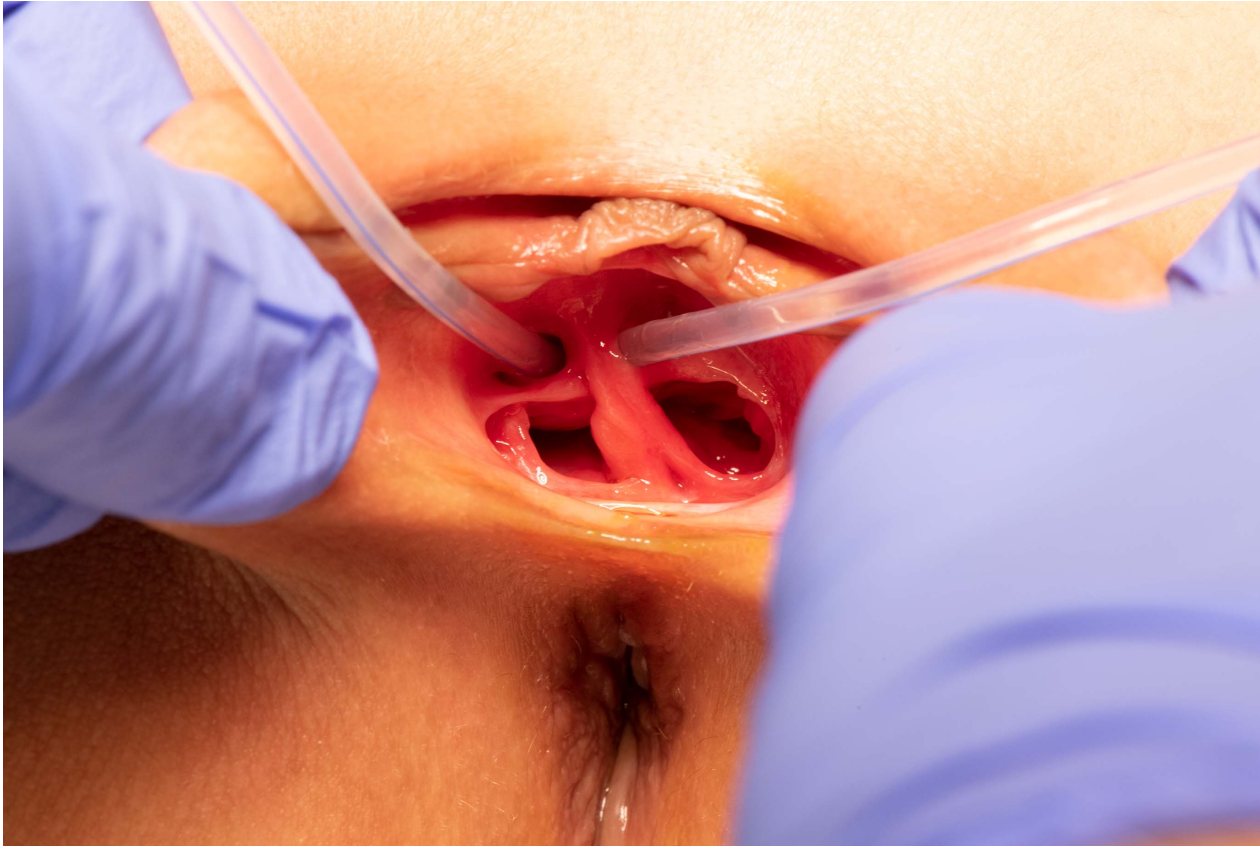Abdominal X-ray



Contrast enema



Exam under anaesthesia



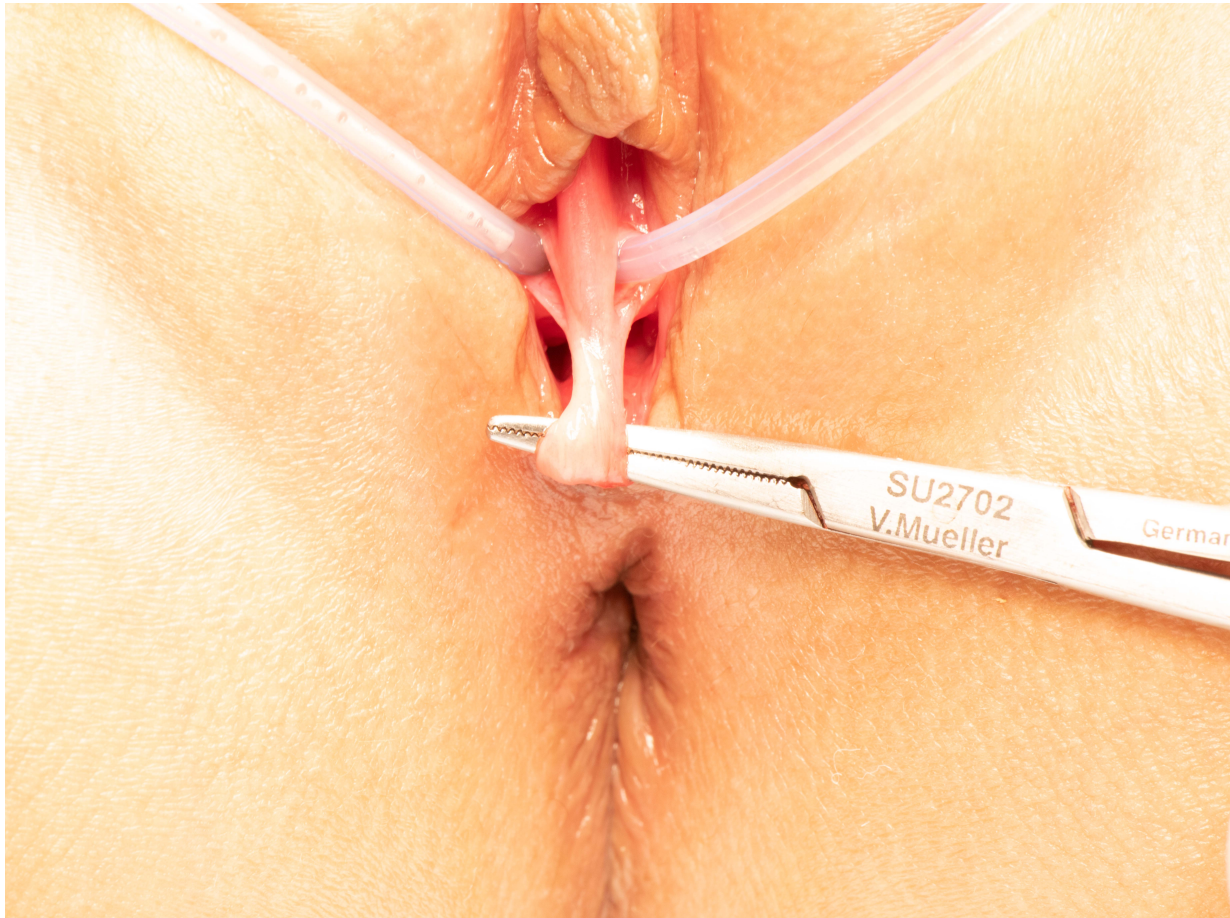

Cystoscopy and Vaginoscopy

Revealed:

- Two separated bladders with each containing one ostium of the ureters
- Two cervixes but...

Exam under anesthesia



Final Diagnosis



- Patient with corrected recto-perineal fistula, with severe constipation and pseudo-fecal incontinence
- Bladder and urethral duplication
- Double cervixes and uterus didelphis
- **ONE VAGINA WITH A SEPTATED HYMEN**

What is the difference between a hymenal versus a vaginal septum?



1. Hymenal septum is an incomplete perforation of the hymen
2. Vaginal septum can be either be longitudinal or transverse
3. All of the above



What are the possibilities for associated malformations of the urogenital tract in patients with anorectal malformation?

1. 30%
2. 50%
3. 70%
4. 90%



What operative planning would you consider for her bladder and urethral duplication?

1. Resection of one urethra
2. No further surgical treatment
3. Surgical resection of one bladder and reimplantation of the ureter

Exam under anesthesia



Resection of the hymenal septum

