



ARM with Recto-Urethral Fistula and “Normal Anus”

Cinthia Galvez-Alegria, MD

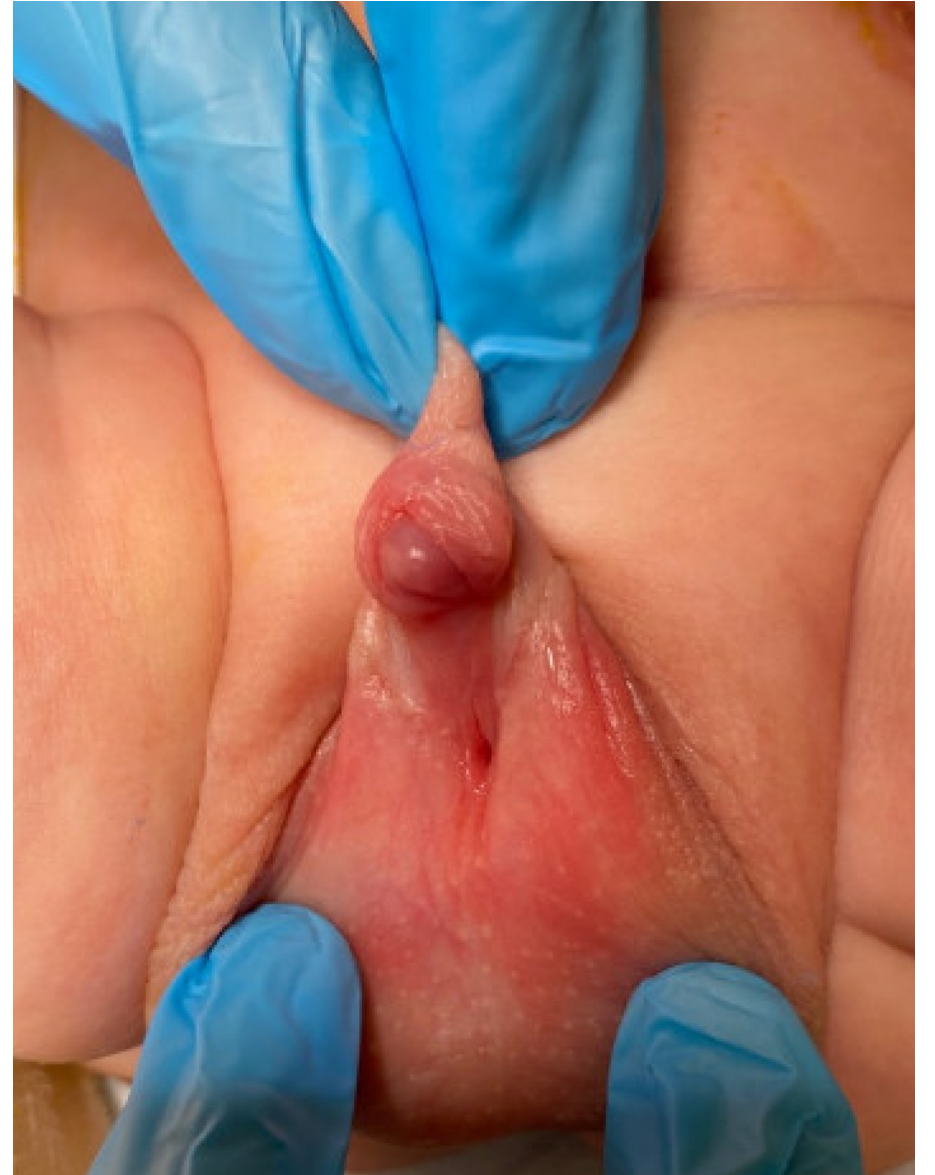Joe Dimaggio Children's Hospital
Hollywood, FL

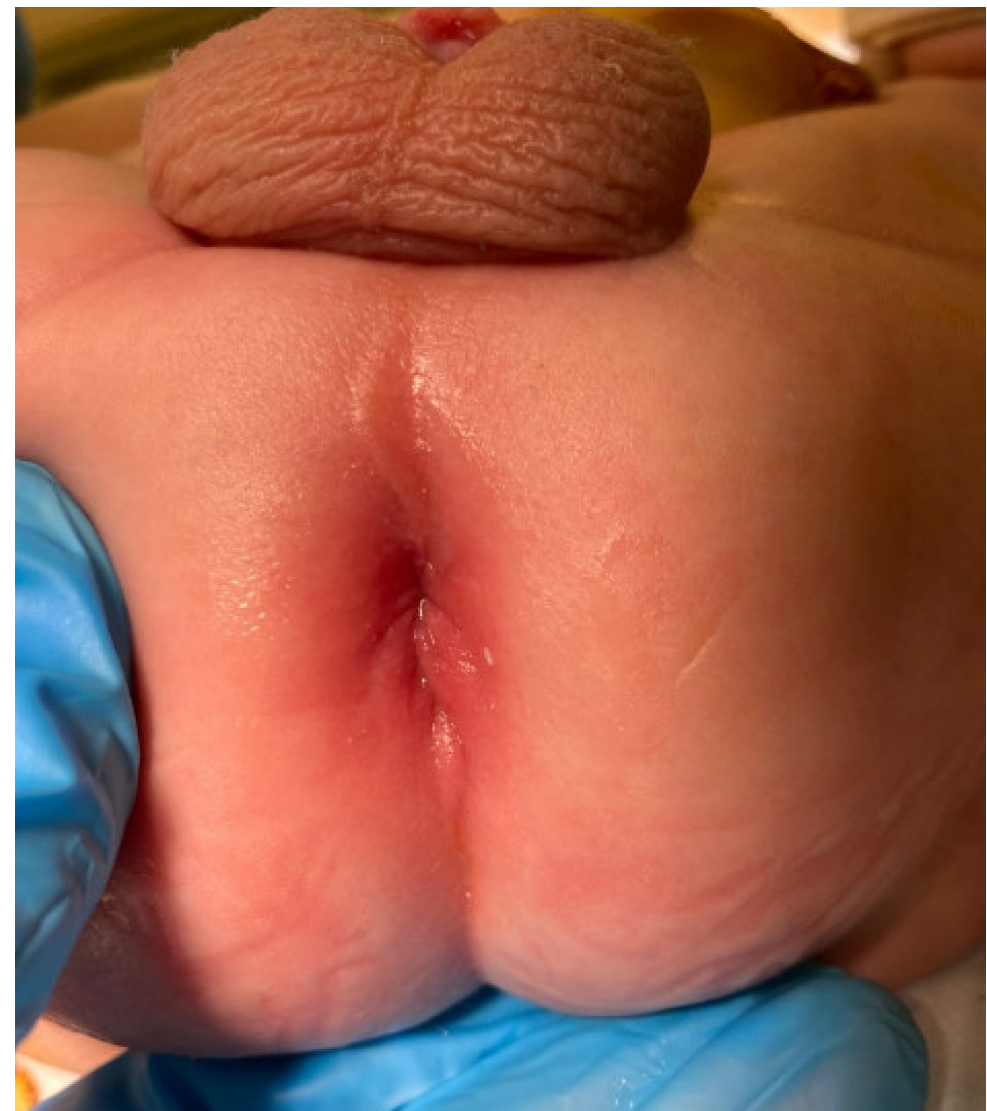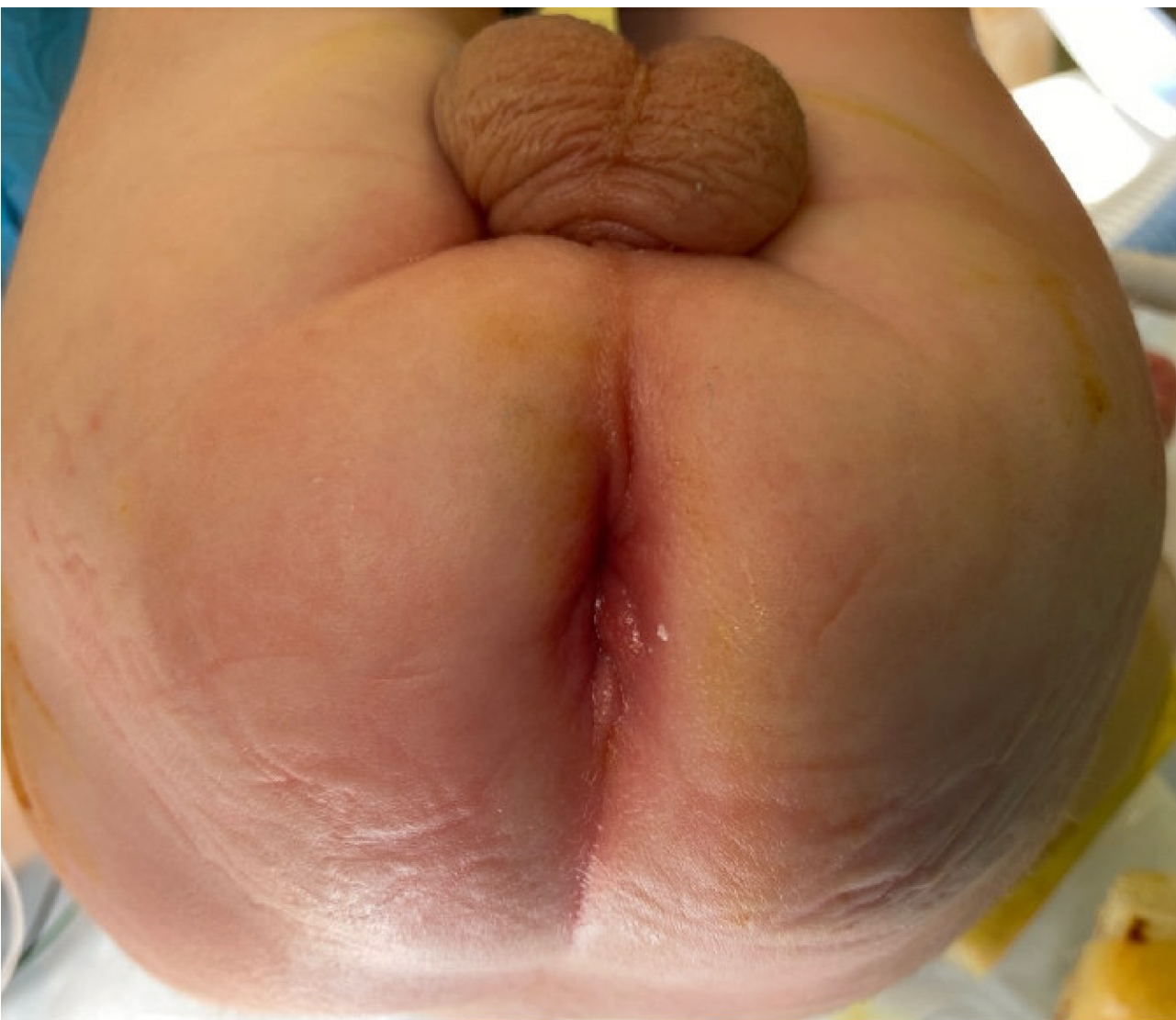11/18/2021

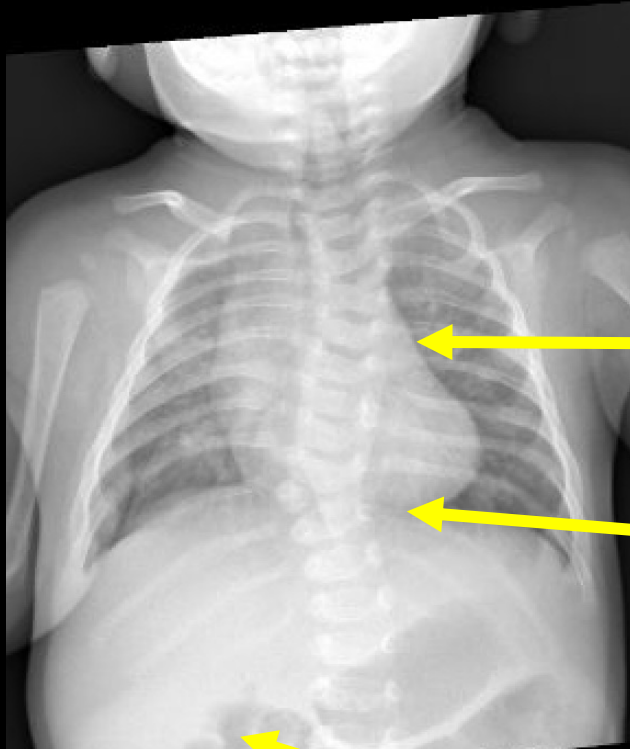


A 2-month-old born at 37 weeks. Stool and urine coming from the penoscrotal hypospadias.

Pre-natal: Single right kidney.

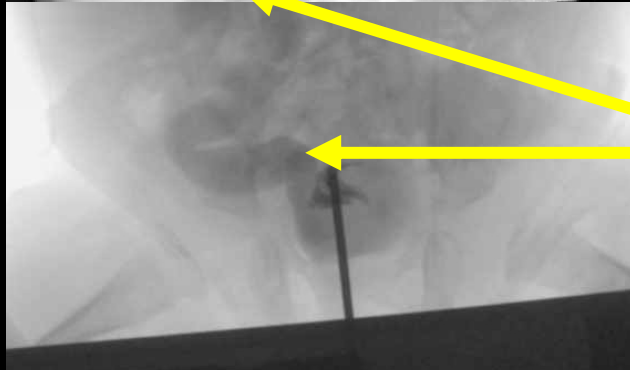






Ventricular septum defect VSD

T4 and T10 hemivertebra
No tethered cord.

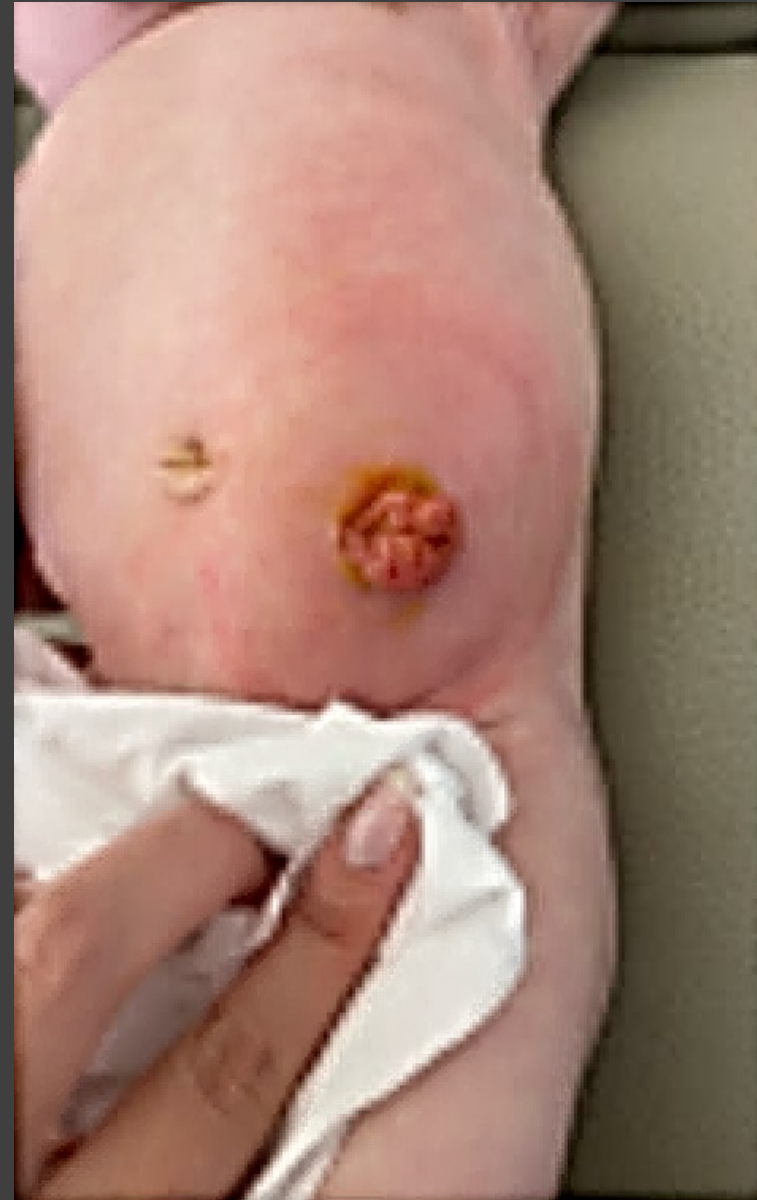

Hydronephrosis of the right kidney
with megauterer.

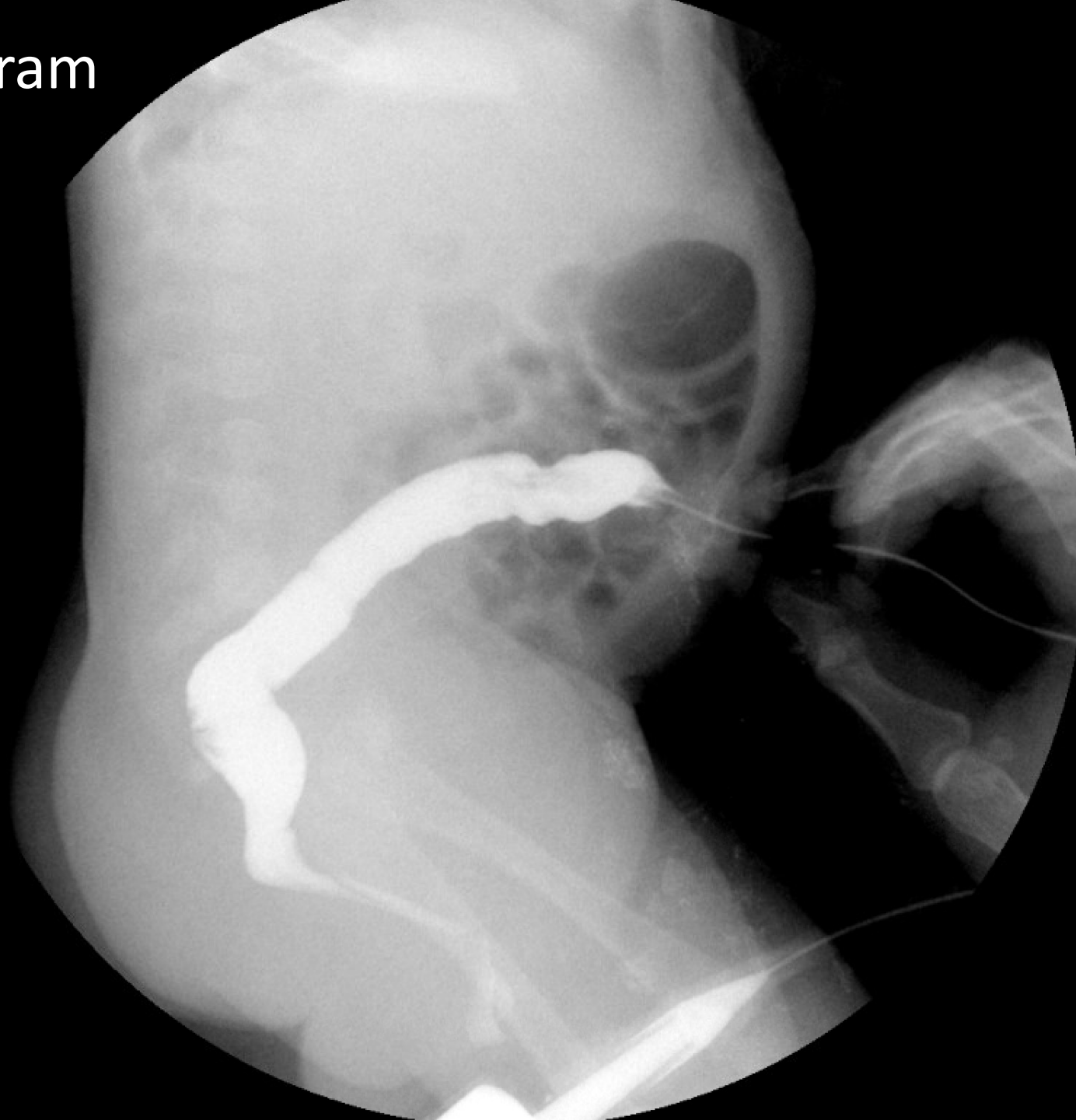
Agenesis of the left kidney.

Post Op:3

- Colostomy
- Vesicostomy



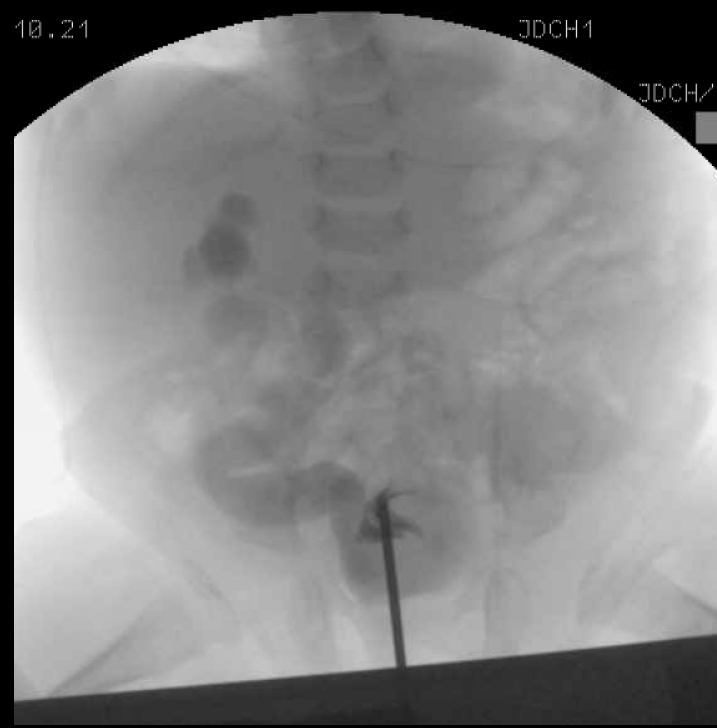Distal Colostogram



10.21

JDCH1

JDCH/1

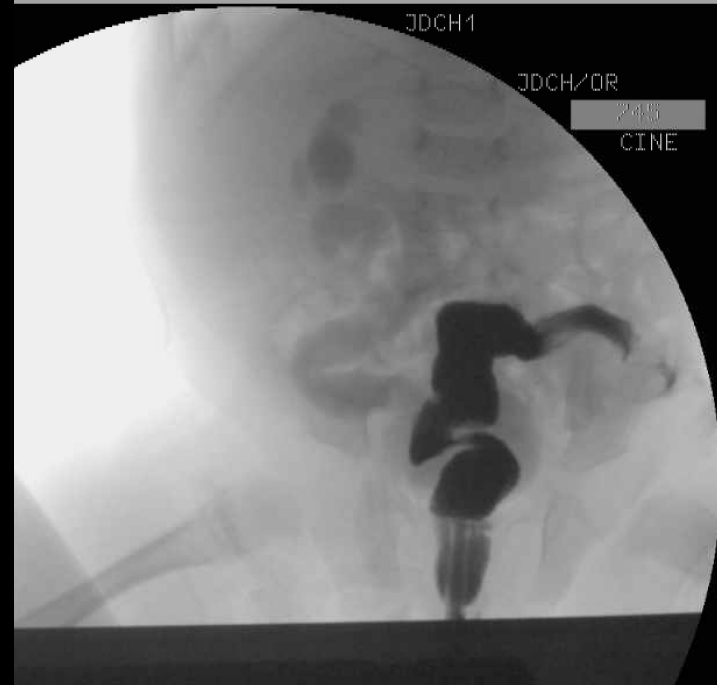

JDCH1

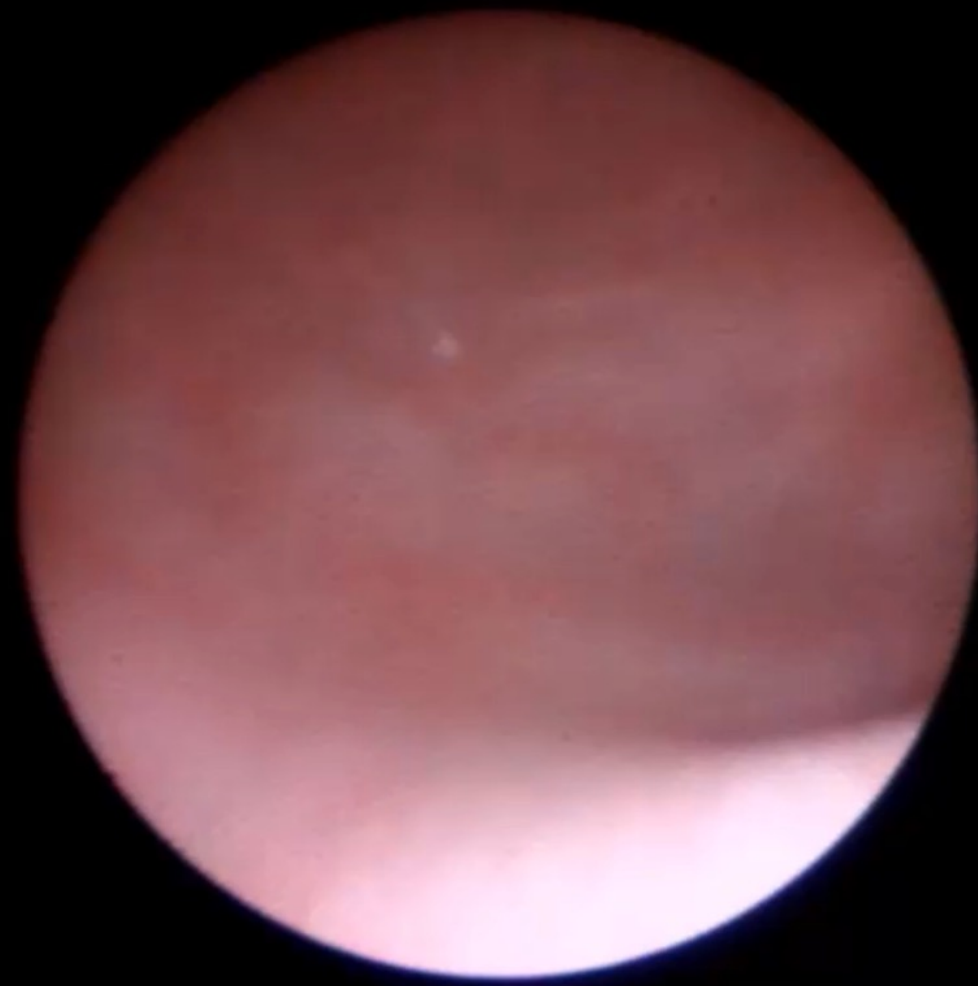
JDCH/DR

200

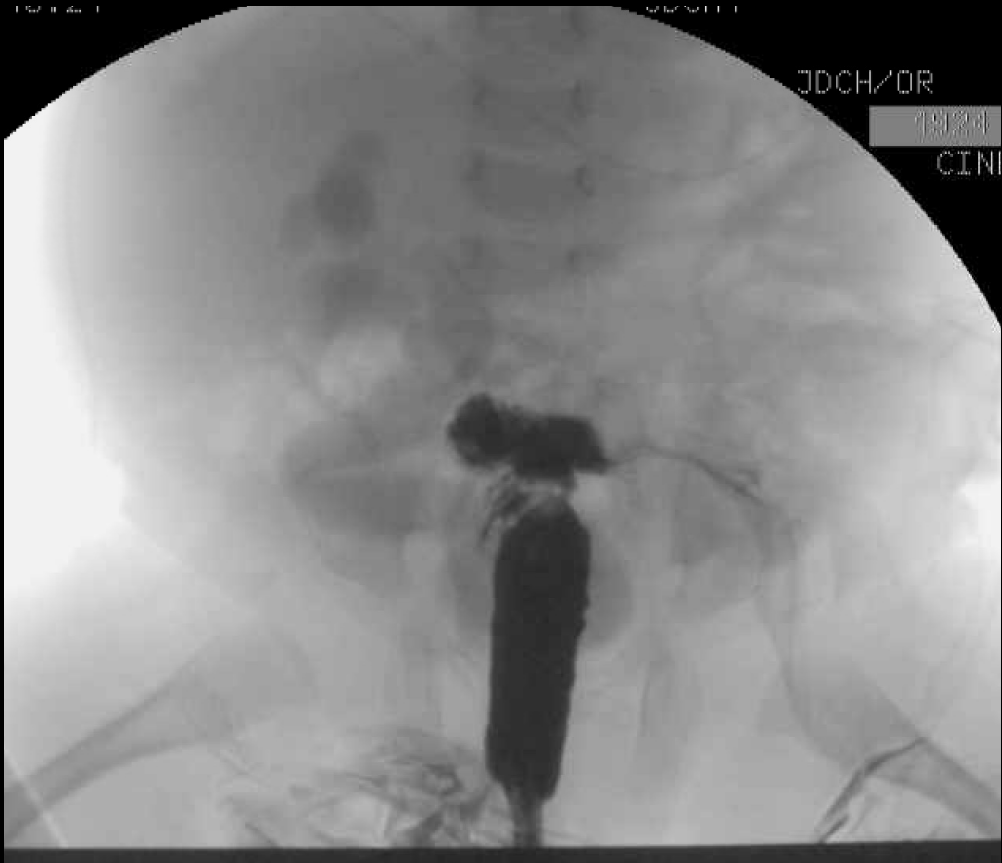CINE



Cystoscopy



Contrast through the anus



Anoscopy

