



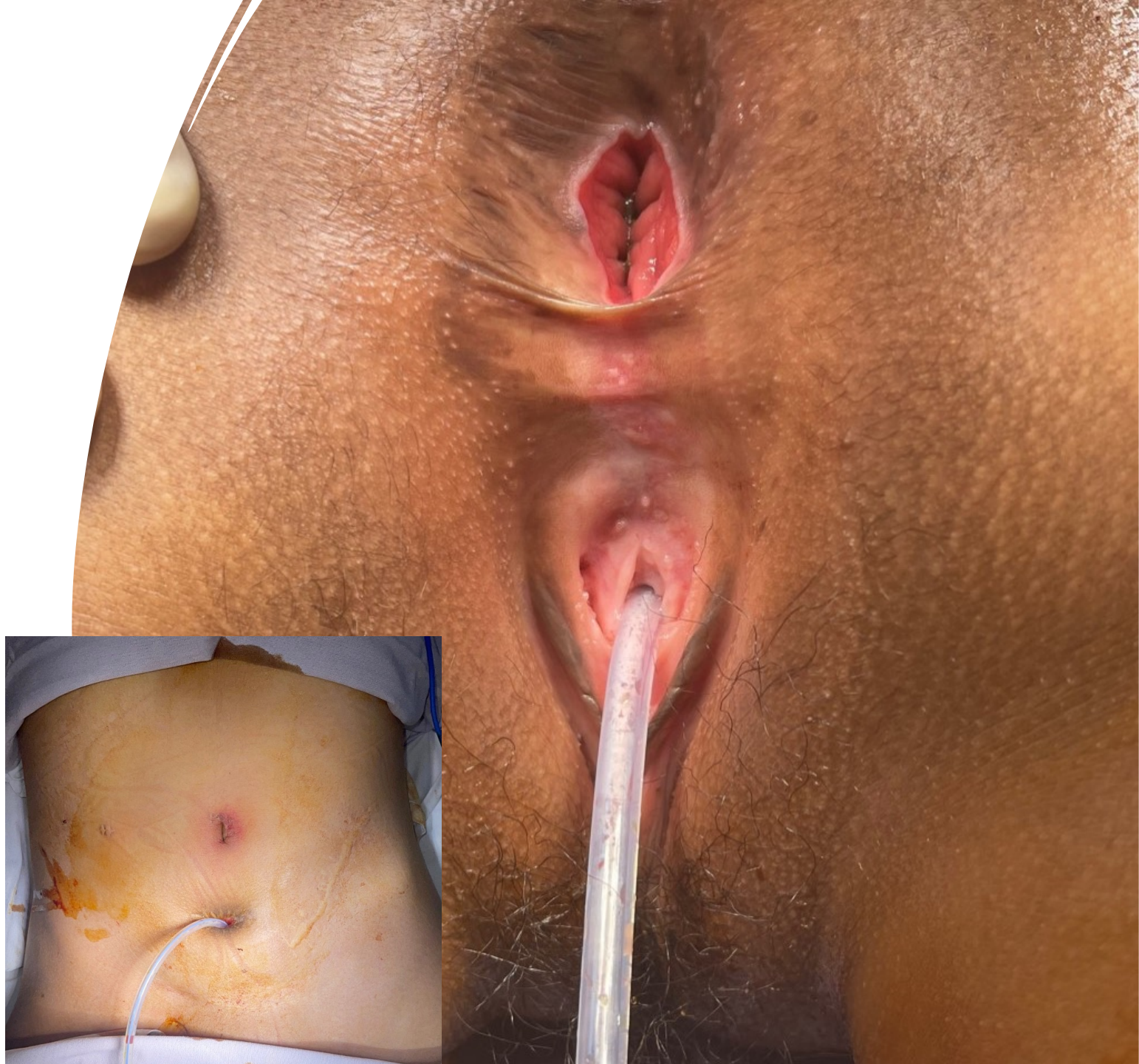Colorectal Web Meeting

Karla Santos Jasso – Carolina Giraldo –Chanel Ugarte MD

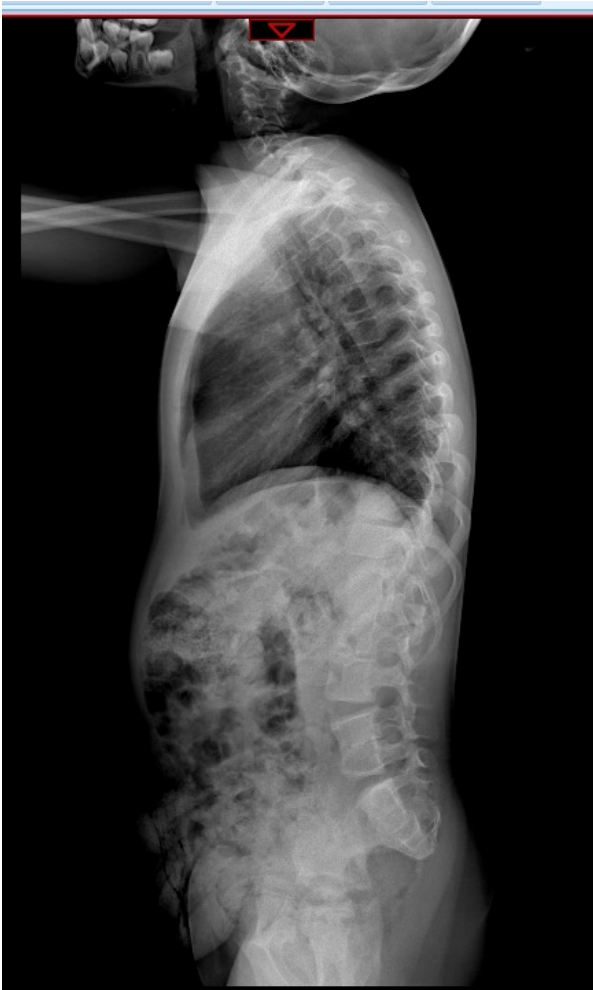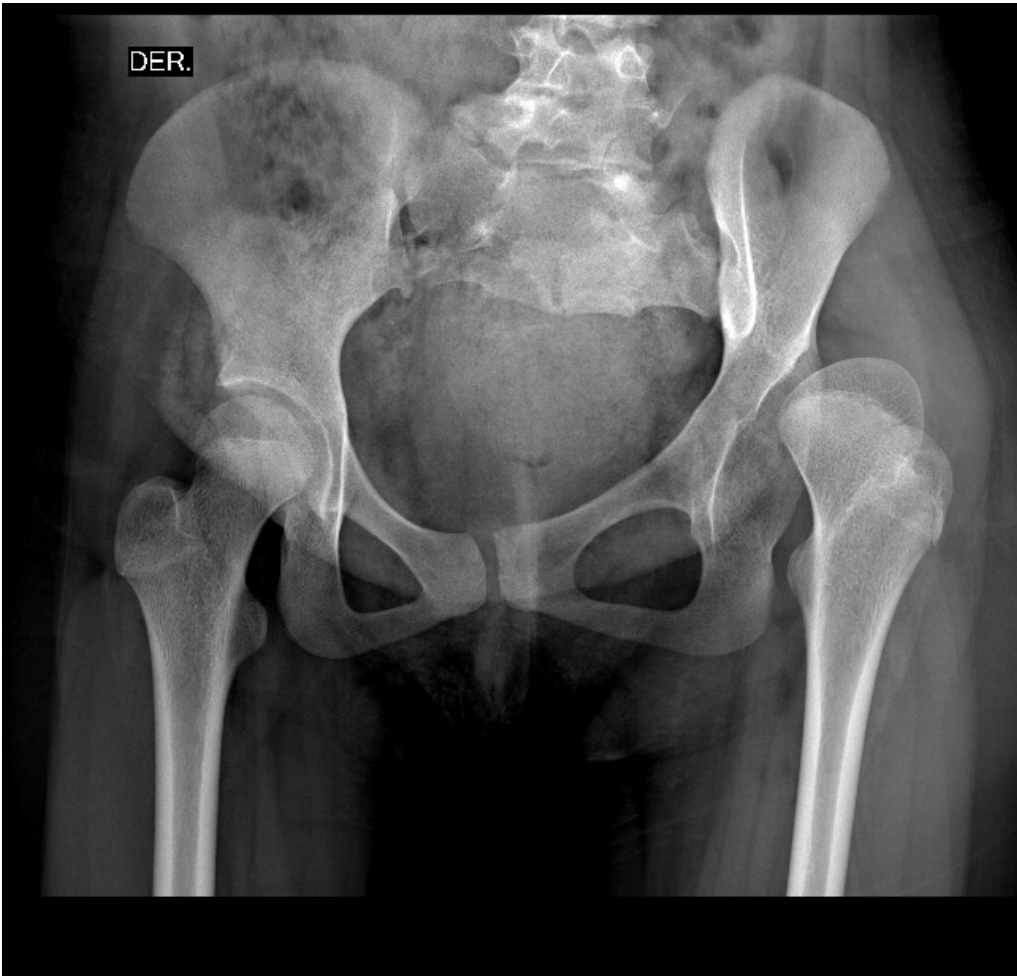Instituto Nacional de Pediatría- México

November 2022.

-
- 15 y.o
 - Anorectal malformation (cloaca)
 1. Colostomy at birth
 2. Anorectoplasty
 3. Colostomy closure
 - She keeps some dried periods of urine and is incontinent for stool.

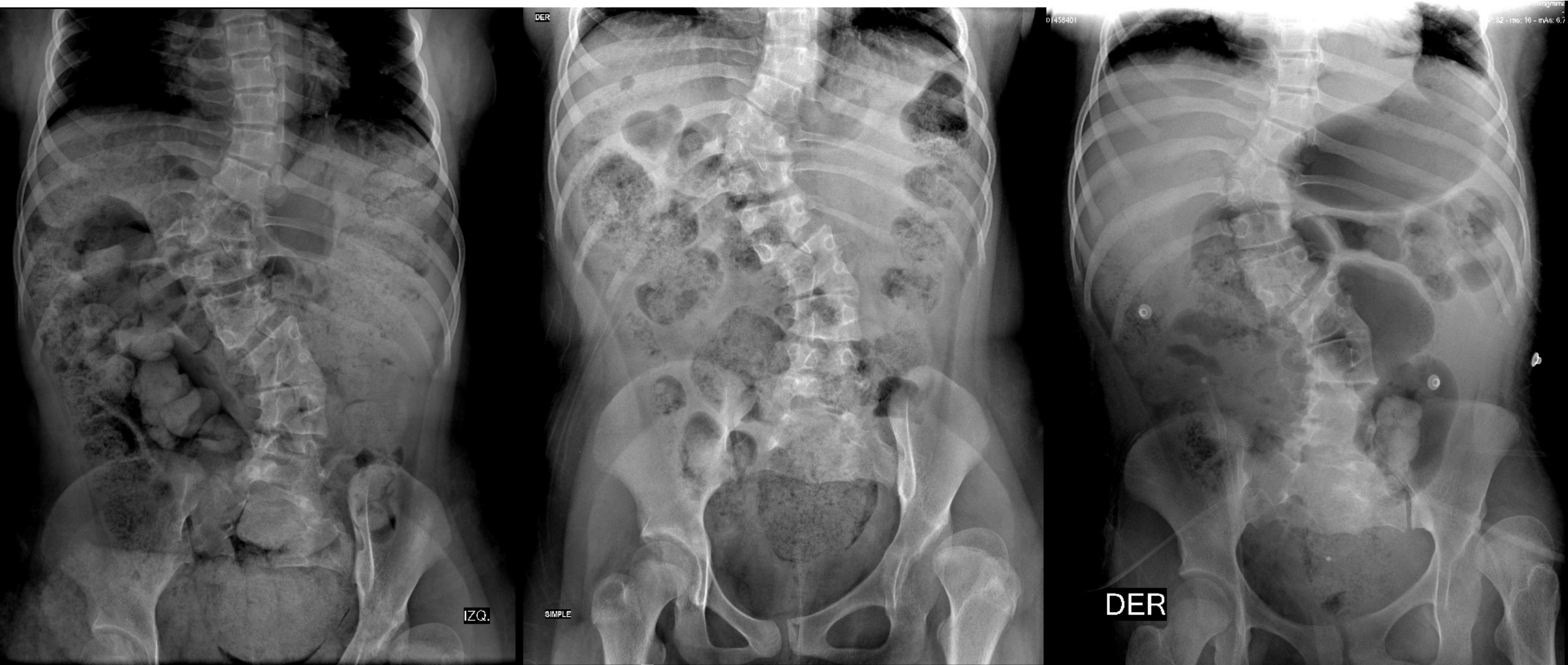

Sacral ratio

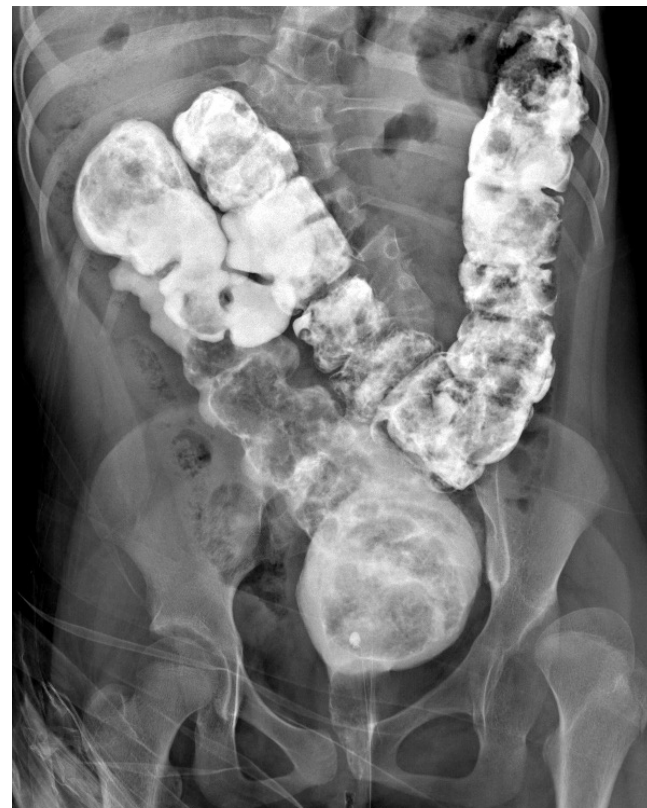
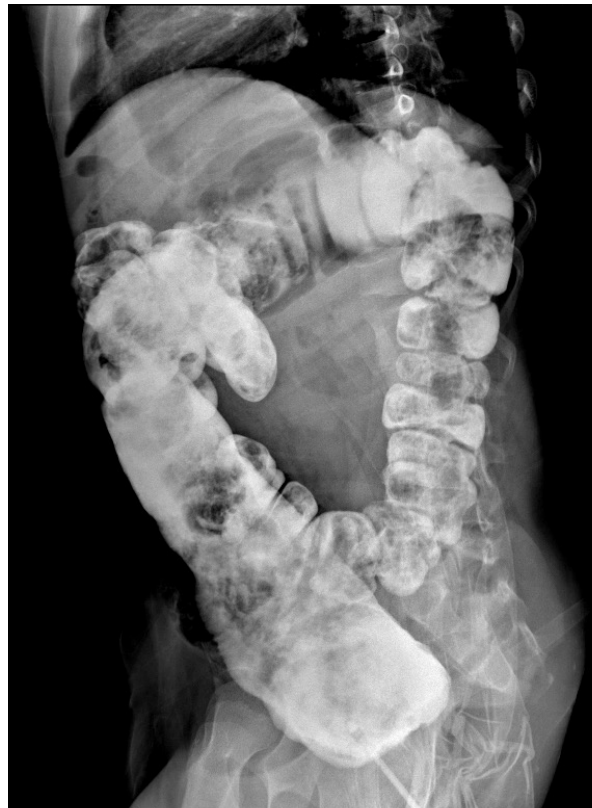
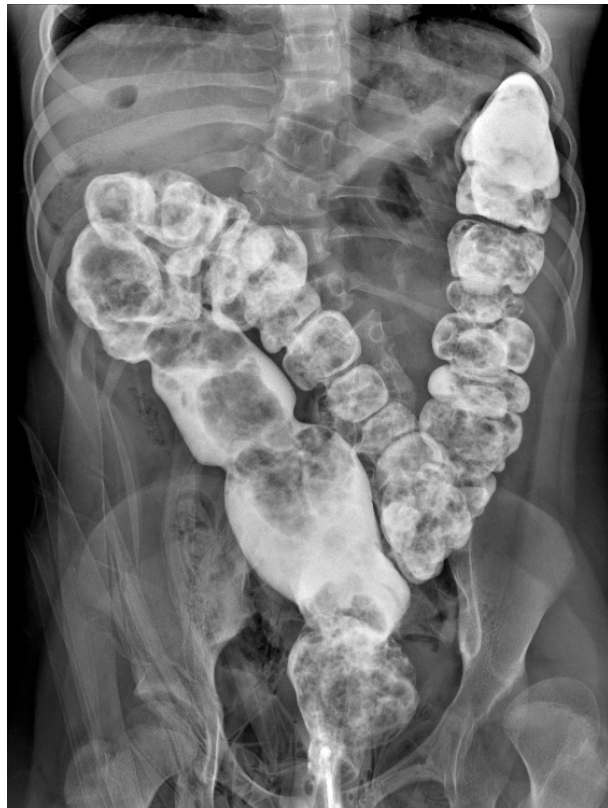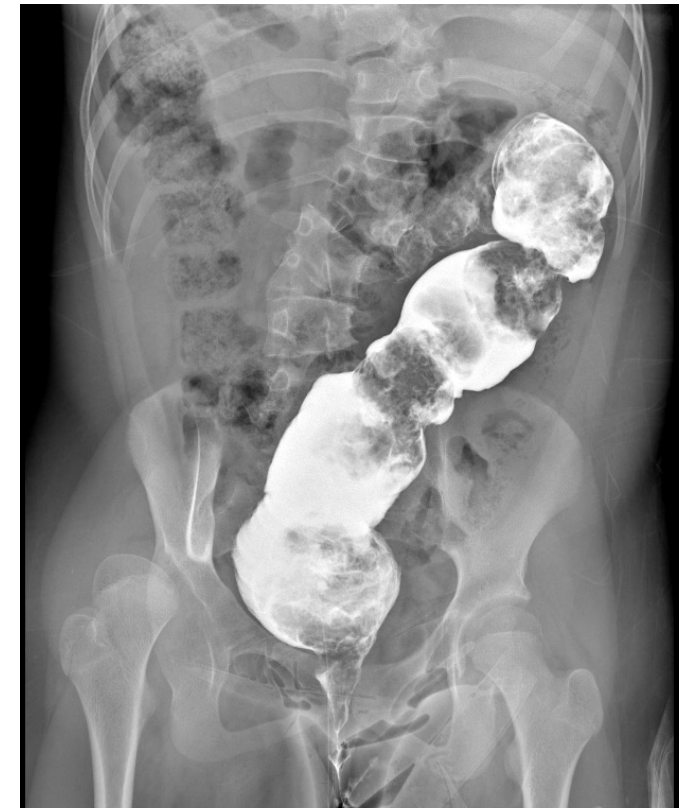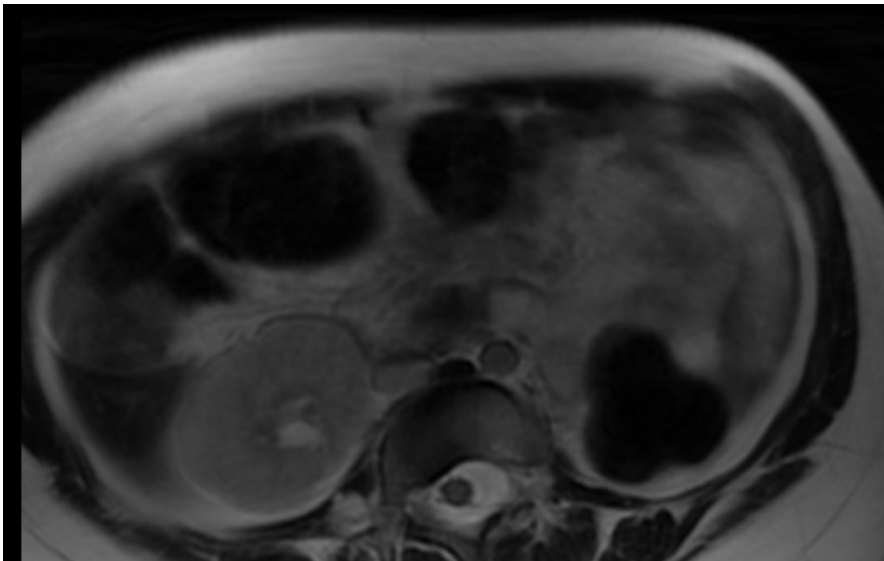
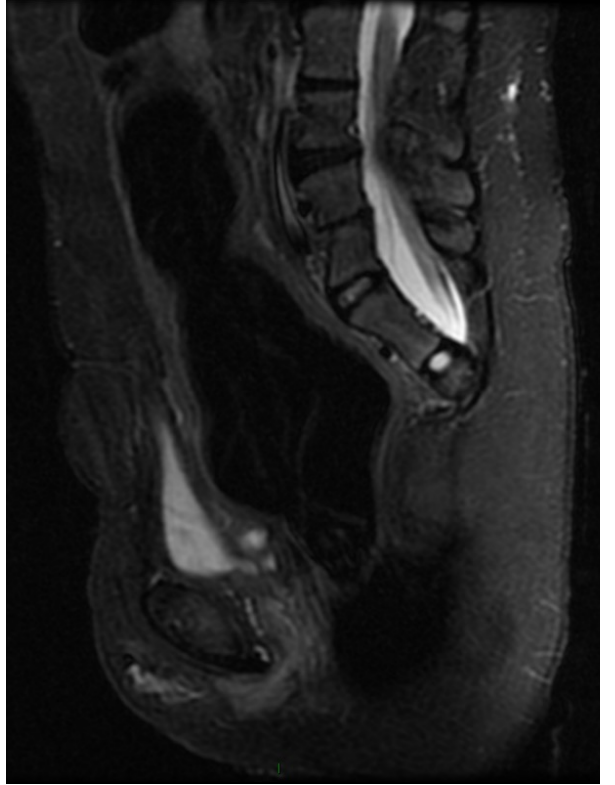
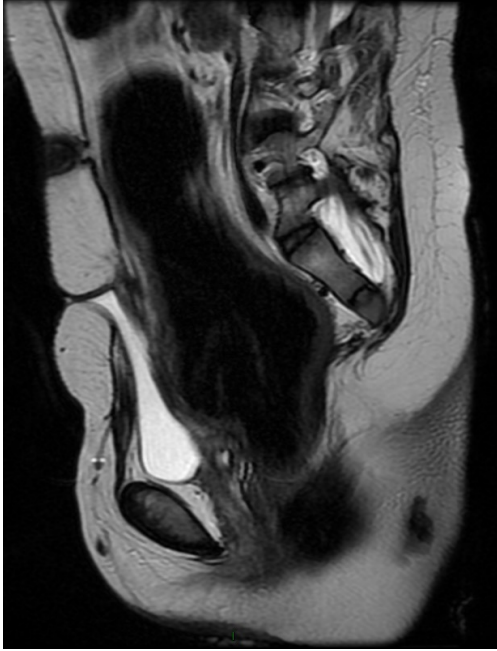
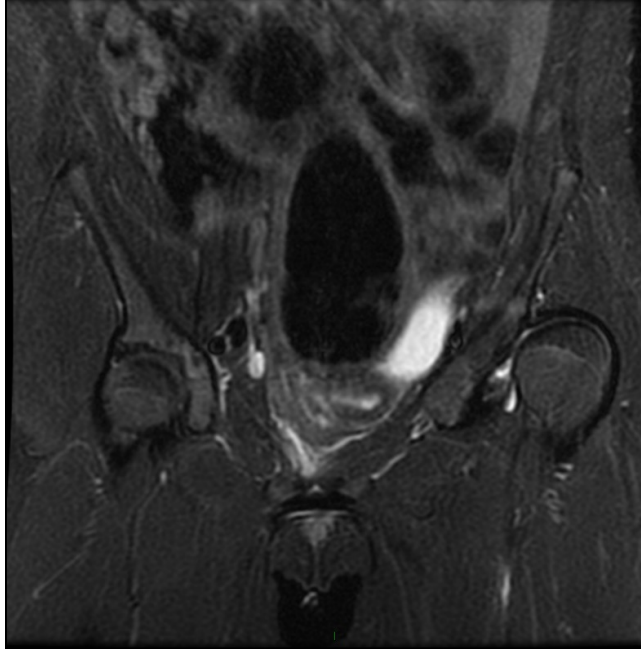
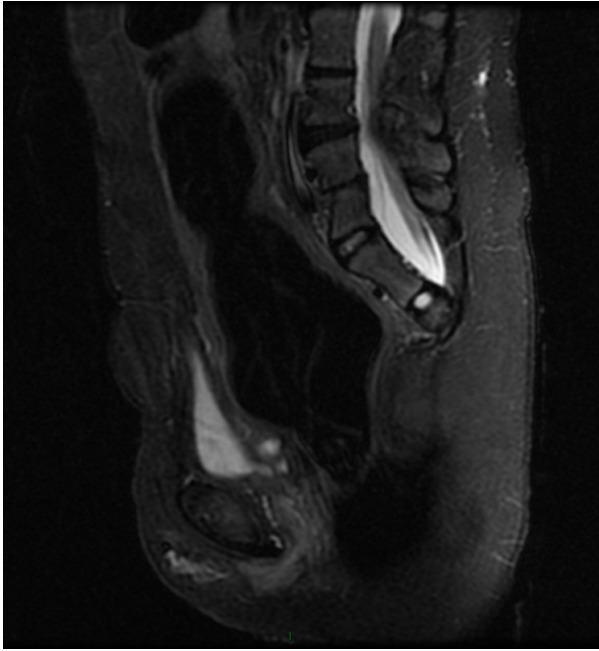
Bowel management program...

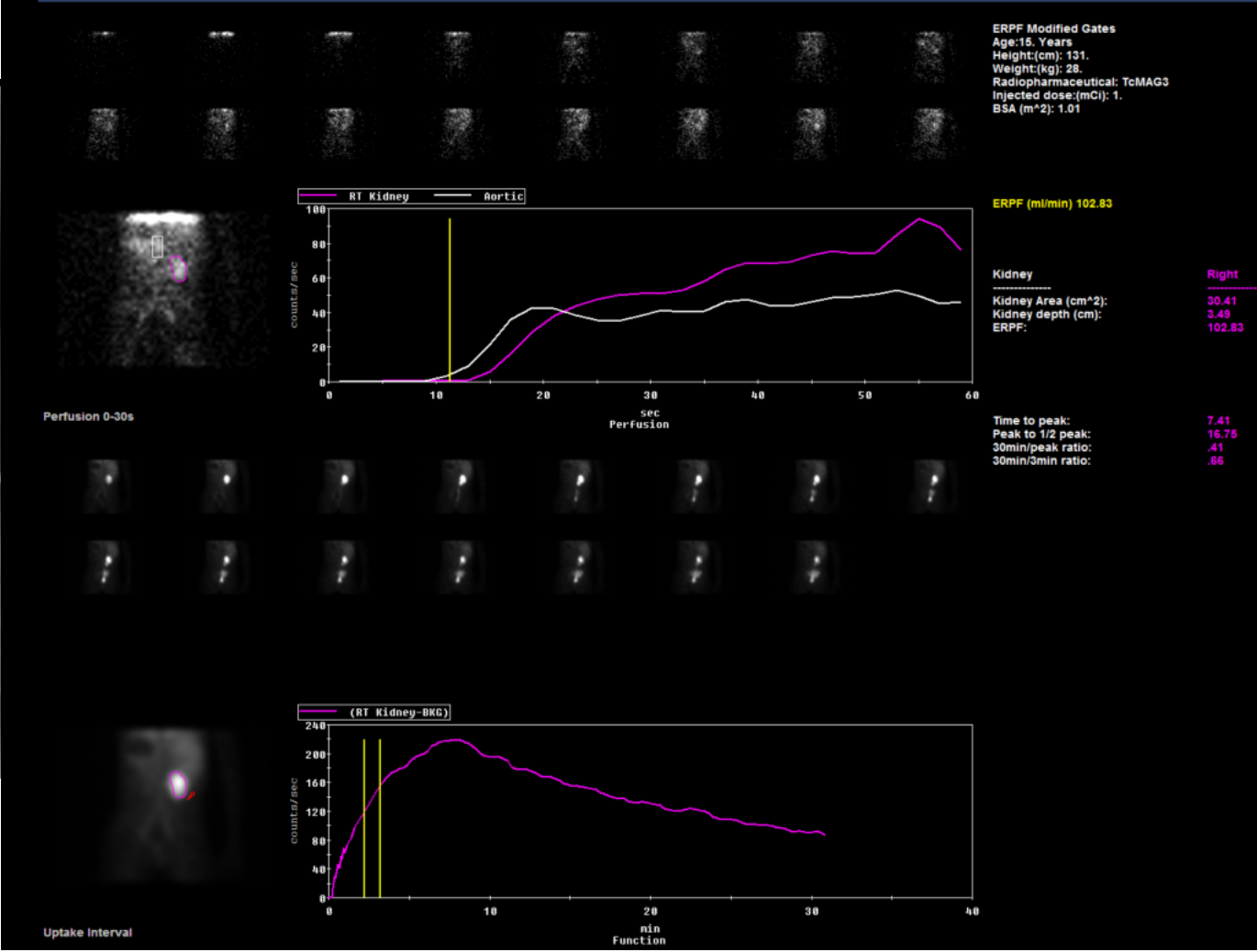
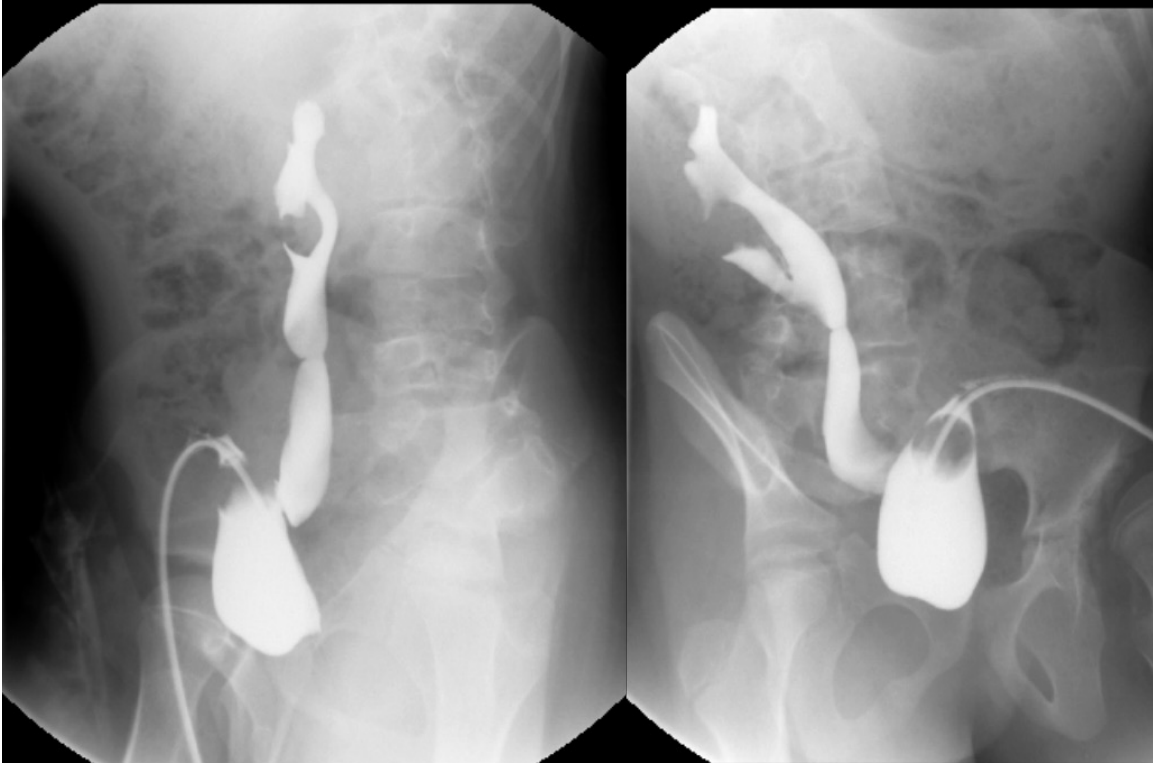With enemas 800/20/0



Contrast enema...



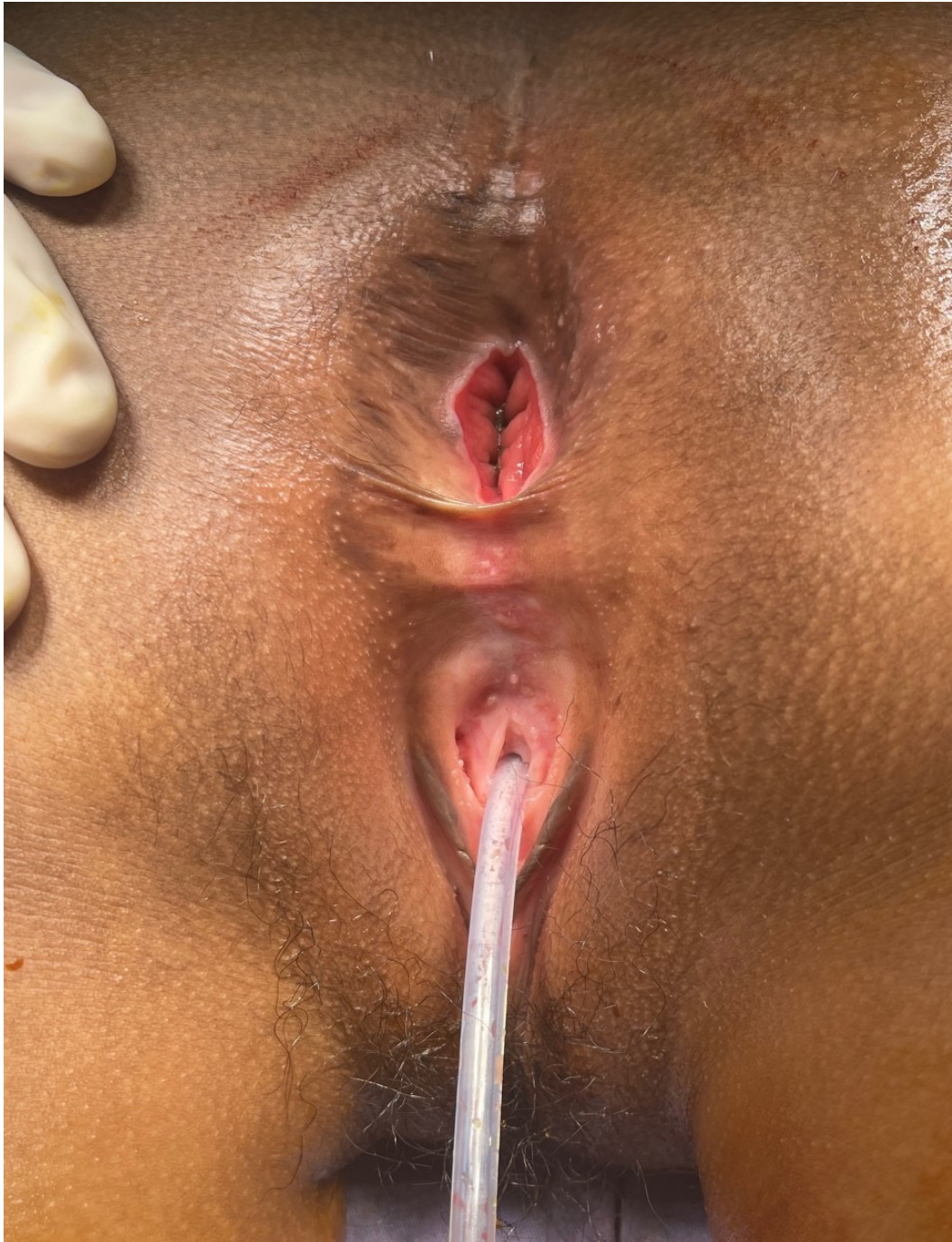


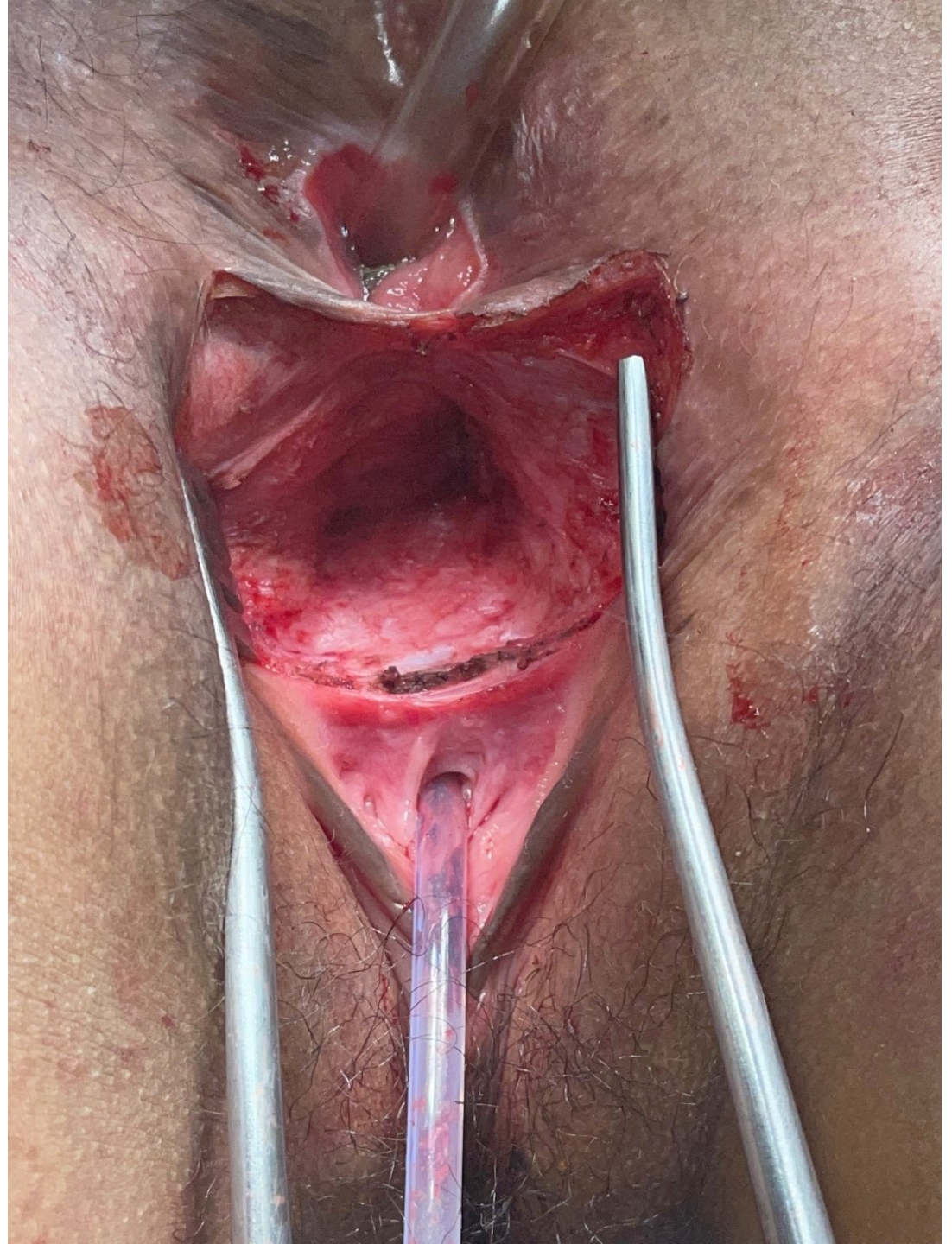
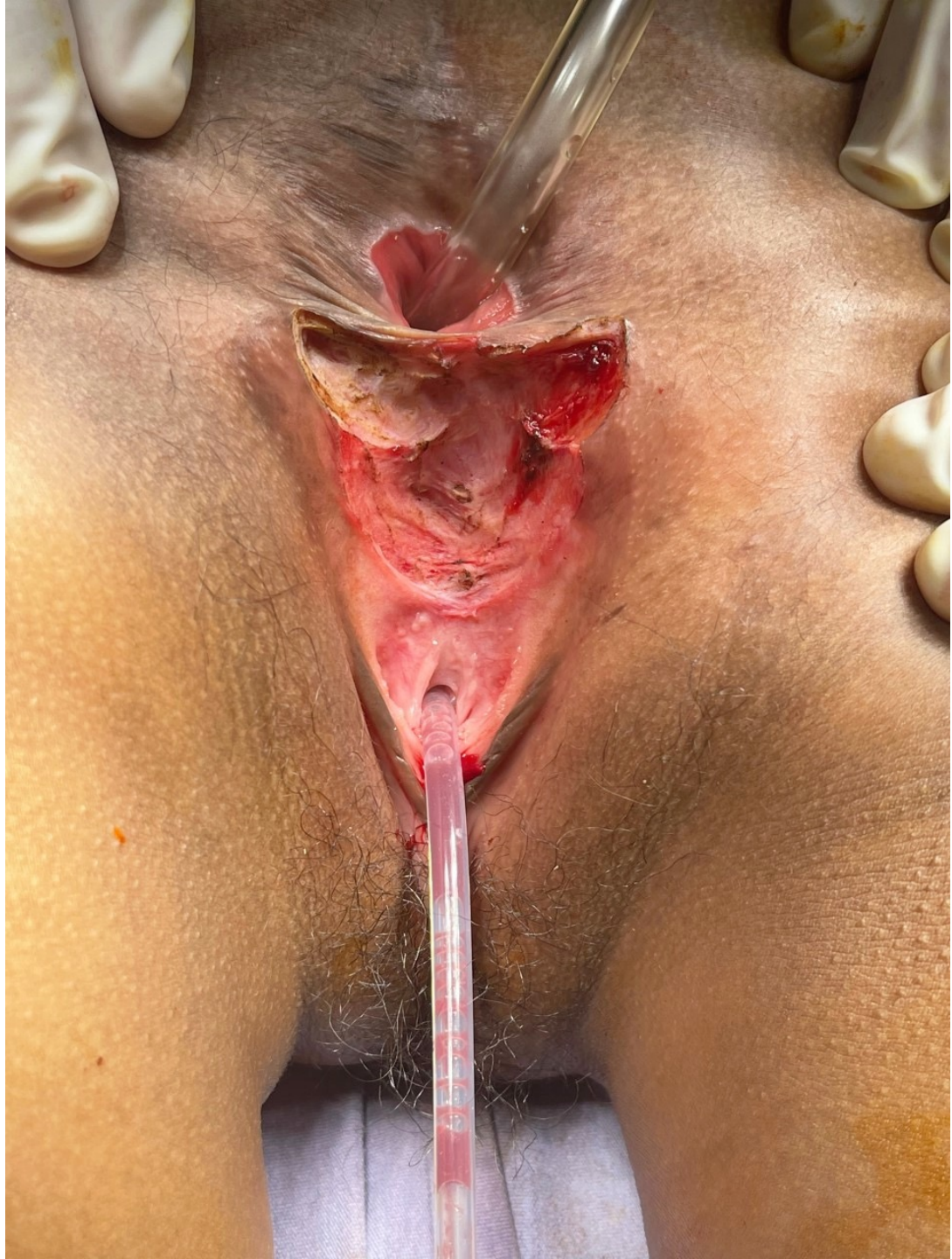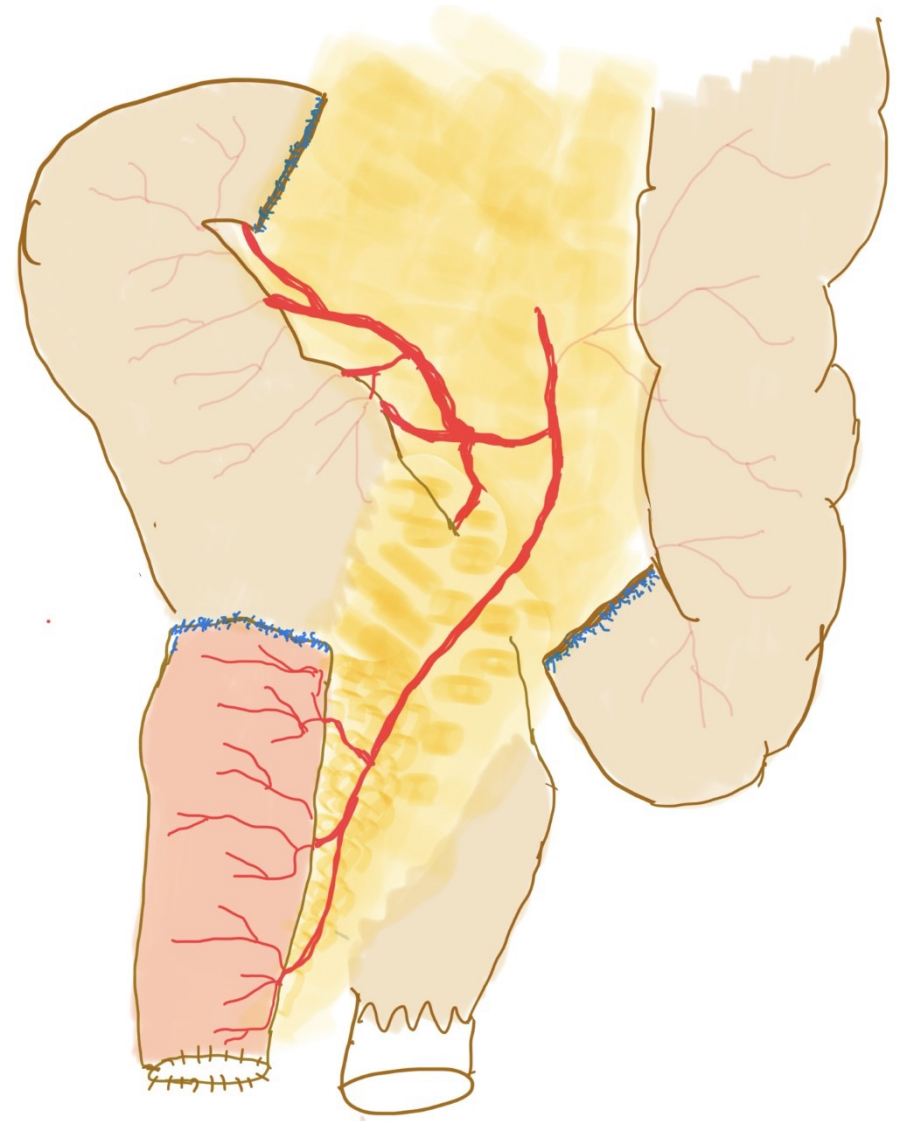
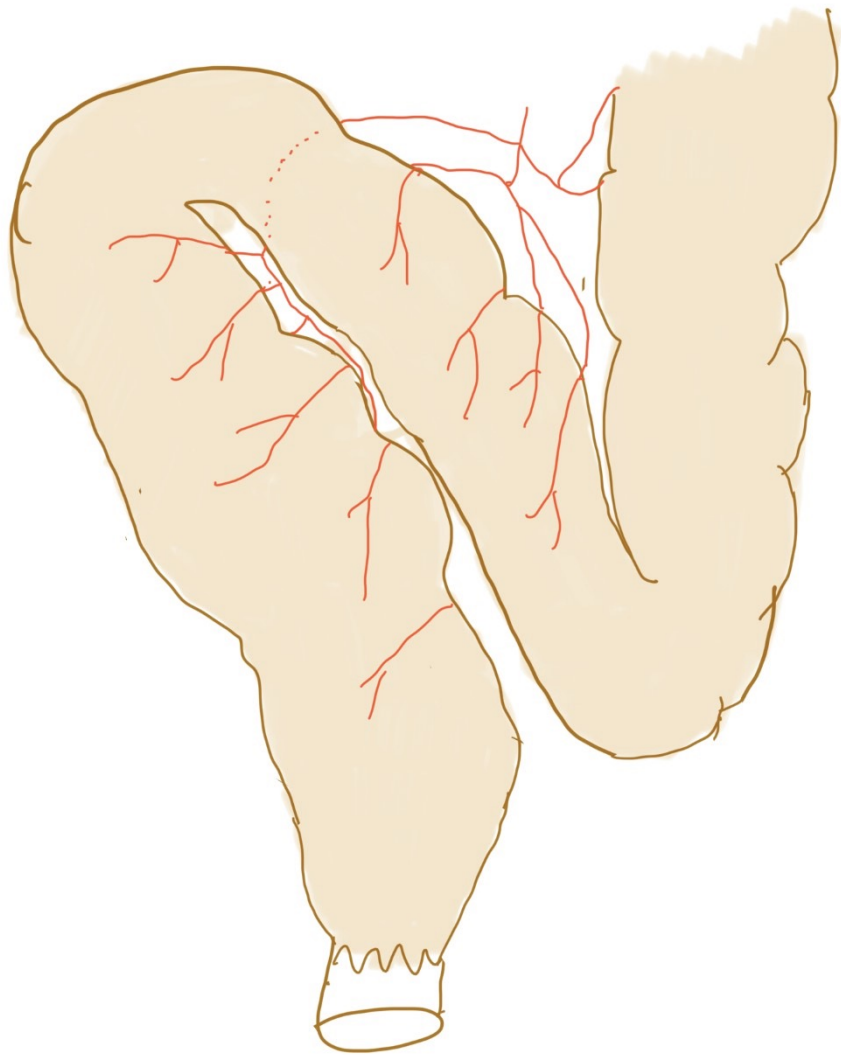
She needs Mitrofanoff and bladder augmentation with ureteral reimplantation (single right kidney)

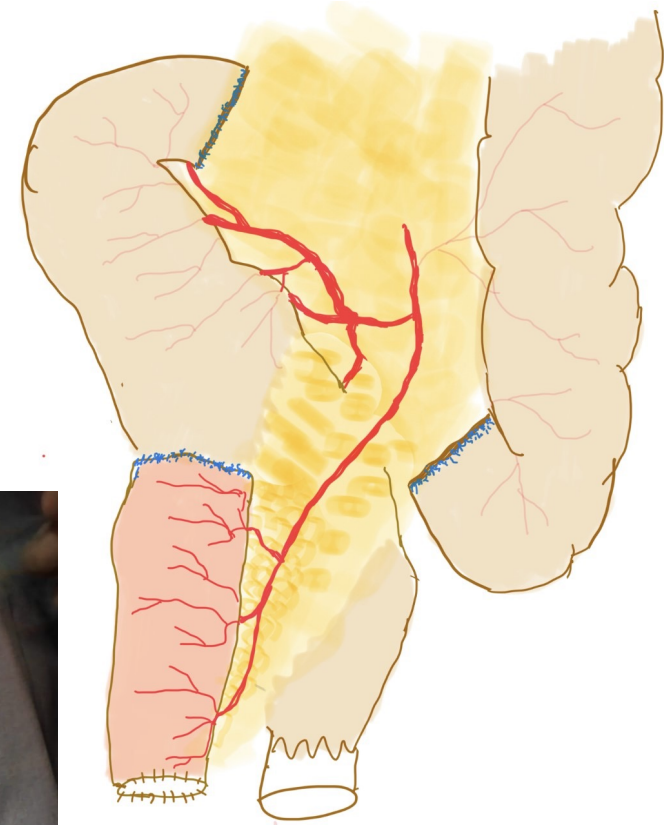
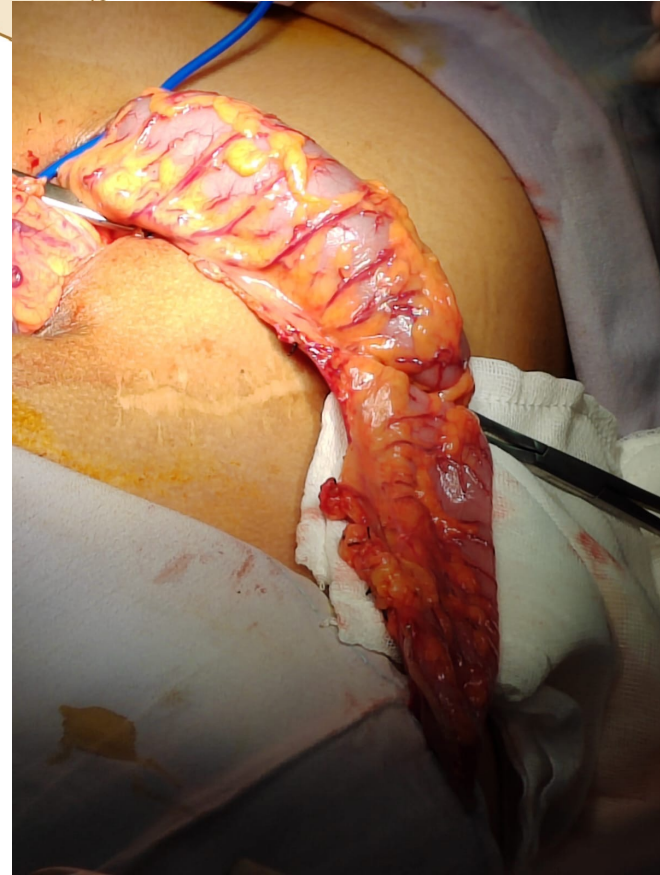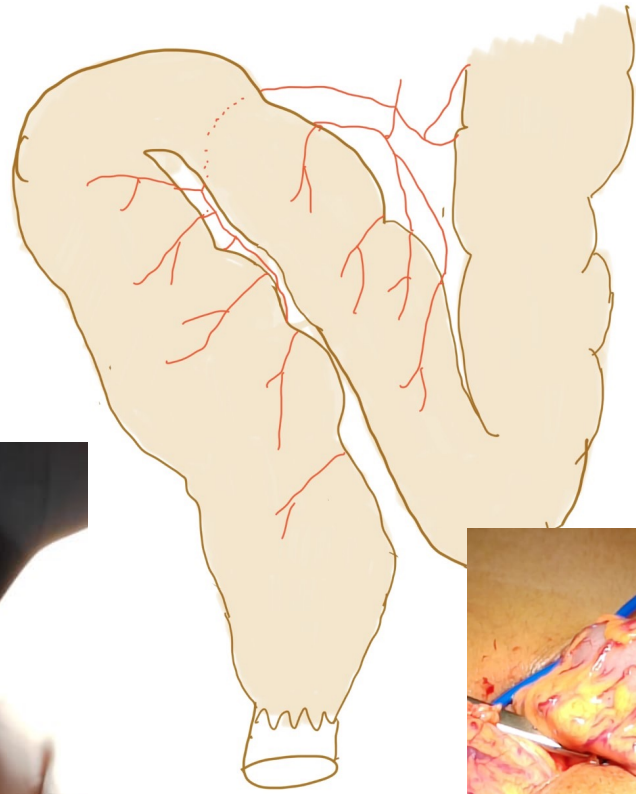
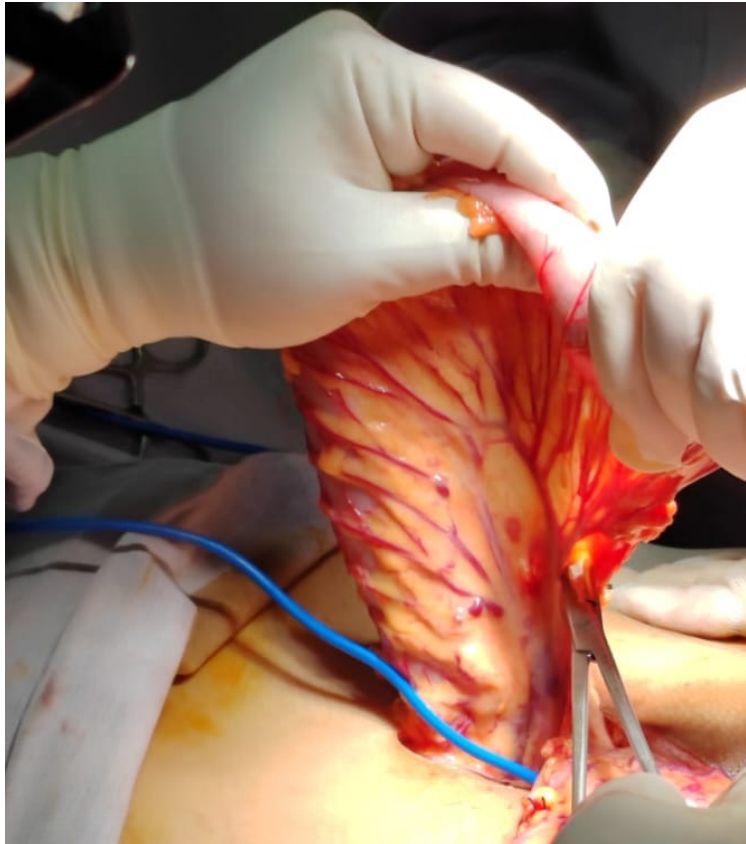


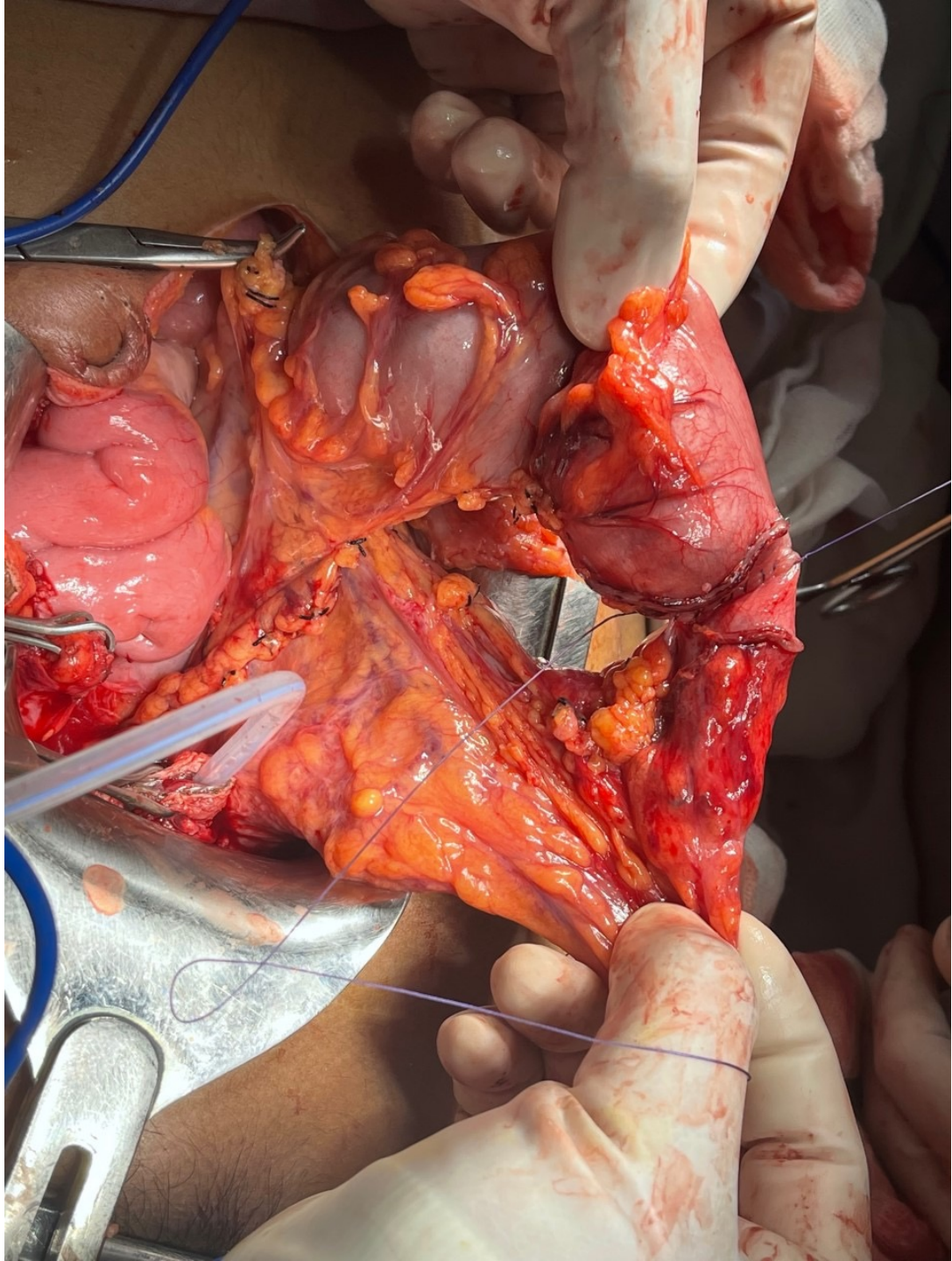
Vaginal replacement and Neo-malone.

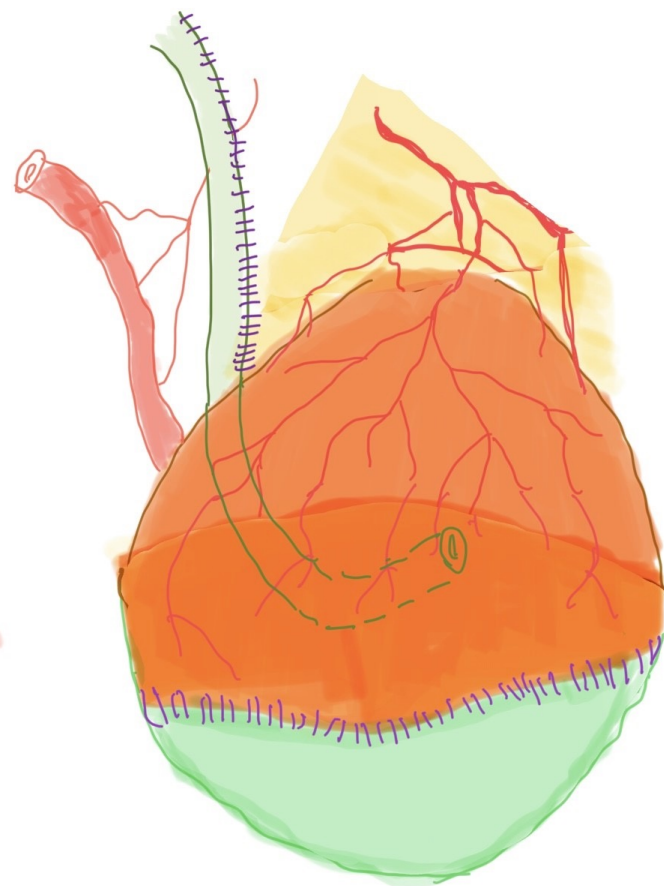
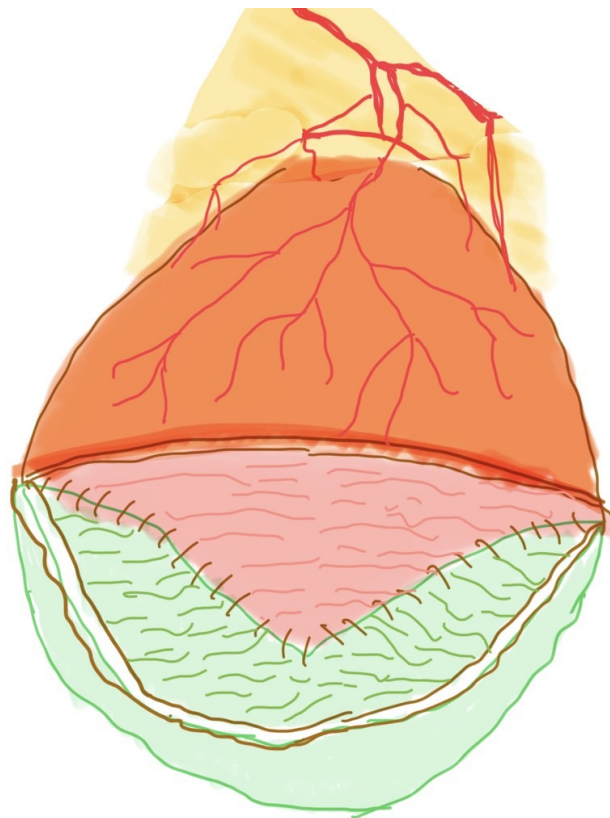
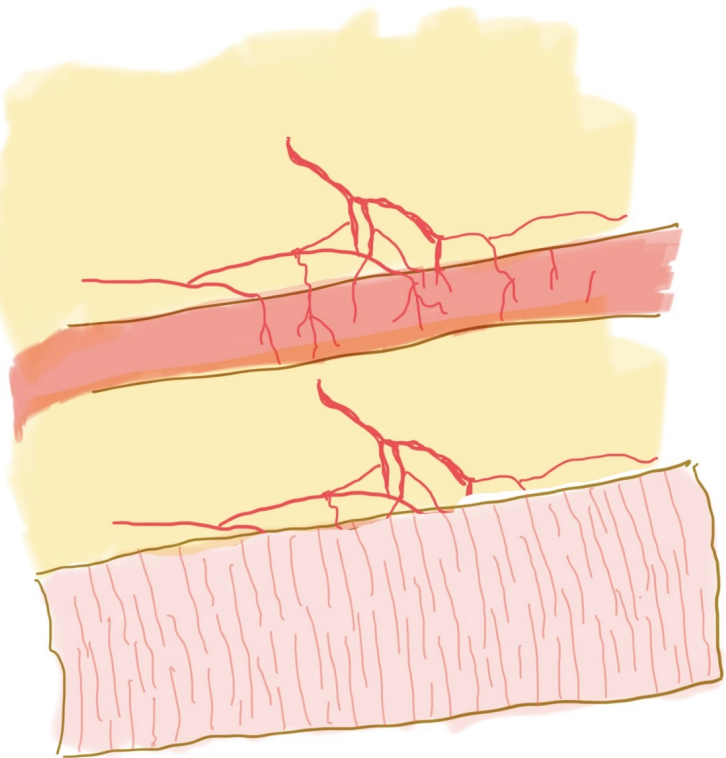
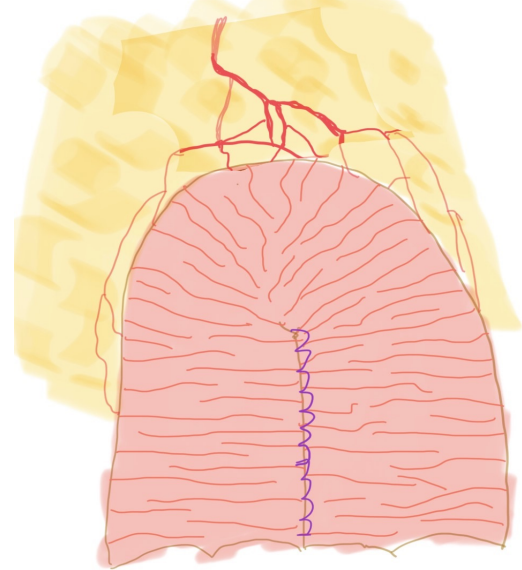
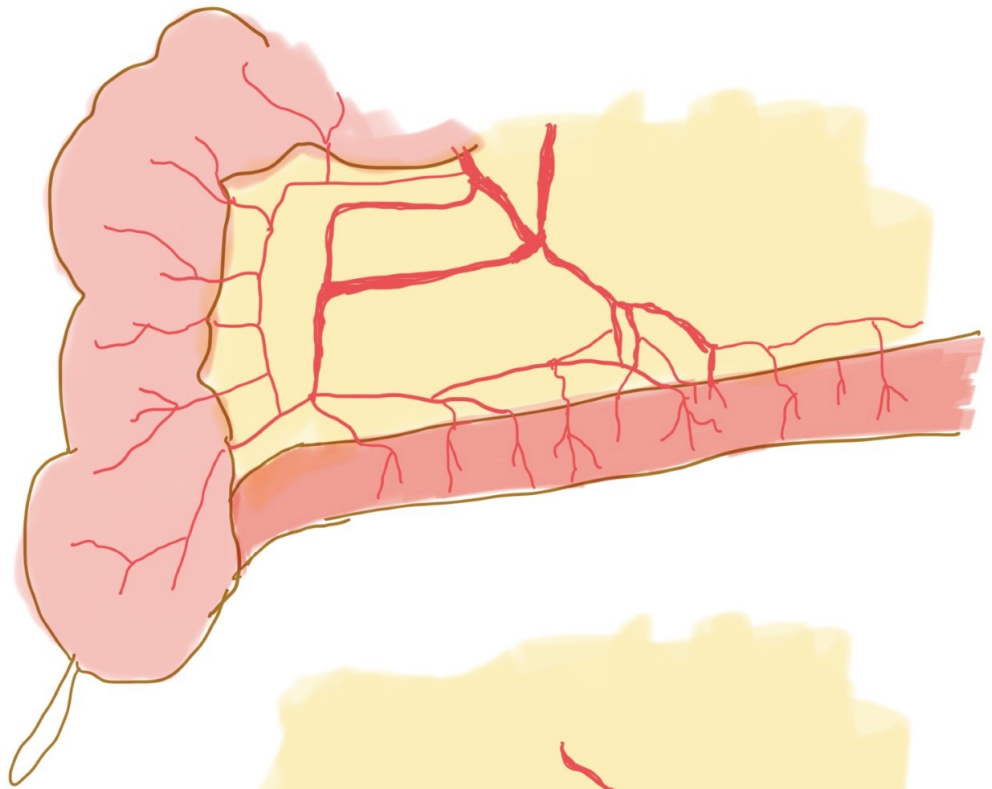


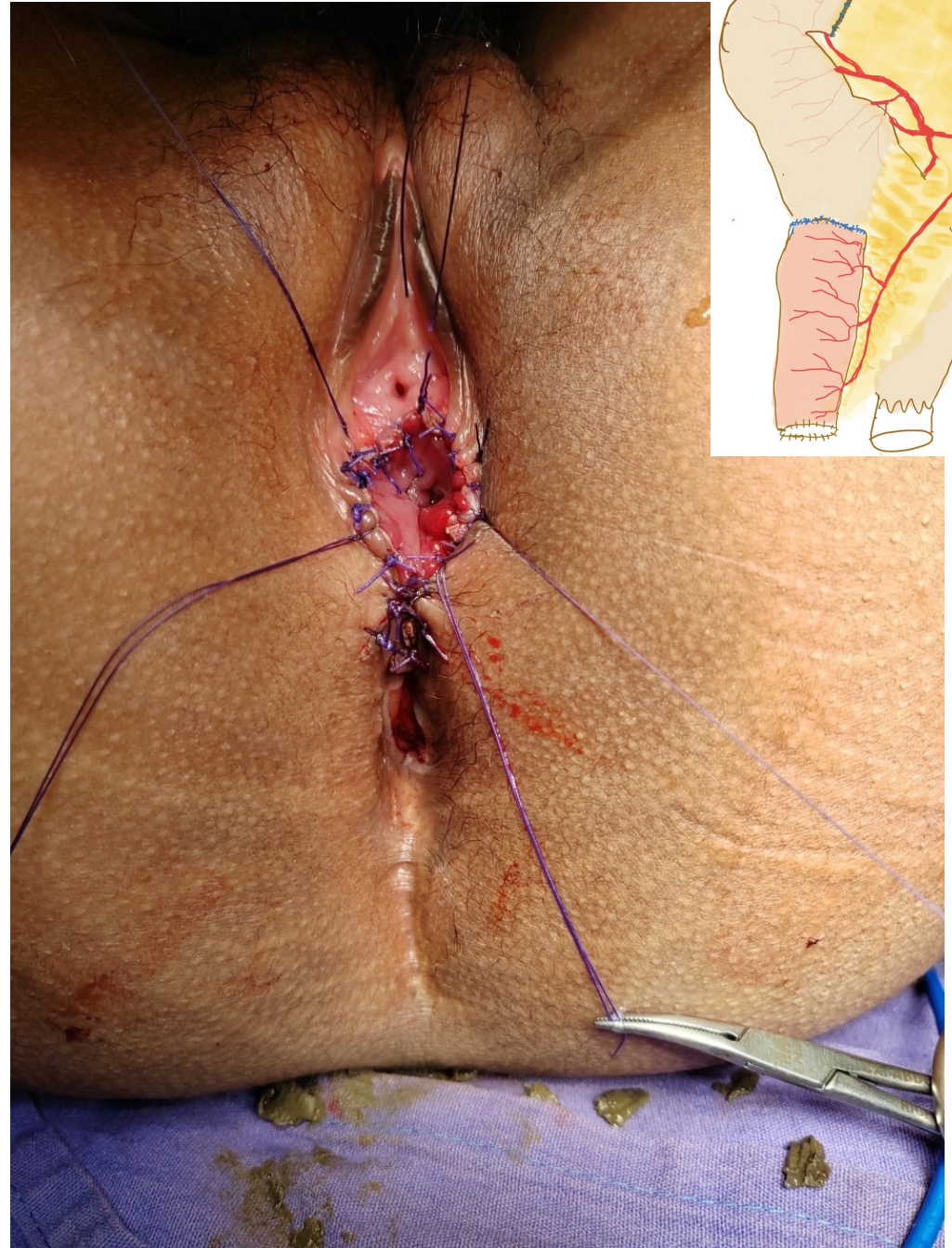
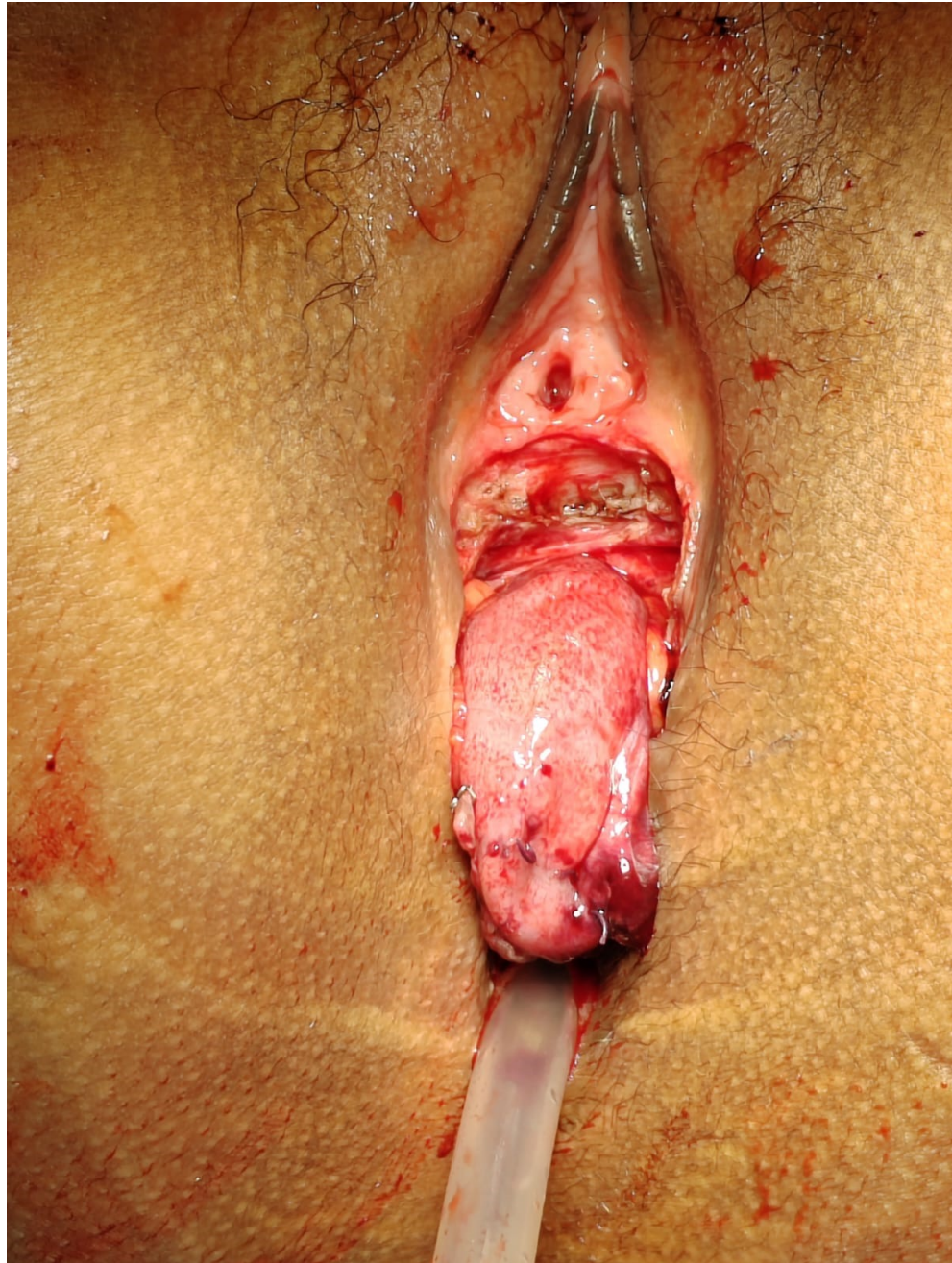

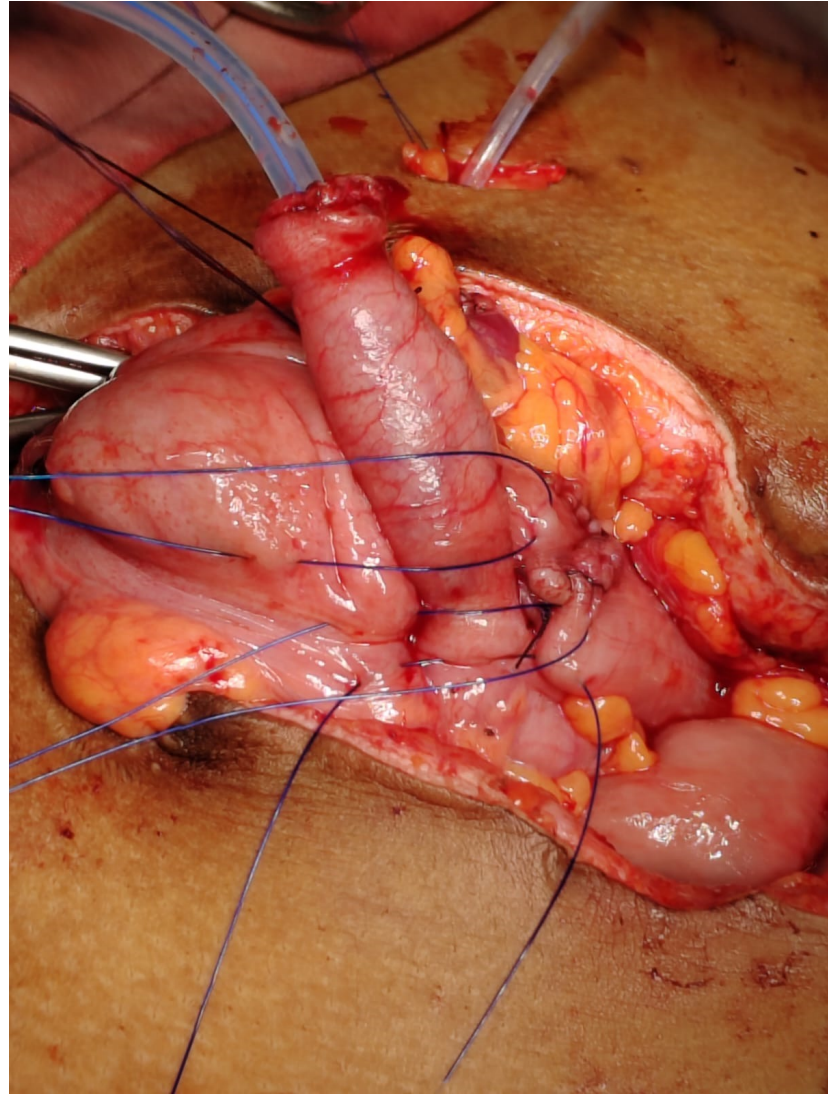
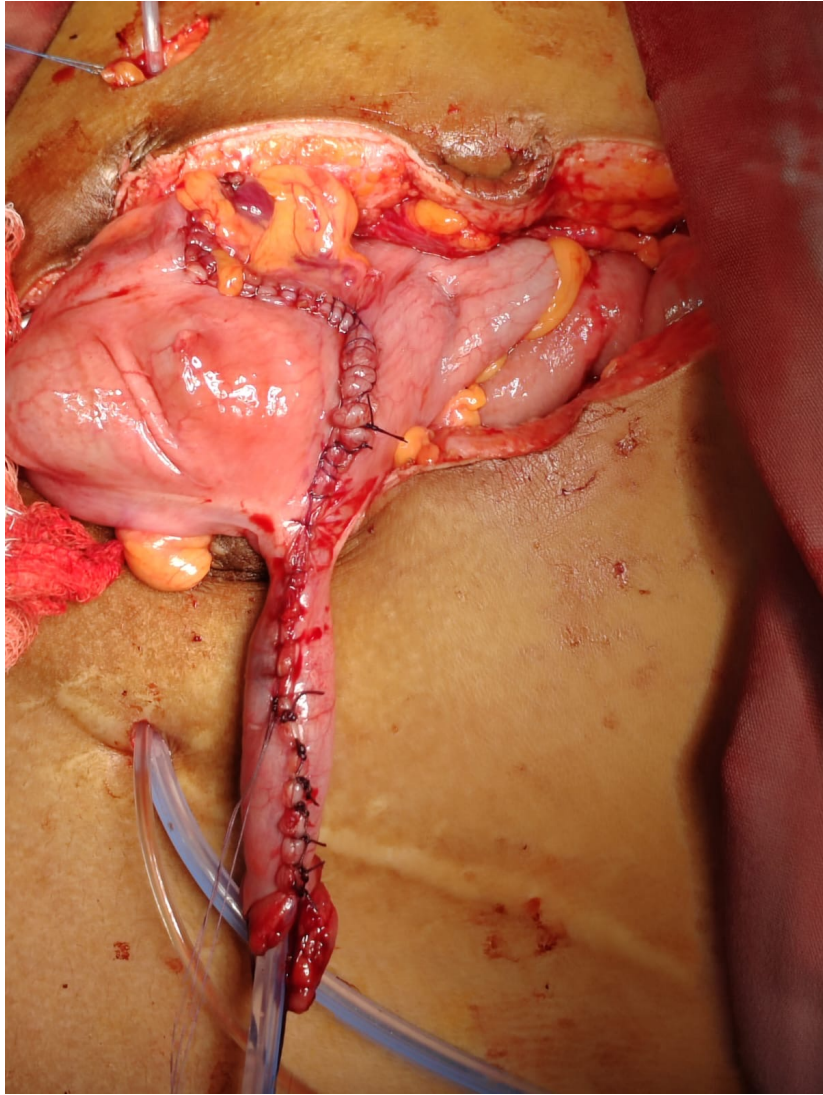












- Thank you.

