

Case # 4

Alberto Peña



Children's Hospital Colorado

INTERNATIONAL CENTER FOR
**COLORECTAL AND
UROGENITAL CARE**



8 yo male patient who suffered from constipation early in life.

He was diagnosed with an “anorectal malformation” and underwent an operation in another country.



Symptoms persisted, family moved to the USA, and he underwent a recto-sigmoid resection and a pullthrough for “Hirschsprung” + cecostomy tube insertion.

Histopathologic findings = normal ganglion cells.



Symptoms persisted, and
the family moved to
another State.

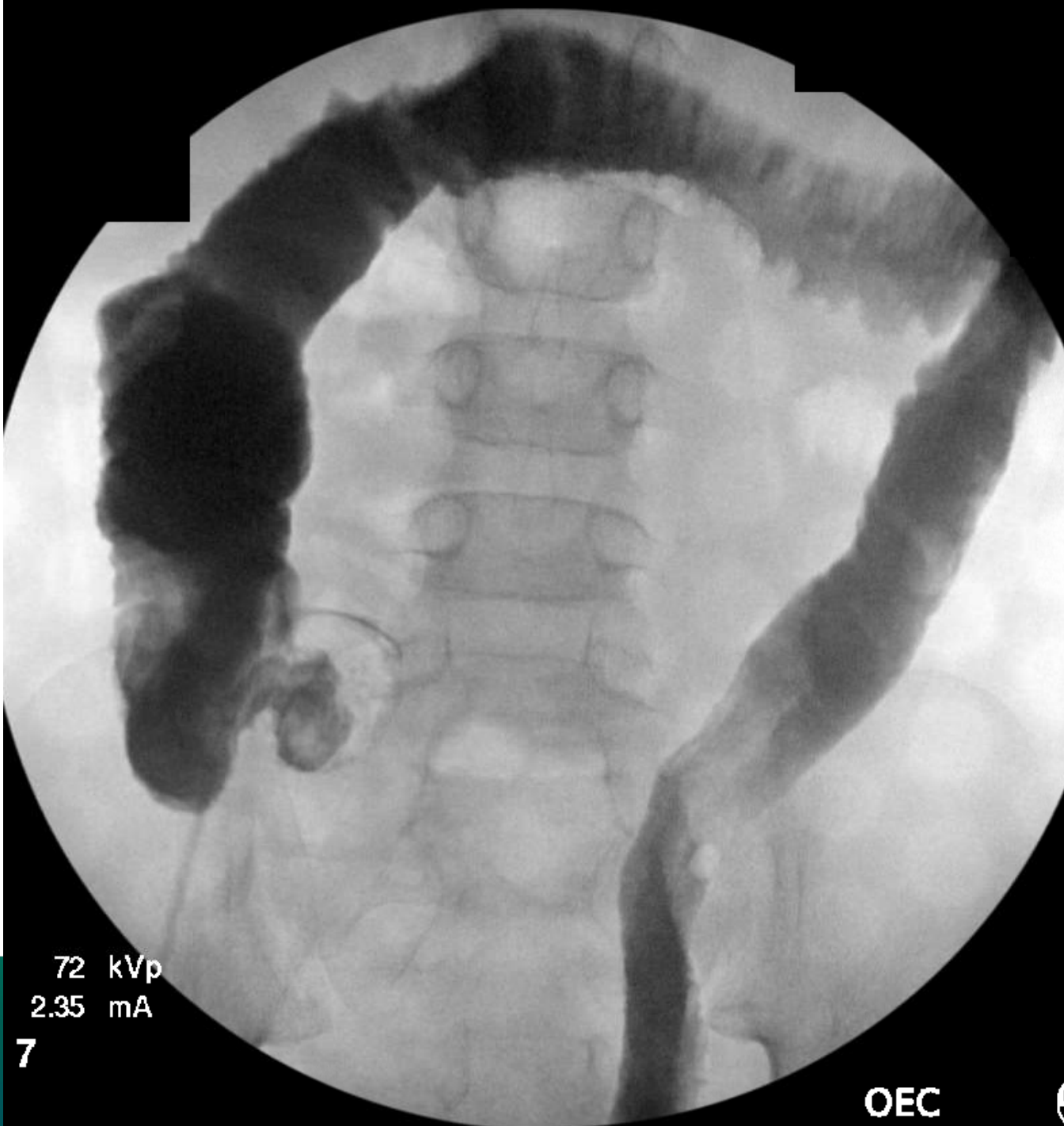


- A redo pullthrough was performed, cecostomy was closed and a neo-appendicostomy was opened.
- Developed a stricture - underwent 7 dilations under anesthesia.



Patient came to us:

- ileostomy
- wait 3 months

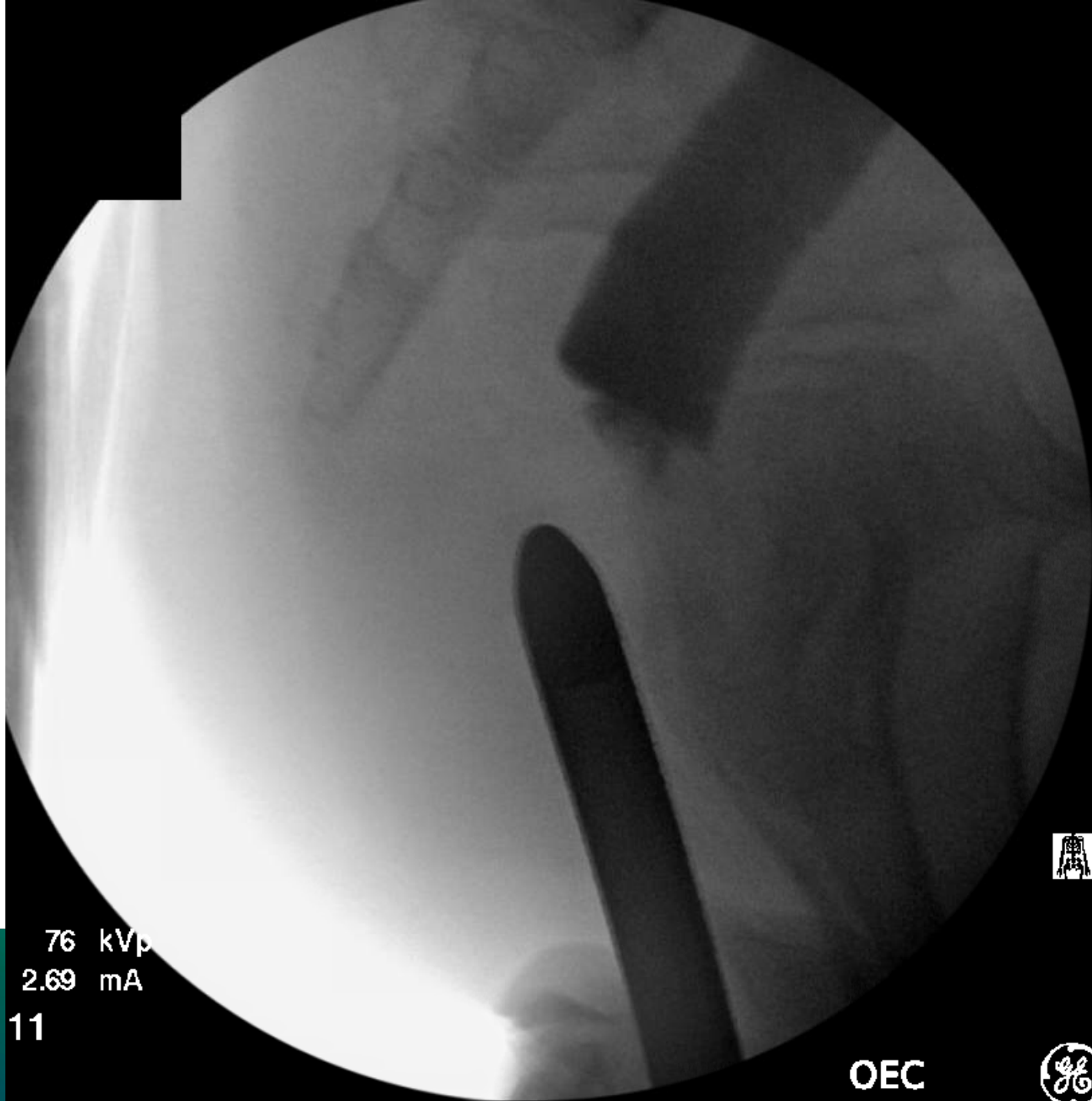

72 kVp
2.35 mA

7

OEC

CENTER FOR
PATIENT SAFETY AND
QUALITY IMPROVEMENT



76 kVp
2.69 mA

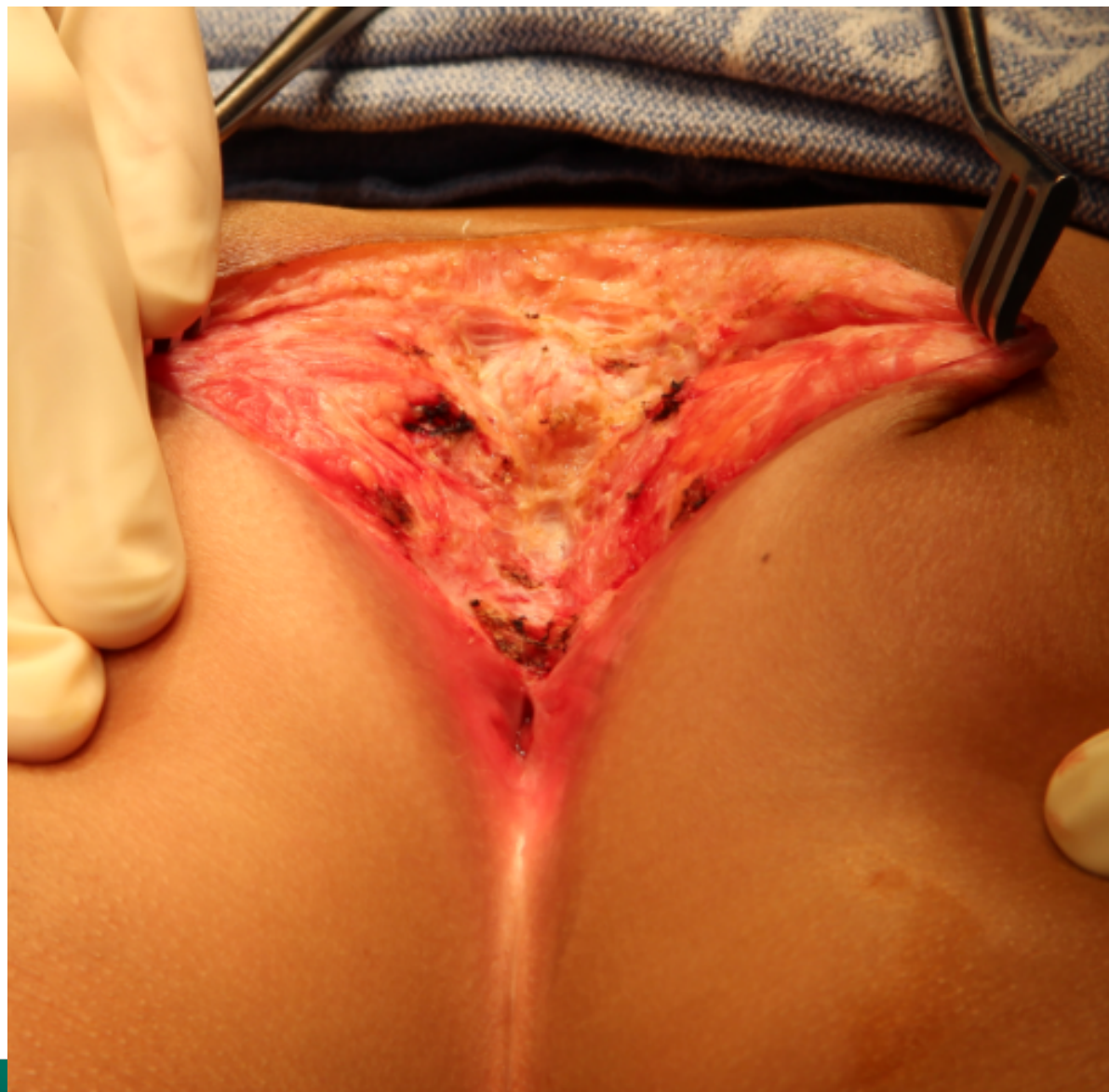11

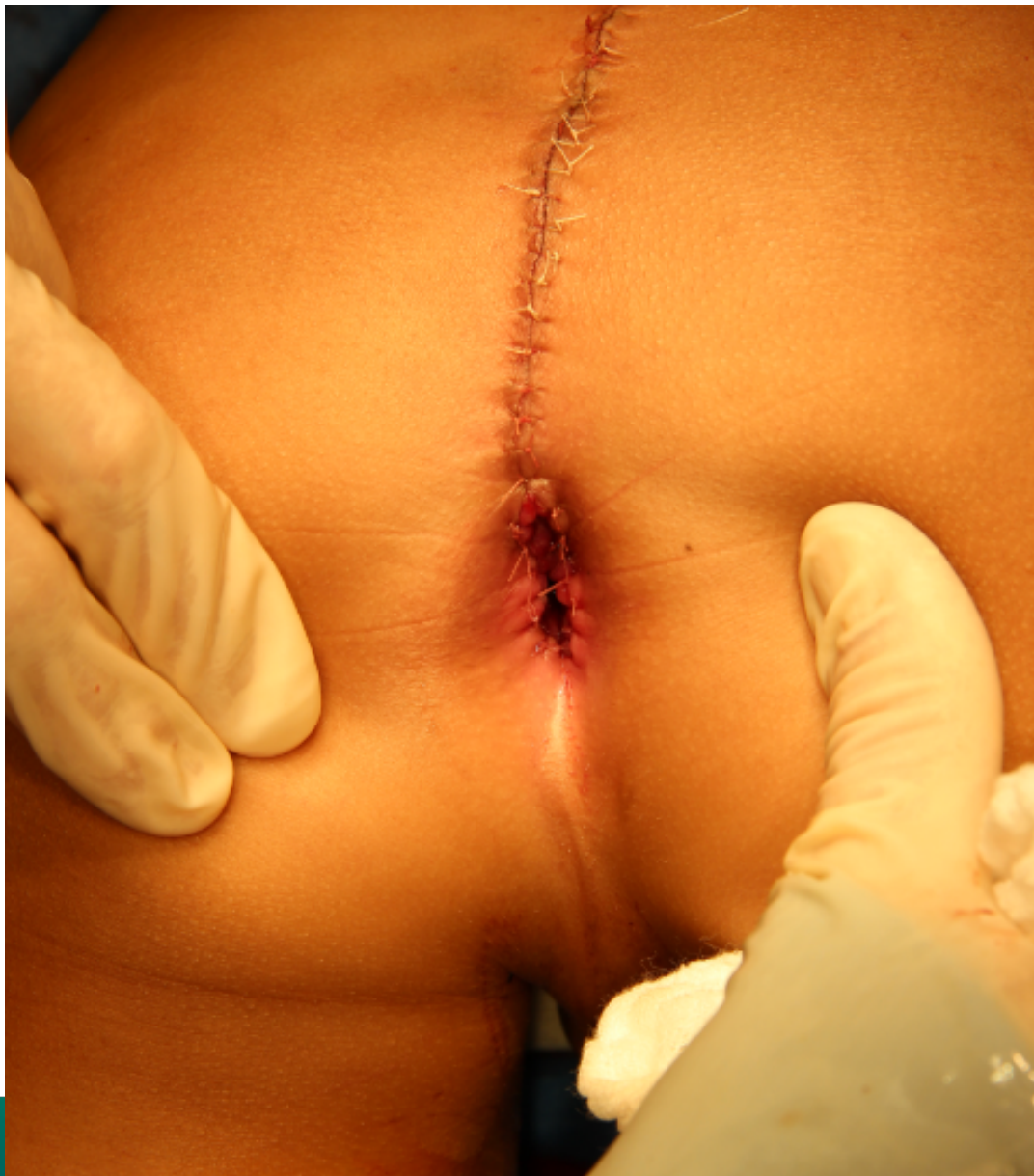

OEC

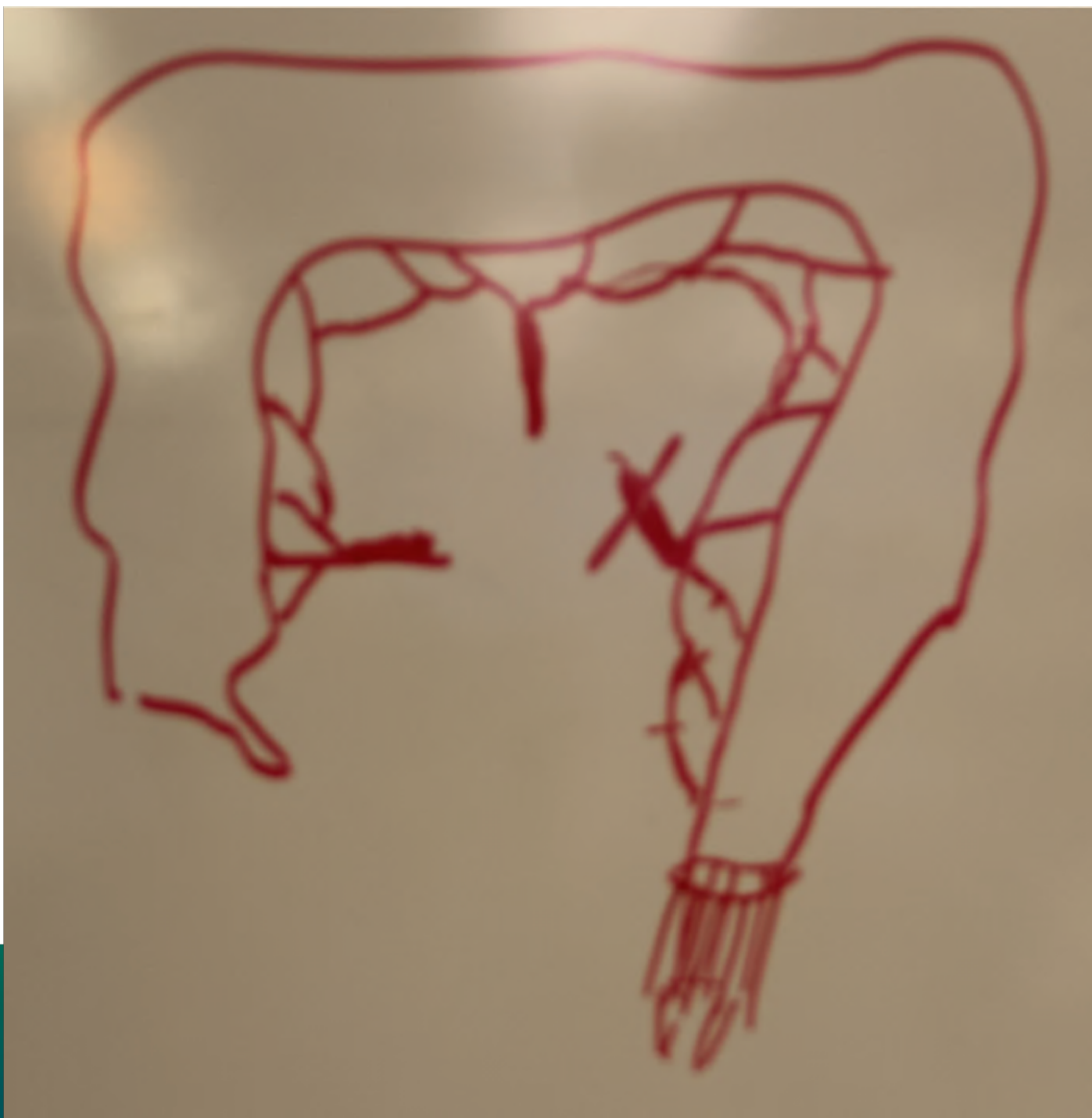


FOR
ND
ARE





NATIONAL CENTER FOR
**COLORECTAL AND
UROGENITAL CARE**



ER FOR
AND
ARE