



COLORECTAL WEB MEETING
DECEMBER 15, 2022
Hospital Infantil de Mexico Federico Gomez
Mexico City

ITZEL LIZARRAGA MD

EMILIO FERNANDEZ MD

ROBERTO DAVILA MD

CASE

- FEMALE
- 18 YEARS OLD
- ANORRECTAL MALFORMATION – RECTOVESTIBULAR FISTULA
- ABSENT VAGINA
- FECALLY CONTINENT
- SR : 0.6

BACKGROUND

- ❑ 8 MONTH: **PSARP & “DISTAL VAGINOPLASTY”**: **LOWER VAGINAL ATRESIA**

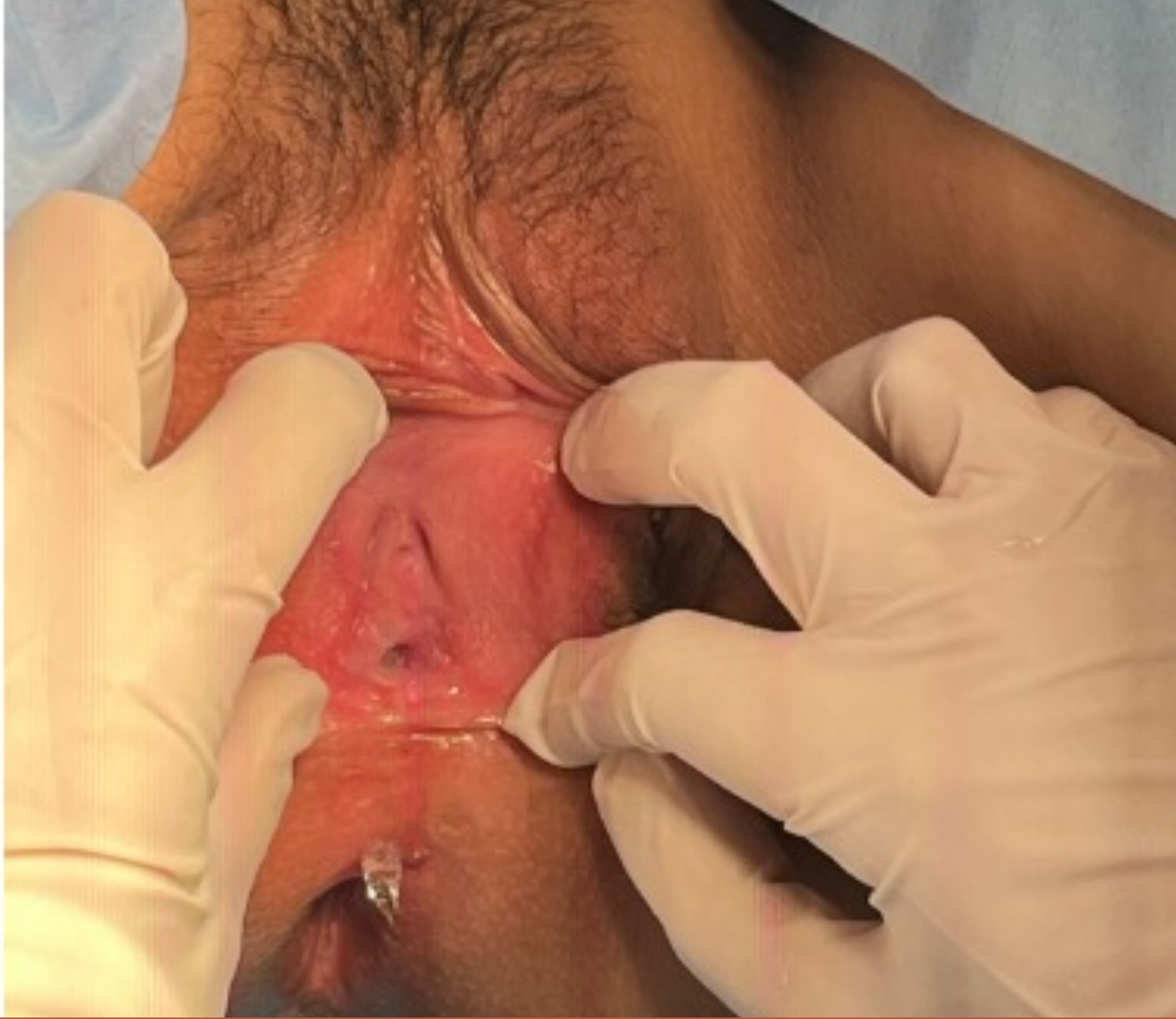- ❑ 12 YEARS: SEVERE ABDOMINAL PAIN
 - ❑ **EXPLORATORY LAPAROTOMY + DRAINAGE OF HEMATOCOLPOS + LEFT VAGINOSTOMY : 350 CC**

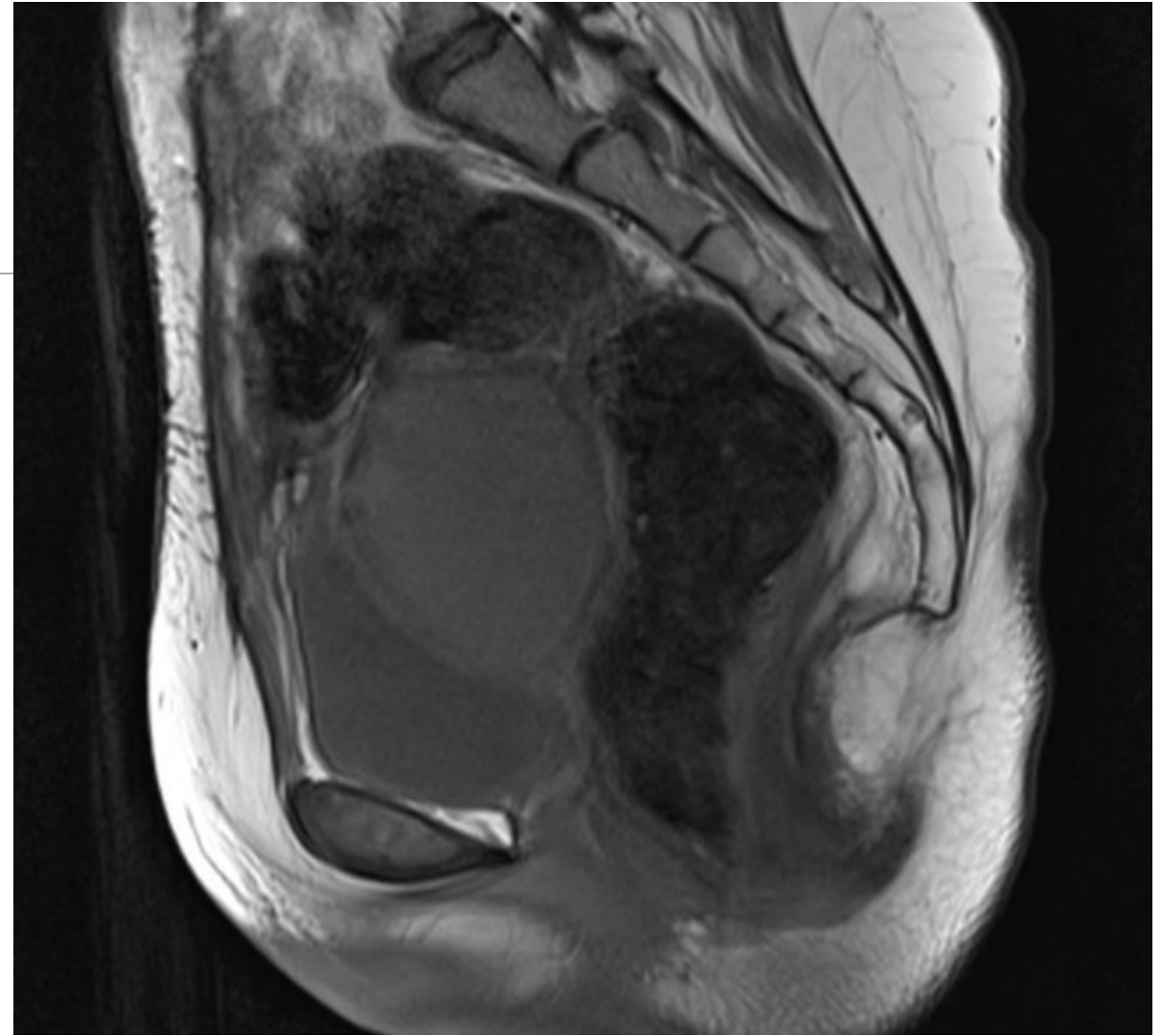
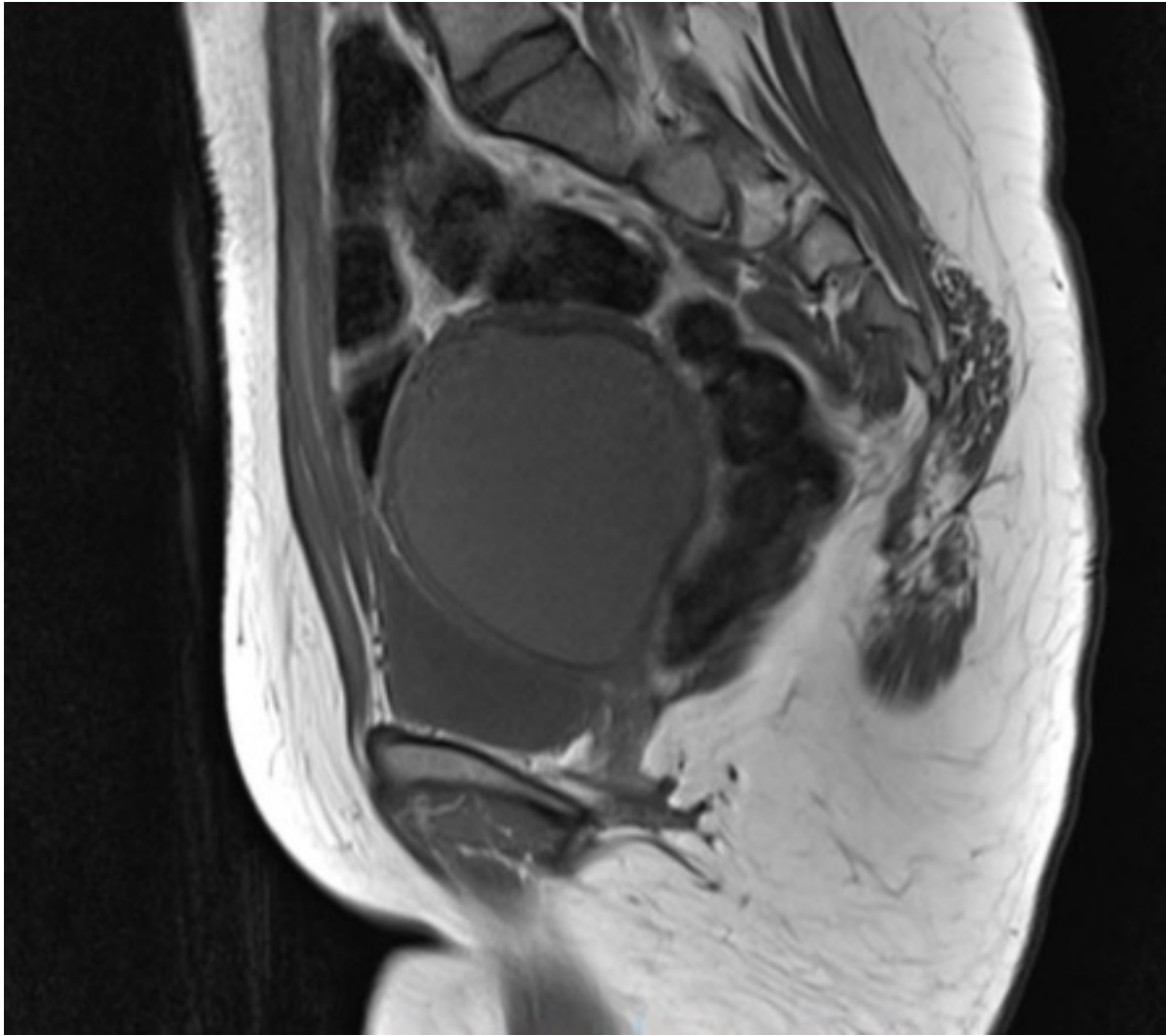
- ❑ 13 YEARS: **DISFUNCTIONAL VAGINOSTOMY: DRAINAGE OF HEMATOCOLPOS: 50 CC**
 - ❑ CONTINUE WITH FEVER AND PAIN
 - ❑ **EXPLORATORY LAPAROTOMY + RESECTION OF LEFT REMANENT VAGINA + DRAINAGE OF PELVIC ABCESS**

BACKGROUND

- ❑ 16 YEARS: POSTOPERATIVELY NO ABDOMINAL DISTENTION, STOOLING DAILY
 - ❑ SHE STOPPED DOING VAGINAL DILATATIONS
 - ❑ MENSTRUAL PERIODS THROUGH VAGINOSTOMY

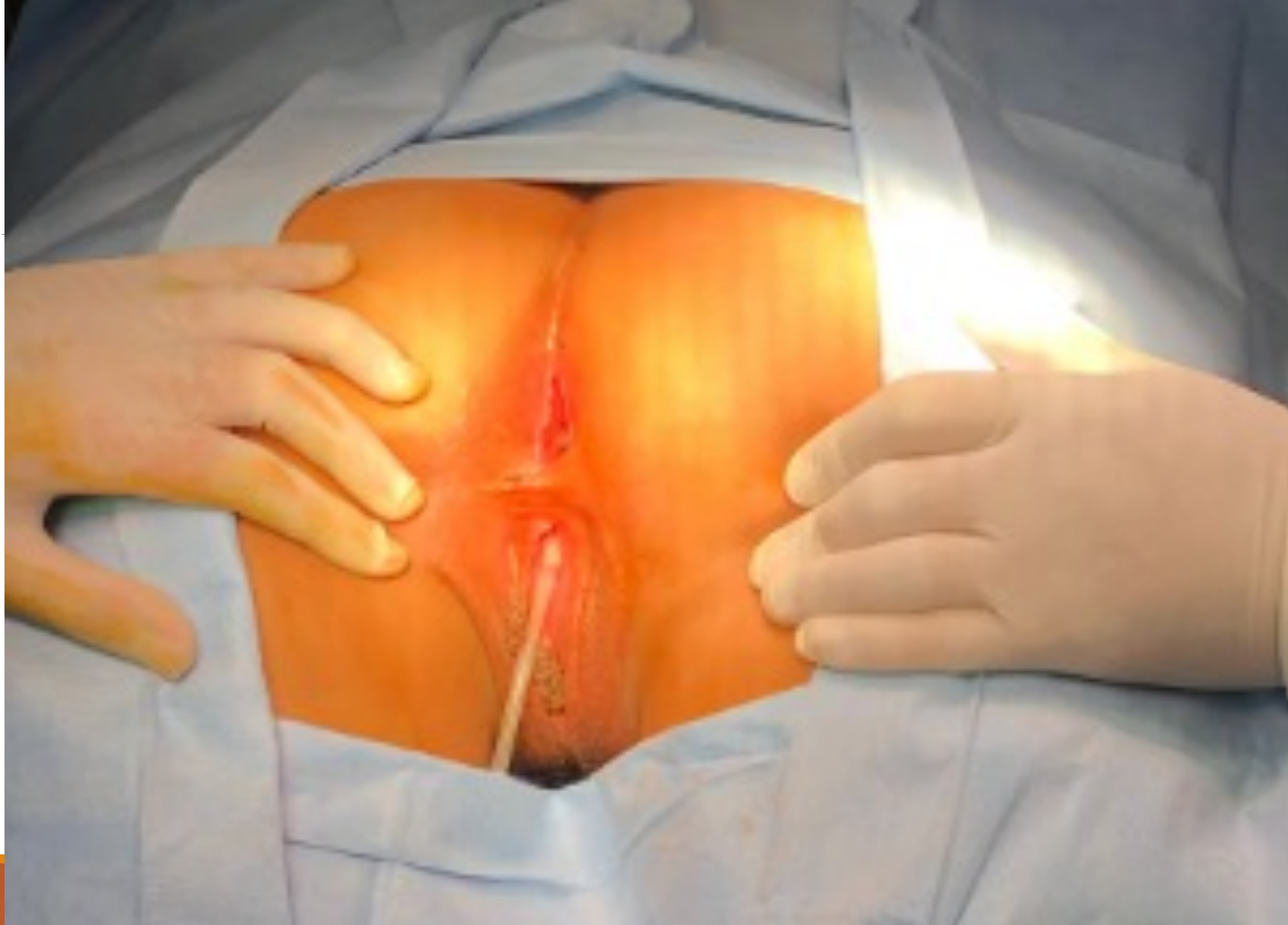- ❑ 18 YEARS ARRIVED AT COLORECTAL CLINIC: EXAMINATION UNDER ANESTESIA:

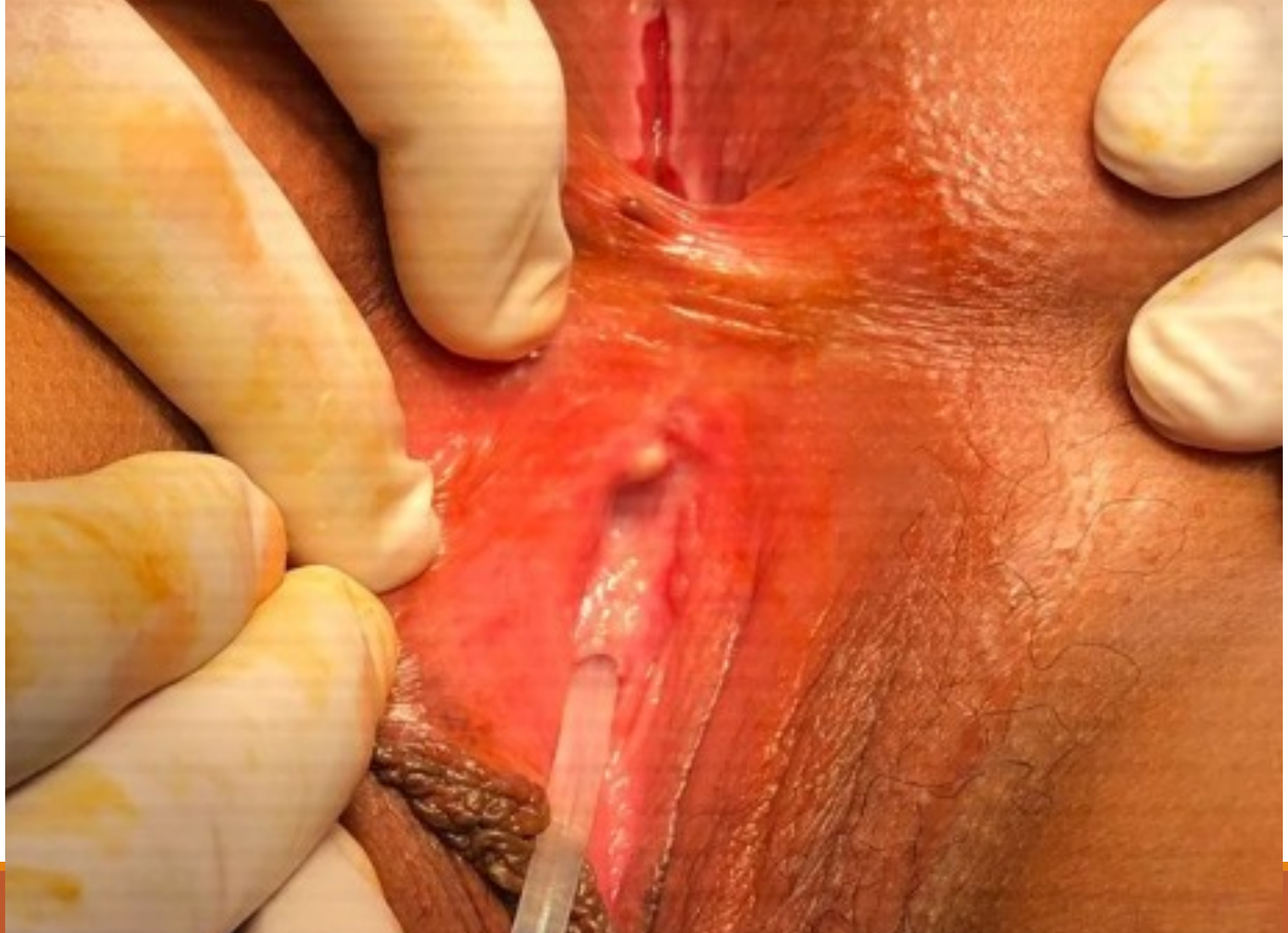

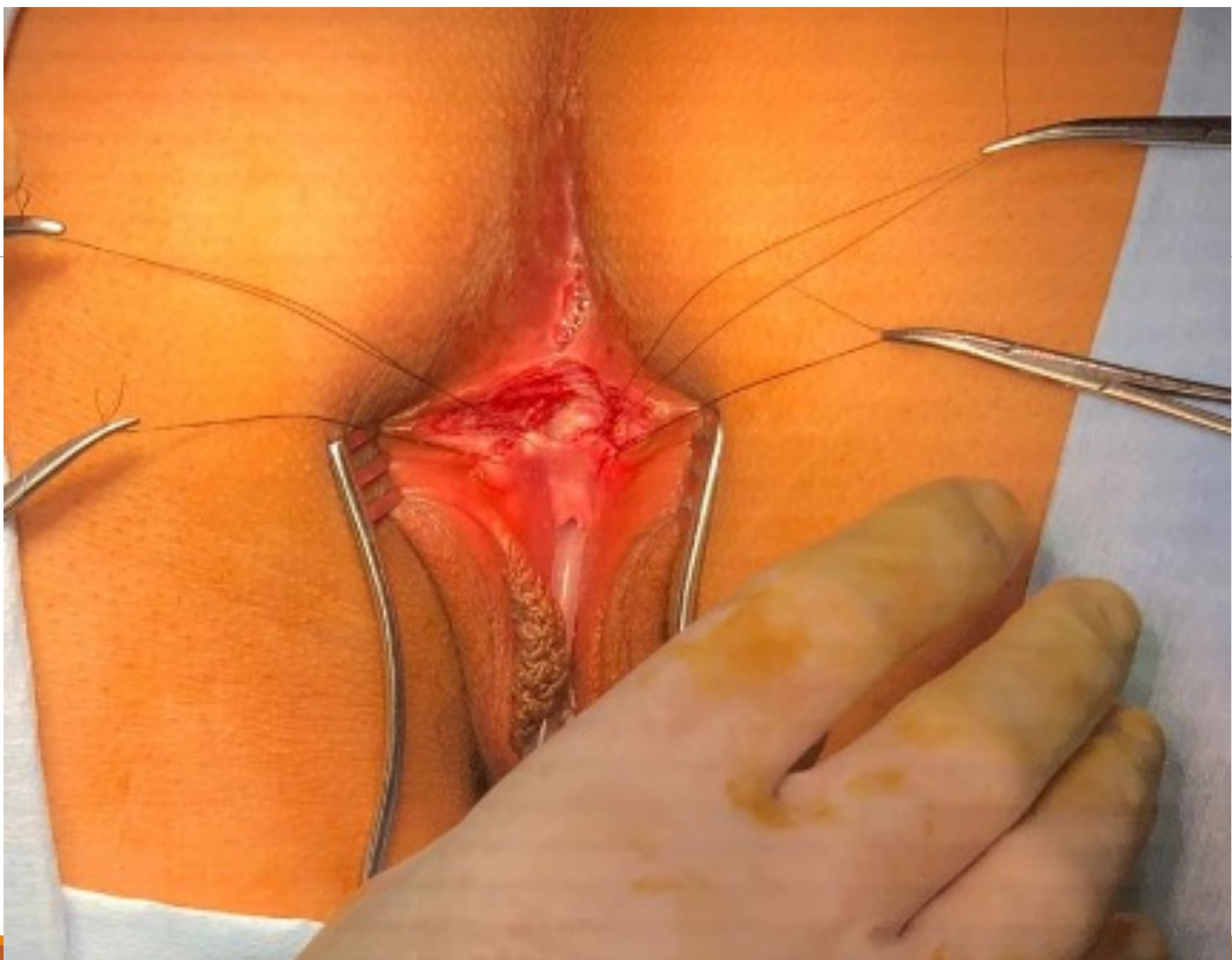


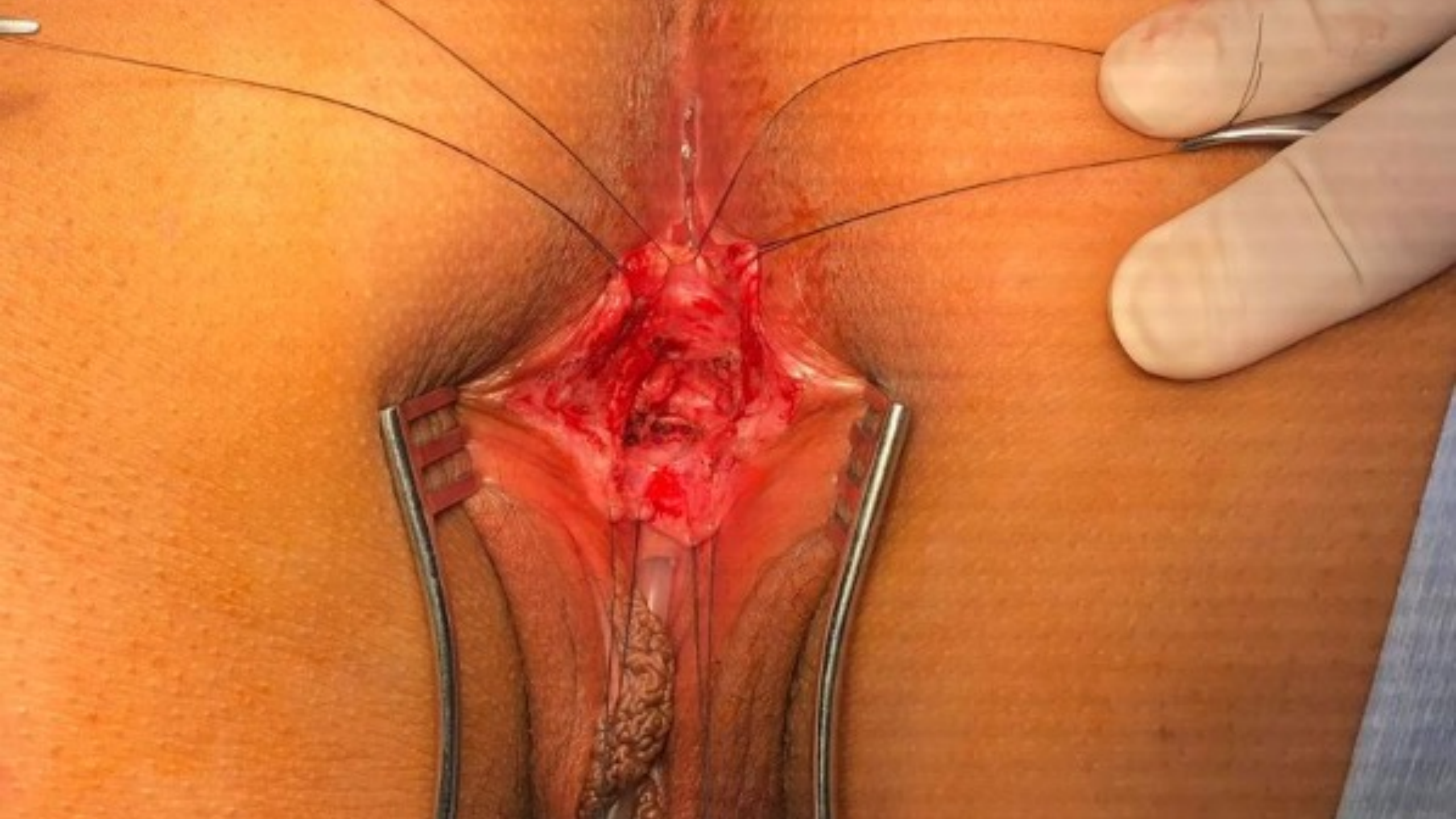What would your approach be?

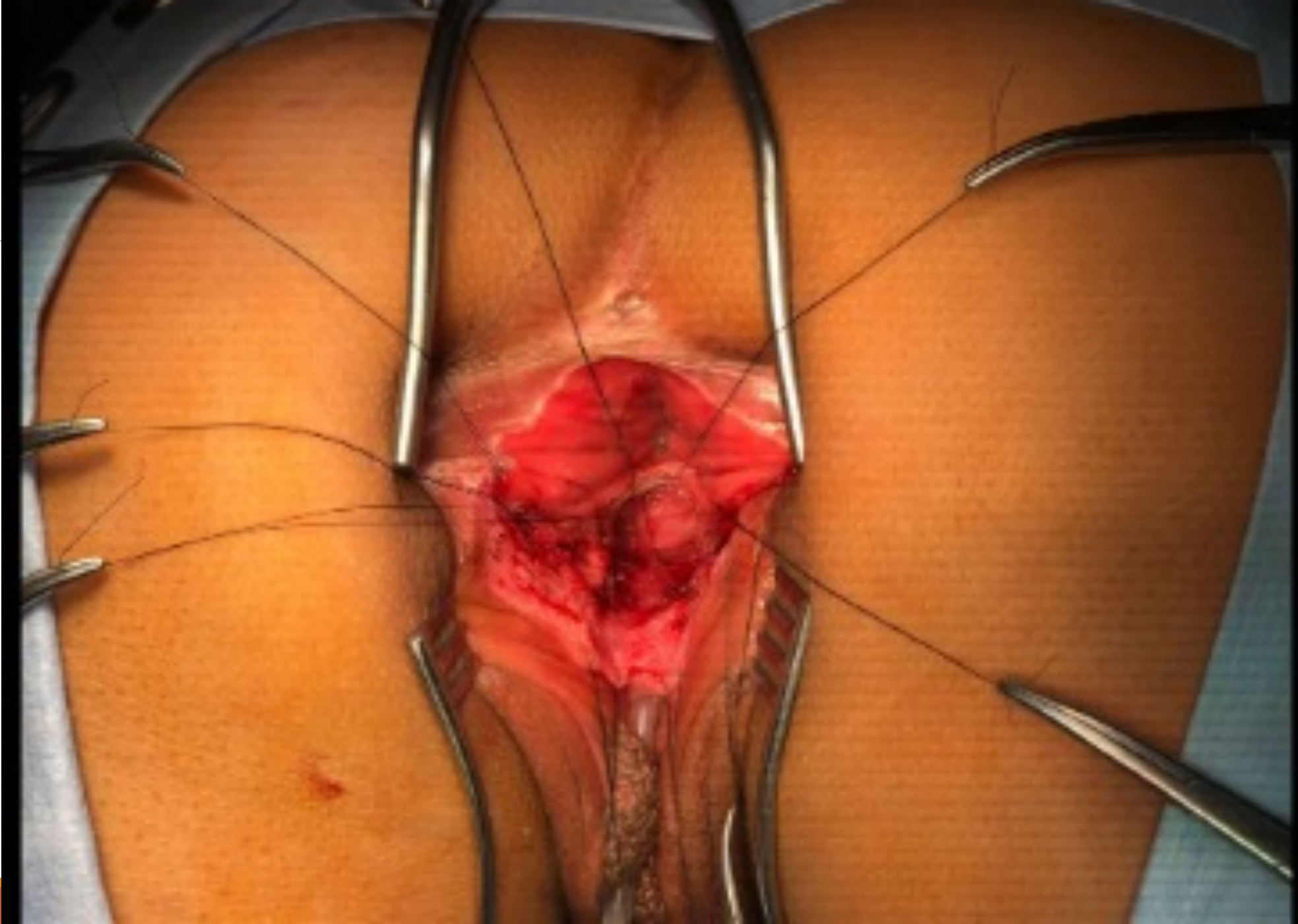1. TRANSANORECTAL ANTERIOR SAGITAL APPROACH AND PROXIMAL VAGINAL PULL THROUGH
2. TOTAL VAGINAL REPLACEMENT WITH BOWEL
3. POSTERIOR SAGITAL APPROACH WITH MOVILIZATION OF RECTUM AND PROXIMAL VAGINAL PULL THROUGH

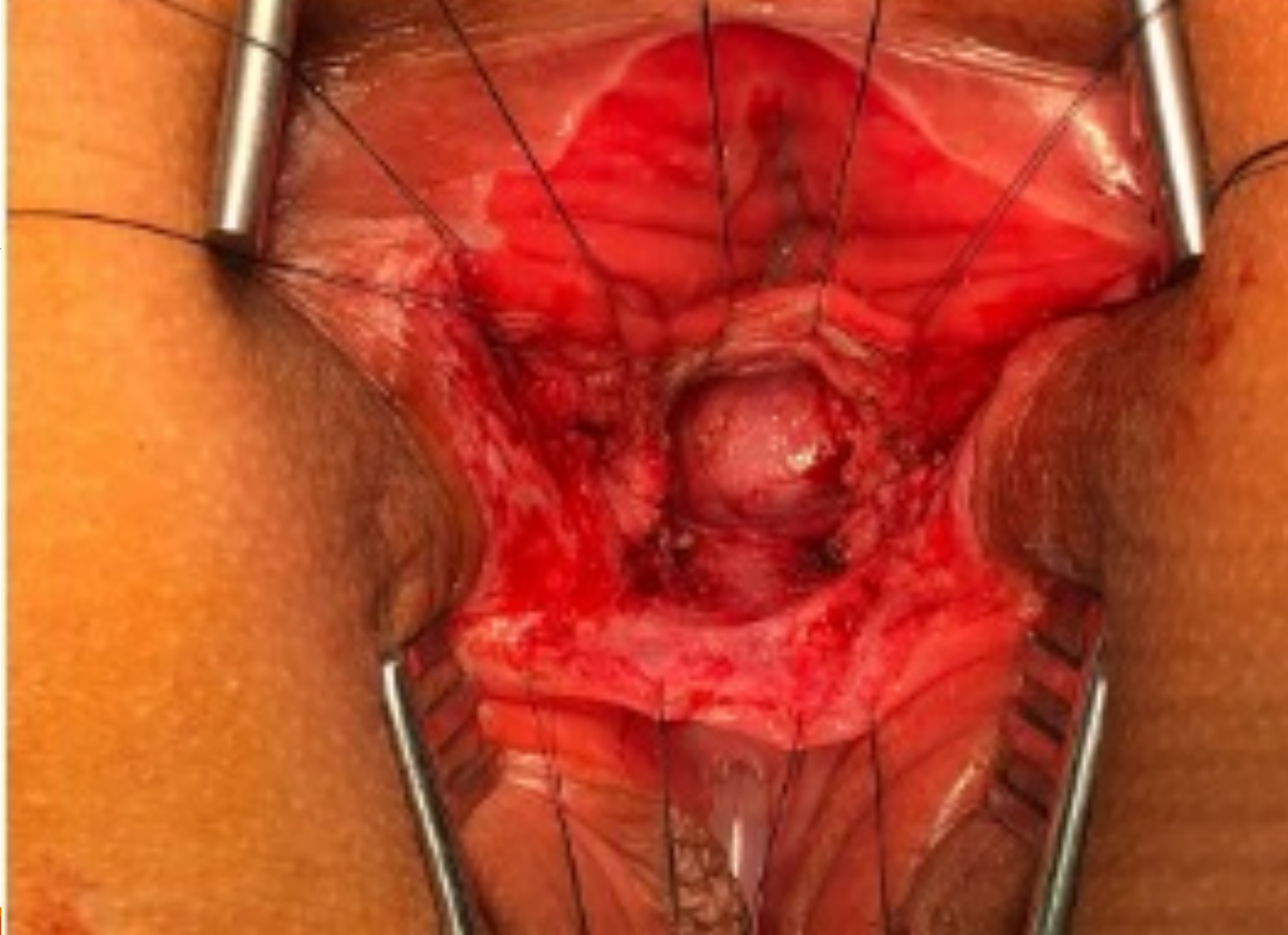

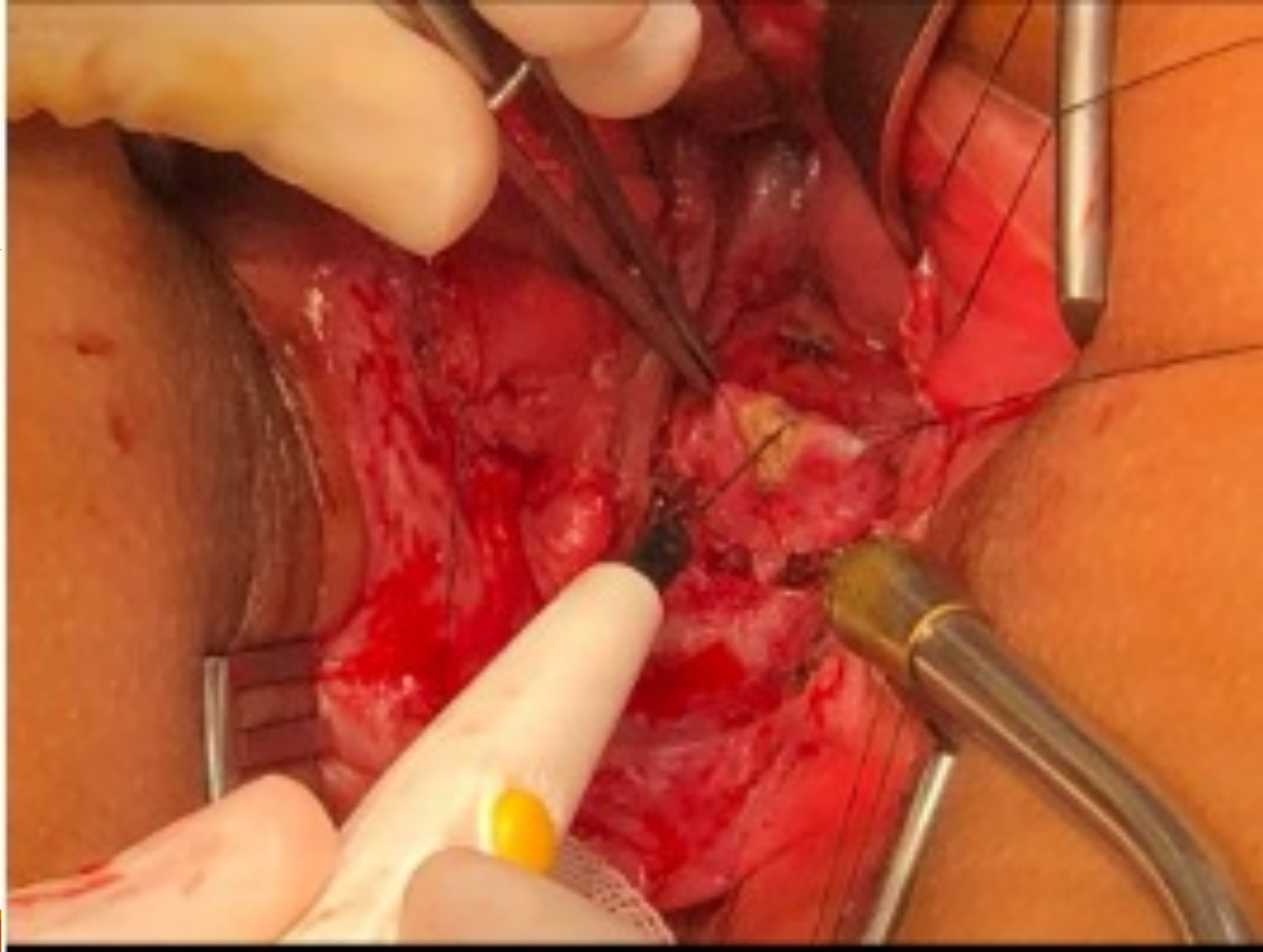



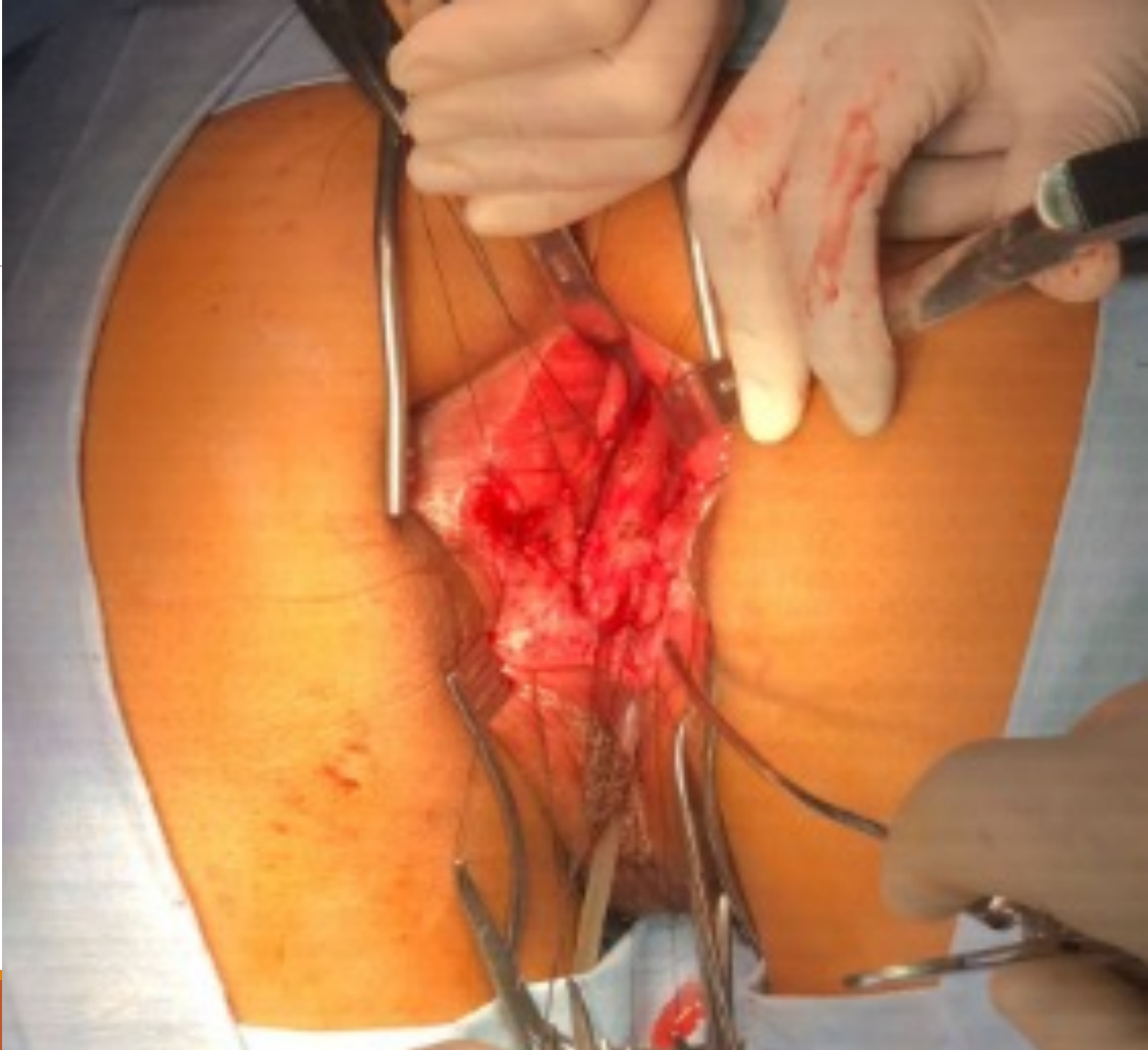


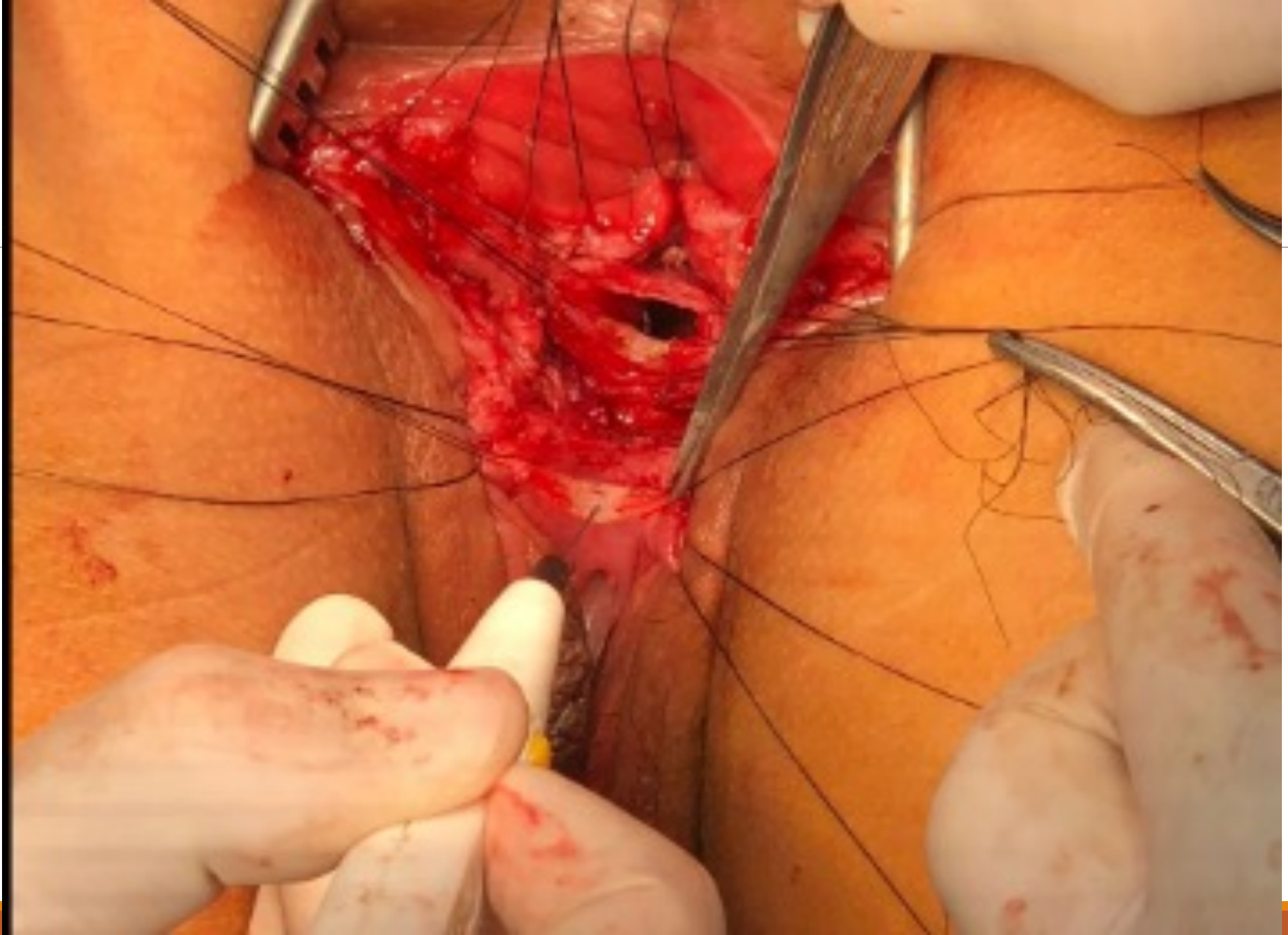


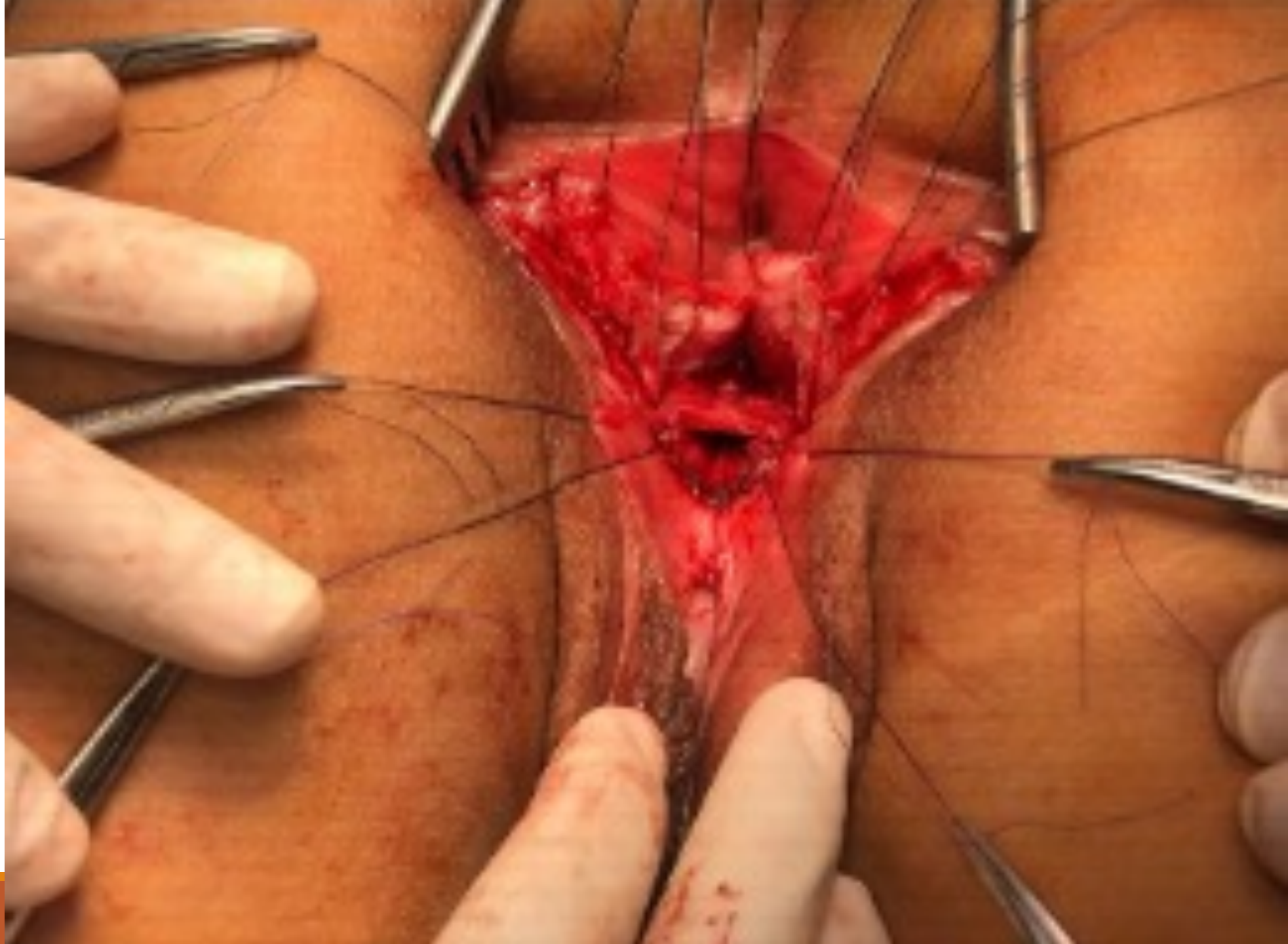


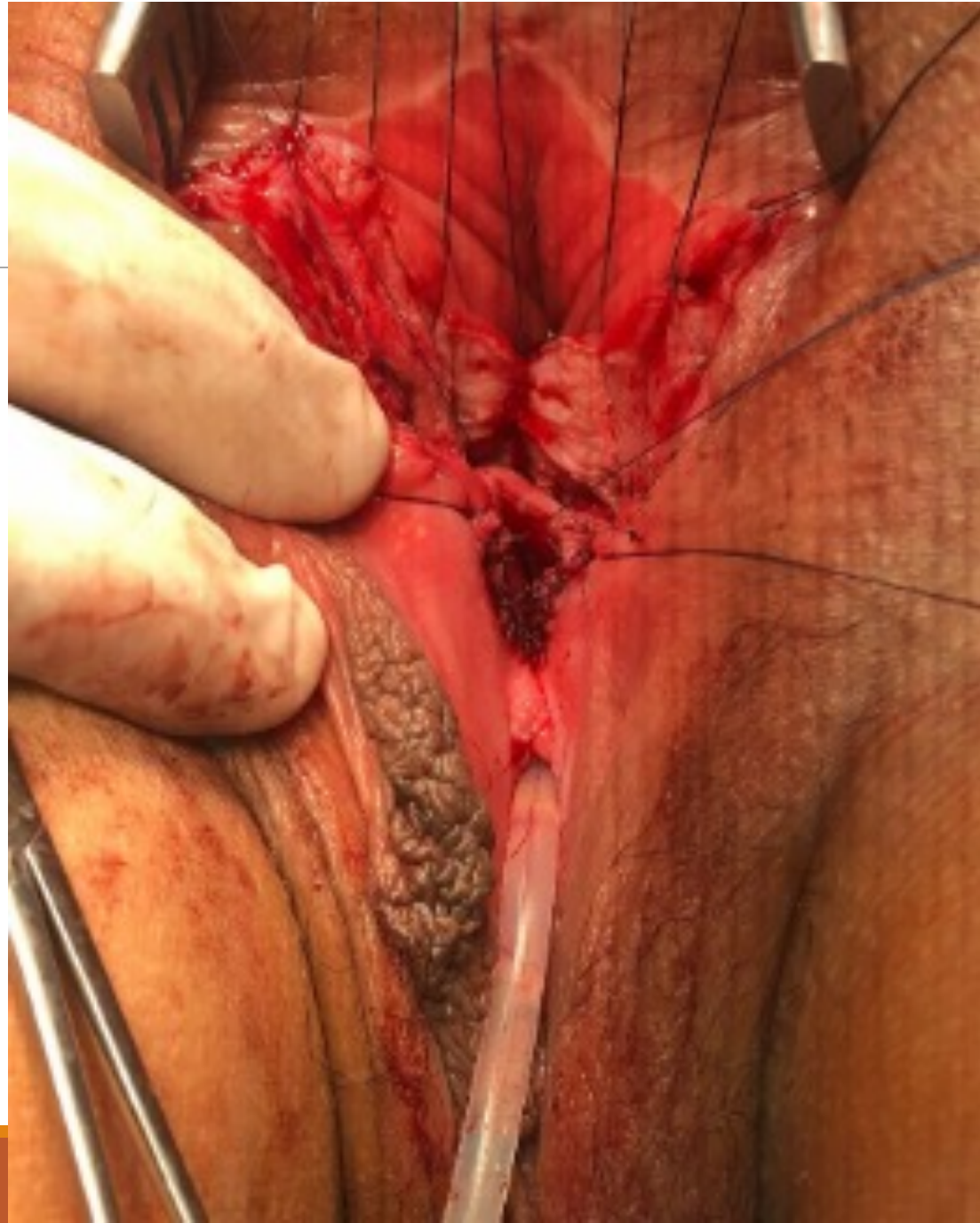


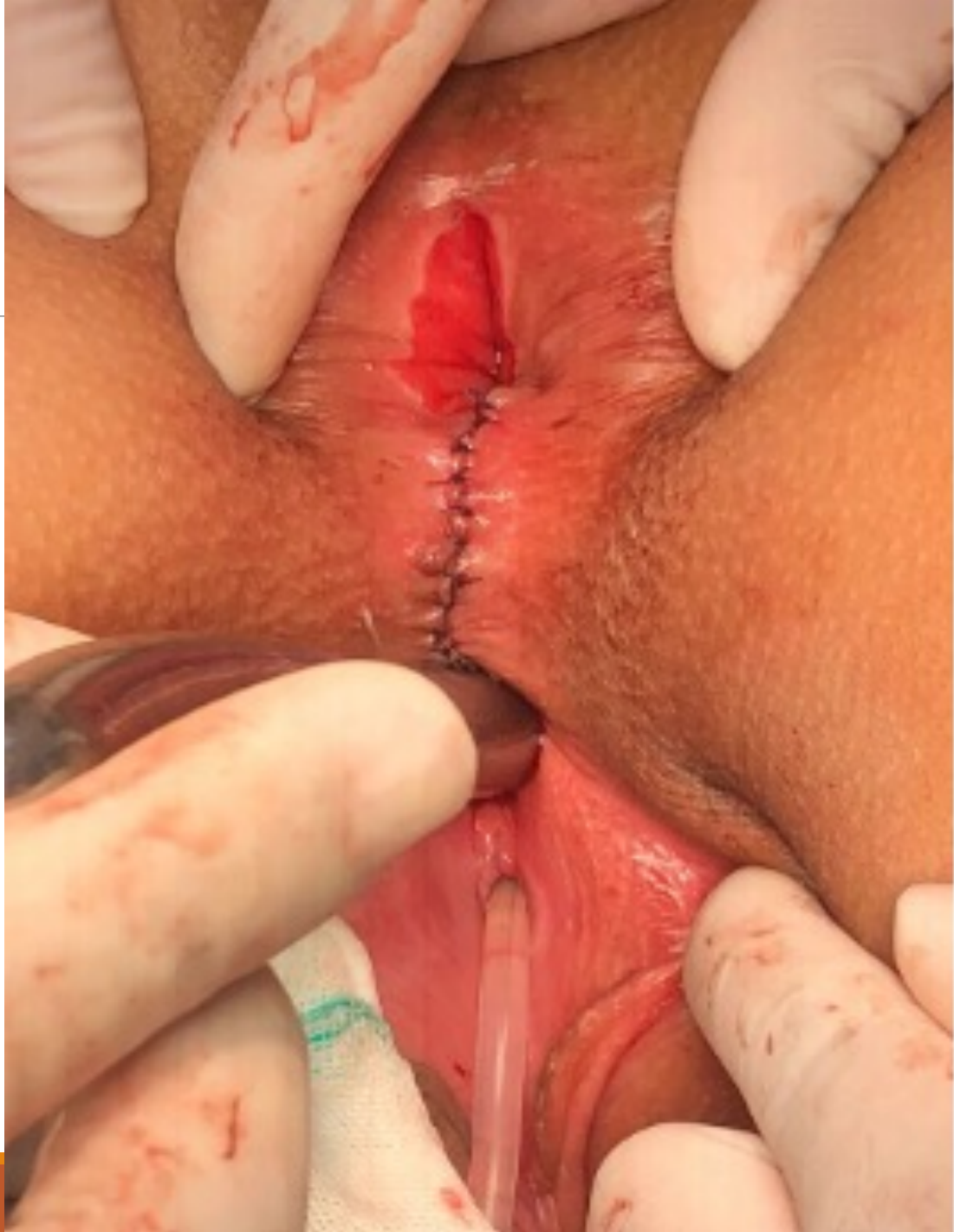






OUTCOME

NORMAL PERIODS THROUGH
VAGINA

EUA SCHEDULED IN THE NEXT 3
MONTHS

FECALLY CONTINENT



HAPPY HOLIDAYS

THANK YOU

