

# Case # 5

---

Andrea Bischoff

December 15<sup>th</sup>, 2022

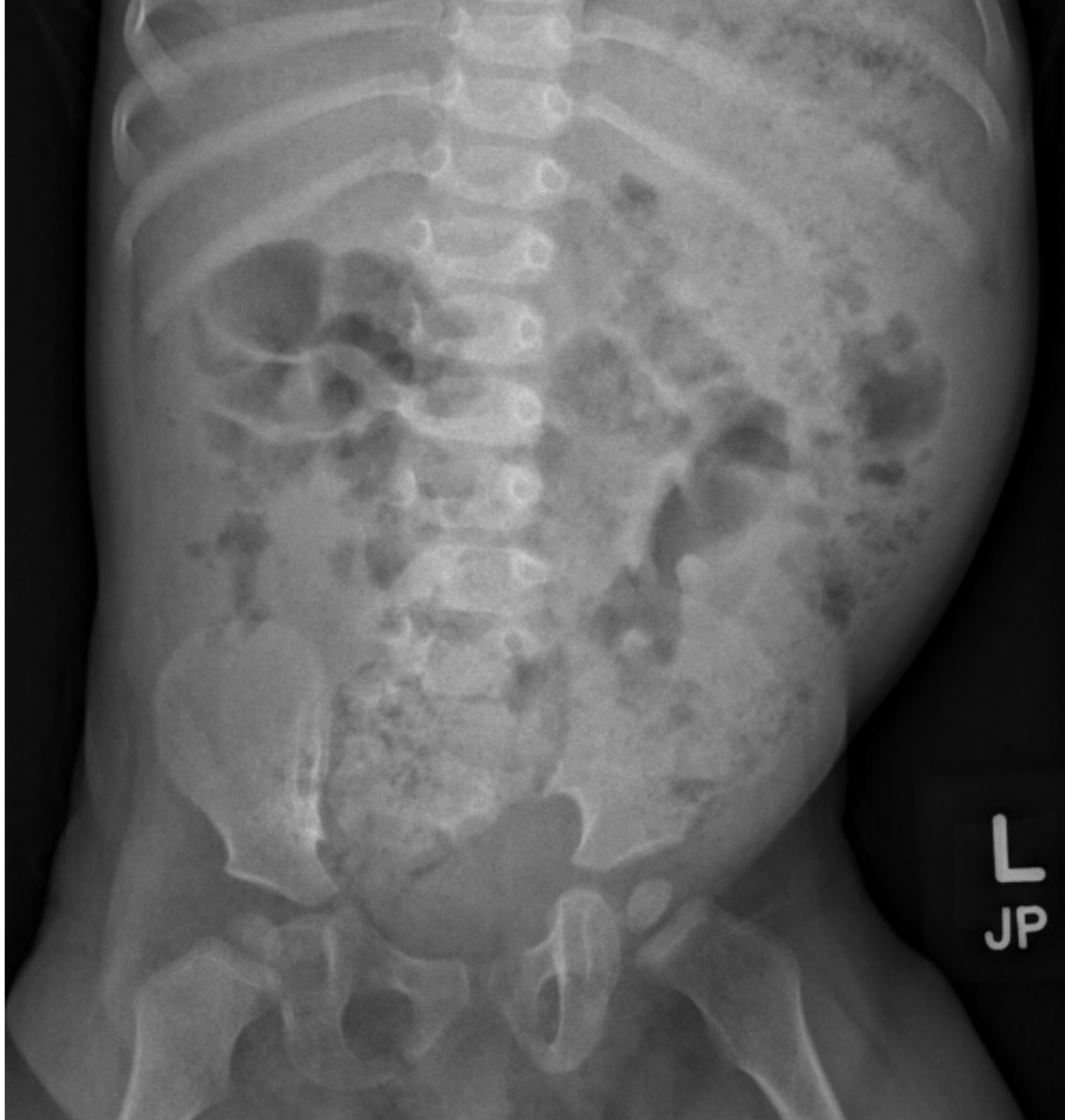

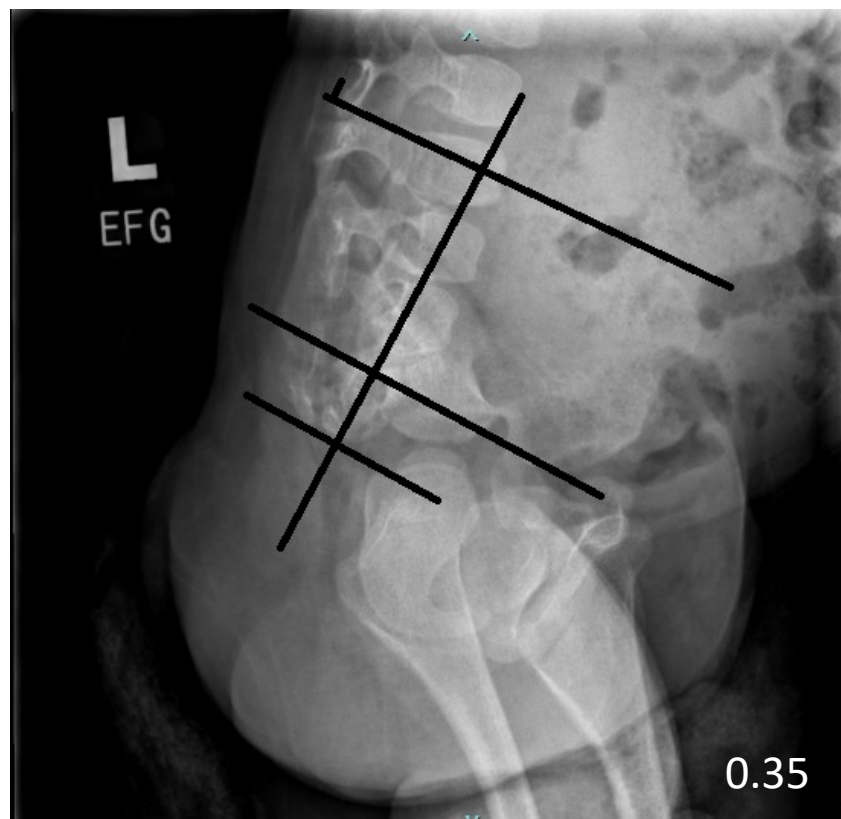
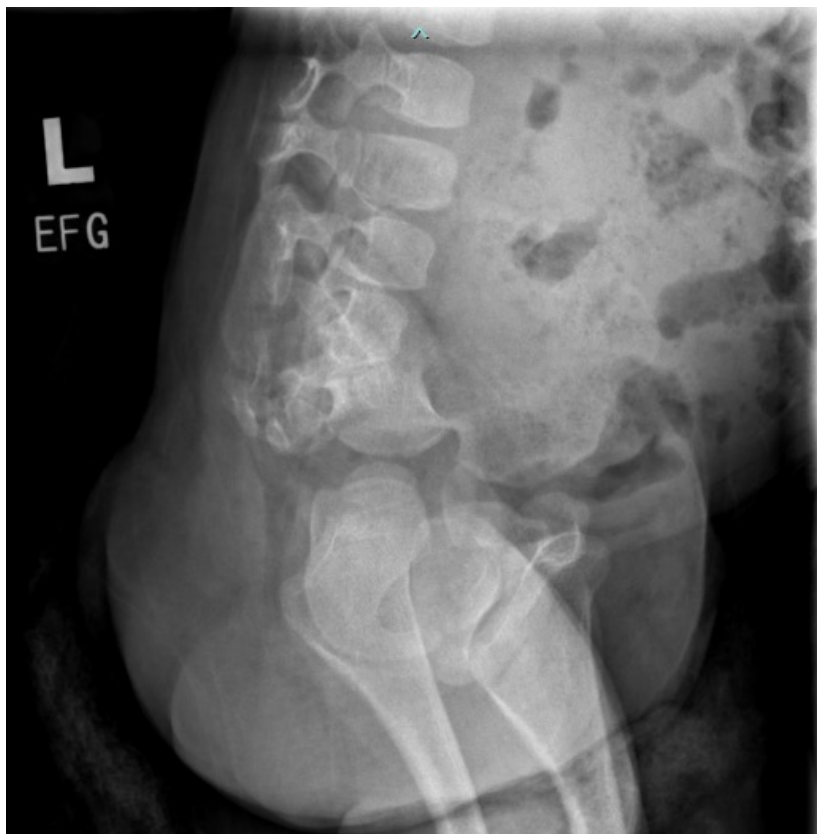
Children's Hospital Colorado

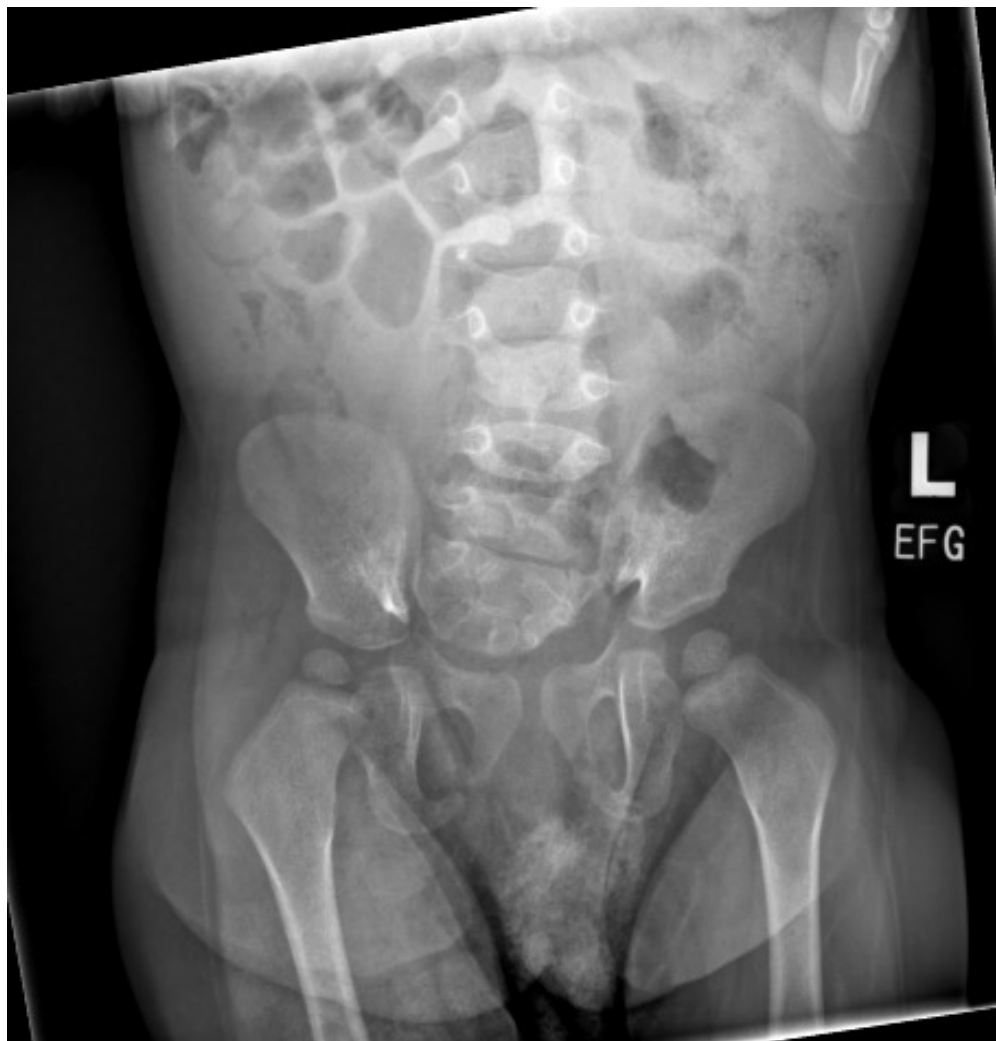INTERNATIONAL CENTER FOR  
**COLORECTAL AND  
UROGENITAL CARE**



- 15 mo, female patient with late diagnosis of recto-perineal fistula due to severe constipation
- Counseled by pediatrician – “anal stenosis”
- Referred by GI





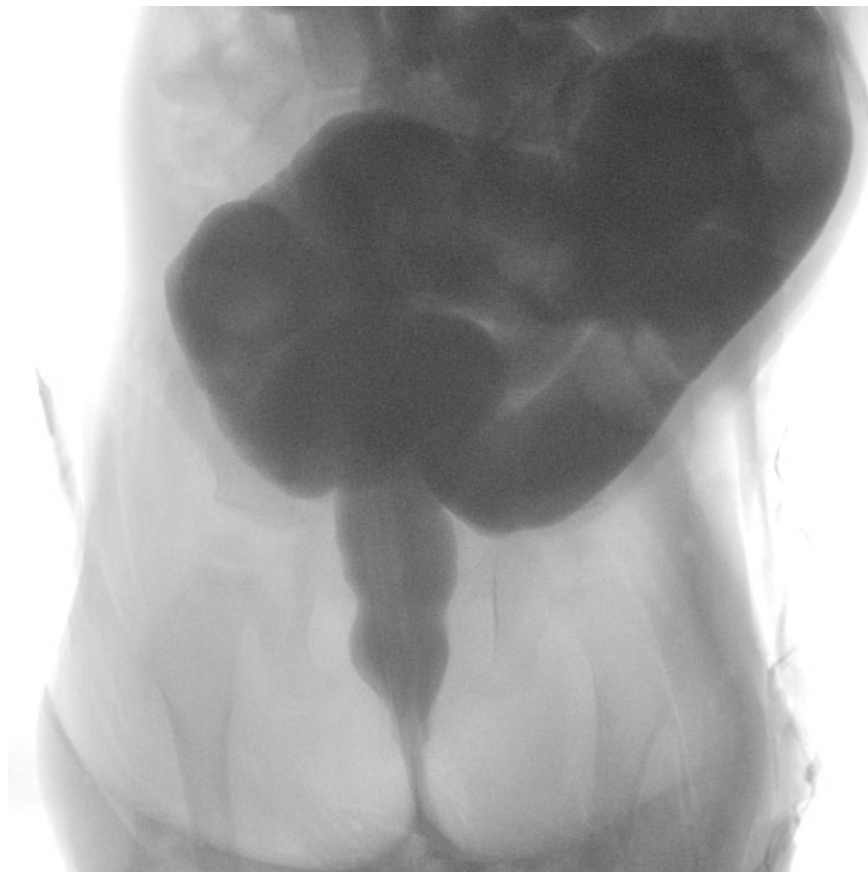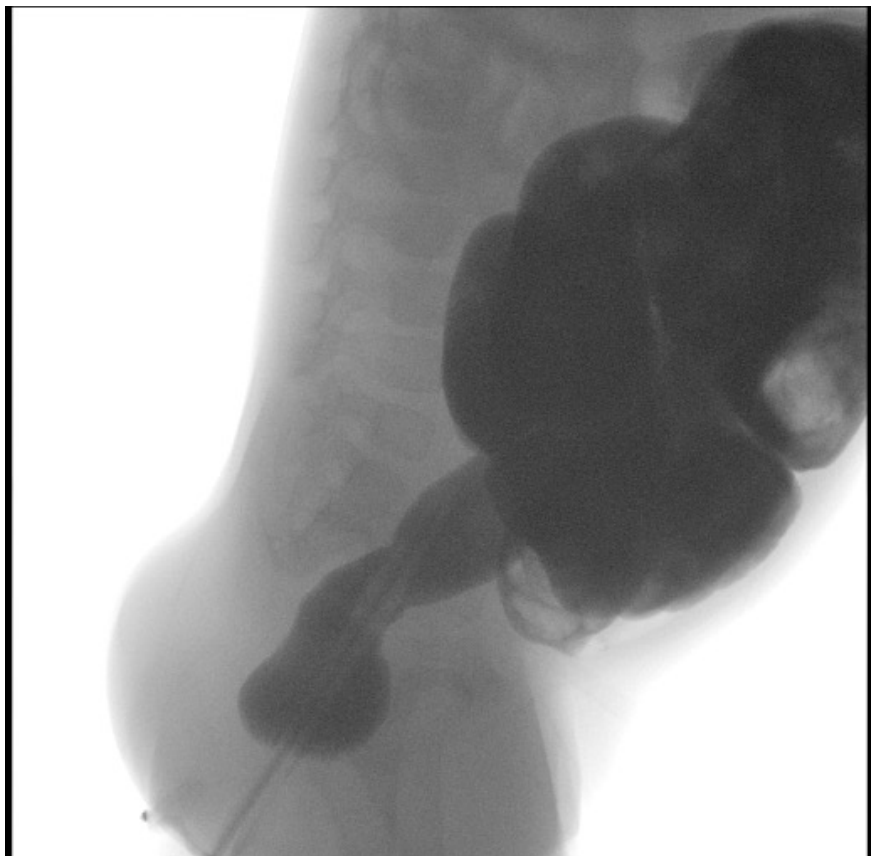


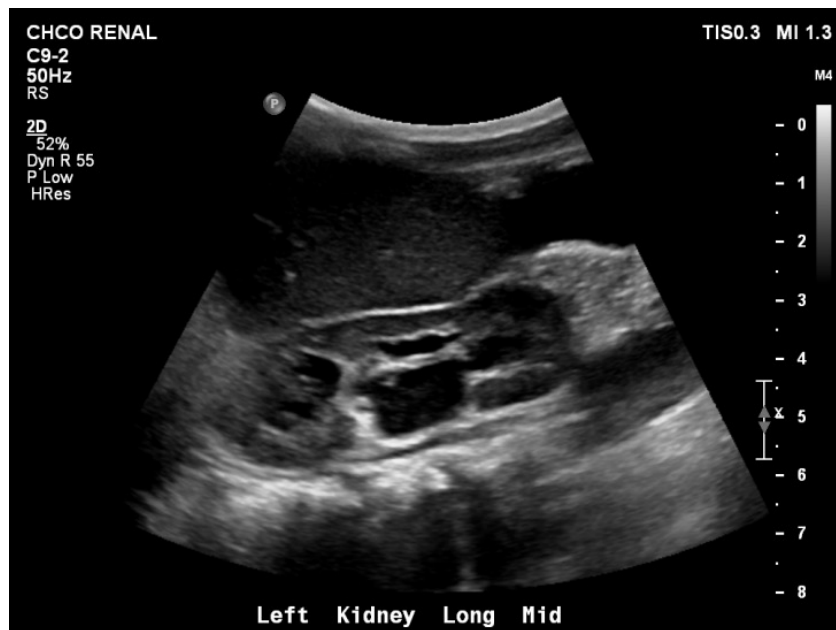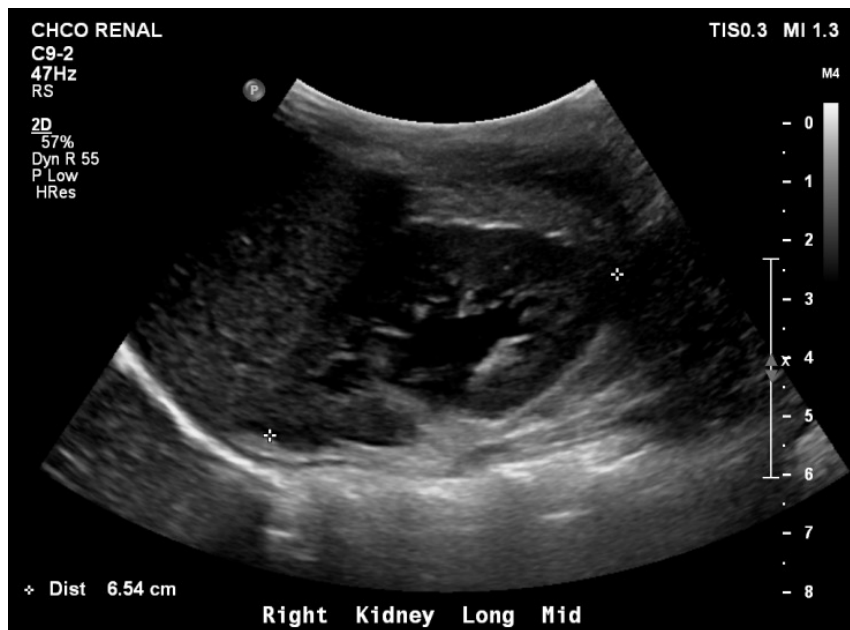# What studies would you like to order?



1. Contrast enema
2. Kidney ultrasound
3. Spinal and pelvis MRI
4. Options 2 and 3
5. All of the above



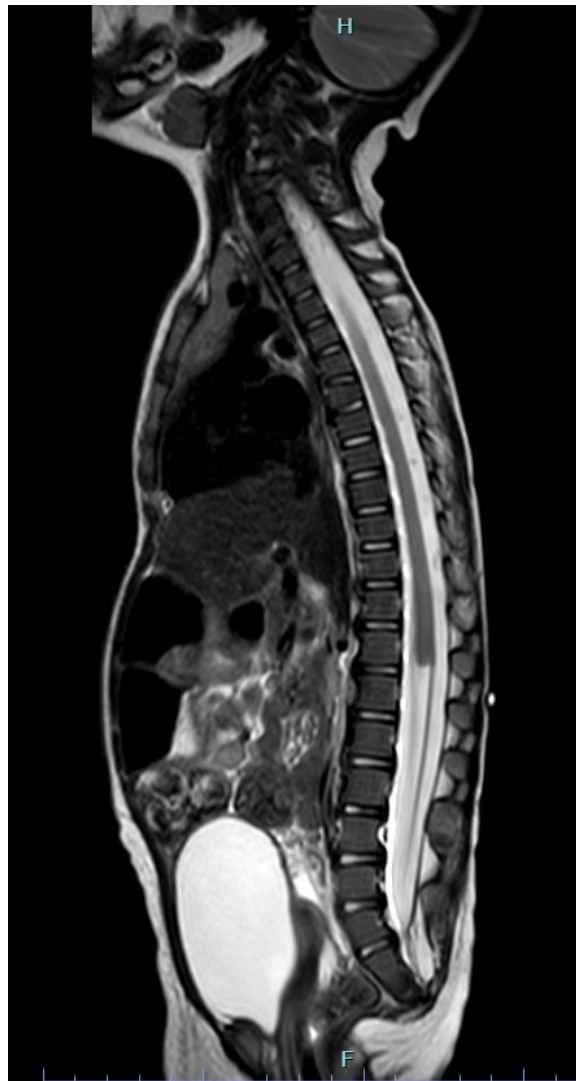






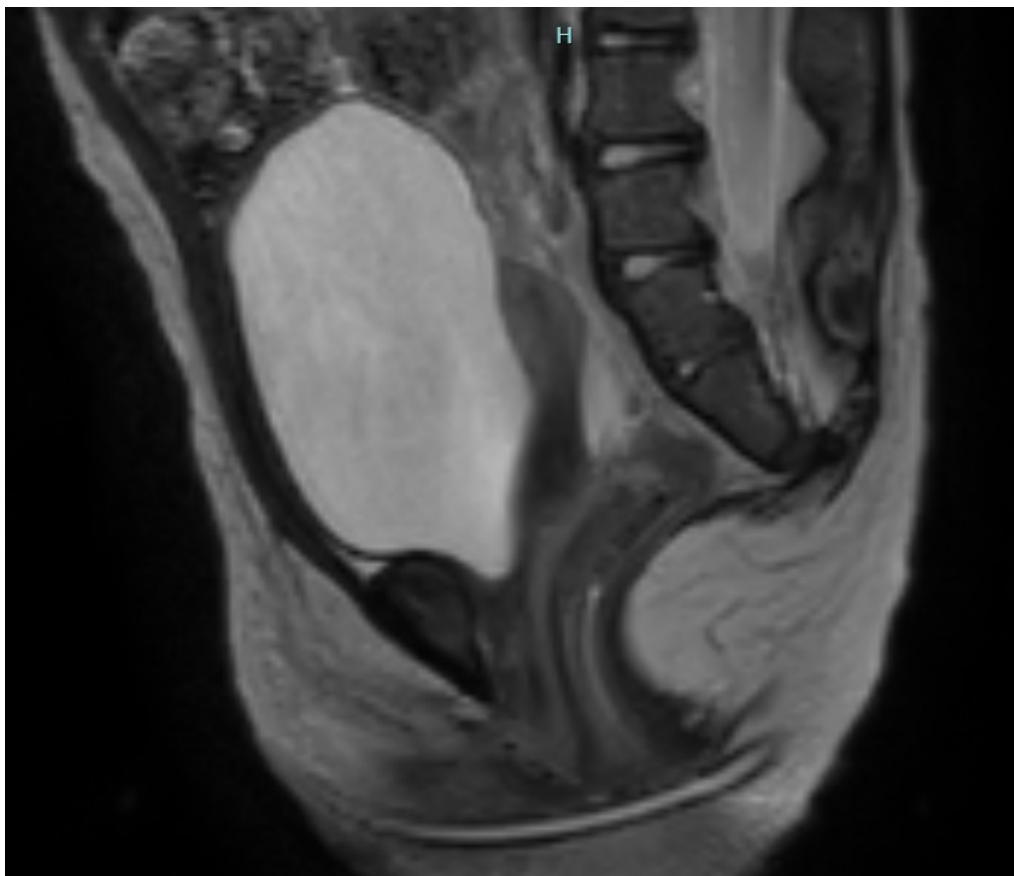


- Blunt Conus





- No presacral mass

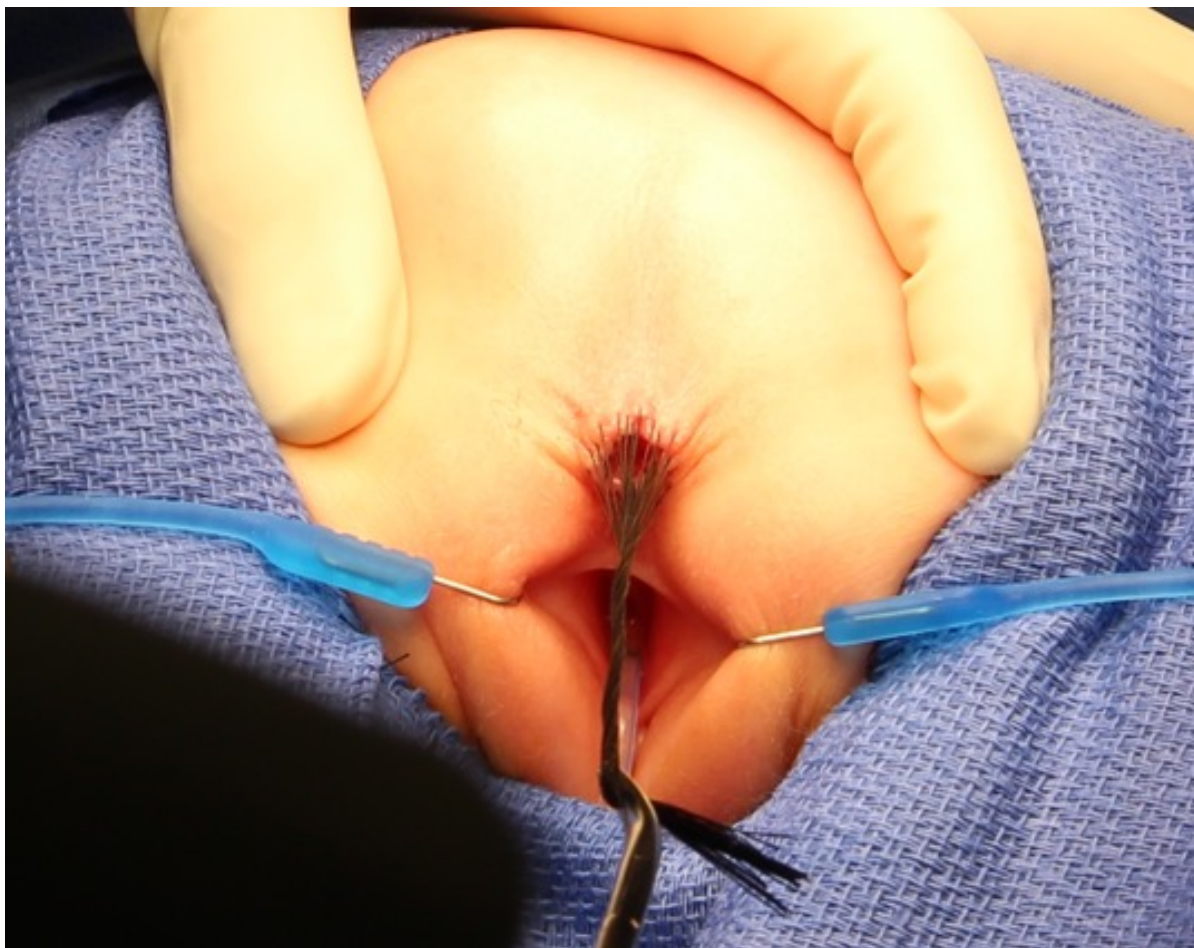

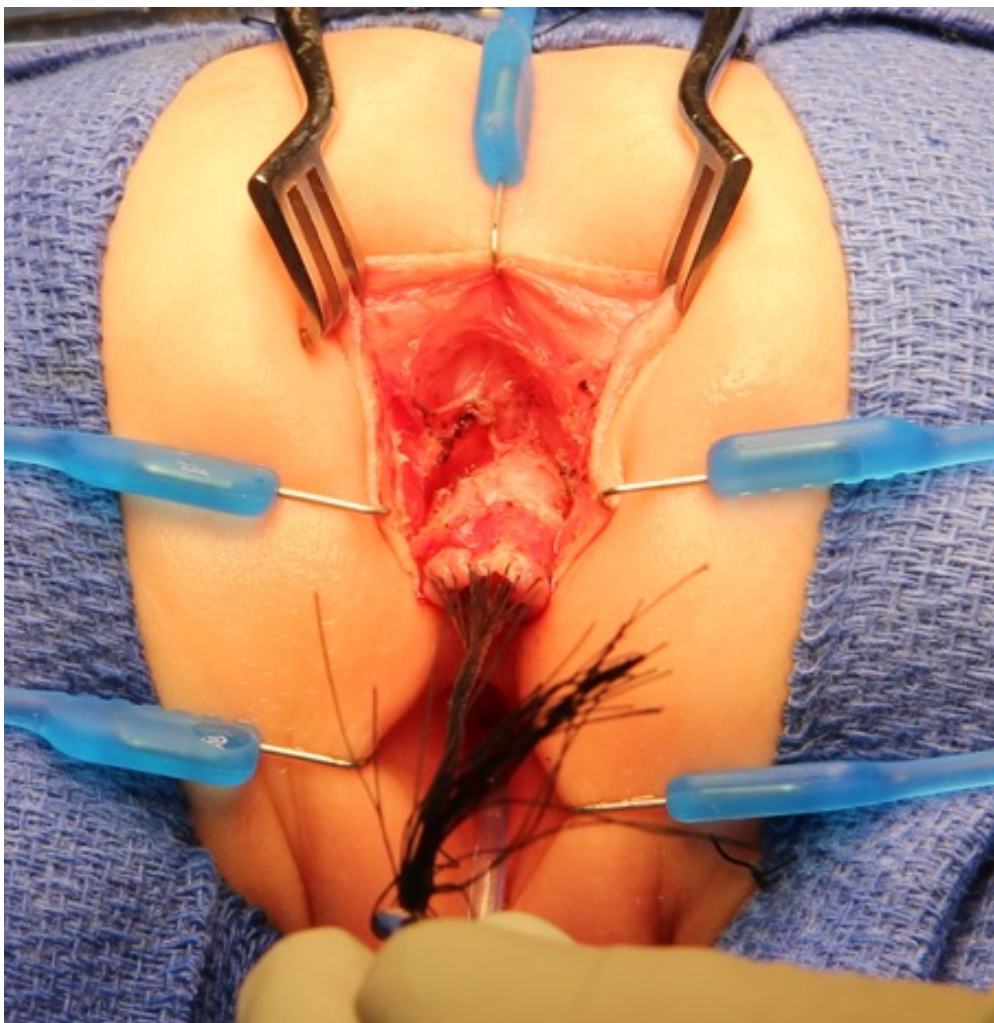


# MRI reported no visualization of Vagina/Uterus

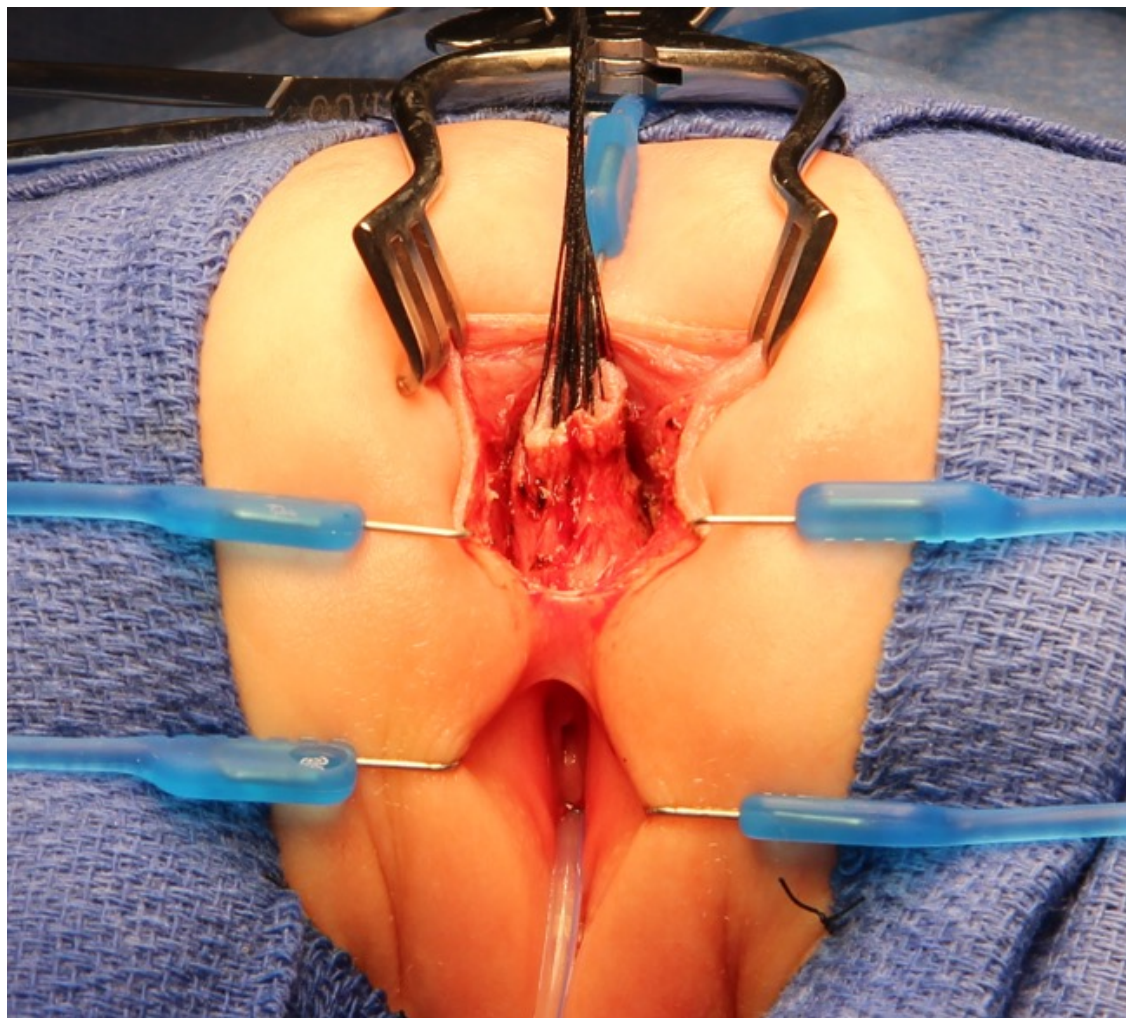
What do you propose?

1. PSARP and vaginal reconstruction at the same time
2. PSARP only and vaginal reconstruction at a later time
3. I don't know

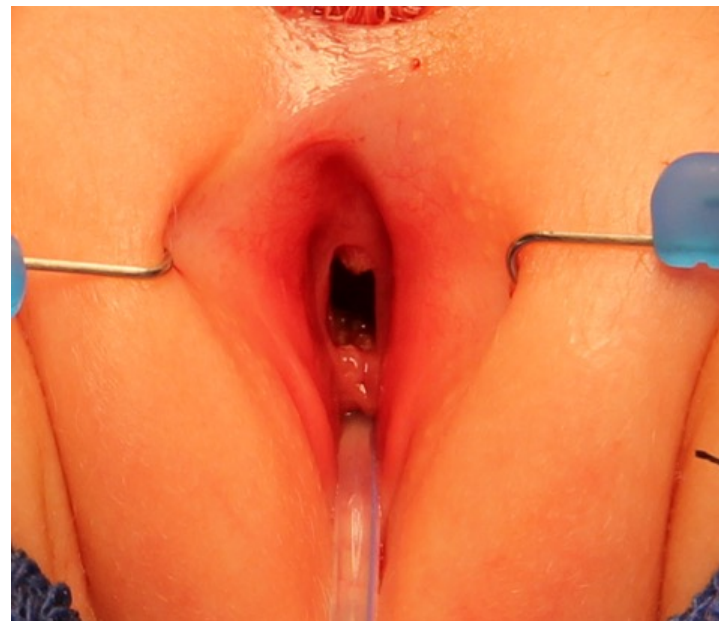
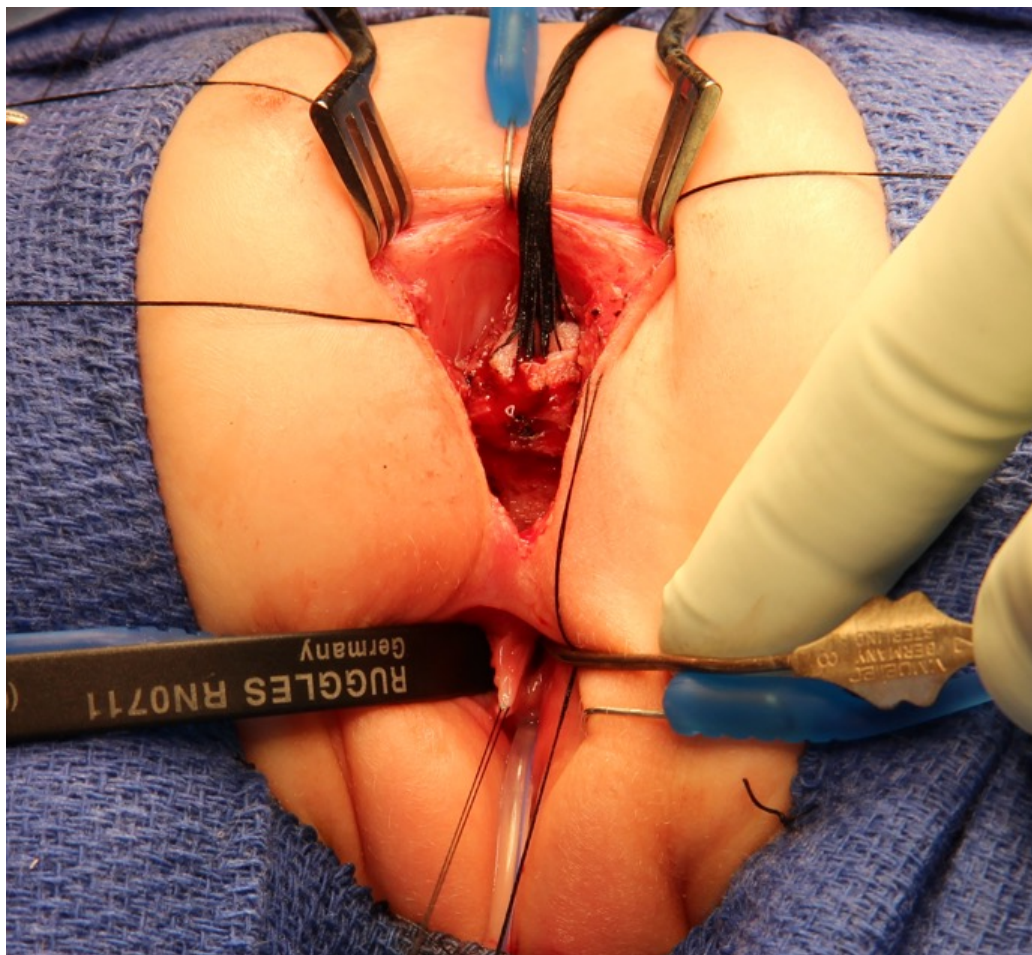


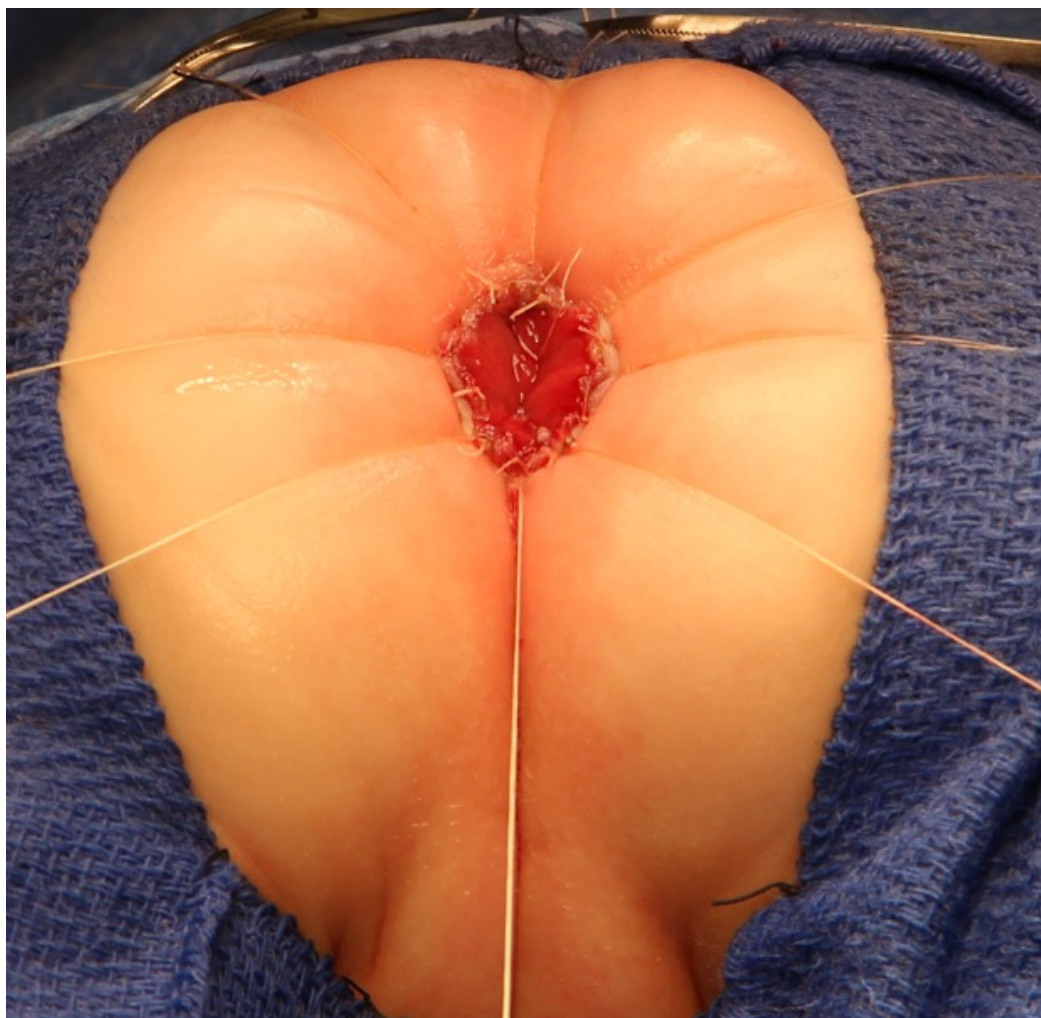


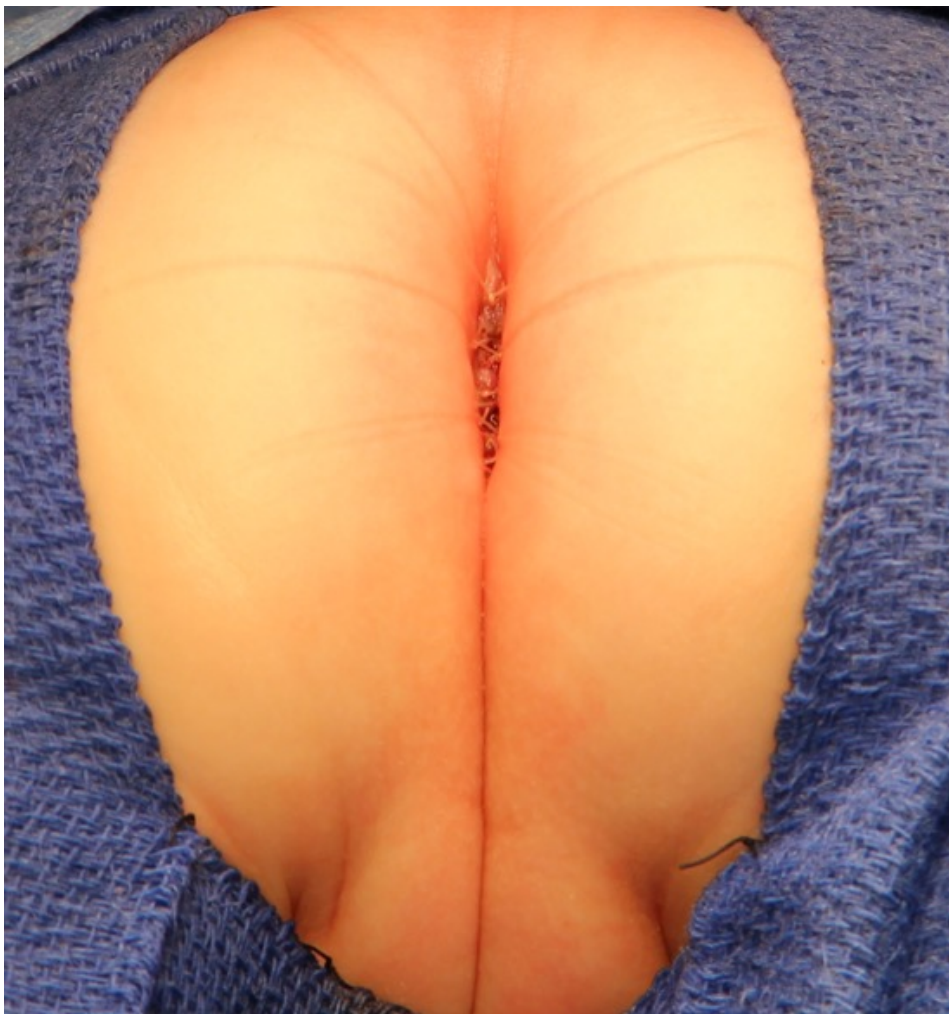
















# Take home messages:

- Not all perineal fistulas are made the same
- Not all perineal fistulas have good functional prognosis
- Vaginal reconstruction in anorectal malformation is different than in other conditions (DSD, Mayer Rokitansky)



*Happy Holidays*

AND HAVE A WONDERFUL NEW YEAR