

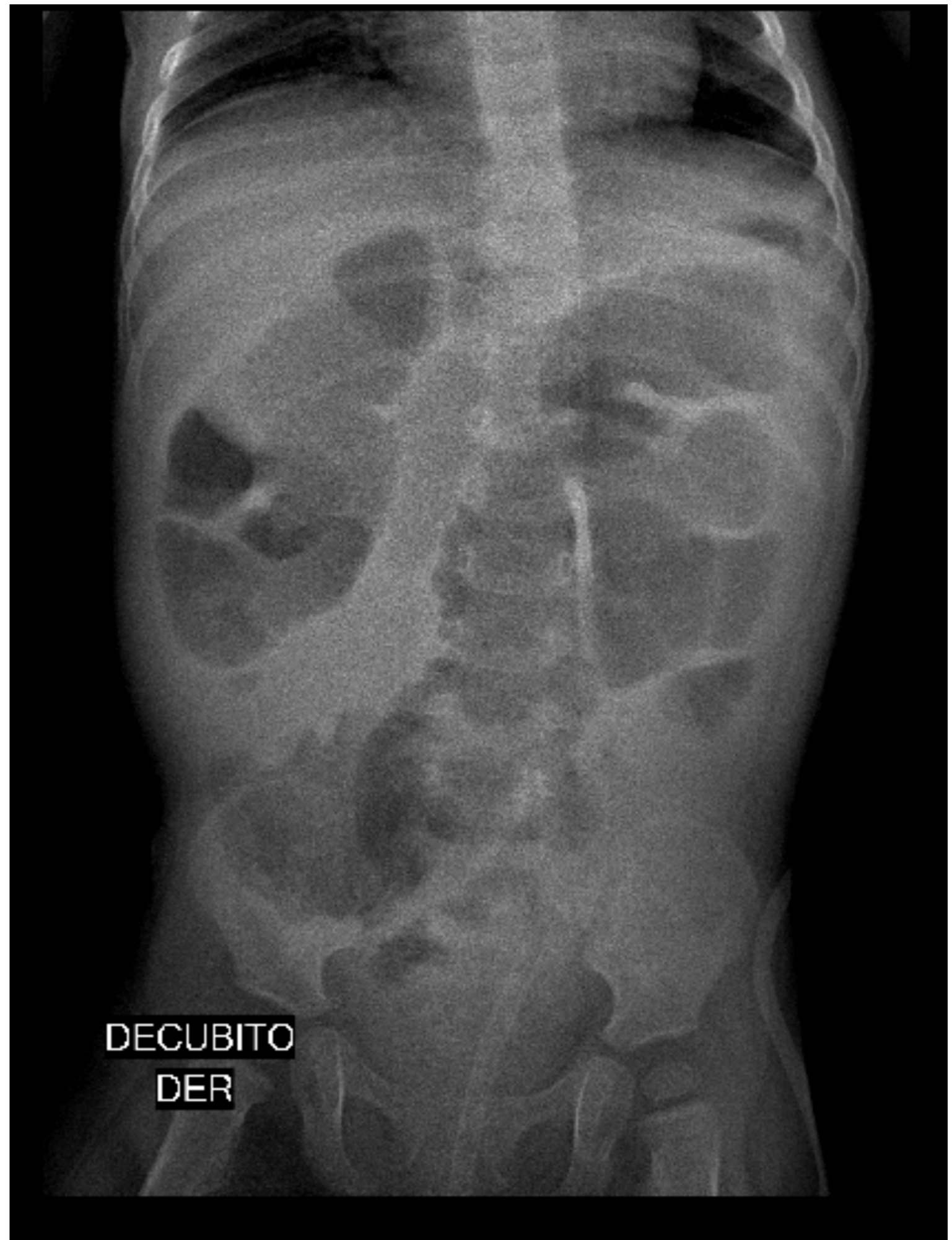- ▶ Female patient
- ▶ Referred to our hospital at 1 year of age with sepsis and septic shock

## **Past Medical History is...**

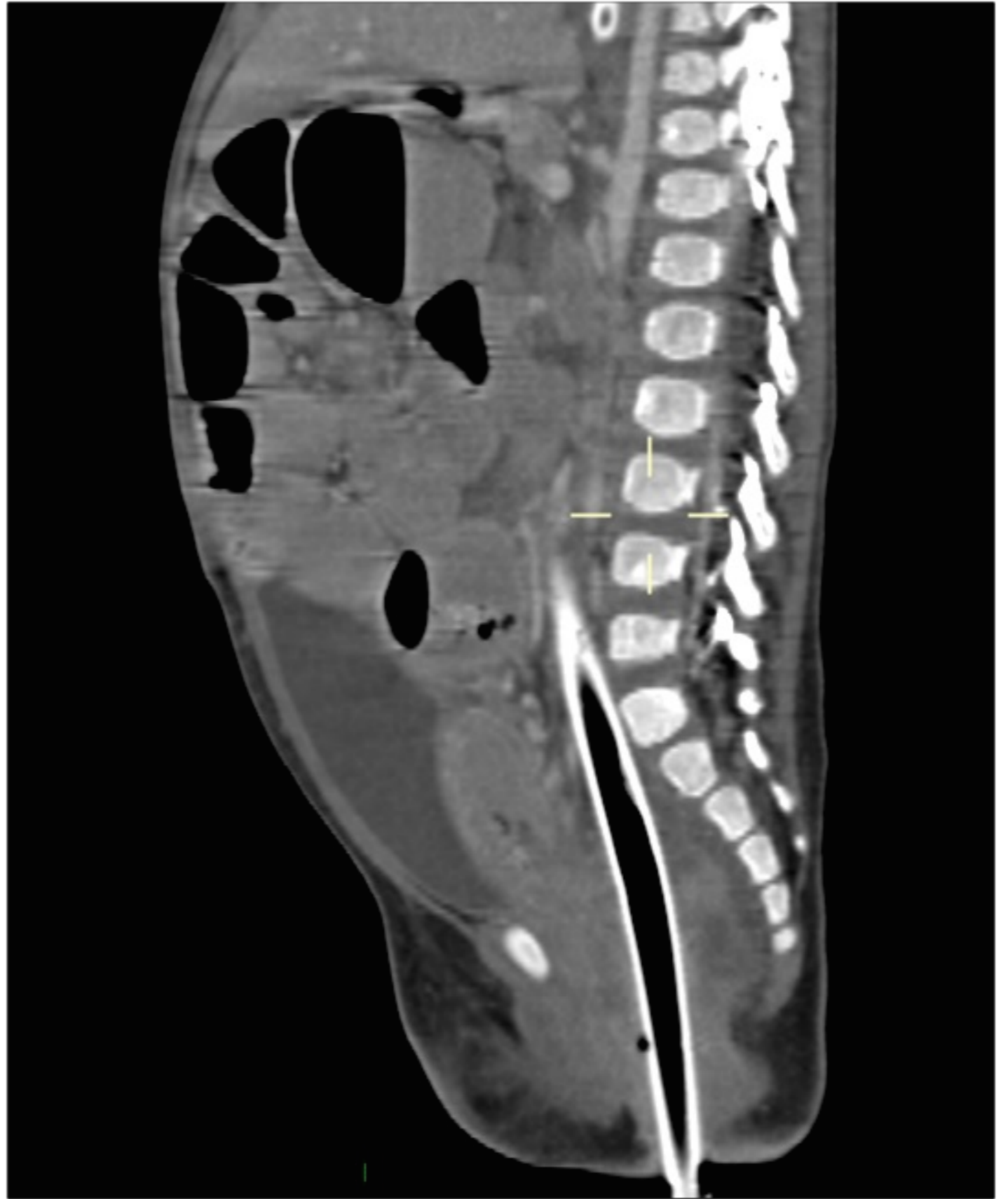- ▶ Colostomy was made at birth
- ▶ Soave procedure and colostomy closure (17 days before admission)

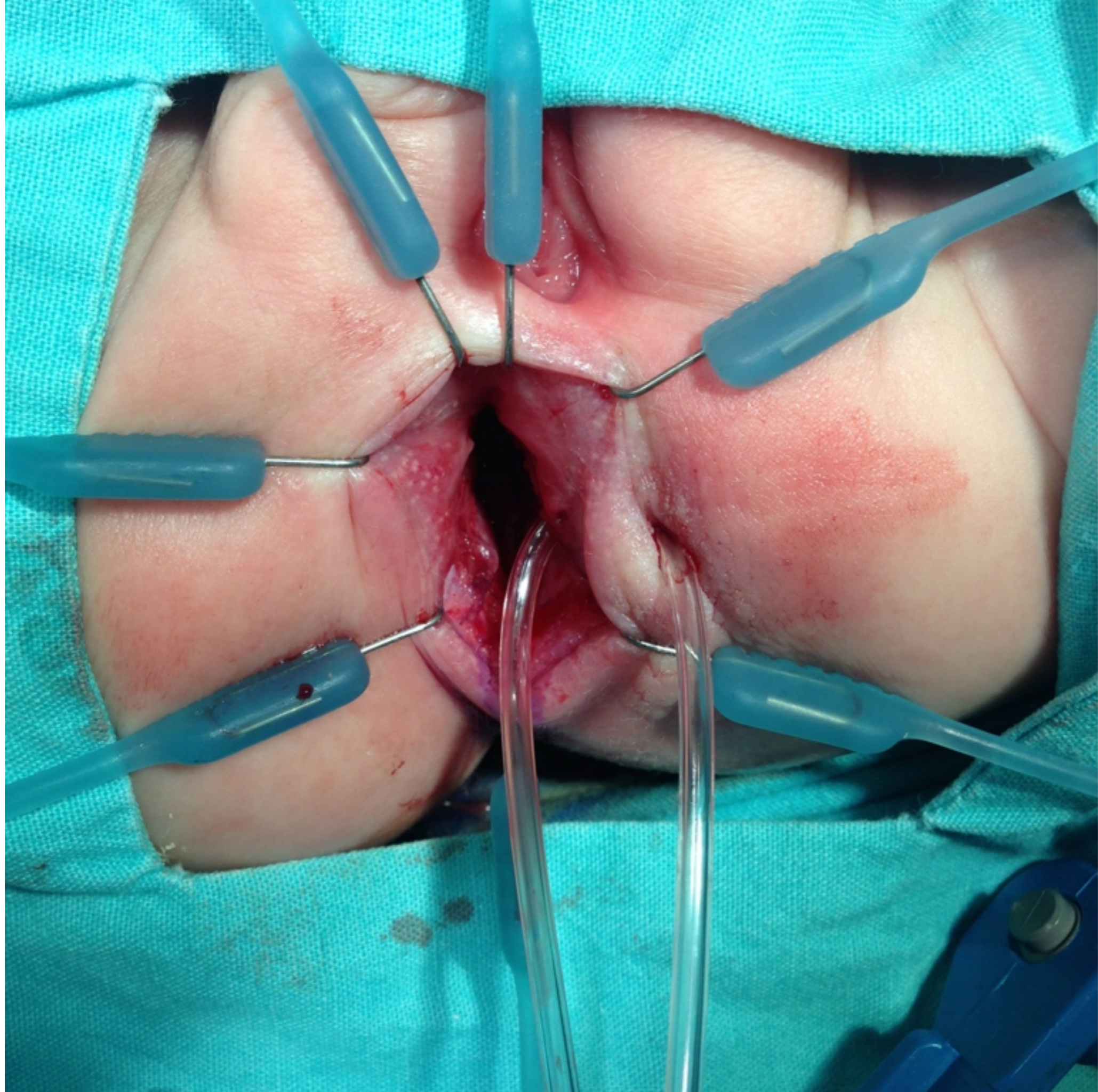
At the hospital admission  
she shows...

- ▶ Fever, abdominal distention, sepsis, and shock
- ▶ She has a rectal catheter (drainage of pus)
- ▶ x ray



We advance the rectal catheter and obtained 700 ml of pus

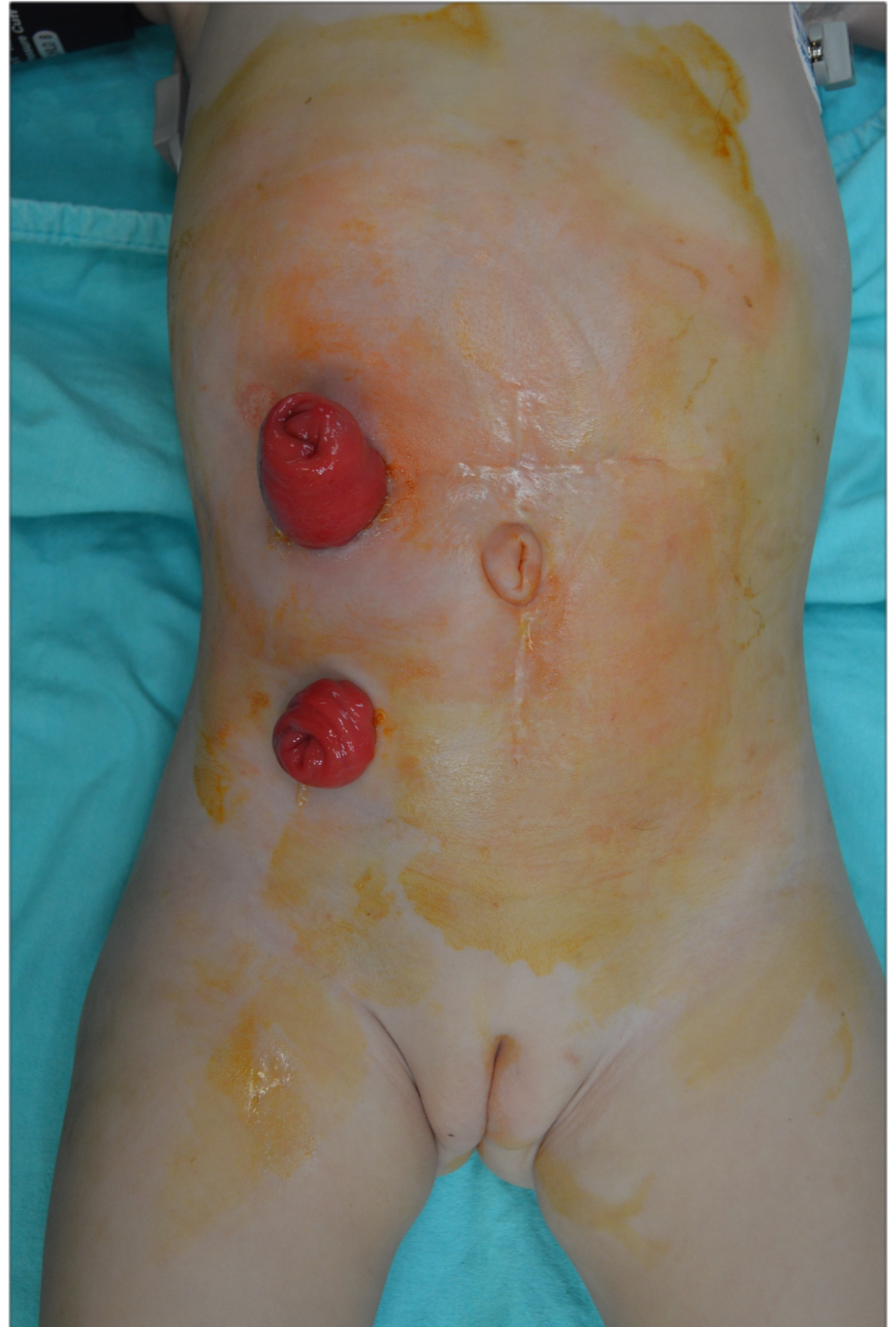



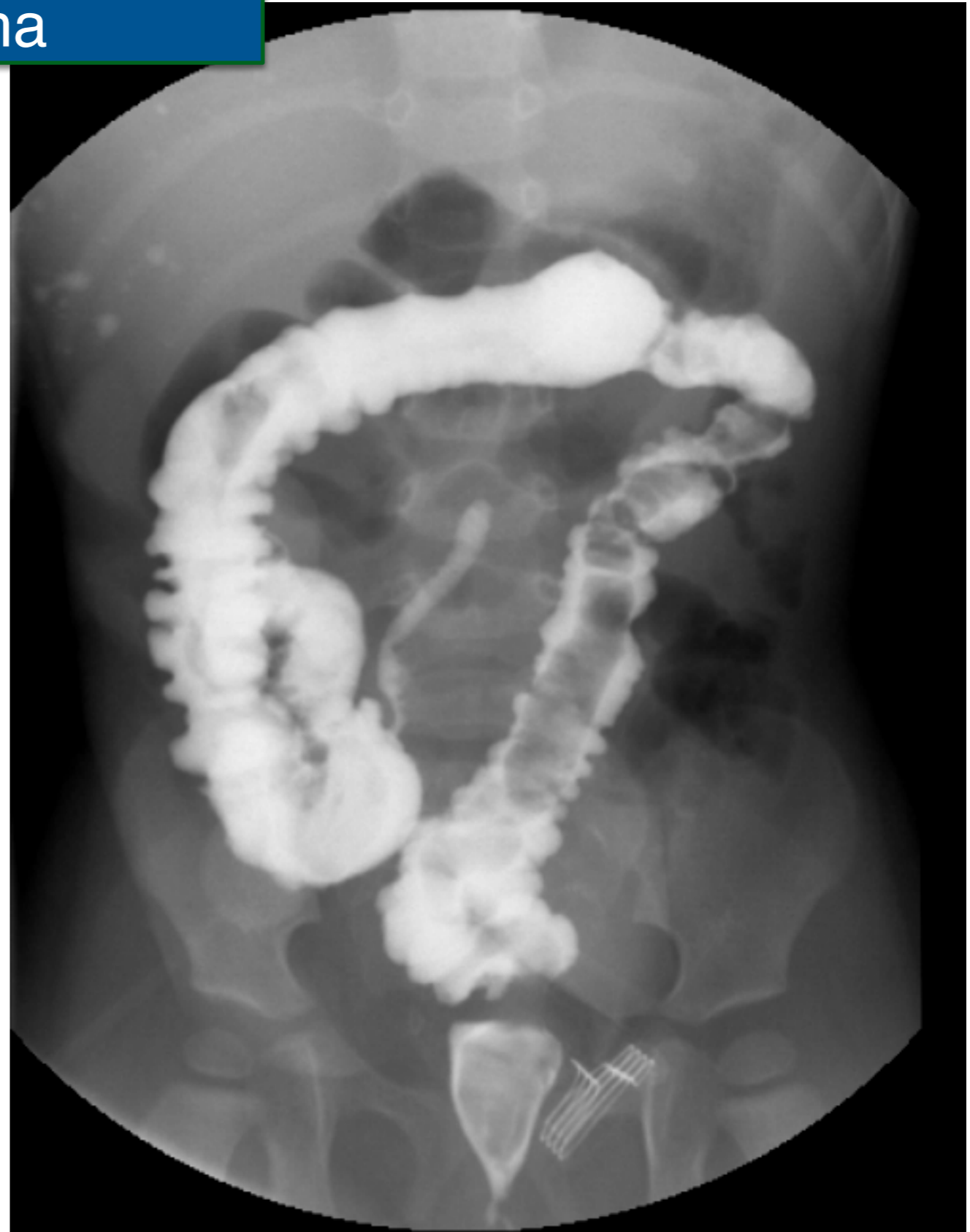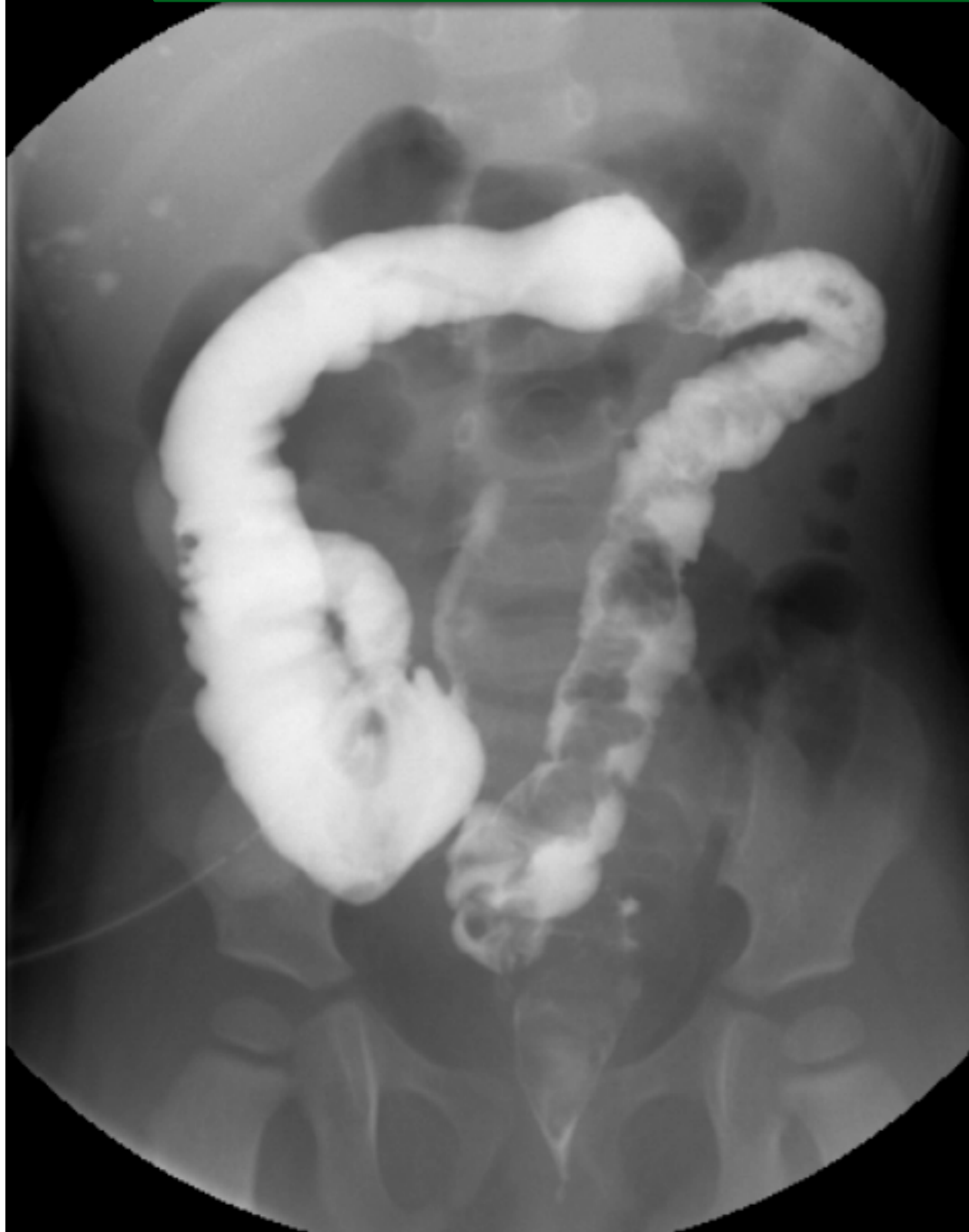Laparotomy with  
ileostomy

+

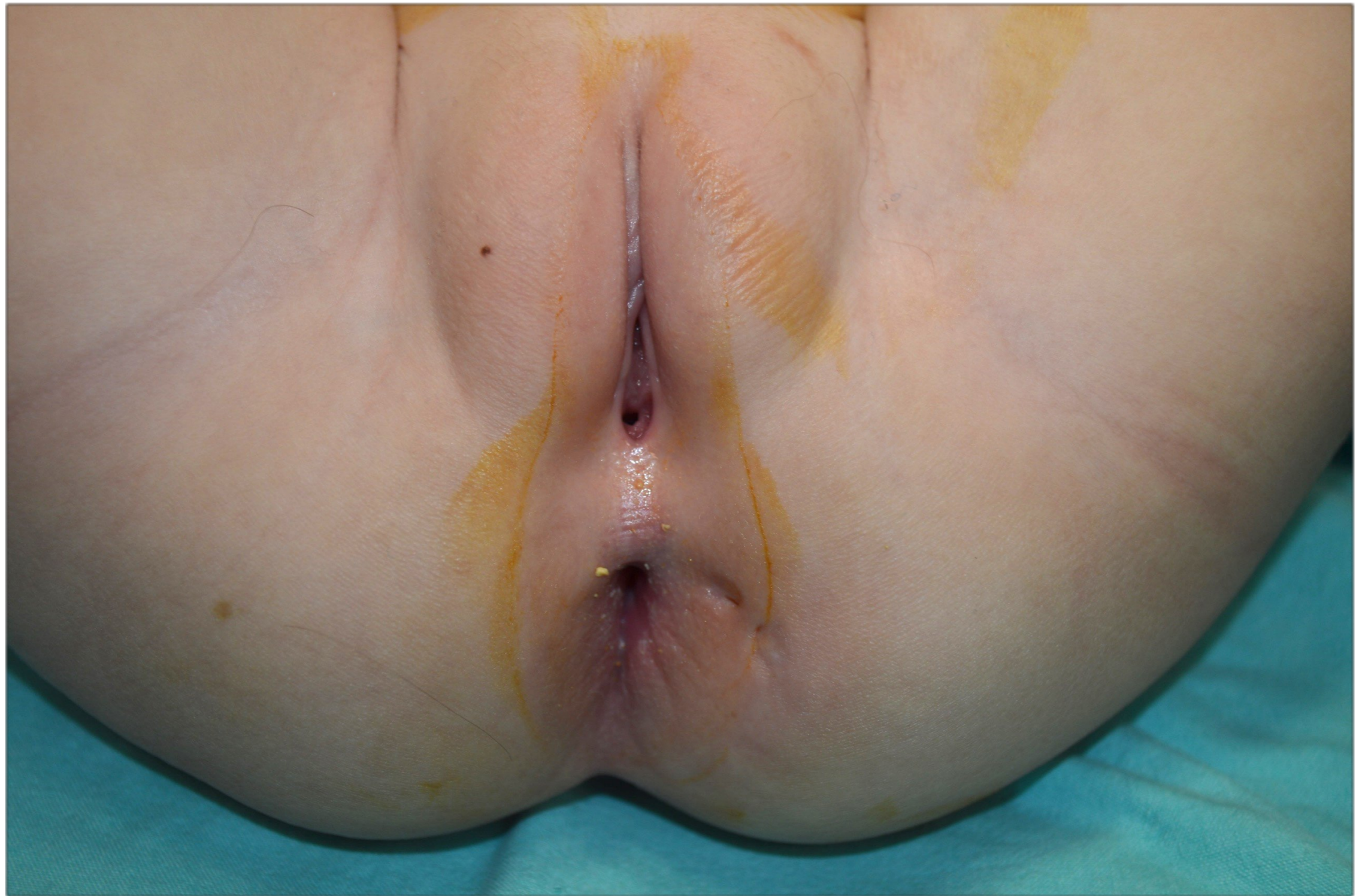biopsy of colon  
(peritoneal reflection:  
normoganglionic)

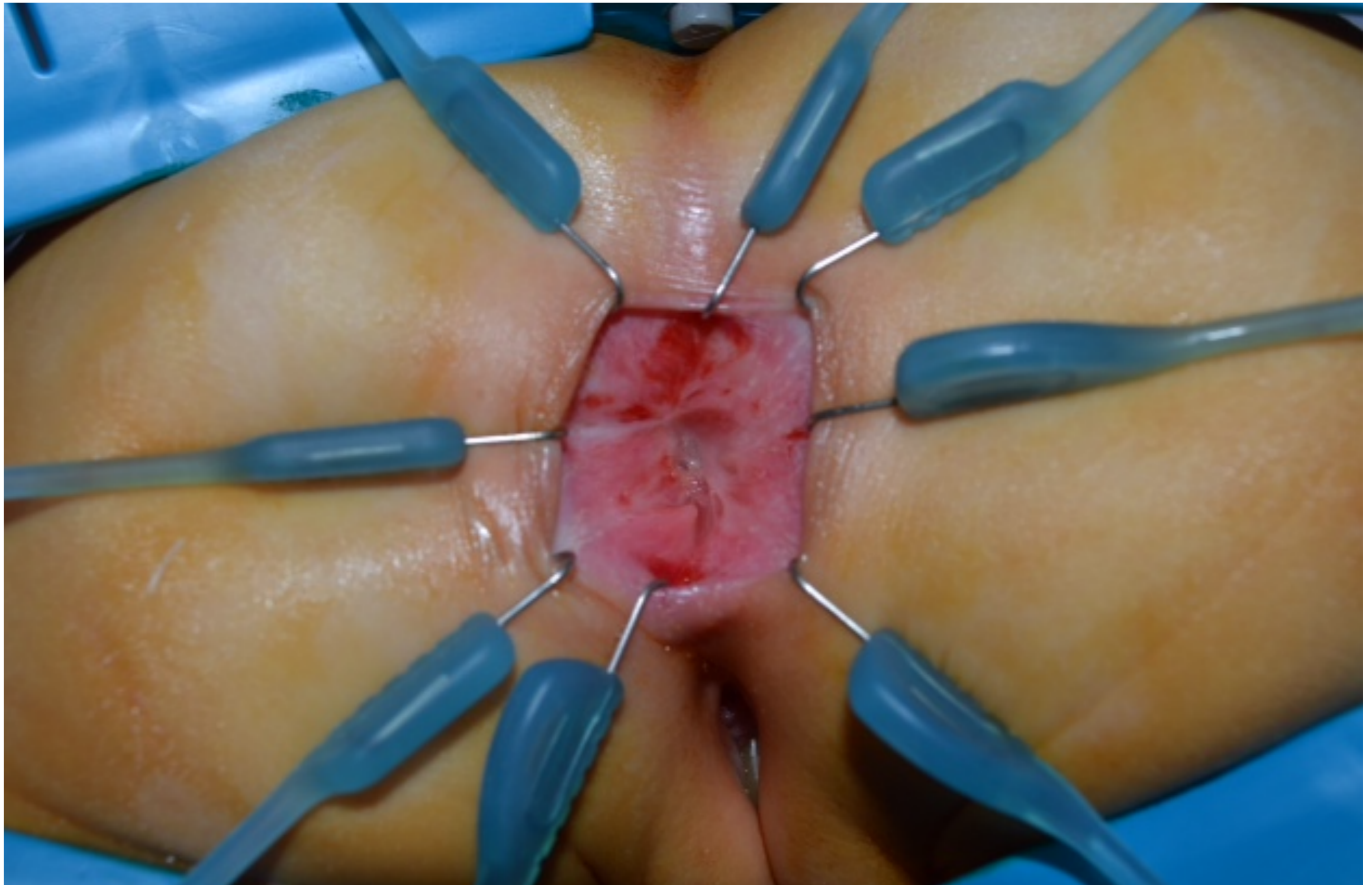


9 months after...  
Injection from the distal stoma

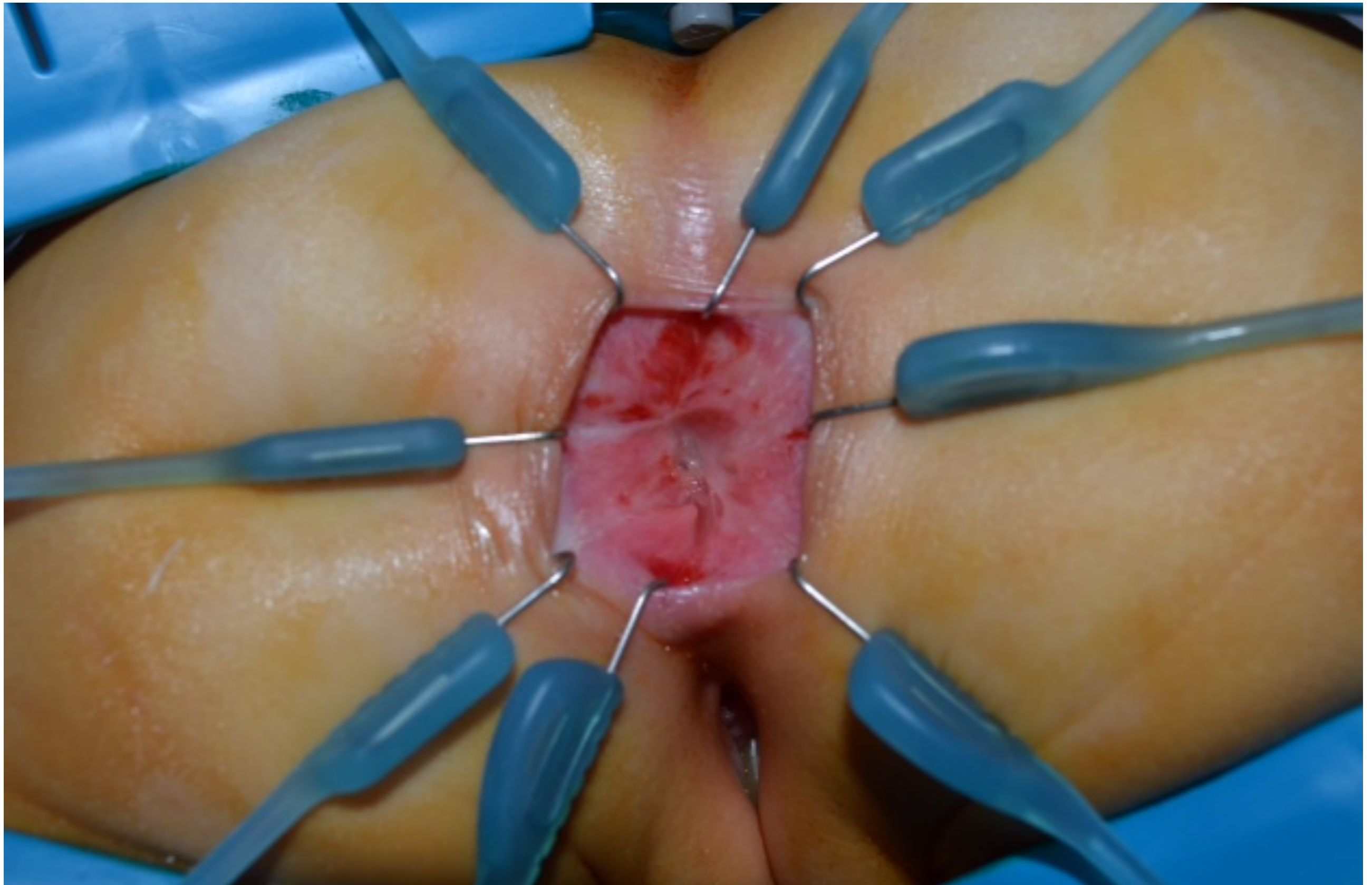


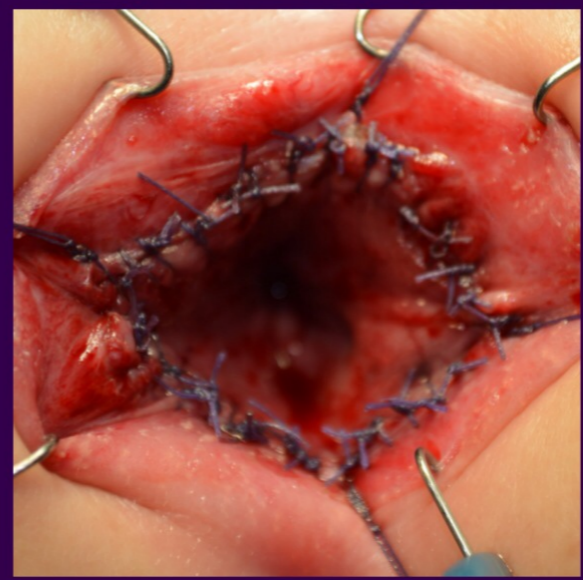
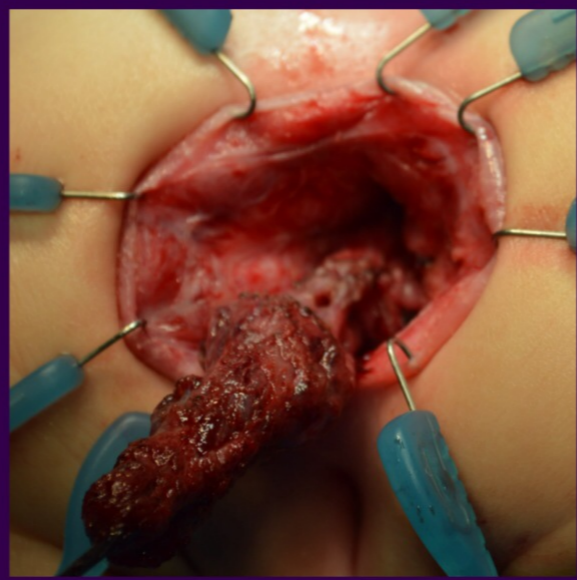
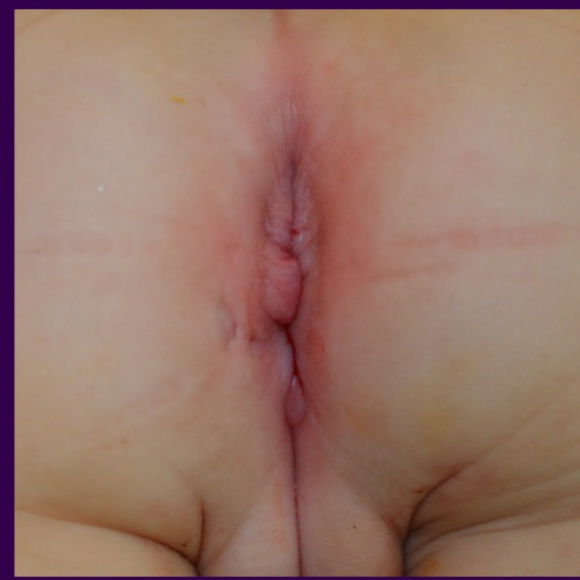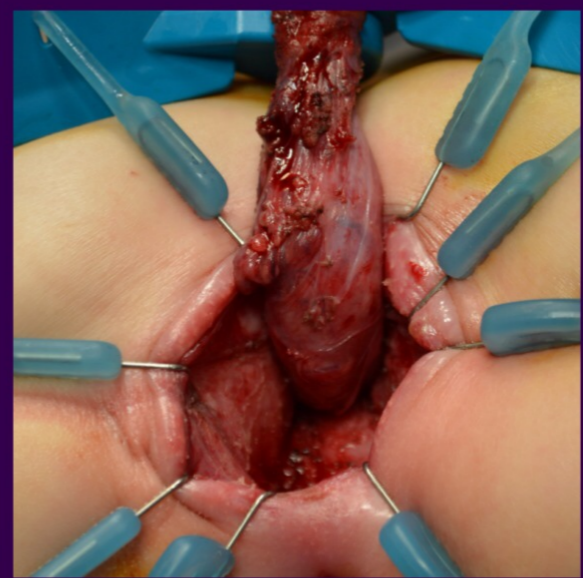
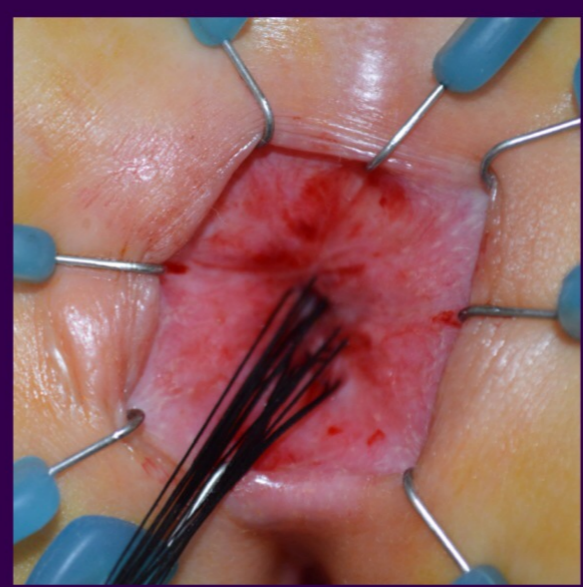
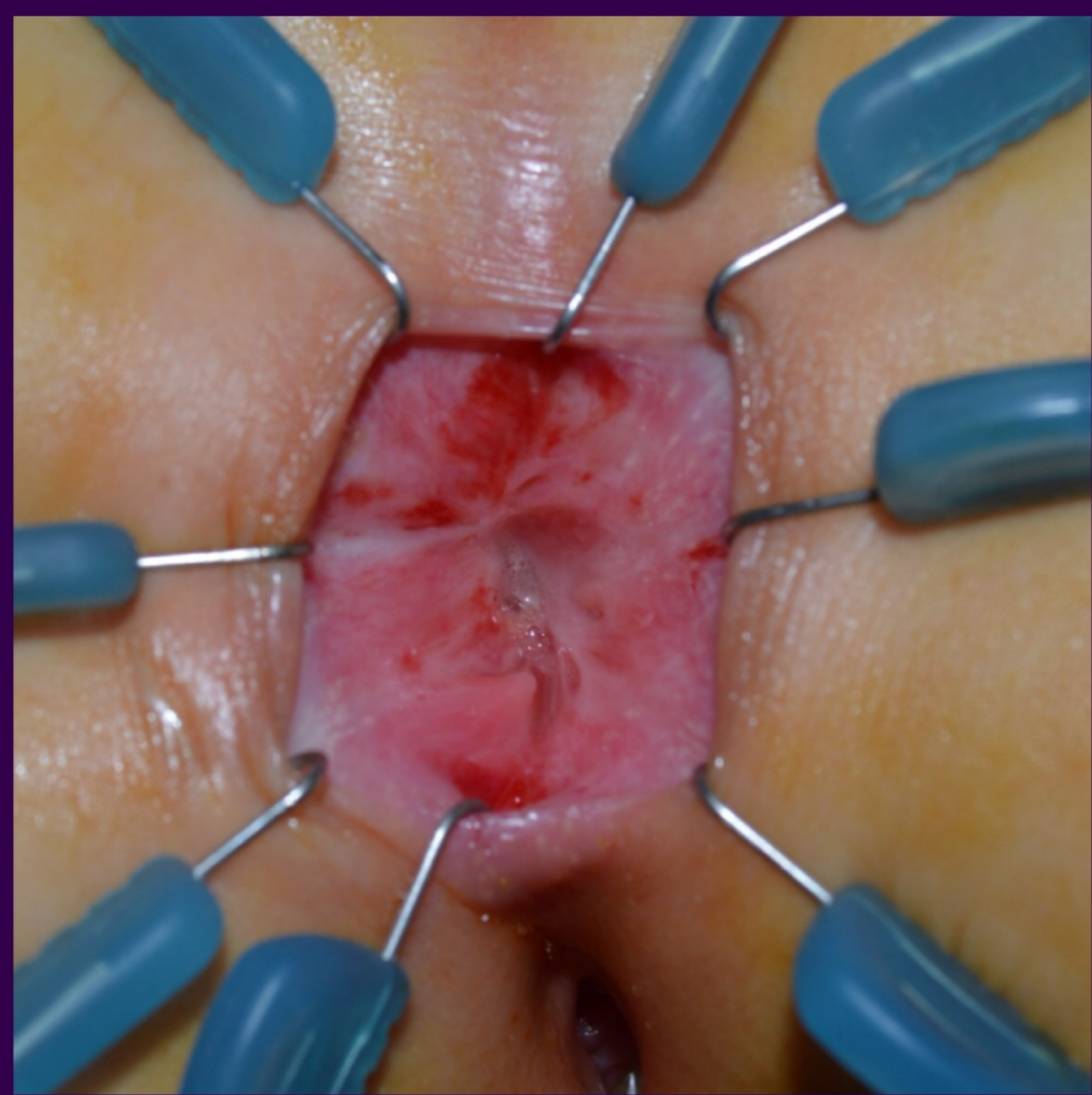
9 months after...

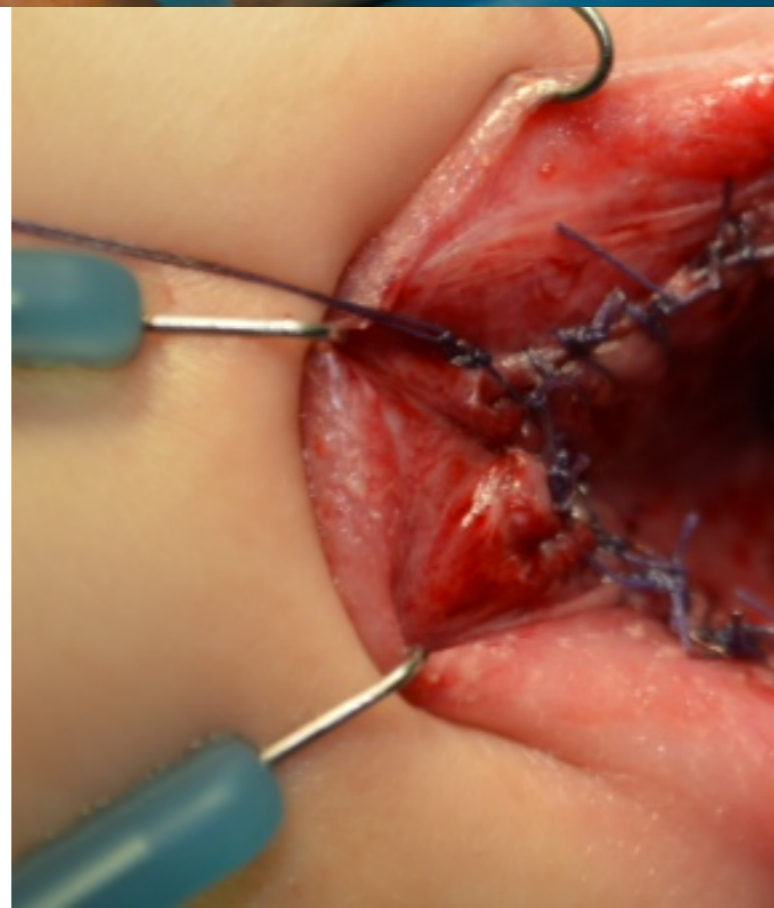
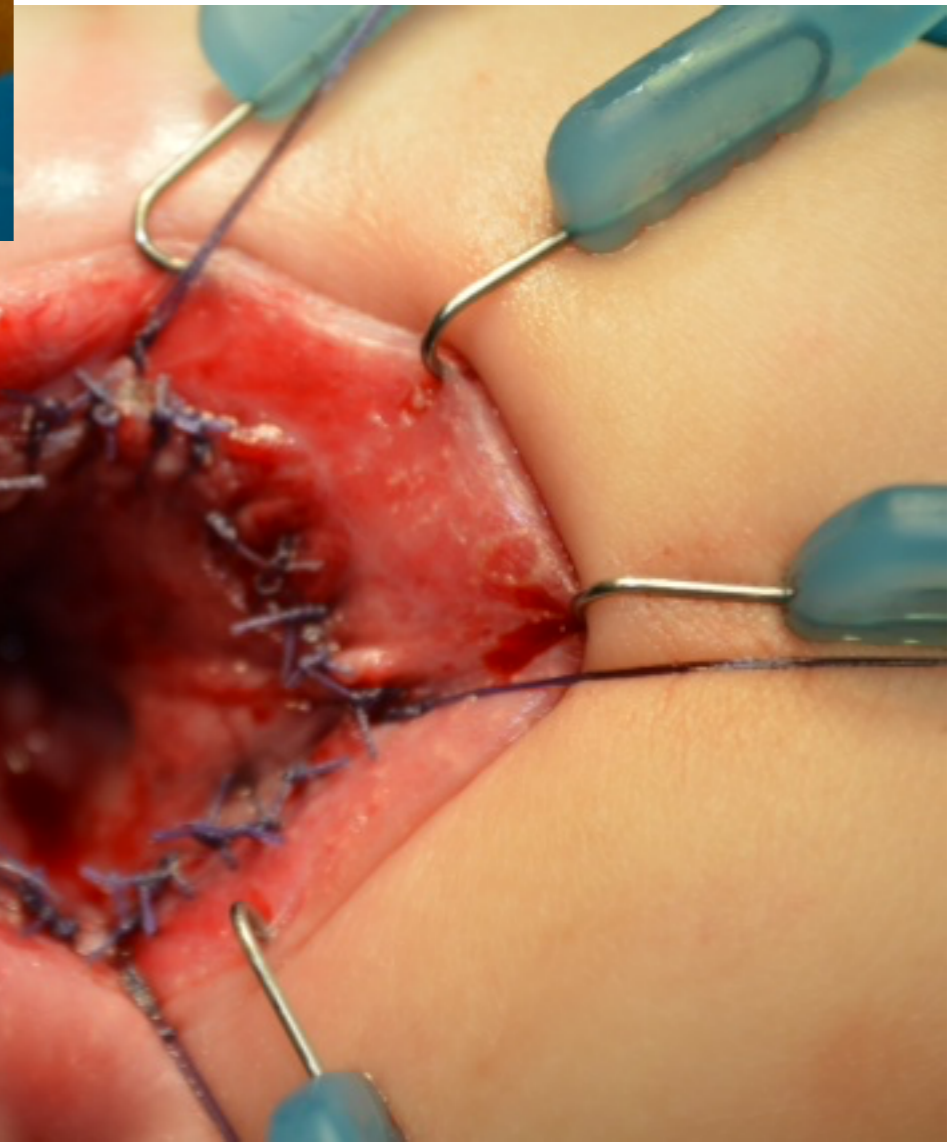
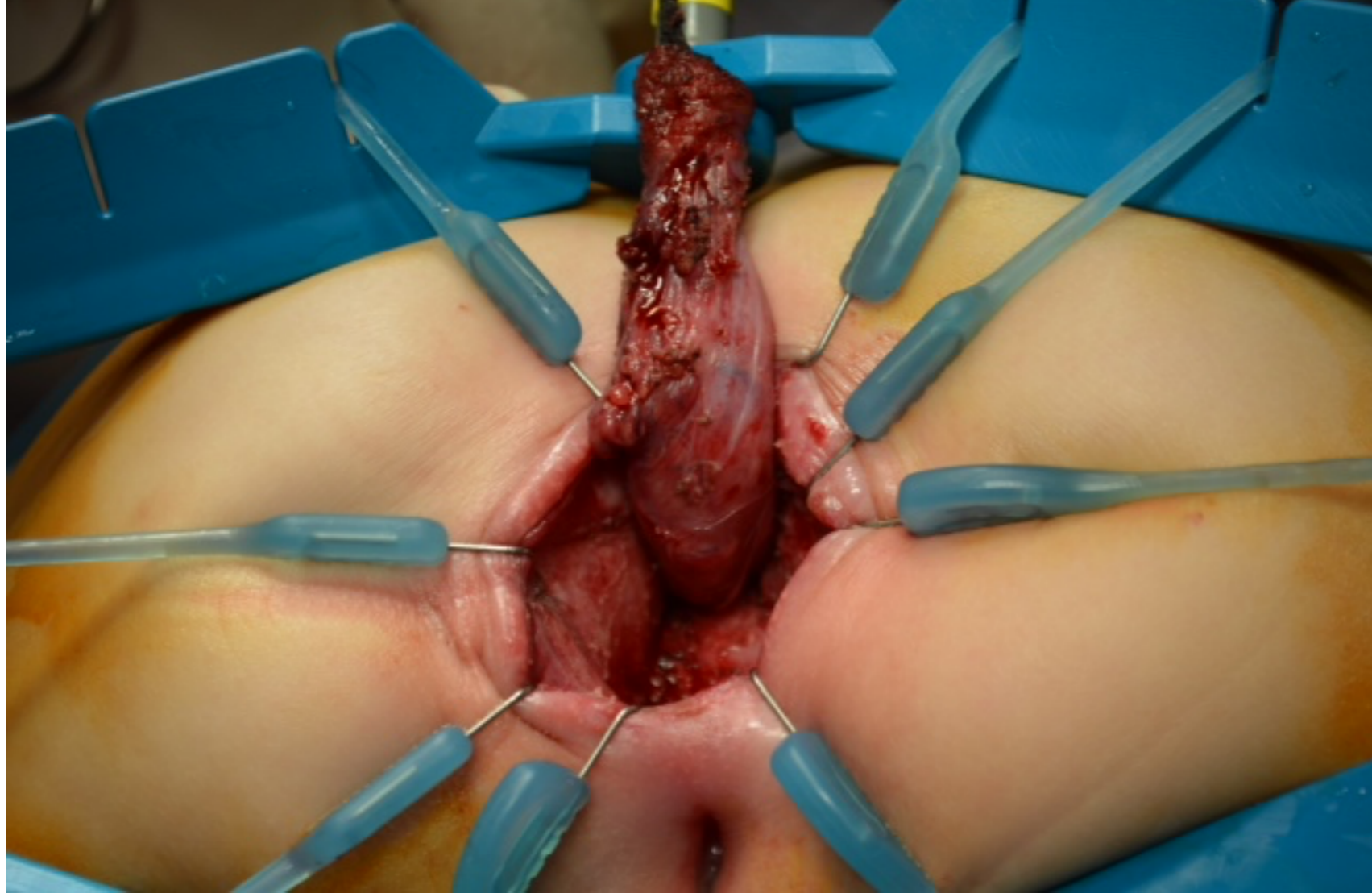












Rectal dilation were initiated  
14 days after the procedure



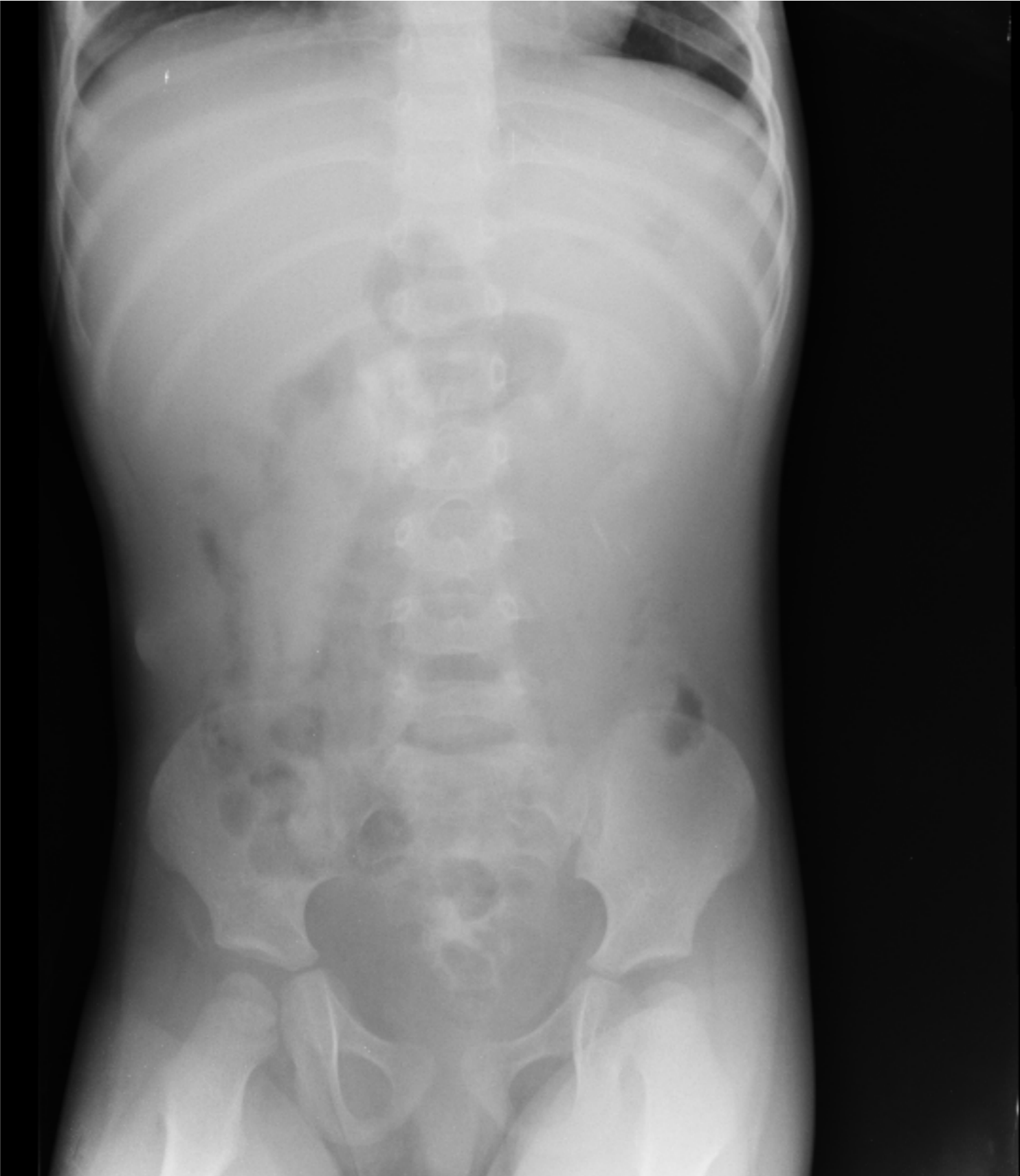Closure of ileostomy  
(3 months after)

# Treatment

## “Fecally incontinent”

Fecally incontinent

- Rectal Enema 250ml of saline solution
- Clean radiograph but with not clean in the underwear (“accidents”)



- Added Loperamide – 2mg every 12 hours

Currently she is 4 years old

Fecally incontinent

- Rectal enema with 250 ml (Saline solution)
- loperamide 2mgs/12 h
- CLEAN in the underwear