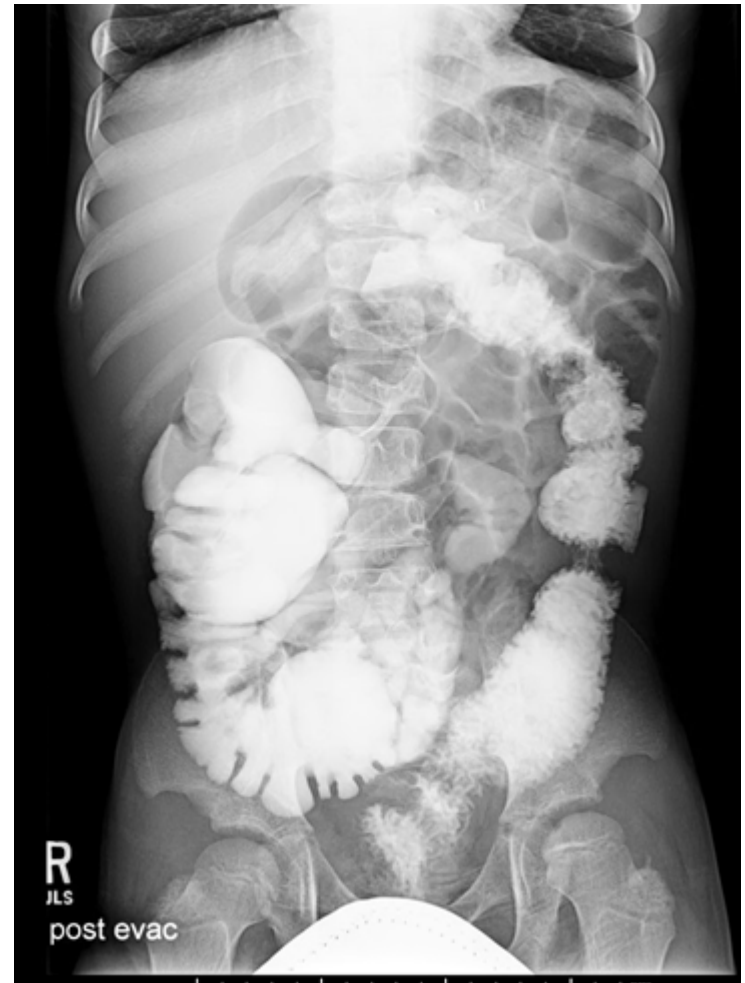
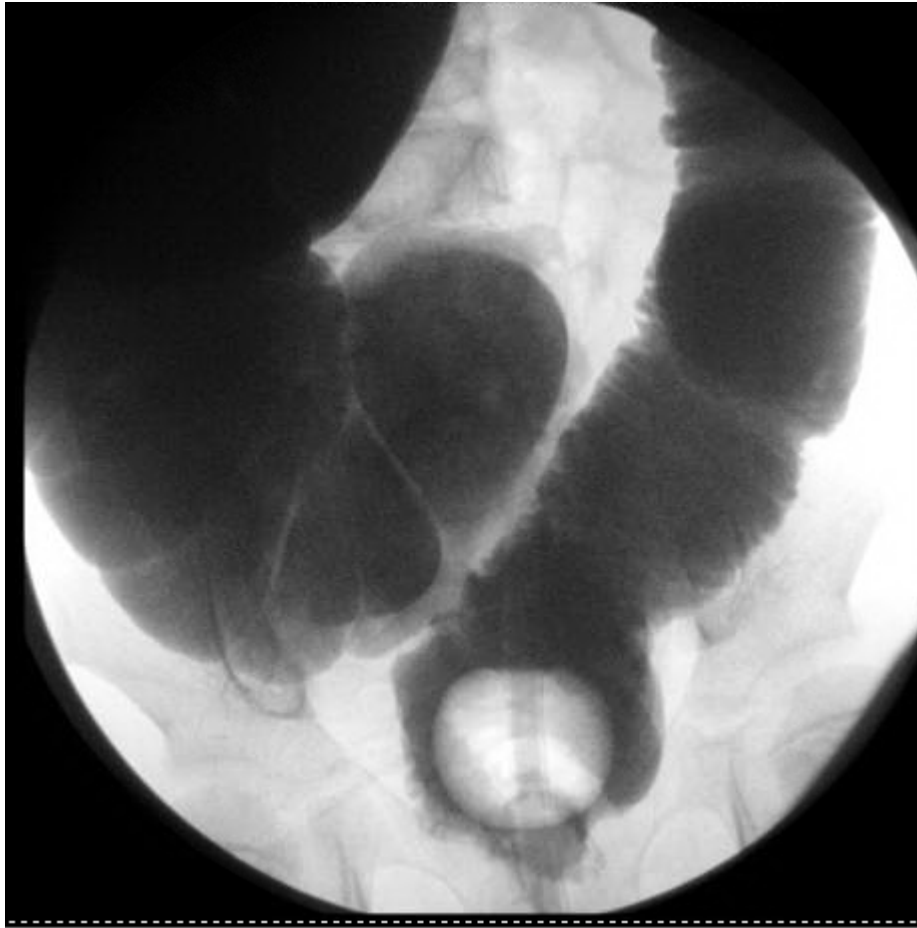
Review of Patient



- 9 years old male presenting with fecal incontinence
- Born with Hirschsprung's disease s/p repair, sacral agenesis, corpus callosum agenesis, and other anomalies
- Sacral ratio: zero

Contrast enema



BMW Friday Clinic

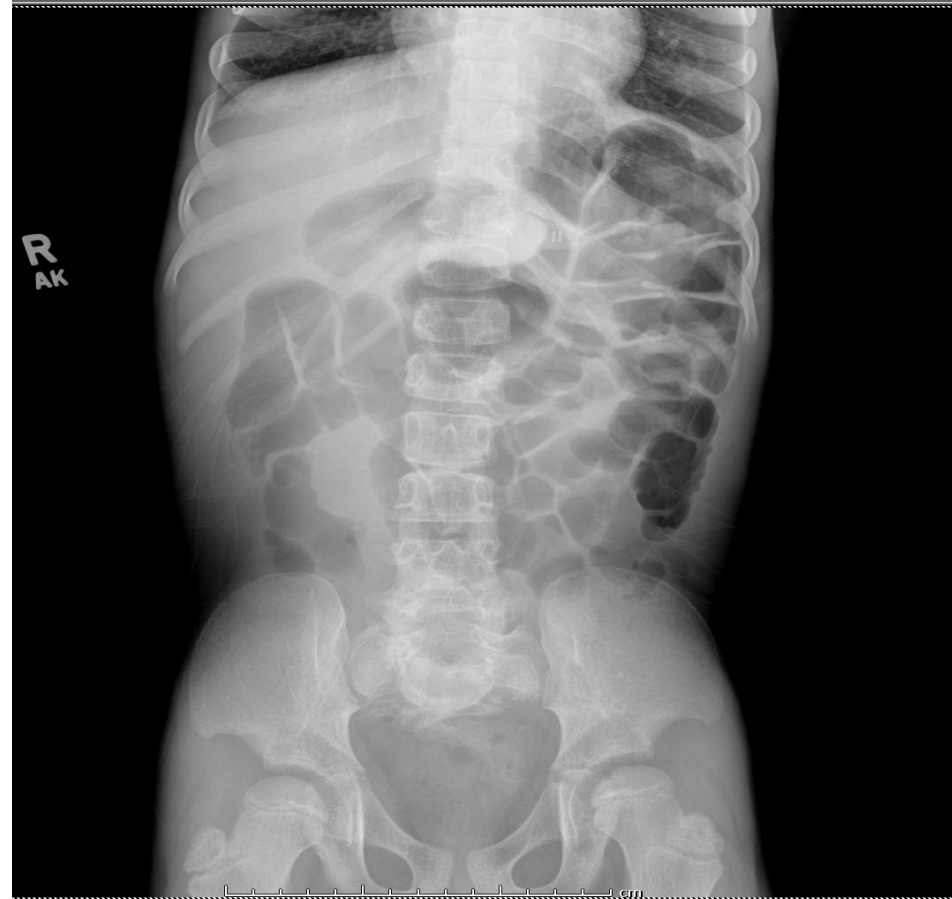

- Enema- 400 mL normal saline with 25 mL glycerin
- Mother was taught enema technique in clinic
- Mother will call nurse Monday morning after enema administration and x-ray

BMW Monday Clinic and X-ray



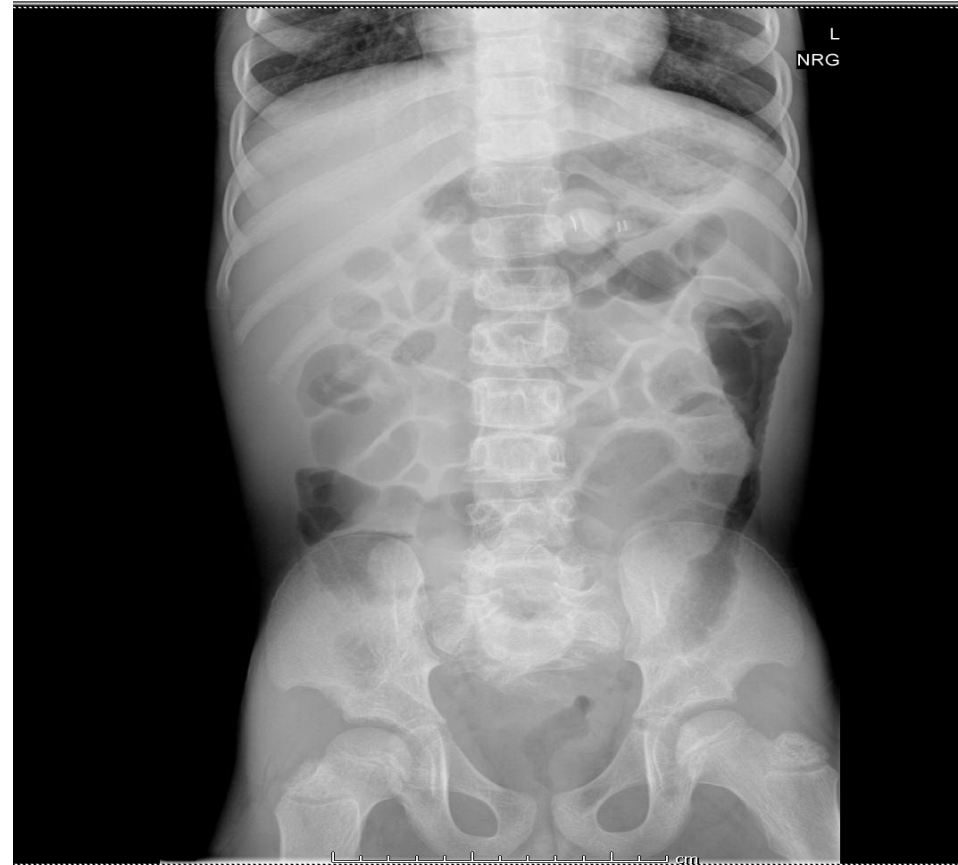
- Reports stool leaking during enema infusion
- Several diarrhea accidents over weekend
- X-ray clean
- Reeducated on enema administration in clinic
- Continue with 400 mL NS + 25 mL glycerin





BMW Day 4 (Tuesday)

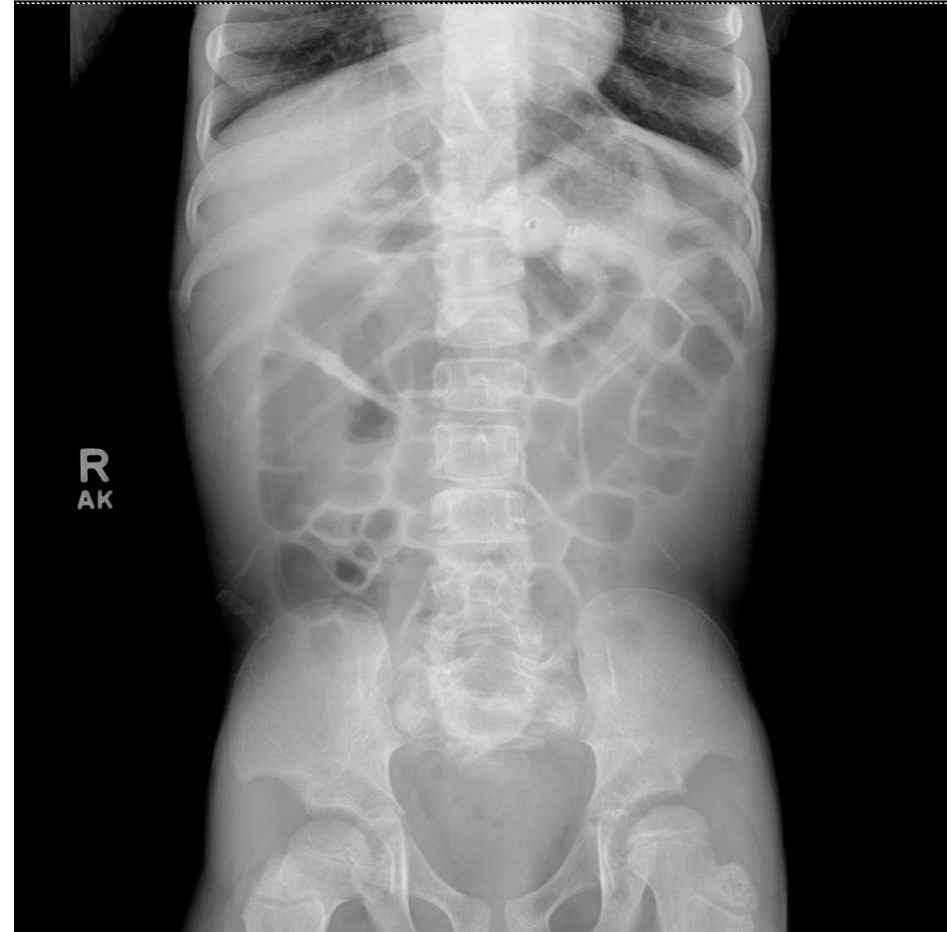- Reports no leaking throughout enema infusion and did not have any other complications
- Reports one small yellow mucous accident in diaper
- X-ray clean
- Continue with same enema of 400 mL NS + 25 mL glycerin



BMW Day 5 (Wednesday)



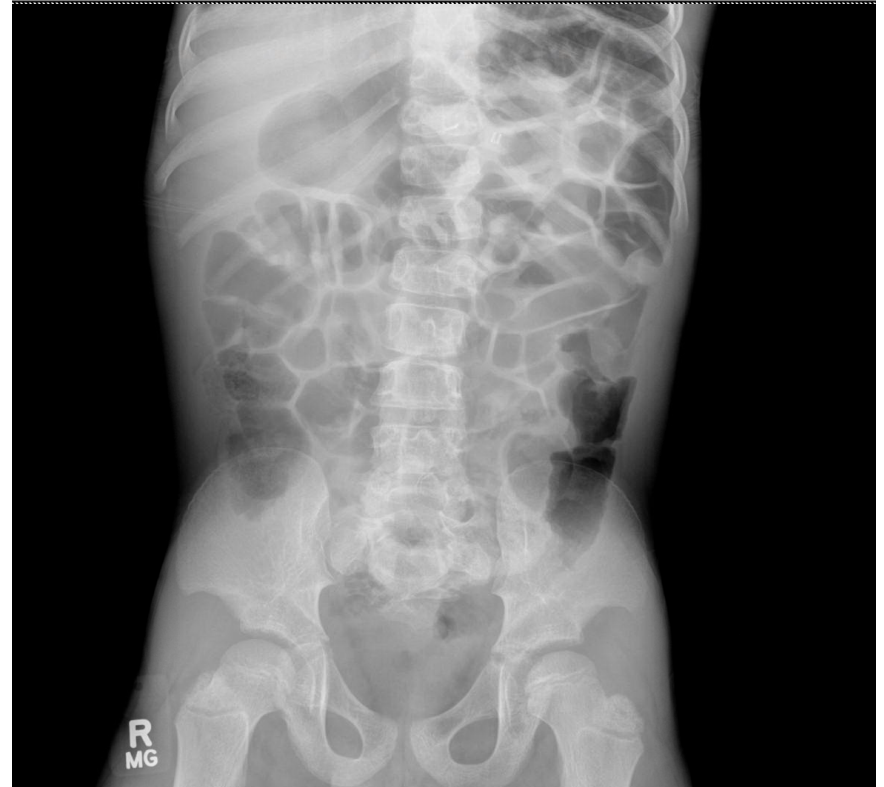- Reports no leaking throughout enema infusion and did not have any other complications
- Accident free
- X-ray clean
- Continue with same enema of 400 mL NS + 25 mL glycerin



BMW Day 6 (Thursday)



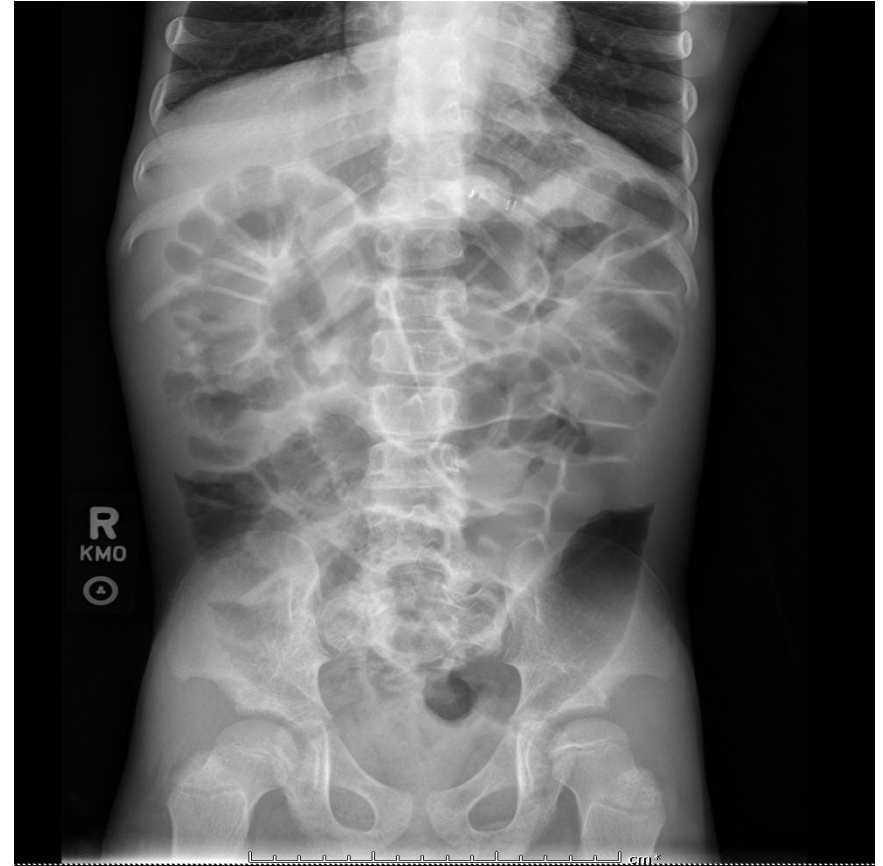- Accident free
- X-ray clean
- Continue with 400 mL NS + 25 mL glycerin



BMW Friday Clinic and X-ray



- Accident free
- X-ray clean
- Continue with 400 mL NS + 25 mL glycerin
- Successful Bowel Management



Key Points



- Determine prognosis for bowel control
- Teach enema technique and administration
- Individualized treatment plan
- Abdominal radiograph to objectively evaluate the result of the enema
- Goal: remain clean of stool in underwear for 24 hours at a time