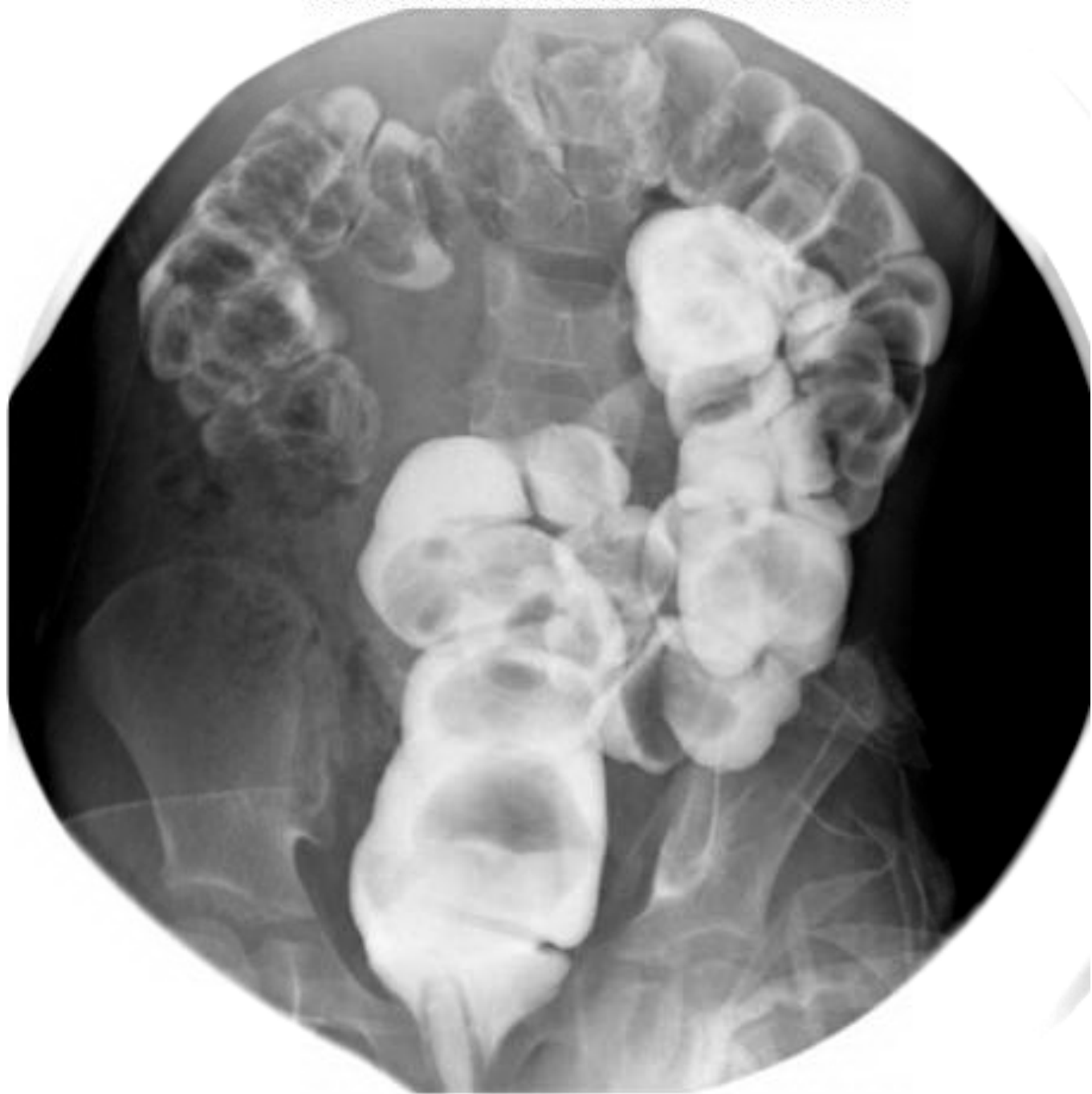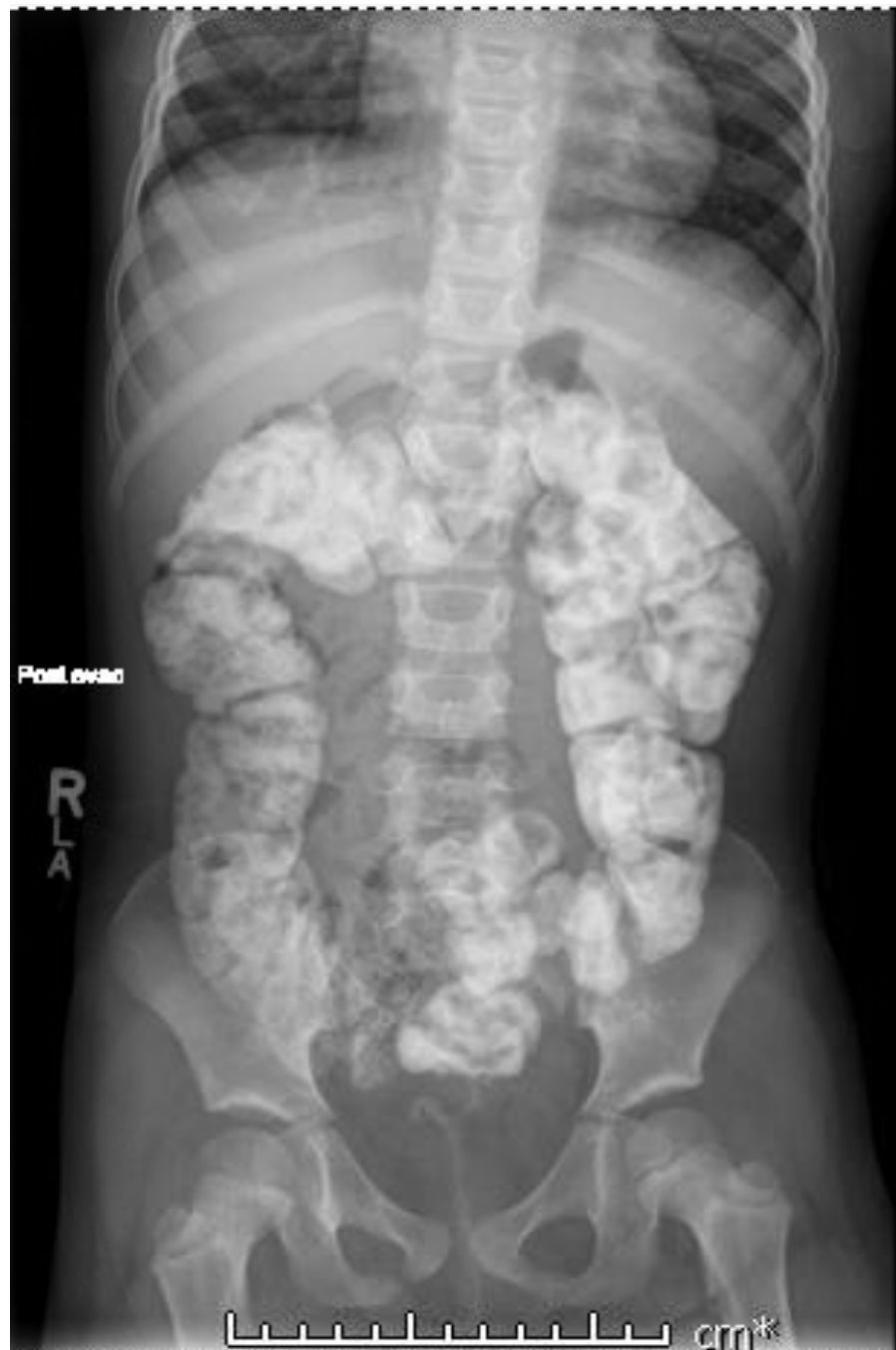




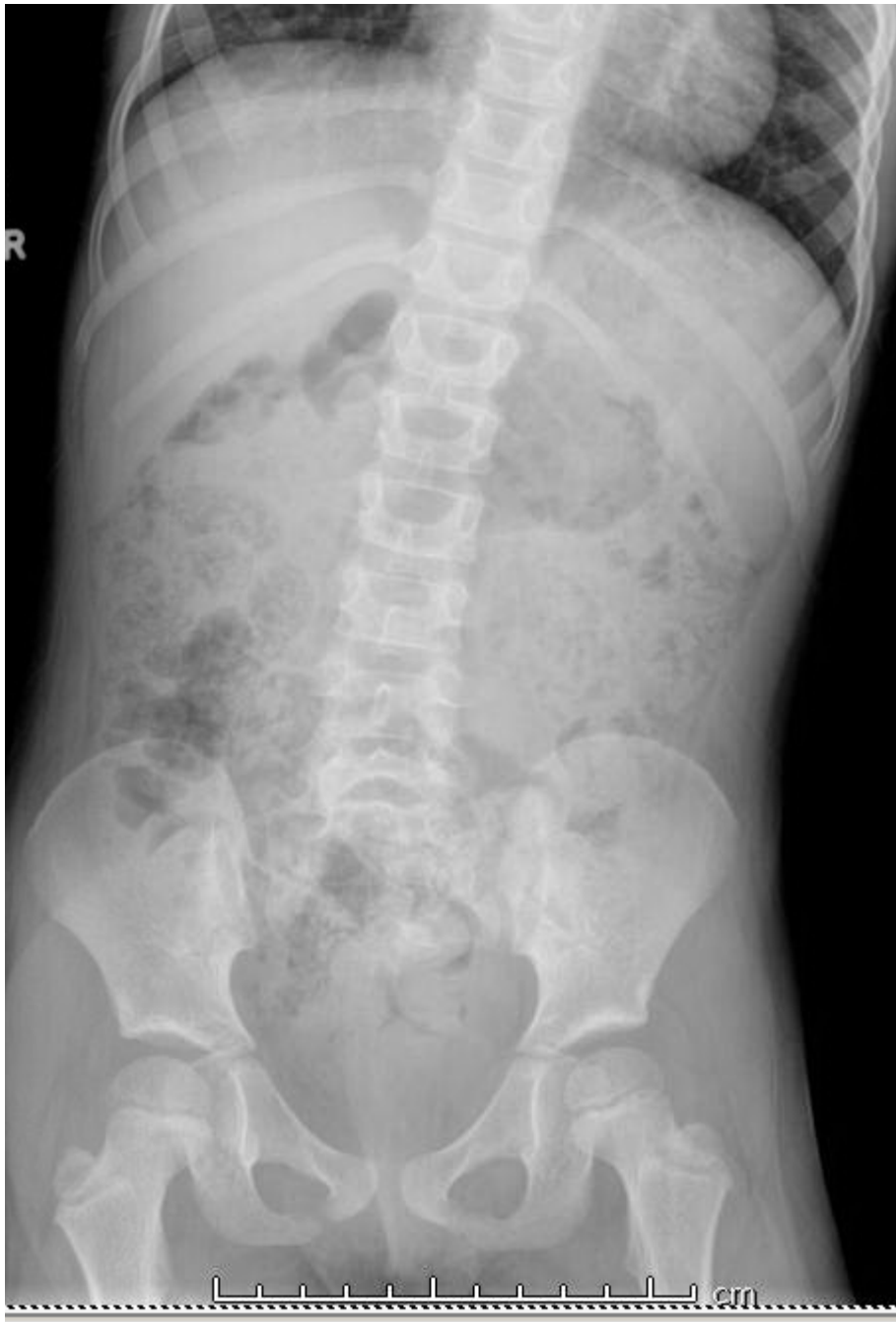Review of Patient

- 6 years old female patient born and operated due to anorectal malformation (recto-perineal fistula)
- Tethered cord
- Sacral ratio = 0.29

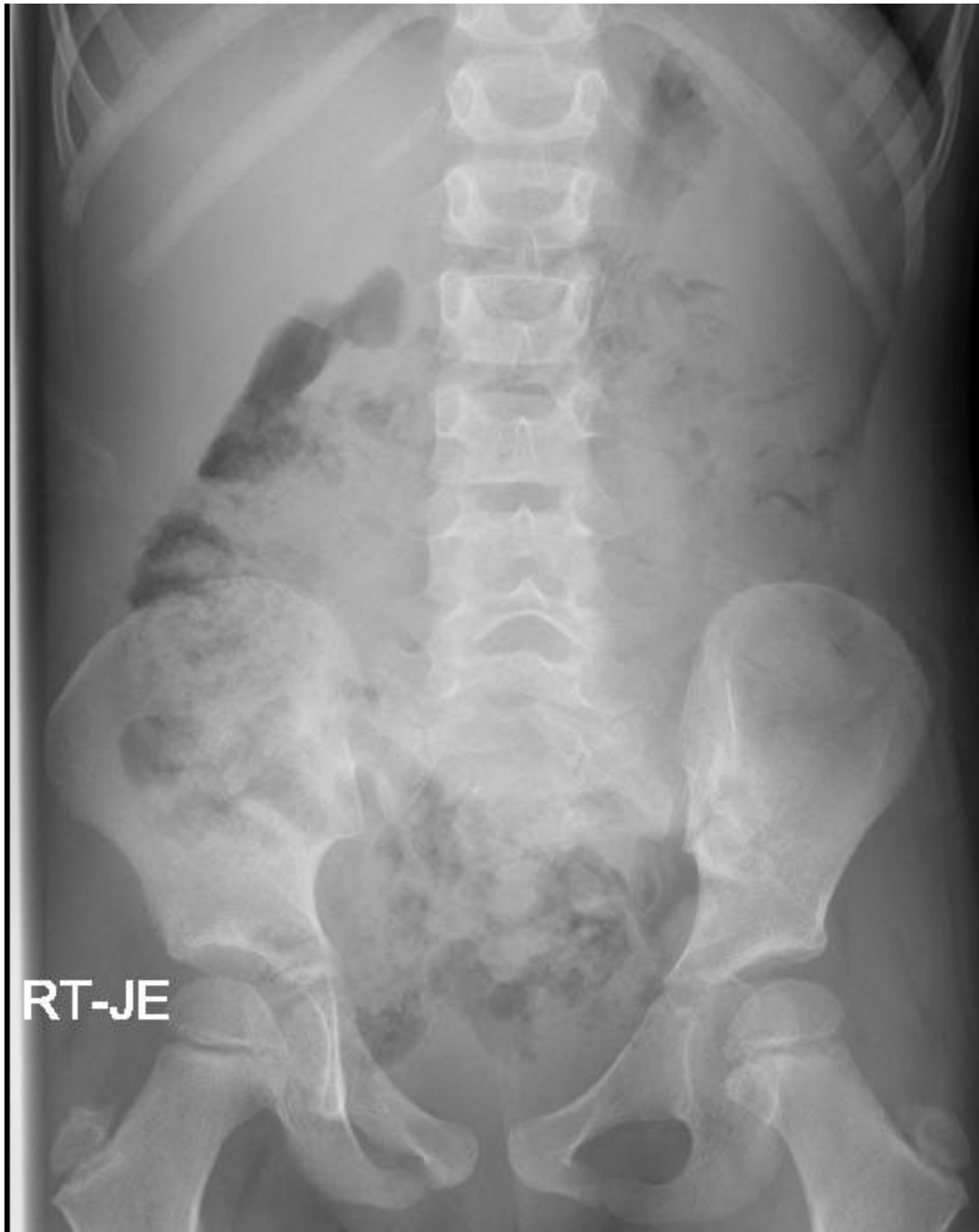



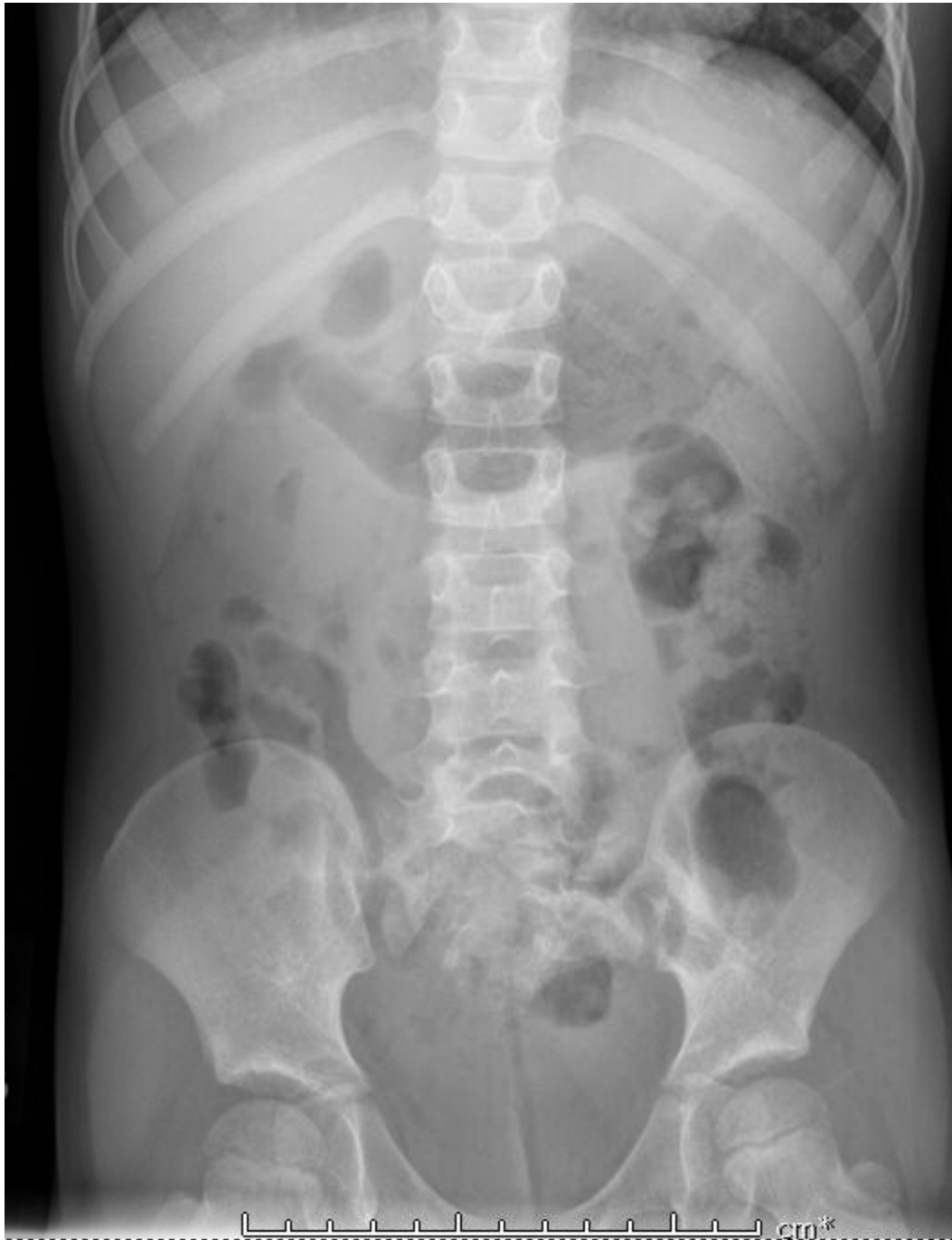- Started on 400 ml of saline and 20 ml of glycerin



- Significant amount of stool and multiple accidents
- Increased to 400 ml + 30 of glycerin



- Less stool on x-ray
- Patient complained of cramping during enema
- 2 "accidents"
- 500ml + 30 ml of glycerin



- Clean patient