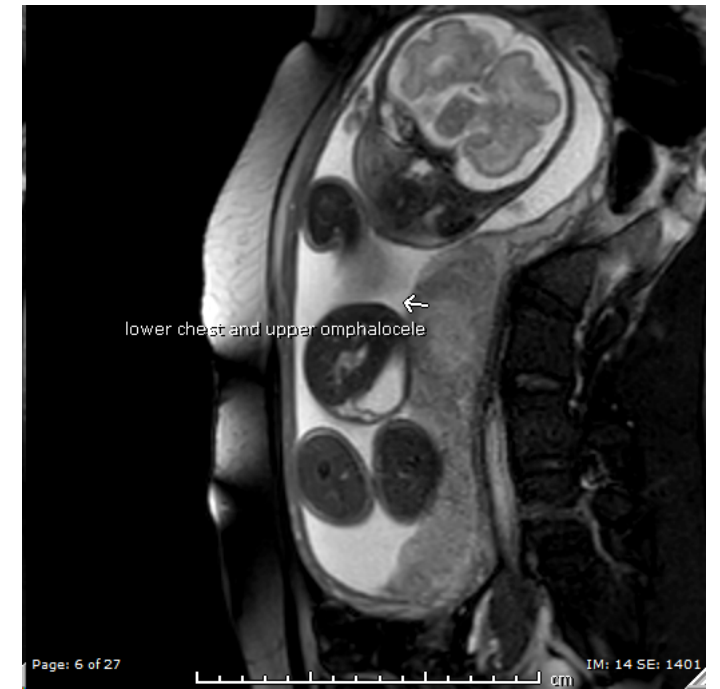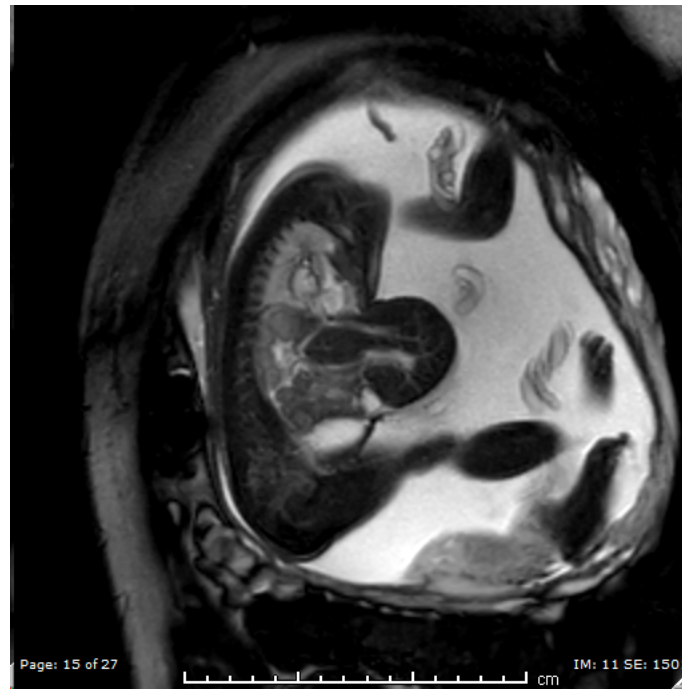


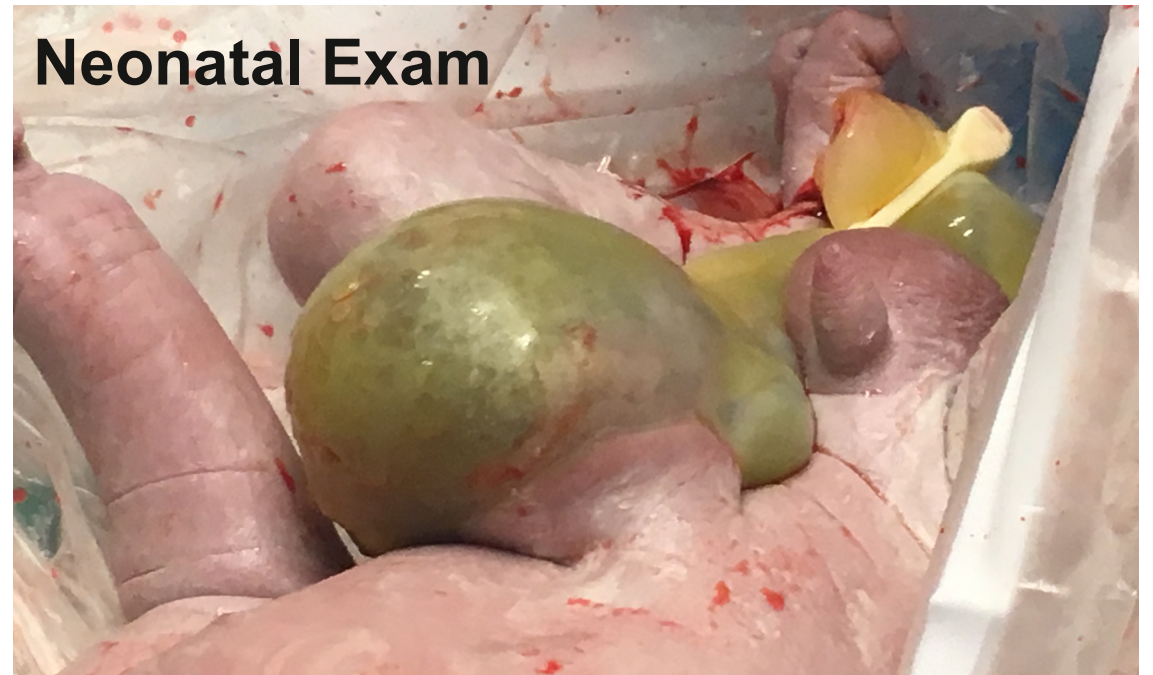
Case # 3

- Prenatally diagnosed Omphalocele
- MRI with 60% of Liver in the sac
- Fetal ECHO: Tetralogy of Fallot
- No other fetal anomalies
- Total lung volume is within normal range

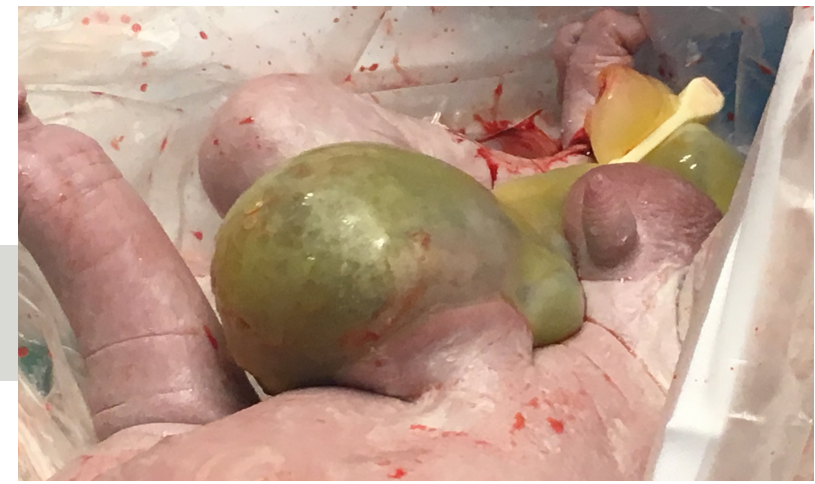


Post natal evaluation

- Baby intubated
- Moderate Ventilator settings
- Evidence of right sided pressures that are > systemic pressures
- Right to left shunting across PDA



Choice of Management



1

Gross-type
closure

2

Paint and
Wait

3

Schuster
Technique

4

Wound Vacuum
therapy





3rd Poll



Panelists Discussion

